

Rabies: ocular pathology

MATTI HALTIA, AHTI TARKKANEN, AND TERO KIVELÄ

From the Helsinki University Eye Hospital and from the Department of Pathology, University of Helsinki, Helsinki, Finland

SUMMARY Ocular pathology in the first European case of human bat-borne rabies is described. The patient was a 30-year-old bat scientist who seven weeks after bat bite developed neurological symptoms and died 23 days later. Rabies virus antigens were detected in brain smears. After extensive virological studies the virus turned out to be a rabies-related virus, closely resembling the Duvenhage virus isolated from bats in South Africa in 1980. By light microscopy focal chronic inflammatory infiltration of the ciliary body and of the choroid was found. PAS-positive exudate was seen in the subretinal and in the outer plexiform layers of the retina, and retinal veins showed endothelial damage and perivascular inflammation. Many of the retinal ganglion cells were destroyed. The presence of rabies-related viral antigen in the retinal ganglion cells was shown by positive cytoplasmic immunofluorescence, though electron microscopy failed to identify definite viral structures in the retina. By immunohistochemistry glial fibrillary acidic protein was observed in the Müller's cells, which are normally negative for this antigen but express it as a reactive change when the retina is damaged. Synaptophysin, a constituent of presynaptic vesicles of normal retinal neurons, was not detected in the retina.

Rabies, a neurotropic rhabdovirus infection of worldwide occurrence, is usually transmitted to humans by animals, most often by dog or cat bite.¹ In addition to transmission via animal bites the virus can penetrate through intact mucous membranes or abraded skin from the saliva of a rabid animal. There are also cases of airborne transmission.^{2,3} However, the only reported cases of human-to-human transmission have occurred via corneal transplants,⁴⁻¹⁰ and rabies virus has been experimentally shown to spread to cornea by axonal transport.^{11,12} In view of this it is surprising that, to the best of our knowledge, there are no reports of ocular pathology in human rabies.

Though human rabies caused by bat bite has long been recognised on the American continent¹ it has only recently become evident that even insectivorous European bats are carriers of rabies-related viruses,^{13,14} constituting a potential hazard to humans.

The purpose of the present paper is to describe the ocular pathology in the first European case of human bat-borne rabies.^{15,16}

Case report

The patient was a 30-year-old man who had previously been in excellent health. He was a zoologist who had been studying bats in different parts of the world but had never been vaccinated against rabies. Four and a half years before his illness he had been bitten by a bat in Malaysia and one year before in Switzerland. Fifty one days before the onset of his neurological symptoms he had been caring for a bat (*Myotis daubentoni*) at his home. The bat had behaved oddly and had bitten him several times. After apparent improvement of the bat the patient had let it go and it was never examined virologically.

Seven weeks later the patient felt numbness and pain in his right arm and neck and developed an ascending paralysis of the Guillain-Barré type. He was admitted to the Helsinki University Central Hospital, where he developed hyperexcitability, hyperventilation, and spasms. Rabies was suspected and the patient was treated intensively on this hypothesis, though virological investigations during life could not confirm the diagnosis. The patient died 23 days after the onset of the first neurological symptoms.

Correspondence to Dr M Haltia, Department of Pathology, University of Helsinki, Haartmaninkatu 3, SF-00290 Helsinki, Finland.

Post-mortem neuropathological and virological studies showed severe encephalitis and peripheral neuritis. Rabies virus antigens were detected in brain smears. After inoculation of brain material into newborn and 3-week-old mice the virus was further characterised by electron microscopy and a set of monoclonal antibodies (Roine *et al.* and Haltia *et al.*, in preparation). It turned out to be closely related to the Duvenhage virus isolated from bats in South Africa in 1980. It was antigenically similar but not identical with the rabies related viruses recently isolated from bats in Germany, Poland, and Denmark.¹⁴

Materials and methods

The eyes were fixed two hours after death in 4% phosphate buffered formaldehyde solution. After fixation they were cut in the horizontal plane and embedded in paraffin. Small selected specimens were postfixed in 2% phosphate-buffered glutaraldehyde and routinely processed for transmission electron microscopy. Paraffin sections were stained with haematoxylin-eosin, van Gieson, and periodic acid-Schiff (PAS) methods. The direct immunofluorescence method was used to detect the presence of rabies antigen in the ocular tissues, by means of a commercial antirabies immune globulin labelled with fluorescein isothiocyanate, isomer I (BBL Microbiology Systems, Cockeysville, MD, USA).

The immunohistochemical stainings to demonstrate neuron-associated and glia-associated antigens in formalin-fixed and paraffin-embedded tissues were carried out with a commercial version (Vectastain ABC Kits for Rabbit and Mouse IgG, Vector Laboratories, Burlingame, CA, USA) of the avidin-biotinylated peroxidase method¹⁷ as previously described in detail.¹⁸⁻²⁰ The primary antibodies used were antineuron specific enolase (Code A589, Lot 084, dilution 1:500) and anti-S-100-protein antisera (Code Z311, Lot 113, dilution 1:100) from Dakopatts a/s (Glostrup, Denmark), monoclonal antisynaptophysin antibodies (Code 902322, Lot 10644526-01, dilution 1:5) from Boehringer-Mannheim Biochemica (Mannheim, FRG), as well as monoclonal antigial fibrillary acidic protein²¹ and anti-200 kD neurofilament triplet protein antibodies (NFI²¹, both diluted 1:50) generously provided by Dr Ismo Virtanen (Department of Pathology, University of Helsinki). Prior to immunohistochemical staining the sections were pretreated with 0.4% pepsin (E Merck, Darmstadt, FRG) in 0.01 N hydrochloric acid for 15 min at 37°C to reduce background and to enhance the intensity of specific staining. Five formalin-fixed and paraffin-embedded human eyes obtained from necropsies at the Department of Forensic Medicine,

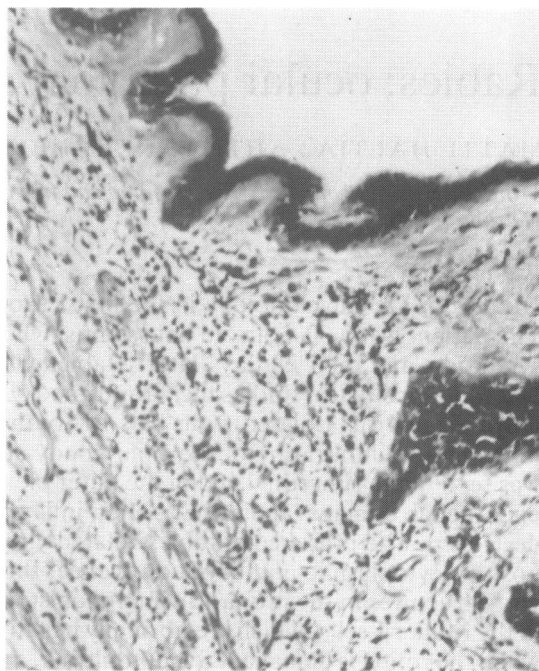


Fig. 1 Chronic mononuclear inflammatory cell infiltration in the ciliary body. PAS, $\times 100$.

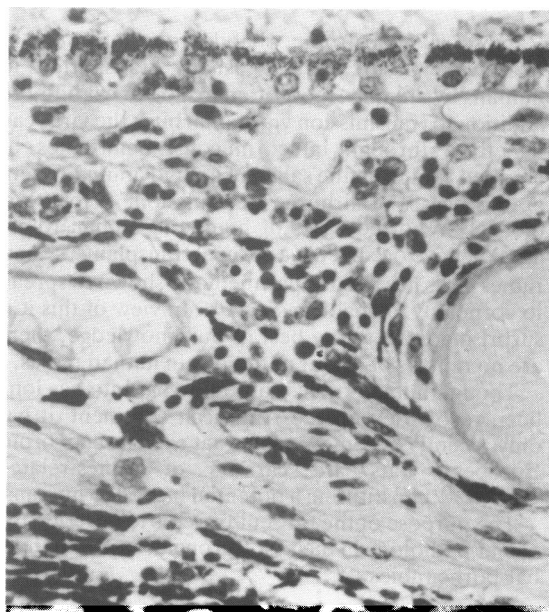


Fig. 2 Focal chorioiditis consisting mainly of lymphocytes and plasma cells. Slight depigmentation of the retinal pigment epithelial cells. PAS, $\times 440$.

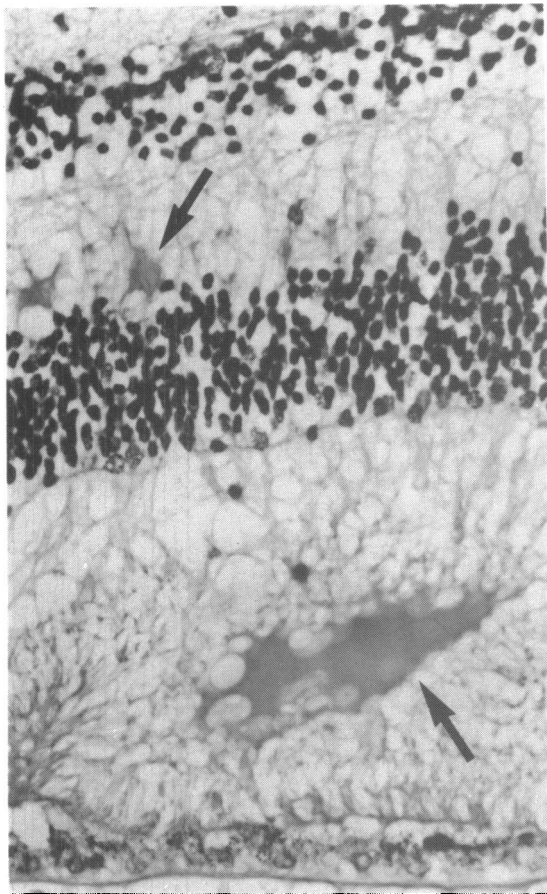


Fig. 3 PAS-positive exudation in the outer plexiform layer and subretinal space (arrows). PAS, $\times 475$.

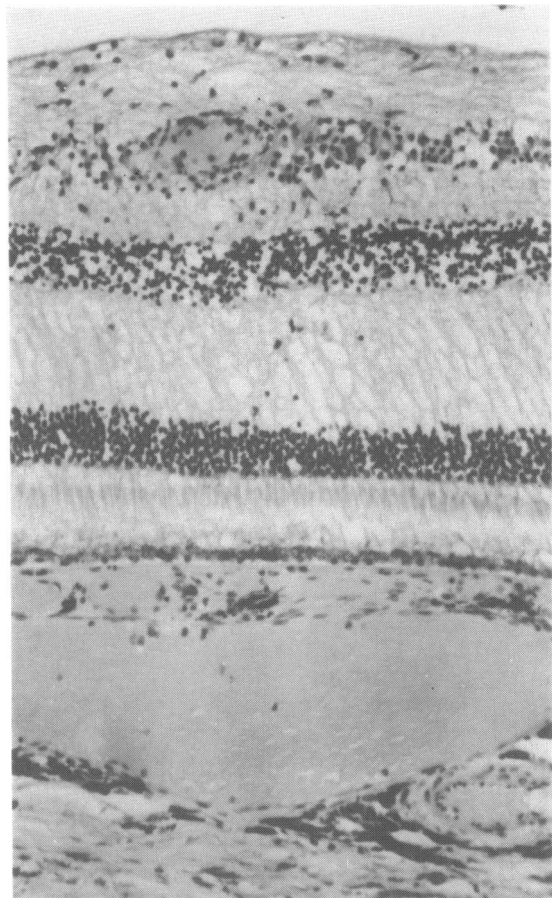


Fig. 4 Good preservation of the visual cells as well as only a slight inflammatory involvement of the choroid are seen. In the nerve fibre layer perivascular inflammatory infiltration is present. PAS, $\times 108$.

University of Helsinki, and previously referred to the Ophthalmic Pathology Laboratory, were used as control post-mortem material. Except for autolytic changes observed in photoreceptor cells and cystic degeneration of the ora serrata region in some specimens, these eyes were entirely normal under the light microscope.

Results

MORPHOLOGICAL FINDINGS

Macroscopic findings were within normal limits. By light microscopy a chronic inflammatory reaction consisting of lymphocytes and plasma cells was seen in the ciliary body and as foci in the choroid (Figs. 1, 2). The pigment epithelium of the retina showed some loss of pigment especially in the posterior fundus (Fig. 2). The overall structure of the sensory retina, including the visual cells, was rather well

preserved. PAS-positive exudate was seen as foci in the subretinal layers as well as in the outer plexiform layer (Fig. 3). In the retinal nerve fibre layer perivascular inflammatory foci consisting of lymphocytes and plasma cells were seen. The endothelium of the retinal veins was destroyed and the lumen almost totally occluded in places (Figs. 4, 5). In semithin sections many of the ganglion cells were seen to be destroyed and the nuclei of many bipolar cells were altered (Fig. 6). As evidence of absence of post-mortem autolysis good preservation of the retinal visual cells can be seen. Electron microscopic studies failed to reveal structures positively identifiable as viral elements.

IMMUNOHISTOCHEMICAL FINDINGS

Sections stained by the rabies antibody showed small

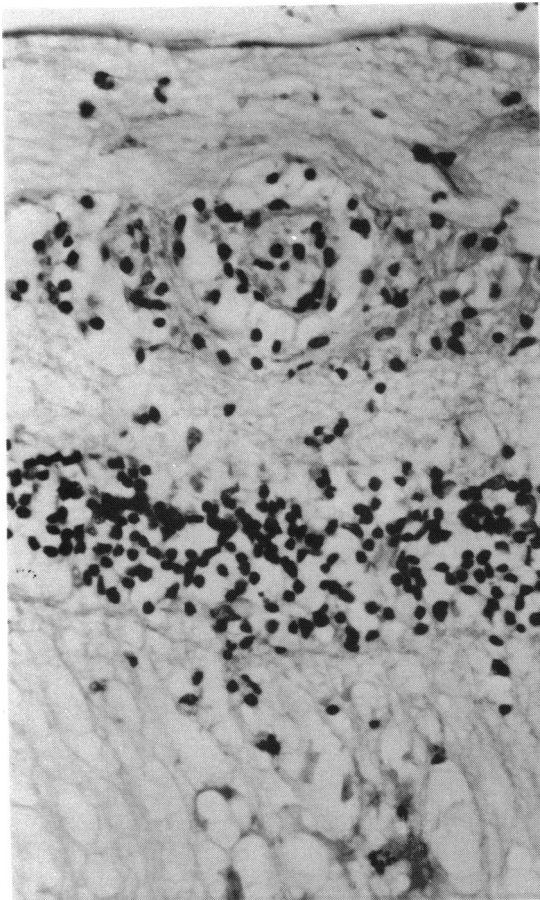


Fig. 5 Vasculitis and perivasculitis have resulted in an almost complete obstruction of the retinal vessel lumen. Exudate in the outer plexiform layer. PAS, $\times 477$.

green intensely fluorescing granules in the cytoplasm of many of the remaining retinal ganglion cells (Fig. 7) (as well as in the patient's brain and in a rabies-infected mouse brain) but not in non-infected control tissues.

In human necropsy eyes of normal appearance on light microscopy the monoclonal antibody to glial fibrillary acidic protein (GFAP) reacted with astrocytes in the nerve fibre and ganglion cell layers (Fig. 8A), as well as with a few Müller's cells close to the ora serrata. In the central retina all Müller's fibres were negative for GFAP. However, in the eye from the rabies patient, Müller's cells expressed GFAP throughout the retina (Fig. 8B). The antiserum to S-100 protein, another marker for retinal glia, labelled retinal astrocytes and a few Müller's cells in all specimens studied.

The polyclonal antiserum to neuron-specific

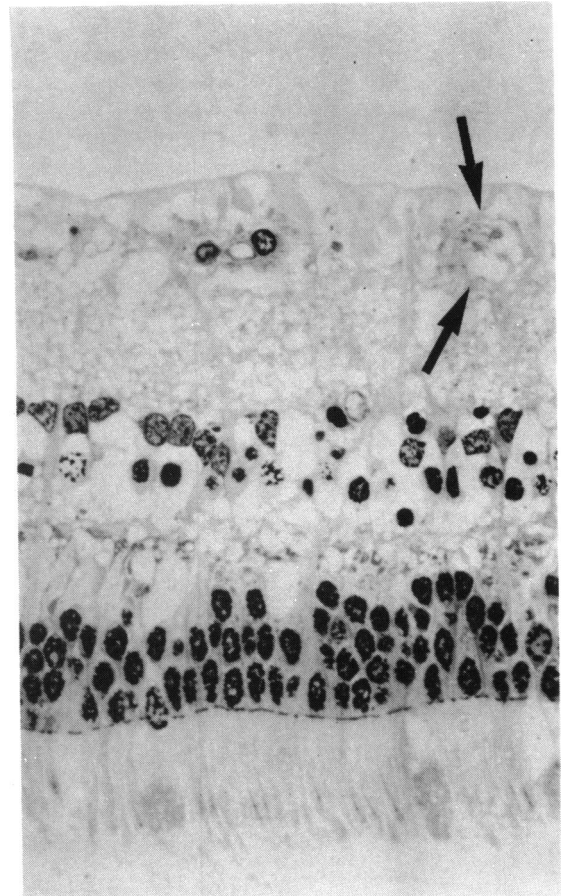


Fig. 6 Semithin section of the retina. Remnants of a destroyed ganglion cell (arrows) and partial disappearance of the bipolar cells are seen while nuclei of the glial cells have been preserved. The rod and cone nuclei show altered chromatin structure. Toluidine blue, $\times 477$.

enolase reacted strongly with photoreceptor cells, but labelled the inner nuclear, inner plexiform, and nerve fibre layers only weakly. A positive reaction was also seen in the remaining ganglion cells. The 200 kD neurofilament triplet protein was detected in neuronal processes of the nerve fibre layer and optic nerve, as well as in occasional nerve fibres in the inner plexiform layer. While these neuronal markers were identically expressed in all retinas examined, both plexiform layers reacted positively for synaptophysin in the control eyes (Fig. 8C), but no reactivity was detected in the eye from the rabies patient (Fig. 8D).

Discussion

Several viruses are known to cause intraocular

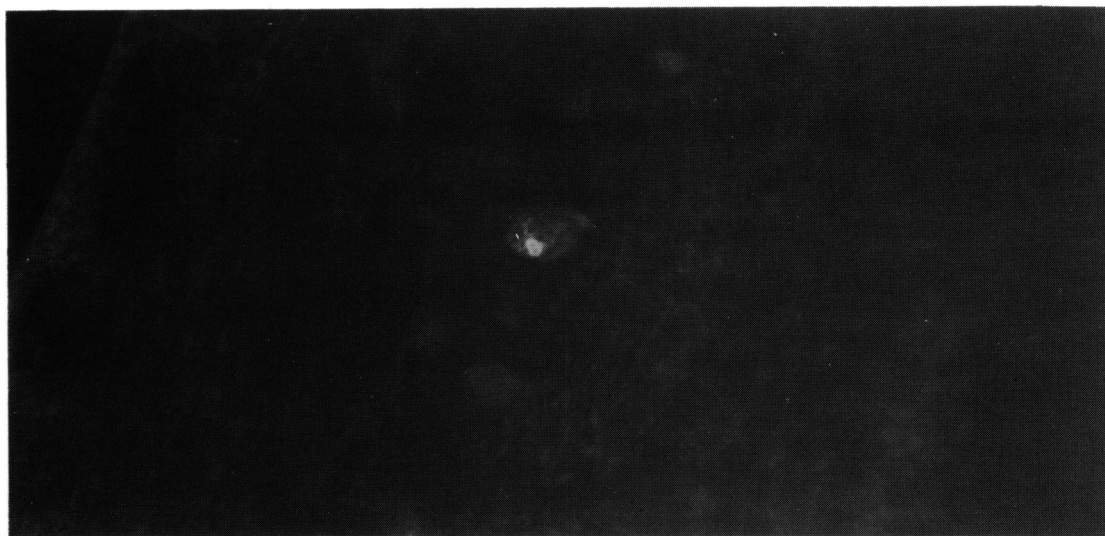


Fig. 7 A remaining ganglion cell shows a strongly fluorescent cytoplasmic inclusion body after staining with rabies antibody. Direct immunofluorescence method, $\times 660$.

lesions. Herpes simplex virus (type 1) is probably the most common cause of viral intraocular inflammation. Uveitis associated with keratitis is characterised by a non-granulomatous inflammatory infiltrate composed of lymphocytes and plasma cells.²² Necrotising retinitis in adults occurs only with immunodeficiency.²³ Varicella zoster may induce

intraocular changes when the nasociliary branch of the trigeminal nerve is involved. When choroiditis is present, it is focal and of the granulomatous type, usually without necrosis.²⁴ In terms of the nature of the uveal inflammatory lesion this type of uveitis is very different from that found in the present case. In cytomegalic inclusion disease a focal progressive

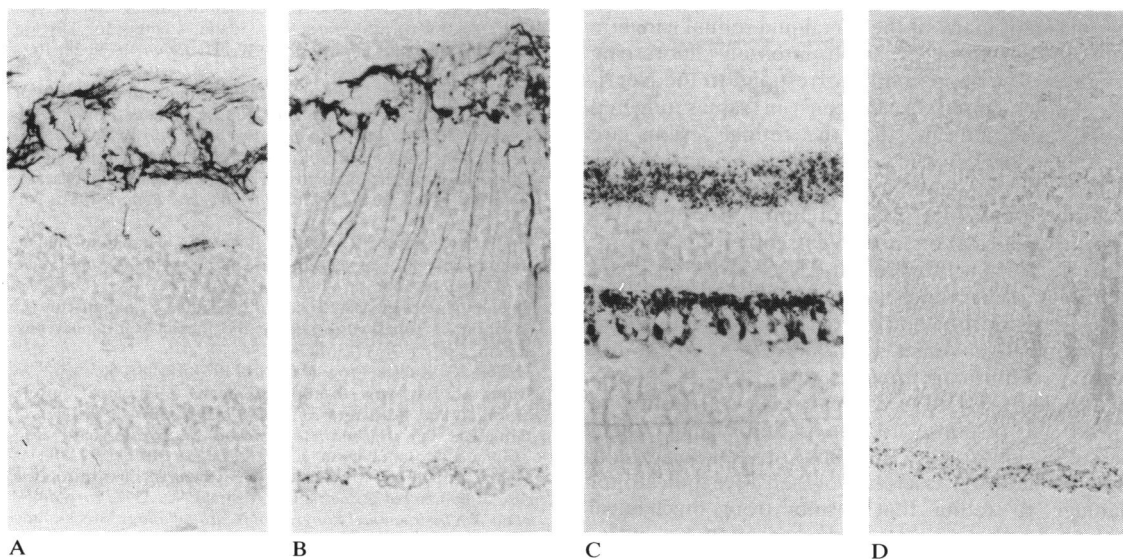


Fig. 8 Differences in antigenic properties of human retina from the rabies patient and from a control necropsy eye (immunoperoxidase staining, $\times 210$). A. In the necropsy eye only astrocytes express glial fibrillary acidic protein (GFAP). B. In the rabies eye an additional positive reaction is observed in slender Müller's fibres reaching towards the outer limiting membrane. C. In the necropsy retina both plexiform layers express synaptophysin. D. The entire rabies infected retina is negative for synaptophysin.

necrotising inflammation is strikingly confined to the retina. It has been repeatedly shown that the vitreous and the choroid are usually spared from any inflammatory changes even in the areas of severe retinal necrosis.^{25, 26} Retinal necrosis is also the main ocular feature of measles retinopathy.²⁷ These findings bear no reflections to the present case, with focal non-granulomatous cyclitis and choroiditis as well as involvement mainly of the inner retina.

To our knowledge no descriptions of ocular pathology in human rabies are available. After inoculation against rabies, neuroretinitis has been described²⁸ as well as bilateral optic neuritis and retinal haemorrhages.²⁹ Rabbits inoculated with rabies virus by Dejean showed extraocular muscle palsy, disappearance of the corneal sensitivity, corneal clouding, venous congestion of the retina and of the optic nerve as well as clouding of the vitreous. At histopathological study Negri-like bodies could be identified in the retinal ganglion cells.³⁰ Argüello and Melita³¹ described two cases, a boy bitten on the right side of his face with facial paralysis of the same side and mydriasis, and an adult showing conjunctival congestion and retinal haemorrhages. In their 100 rabbits inoculated with rabies virus choroidal haemorrhages were found. In comparison with the rabbit study of Dejean³⁰ our findings agree only with regard to the involvement of the retinal ganglion cells. No changes in the vitreous or in the cornea could be identified. Our immunofluorescence studies showed the presence of rabies virus antigen in the cytoplasm of many of the remaining retinal ganglion cells in the form of small intensely fluorescing granules. They apparently correspond to the Negri-like bodies found by Dejean³⁰ in rabies infected rabbits and indicate that the retinal lesions are directly induced by the virus.

Two further immunohistochemical deviations from the usual pattern seen in human necropsy eyes appearing normal on light microscopy were evident. Glial fibrillary acidic protein (GFAP) was observed in Müller's cells, which are normally negative for this antigen.³²⁻³⁸ In the control necropsy eyes only a few GFAP-positive Müller's cells were seen at the ora serrata, confirming previous reports.^{34, 38} It appears that Müller's cells in the rabies eye have accumulated GFAP in response to the retinitis and retinal vasculitis observed. Previous observations have shown that GFAP is a relatively sensitive indicator of damage to retina that results from mechanical trauma,³⁵ photoreceptor degeneration,^{36, 37} intra-ocular tumours,¹⁹ glaucoma, retinal detachment, or inflammatory reaction involving the vitreous cavity.³²

On the other hand synaptophysin, a constituent of presynaptic vesicle membranes that is normally present in synapses of both plexiform layers of the

mammalian retina,³⁹ was absent in the rabies eye. This was unexpected, since synaptophysin was detected in all control necropsy eyes, obtained after comparable delays after death, albeit less strongly than we have seen in surgical specimens. There is a possibility that the amount of synaptophysin in retinal neurons was diminished before death, though this remains conjectural at present. There was no obvious change in the expression of other neuronal markers examined. The inner retinal layers, however, reacted more weakly with antiserum to neuron-specific enolase than is seen in surgical specimens.¹⁸ This may reflect virus-induced degeneration and loss of the retinal ganglion cells and bipolar cells in addition to post-mortem change.

References

- 1 Johnson RT. Rabies. In: Johnson RT. *Viral infections of the nervous system*. New York: Raven Press, 1982: 159-67.
- 2 Constantine DG. Rabies transmission by non-bite route. *Public Health Rep* 1962; **77**: 287-9.
- 3 Centers for Disease Control. Rabies in a laboratory worker—New York: Centers for Disease Control. *Morbidity and Mortality Weekly Report* 1977; **26**: 183-4.
- 4 Baer GM, Shaddock JH, Houff SA, Harrison AK, Gardner JJ. Human rabies transmitted by corneal transplant. *Arch Neurol* 1982; **39**: 103-7.
- 5 Anderson LJ, Winkler WG, Madde DL, Sever JL. Human-to-human transmission of rabies virus by corneal transplant. *N Engl J Med* 1979; **300**: 603-4.
- 6 Anderson LJ, Williams LP Jr, Layde JB, Dixon FR, Winkler WG. Nosocomial rabies: investigation of contacts of human rabies cases associated with a corneal transplant. *Am J Public Health* 1984; **74**: 370-2.
- 7 Centers for Disease Control. Human-to-human transmission of rabies by corneal transplant—Idaho. Centers for Disease Control. *Morbidity and Mortality Weekly Report* 1979; **28**: 109-11.
- 8 Centers for Disease Control. Human-to-human transmission of rabies via a corneal transplant—France. Centers for Disease Control. *Morbidity and Mortality Weekly Report* 1980; **29**: 25-6.
- 9 Centers for Disease Control. Human-to-human transmission of rabies via corneal transplants—Thailand. Centers for Disease Control. *Morbidity and Mortality Weekly Report* 1981; **30**: 473-4.
- 10 Houff SA, Burton RC, Wilson RW, et al. Human-to-human transmission of rabies virus by corneal transplant. *N Engl J Med* 1979; **300**: 603-4.
- 11 Duenas A, Belsey MA, Escobar J, Medina P, Sammartin C. Isolation of rabies virus outside the human central nervous system. *J Infect Dis* 1973; **127**: 702-4.
- 12 Debbie JG. Rabies. *Progr Med Virol* 1974; **18**: 241-56.
- 13 Bitsch V. Bat virus—Europe. Centers for Disease Control. *Morbidity and Mortality Weekly Report* 1986; **35**: 430-2.
- 14 Grauballe PC, Baagoe HJ, Fekadu M, Westergaard JM, Zoffmann H. Bat rabies in Denmark. *Lancet* 1987; **i**: 379-80.
- 15 Haltia M, Hillbom M, Valle M, Neuvonen E. First European case of human bat-borne rabies. Abstract No. 359. *Proceedings of the Xth International Congress of Neuropathology*. Stockholm: 1986: 178.
- 16 Lumio J, Hillbom M, Roine R, et al. Human rabies of bat origin in Europe. *Lancet* 1986; **i**: 378.
- 17 Hsu S-M, Raine L, Fanger H. Use of avidin-biotin-peroxidase complex (ABC) in immunoperoxidase techniques: a comparison between ABC and unlabeled antibody (PAP) procedures. *J Histochem Cytochem* 1981; **29**: 577-80.

- 18 Kivelä T. Neuron-specific enolase in retinoblastoma. An immunohistochemical study. *Acta Ophthalmol (Kbh)* 1986; **64**: 19–25.
- 19 Kivelä T, Tarkkanen A, Virtanen I. Intermediate filaments in the human retina and retinoblastoma. An immunohistochemical study of vimentin, glial fibrillary acidic protein, and neurofilaments. *Invest Ophthalmol Vis Sci* 1986; **27**: 1075–84.
- 20 Kivelä T, Tarkkanen A. S-100 protein in retinoblastoma revisited. An immunohistochemical study. *Acta Ophthalmol (Kbh)* 1986; **64**: 664–73.
- 21 Virtanen I, Miettinen M, Lehto V-P, Kariniemi A-L, Paasivuo R. Diagnostic application of monoclonal antibodies to intermediate filaments. *Ann NY Acad Sci* 1986; **455**: 635–48.
- 22 Naumann G, Gass JDM, Font RL. Histopathology of herpes zoster ophthalmicus. *Am J Ophthalmol* 1968; **65**: 533–41.
- 23 Grutzmacher RD, Henderson D, McDonald PJ, Coster DJ. Herpes simplex chorioretinitis in a healthy adult. *Am J Ophthalmol* 1983; **96**: 788–96.
- 24 Kreibitz W. Histologische Befunde bei Herpes Zoster ophthalmicus. *Ber Dtsch Ophthalmol Ges* 1938; **52**: 461–2.
- 25 Wyhinny GJ, Apple DJ, Guartella FR, Vygants CM. Adult cytomegalic inclusion retinitis. *Am J Ophthalmol* 1973; **76**: 773–81.
- 26 Tarkkanen A, Merenmies L, Holmström T. Ocular involvement in congenital cytomegalic inclusion disease. *J Pediatr Ophthalmol Strabismus* 1972; **9**: 82–6.
- 27 Haltia M, Tarkkanen A, Vaheeri A, Paetau A, Kaakinen K, Erkkilä H. Measles retinopathy during immunosuppression. *Br J Ophthalmol* 1978; **62**: 356–60.
- 28 Fodor G. Myelitis, chronische lymphocytäre Meningitis und Papilloretinitis nach Lyssaschutzimpfung. *Wien Z Neurrenheilkd* 1950; **3**: 36–41.
- 29 Pagliarani N. Complicanze neuro-oculari della vaccinazione antirabbica. *Riv Oto-neuro-oftalmol* 1951; **26**: 200–12.
- 30 Dejean Ch. Les modifications du fond d'oeil dans la rage chez le lapin. *Bull Soc Fr Ophthalmol* 1937; **50**: 247–54.
- 31 Argüello DM, Melita AM. Alteraciones que la rabia y su tratamiento provocan en el ojo y anexos. *Arch Ofal B Aires* 1949; **24**: 116–22.
- 32 Hiscott PS, Grierson I, Trombetta CJ, Rahi AHS, Marshall J, McLeod D. Retinal and epiretinal glia—an immunohistochemical study. *Br J Ophthalmol* 1984; **68**: 698–707.
- 33 Molnar ML, Stefansson K, Marton LS, Tripathi RC, Molnar GK. Distribution of S-100 protein and glial fibrillary acidic protein in normal and gliotic human retina. *Exp Eye Res* 1984; **38**: 27–34.
- 34 Kumpulainen T, Dahl D, Korhonen LK, Nyström SHM. Immunolabeling of carbonic anhydrase isoenzyme C and glial fibrillary acidic protein in paraffin-embedded tissue sections of human brain and retina. *J Histochem Cytochem* 1983; **31**: 879–86.
- 35 Bignami A, Dahl D. The radial glia of Müller in the rat retina and their response to injury. An immunofluorescence study with antibodies to the glial fibrillary acidic (GFA) protein. *Exp Eye Res* 1979; **28**: 63–9.
- 36 Eisenfeld AJ, Bunt-Milam AH, Sarthy PV. Müller cell expression of glial fibrillary acidic protein after genetic and experimental photoreceptor degeneration in the rat retina. *Invest Ophthalmol Vis Sci* 1984; **25**: 1321–8.
- 37 Shaw G, Weber K. The intermediate filament complement of the retina: a comparison between different mammalian species. *Eur J Cell Biol* 1984; **33**: 95–104.
- 38 Bromberg JS, Schachner M. Localization of nervous system antigens in retina by immunohistology. *Invest Ophthalmol Vis Sci* 1978; **17**: 920–4.
- 39 Wiedenmann B, Franke WW. Identification and localization of synaptophysin, an integral membrane glycoprotein of M_r 38 000 characteristic of presynaptic vesicles. *Cell* 1985; **41**: 1017–28.

Accepted for publication 3 December 1987.