

Case reports

Acquired Brown's syndrome associated with Hurler-Scheie's syndrome

J A BRADBURY, L MARTIN, AND I M STRACHAN

From the Department of Ophthalmology, University of Sheffield, Royal Hallamshire Hospital, Glossop Road, Sheffield S10 2JF

SUMMARY A 5-year-old Caucasian girl with known Hurler-Scheie's syndrome (mucopolysaccharidosis) developed a right Brown's syndrome while under orthoptic review. There was no evidence of trauma or inflammation of the superior oblique tendon, trochlea, or surrounding tissues. The Brown's syndrome in this case may be due to shortening of the superior oblique tendon, associated with the shortening of long tendons of the arms and feet, which is common in Hurler-Scheie's syndrome.

Hurler-Scheie's syndrome is an autosomal recessive mucopolysaccharidosis which results in reduced activity of the enzyme α -L-iduronidase with subsequent accumulation in the tissues of heparan and dermatan sulphate. The syndrome represents a spectrum of disease, patients with the more severe, rapidly progressive disease being classified as Hurler's syndrome (mucopolysaccharidosis I-M) and those less severely affected as Scheie's syndrome (mucopolysaccharidosis I-S).¹

The clinical features of Hurler-Scheie's syndrome are presented in Table 1.

Brown's syndrome is due to a mechanical limitation of movement of the superior oblique tendon, which results in a limitation of elevation in adduction. The condition may be congenital or acquired. Most cases of acquired Brown's syndrome are due to trauma or inflammation of the superior oblique tendon/trochlea complex. So far no cases have been described of an acquired Brown's syndrome in association with Hurler-Scheie's syndrome.

Case report

The patient, a 5-year-old girl with known Scheie's syndrome, was first referred to the Ophthalmic Department in 1985 having developed bilateral corneal clouding (her younger brother has Hurler's syndrome). General examination revealed abnormal facies (Fig. 1), coarse hair, and contracture of fingers (Fig. 2), elbows, and hips. She was of normal height and intelligence; orthoptic assessment showed her to

be orthophoric, with unaided vision of 6/9 right 6/9 left. Slit-lamp biomicroscopy confirmed the presence of mild corneal clouding (Fig. 3), but there were no other ocular signs of Scheie's syndrome.

When she attended some eight months later her mother reported that she had recently noticed the development of a convergent squint. On examination the patient had an esotropia measuring 20 prism dioptres base out both for near and distance. Wearing the full hypermetropic correction (OD +4.0, OS +3.50) reduced the angle of deviation to 8 prism dioptres base out for near and distance.

There was no change in her squint or visual acuity

Table 1 Clinical features of Hurler-Scheie's syndrome

Non-ocular features²

1. Abnormal facies, enlarged skull, thickened lips, prominent forehead, coarse hair, abnormally low ears
2. Contracture of hips, knees, elbows, and fingers
3. Hepatosplenomegaly
4. Diastasis recti, umbilical hernia
5. Growth retardation
6. Mental retardation
7. Heart defects

Ocular features

1. Clouding of the cornea: the opacities are stromal and Bowman's membrane is absent
2. Defective dark adaptation and ERG
3. Retinal degeneration
4. Optic atrophy
5. Ptosis
6. Strabismus (esotropia)
7. Glaucoma

Correspondence to J A Bradbury, FRCS Glas.

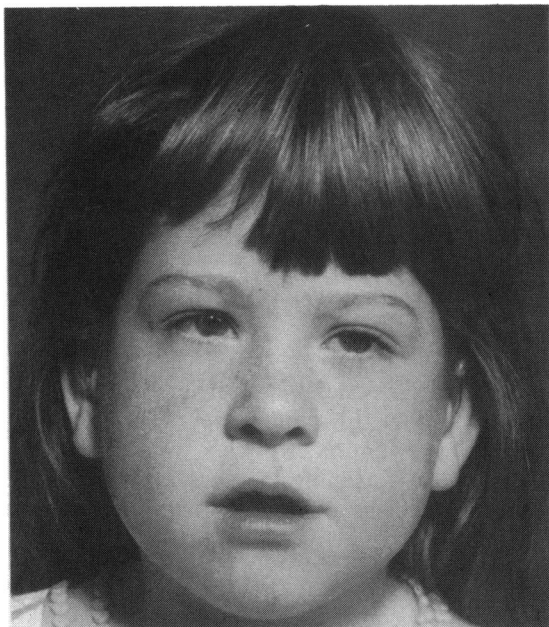


Fig. 1 Five-year-old girl with typical facies of Scheie's syndrome.

until December 1985, when her mother reported that she had 'started to look at her strangely'. There had been no change in her general health, she had complained of no pain, and there was no history of trauma. On examination there was no swelling or tenderness and no sign of trauma. Orthoptic examination (Fig. 4) revealed a marked limitation of the right eye on attempted laevo elevation with only a very slight limitation of the right eye in dextro elevation. She had also developed an 'A' esotropia which measured 20 prism dioptres base out for near and distance in the primary position, which increased

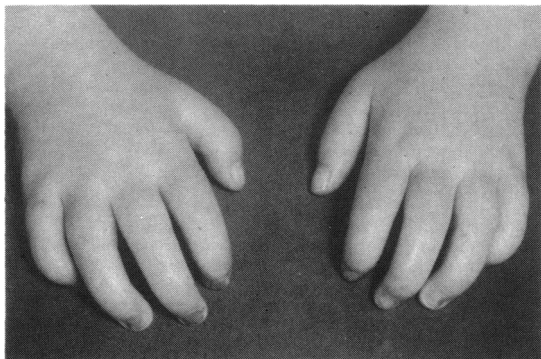


Fig. 2 Hands of 5-year-old girl with Scheie's syndrome, showing contracture of fingers.

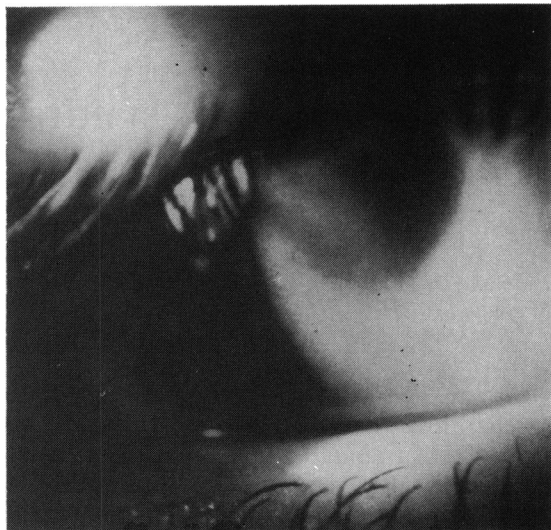

Fig. 3 Corneal clouding seen in Scheie's syndrome.

to 35 prism dioptres base out in elevation and decreased to 4 prism dioptres base out in full depression. Unfortunately it was not possible to perform a forced duction test owing to poor patient co-operation.

INVESTIGATION

A high resolution CT scan of both orbits was performed which showed no bony or soft tissue abnormality and no evidence of trauma or inflammation. A Hess chart (Fig. 5) confirmed the diagnosis of a right Brown's syndrome. This has remained constant since 1985.

Discussion

Most cases of acquired Brown's syndrome are due to trauma or inflammation of the superior oblique muscle, tendon, trochlea, or surrounding tissues.³ It may also be caused by a tucking of the superior oblique tendon. Less well known causes include orbital metastasis.⁴ In some non-traumatic cases nodules are thought to develop on the superior oblique tendon.⁵ Such cases are often associated with rheumatoid arthritis or systemic lupus erythematosus and produce a palpable click on eye movement. In all cases the result is a mechanical limitation of the tendon/muscle complex producing defective upgaze in adduction.

Clinically the patient complains of diplopia in adduction and pain on movement, and may have tenderness over the trochlear region. On testing ocular movement there is reduced elevation in adduction. There may be a V exotropia or an A

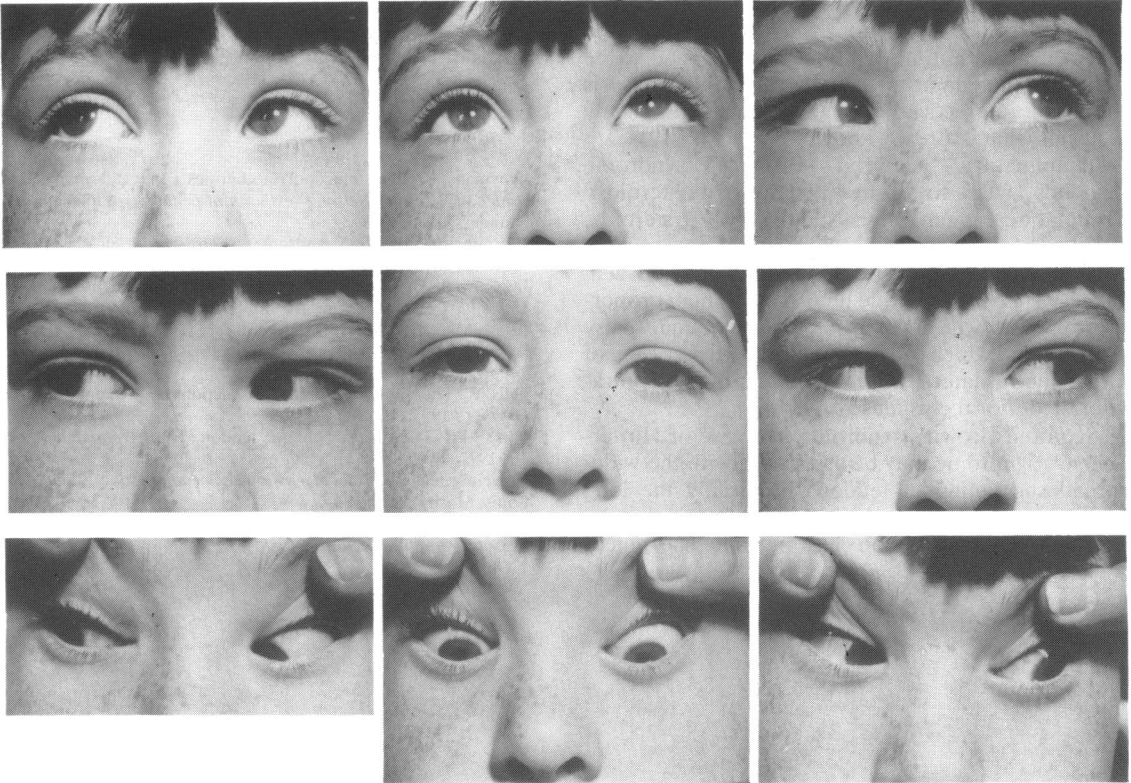

Fig. 4 Nine positions of gaze showing a right Brown's syndrome.

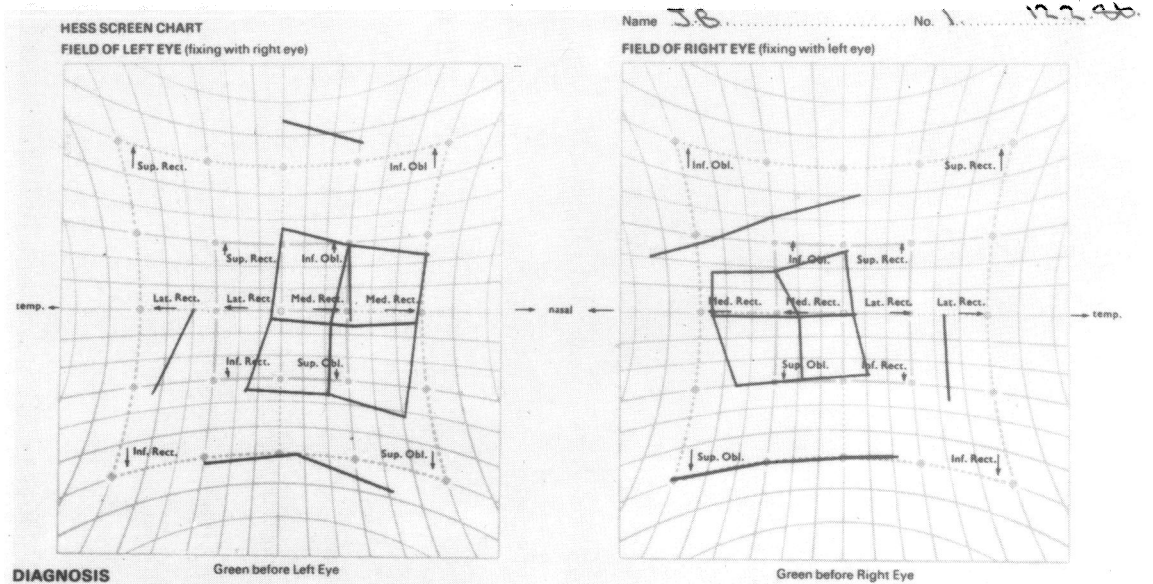


Fig. 5 Hess chart showing mechanical limitation of superior oblique tendon.

esotropia.⁵ A Hess chart will show the limitation to be mechanical; a traction test will confirm the mechanical limitation. This test would need to be done under general anaesthetic in children and is therefore impracticable, and in most cases only confirms what is already known.

Inflammatory acquired Brown's syndrome responds well to local injection of steroids.³ Traumatic cases generally respond poorly to steroids, but they may resolve spontaneously; if not, surgery may be needed. Both Parks⁶ and Von Noorden⁷ suggest a superior oblique tenotomy. A high proportion of these will develop a superior oblique palsy after surgery which can be managed with recession of either the ipsilateral inferior oblique or the contralateral inferior rectus muscle.

Acquired Brown's syndrome in a case of Hurler-Scheie's syndrome may be associated with the widespread shortening of tendons, especially the long tendons in the hands and feet. Possibly in this case the superior oblique tendon has become shortened,

thereby producing a Brown's syndrome.

Brown's syndrome has not been noted previously in cases of Hurler-Scheie's syndrome.

References

- 1 Dorfman A. The mucopolysaccharides. In: Behrman RE, Vaughan VC, eds. *Nelson's textbook of pediatrics*. Philadelphia: Saunders, 1983: 1651-3.
- 2 Wormington J. Hurler's syndrome. *Br Orthopt J* 1986; **43**: 76.
- 3 Trimble RB, Kelly V, Mitchell M. Acquired Brown's syndrome. In: Ravault D, Lenk M. *Transactions of the Fifth International Orthoptic Congress*. Lyon: LIPS, 1983: 267-72.
- 4 Booth-Mason S, Kyle GM, Rossar M, Bradbury P. Acquired Brown's syndrome: an unusual cause. *Br J Ophthalmol* 1985; **69**: 791-4.
- 5 Fells P. The superior oblique: its actions and anomalies. *Br Orthopt J* 1975; **32**: 43-53.
- 6 Parks MM. The superior oblique tendon. *Trans Ophthalmol Soc UK* 1977; **97**: 288-305.
- 7 Von Noorden GK. *Binocular vision and ocular motility*. 2nd ed. St Louis: Mosby, 1980: 384-7.

Accepted for publication 9 June 1988.