

# Sex linked juvenile retinoschisis with optic disc and peripheral retinal neovascularisation

RUSSELL PEARSON AND JONATHAN JAGGER

*From the Retinal Diagnostic Department, Moorfields Eye Hospital, City Road, London EC1V 2PD*

We wish to report a case of sex linked juvenile retinoschisis with optic disc and peripheral retinal neovascularisation. Both forms of neovascularisation resolved following panretinal photocoagulation. Optic disc neovascularisation has not been previously reported with this condition, though peripheral retinal vascular anomalies are well recognised.

## Case report

The patient, a 24-year-old white male, first attended Moorfields Eye Hospital at the age of 7 years when referred with poor visual acuity at school eye testing. At that time his best corrected visual acuities were Snellen 6/36 in the right and 6/24 in the left eye. Slit-lamp biomicroscopic examination revealed bilateral foveal retinoschisis in a 'wheel-like' configuration (Fig. 1). Peripheral retinoschisis was absent. A general examination gave normal results. Low visual aids were dispensed when, at the age of 10 years, binocular distance visual acuity had deteriorated to 6/60 unaided.

There was a family history of sex linked retinoschisis, the patient's maternal grandfather having the condition. The mother and the twin sister of the patient were not, however, affected.

At the age of 20 the patient was re-examined after developing a symptomatic floater in the visual field of the right eye. His best corrected visual acuities at this time were 1/60 right and 6/36 left. Vitreous haemorrhage precluded examination of the fundus of the right eye. The right visual acuity improved to 6/36 as the vitreous haemorrhage cleared, but no source for the haemorrhage could be detected clinically at this stage. A further three vitreous haemorrhages occurred in the right eye during the next seven months, after which time fine, forward new vessels were detected at the right optic disc (Fig. 2) together with tortuosity of the peripheral retinal vessels. Flat new vessels in the retinal periphery were observed in the superior nasal quadrant of the left eye.

Correspondence to Mr R Pearson, FRCS.

Fluorescein angiography showed leakage of the dye from new vessels originating on the right optic disc (Fig. 3) and in the retinal periphery, together with areas of non-perfusion of the retinal capillary circulation in the periphery. There was leakage from peripheral retinal new vessels in the left eye, but no disc neovascularisation was present.

Panretinal photocoagulation of the right eye with argon blue-green laser was administered in three sessions over a five-month period, with regression of the neovascularisation within four months of the final treatment session (Fig. 4). A horizontal traction fold of the internal limiting membrane was noted to have formed across the right macula (Fig. 4). Laser treatment was not administered to the left eye, and the peripheral new vessels underwent sheathing followed by spontaneous resolution.

Three years after panretinal photocoagulation the best attainable visual acuities were 6/36 right, and 6/60 left. Ophthalmoscopy showed bilateral cystoid macular oedema, peripheral retinoschisis, patchy sheathing of peripheral retinal vessels, many of which were straight and thin, peripheral retinal grey dots, and bilateral vitreous membranes. The right fundus also showed markedly pigmented scars due to the previous laser treatment (Fig. 4).

Blood tests, including syphilis serology and a glucose tolerance test, were normal. Electrodiagnostic tests showed no response to flash electroretinogram in either eye, but the electro-oculogram was 210% in the right and 200% in the left eye. B-scan ultrasonic examination showed detachment of the posterior vitreous face in both eyes, with intragel opacities.

## Discussion

Peripheral vascular anomalies, considered by some authors often to pass undiagnosed, have been well described in sex linked juvenile retinoschisis. The peripheral retinal or schitic areas may be relatively avascular. Aberrant underdeveloped capillaries have

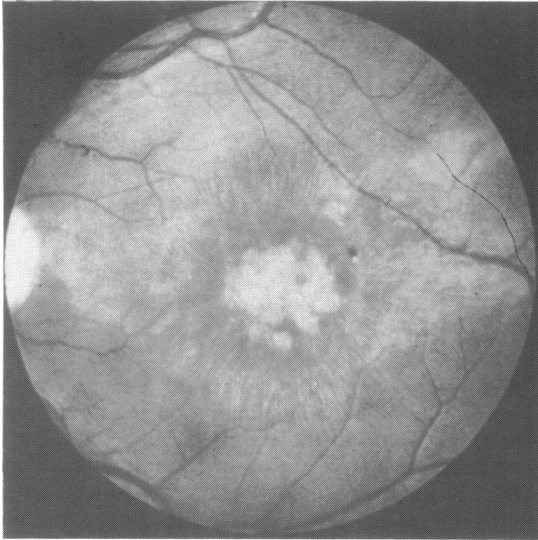


Fig. 1 Left eye. Foveal retinoschisis in a 'wheel-like' configuration with microcysts and radial folds of the internal limiting membrane surrounding a central atrophic lesion.

been noted in retina central to such schitic areas, associated with greyish white dendritiform structures of vascular origin in the deeper layer of the peripheral retinal schisis itself.<sup>1-4</sup> Several authors have described arborisation (neovascularisation) of the peripheral retinal vasculature.<sup>1,5-8</sup> Some cases show slow circulation in one retinal quadrant or delayed filling of the central retinal artery.<sup>3</sup> The formation and coalescence of breaks in the inner layer of areas of

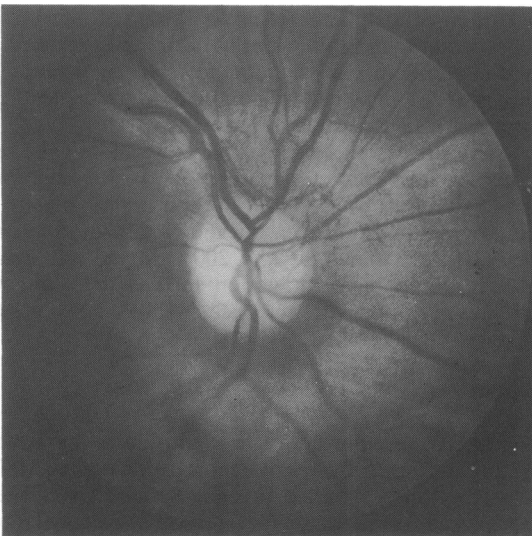


Fig. 2 Forward new vessels at the right optic disc.

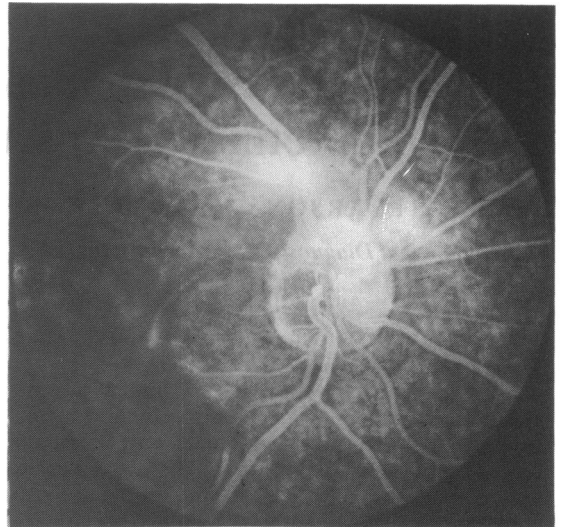

Fig. 3 Fluorescein angiogram showing leakage of dye from new vessels at the right optic disc.

peripheral retinoschisis may result in 'vitreous veils', which may contain veins and arterioles which are continuous with the retinal vasculature,<sup>14</sup> and some reports contain diagrams showing such vascularised veils attached to the optic disc.<sup>8-10</sup> Vitreous haemorrhage has been described, but unlike the condition in

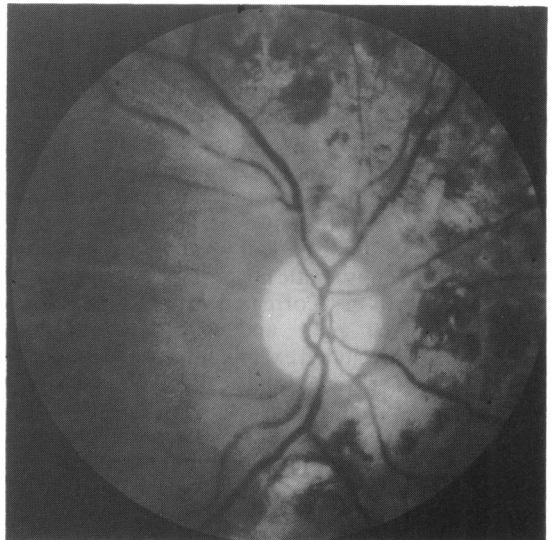

Fig. 4 Total regression of new vessels at the right optic disc following panretinal photocoagulation. Horizontal traction fold of the internal limiting membrane across the right macula. Markedly pigmented scars due to previous laser treatment.

this case, is most commonly due to rupture of vessels in the inner wall of areas of retinoschisis. Other vascular anomalies include temporally extending stretched vessels in the posterior pole, perivascular grey cuffing,<sup>1</sup> corkscrew and drumstick appearance of retinal vessels,<sup>10</sup> persistent hyaloid artery,<sup>8</sup> situs inversus vasculorum,<sup>1</sup> and an increased degree of branching of the retinal vessels on the surface of the optic disc.<sup>1</sup>

Peripheral retinal neovascularisation has been described so frequently in association with sex linked juvenile retinoschisis that it must certainly represent a feature of the 'disease' process. Optic disc neovascularisation has not, however, previously been described in association with this condition. The absence of any systemic disease known to be associated with retinal neovascularisation would suggest that the optic disc neovascularisation seen in this patient was a stage further than that of the peripheral neovascularisation frequently seen in this condition. That the underlying cause of the optic disc neovascularisation is retinal ischaemia is supported by the fluorescein angiographic findings and the response to panretinal photocoagulation. It is possible that the cause of the retinal ischaemia is related to the level of retinal splitting in the schitic areas. The level of splitting is very superficial, but sufficiently variable to include one branch of a retinal vessel in one layer while another branch may be seen in other layers.<sup>3</sup> Splitting at a deeper level, with the majority of vessels passing to the inner layer of schisis, may render those portions of the deeper layer relatively ischaemic, if they are not or are insufficiently supplied by the choroidal circulation. This theory could not, however, explain the presence of avascularity of non-schitic areas of peripheral retina. A more plausible explanation may be that a retinal microangiopathy, which in extreme cases could

produce sufficient retinal ischaemia to stimulate neovascularisation, is a feature of this condition and that its effects and appearance are modified by or contribute to the formation of schitic areas.

It is possible, but most improbable, that the optic disc neovascularisation is a vascularised 'vitreous veil' attached to the optic disc.<sup>8-10</sup> Such a proposition could explain fluorescein leakage by and vitreous haemorrhage from such vessels, but could not account for the regression of the vessels following photocoagulation. Nor is a mistake between the two likely on ophthalmoscopy or fluorescein angiography.

We thank Mr R K Blach for kindly giving his permission to report this patient under his care, and Mr Max Brown for his assistance with the photographs.

#### References

- 1 Balian JV, Falls HF. Congenital vascular veils in the vitreous. *Arch Ophthalmol* 1960; **63**: 92-101.
- 2 Cibis PA. *Vitreo-retinal pathology and surgery in retinal detachment*. St Louis: Mosby, 1965: 80-97.
- 3 Ewing CC, Ives EJ. Juvenile hereditary retinoschisis. *Trans Ophthalmol Soc UK* 1969; **89**: 29-39.
- 4 Keunen JEE, Hoppenbrouwers RWJN. A case of sex linked juvenile retinoschisis with peripheral retinal anomalies. *Ophthalmologica* 1985; **191**: 146-9.
- 5 Sabates F. Juvenile retinoschisis. *Am J Ophthalmol* 1966; **62**: 683-8.
- 6 Sarin LK, Green WR, Dailey EG. Juvenile retinoschisis. *Am J Ophthalmol* 1964; **57**: 793-6.
- 7 Geiser EP, Falls HF. Hereditary retinoschisis. *Am J Ophthalmol* 1961; **51**: 1193-200.
- 8 Mann I, Macrae A. Congenital vascular veils in the vitreous. *Br J Ophthalmol* 1938; **22**: 1-10.
- 9 Forsius H, Eriksson AW, Vainio-Mattila BA. Geschlechtsgebundene erbliche Retinoschisis in zwei Familien in Finnland. *Klin Monatsbl Augenheilkd* 1963; **143**: 806-16.
- 10 Deutmann AF. The hereditary dystrophies of the posterior pole of the eye. Assen: Van Gorcum, 1971: 48-98.

Accepted for publication 28 April 1988.