

The Mersilene mesh sling—a new concept in ptosis surgery*

R N DOWNES AND J R O COLLIN

From Moorfields Eye Hospital, City Road, London EC1

SUMMARY The use of a Mersilene mesh sling in brow suspension ptosis surgery is presented. Seventeen cases of severe blepharoptosis have been treated by means of this sling with favourable results. Materials used in brow suspension procedures are categorised and discussed, and it is concluded that the Mersilene sling is an alternative to those currently available for the management of severe blepharoptosis requiring brow suspension surgery.

The use of synthetic non-absorbable macro-mesh materials has not previously been described in eyelid surgery. One such material is Mersilene mesh. It is a polyester fibre mesh manufactured by a machine knitting process which interlocks individual fibre junctions. This feature prevents unravelling and facilitates cutting of the mesh without disruption of adjacent fibre junctions.¹ Mersilene mesh has been used in a variety of clinical settings (Table 1). Workers in many fields, including Amis² and Peyman *et al.*,³ have shown histologically in animal and subsequent clinical studies that the mesh acts as a permanent scaffold supporting fibrovascular ingrowth. This feature represents an attractive concept to the oculoplastic surgeon with potential application in a number of clinical settings. Brow suspension ptosis surgery is one such. We have recently undertaken a clinical study aimed at evaluating the Mersilene sling. This paper outlines our initial findings.

Material and methods

We have used the Mersilene sling for correcting 17 ptotic eyelids in 11 patients—five children (age range 4 months to 3½ years) and six adults (age range 57–76 years). All the patients had severe ptosis with minimal or no demonstrable levator palpebrae superioris function. The aetiology of the ptosis was chronic progressive external ophthalmoplegia in six cases, congenital ptosis in four, and trigemino-

Table 1 Clinical applications of Mersilene mesh

| | | |
|---|----------------------|---|
| 1 | General surgery: | diaphragmatic defects hernia repairs rectal/urogenital slings |
| 2 | Vascular surgery: | vascular prostheses |
| 3 | Orthopaedic surgery: | ligament/tendon repairs/replacement |

oculomotor synkinesis in one. The eyelid occluded the visual axis in every case. In all the children urgent surgery was indicated to prevent or minimise the development of amblyopia; the adults requested surgery for functional reasons. Four patients had undergone previous brow suspension surgery by stored human fascia lata,⁴ but the ptosis recurred within three months in all of them. One patient with chronic progressive external ophthalmoplegia had had successful levator surgery some 10 years previously. The ptosis gradually recurred as the underlying disease progressed.

The surgical technique is a modified Fox's method as described by the senior author.⁴ Stab incisions are made in the eyelid and brow (Fig. 1). The lid incisions are made 3–7 mm from the eyelid margin in an attempt to match the position of the contralateral skin crease. The lid is divided into thirds, with incisions being made at the junction between the lateral and central thirds and the central and medial thirds. The medial and lateral brow incisions are made within the superior hair line of the eyebrow above the medial and lateral canthal positions. The superior brow incision is made midway between the two lower incisions, 7–10 mm above the brow. The position of the stab incisions is important. A peaked

*Presented to the European Society of Ophthalmic Plastic and Reconstructive Surgery, Brussels, May 1988.

Correspondence to Sqd Ldr R N Downes, Princess Mary's Hospital, RAF Halton, Aylesbury, Bucks HP22 5PS.



Fig. 1 Diagram illustrating position of stab incisions.

or flat lid contour is avoided and satisfactory lid lift is obtained by means of these guidelines.

The sling is easily cut from a sheet of Mersilene mesh to the approximate dimensions of 15 cm long by 5–7 mm wide (Fig. 2). The individual mesh pore configuration is oval; it is critical to cut the sling along the long axis of adjacent ovals until the required length is obtained. If the mesh is cut at right angles to this, a very stretchable and much weakened strip is fashioned. The sling is autoclaved and packaged prior to use. When required it is soaked in a suitable antibiotic solution for 5–10 min and then washed thoroughly in sterile saline.

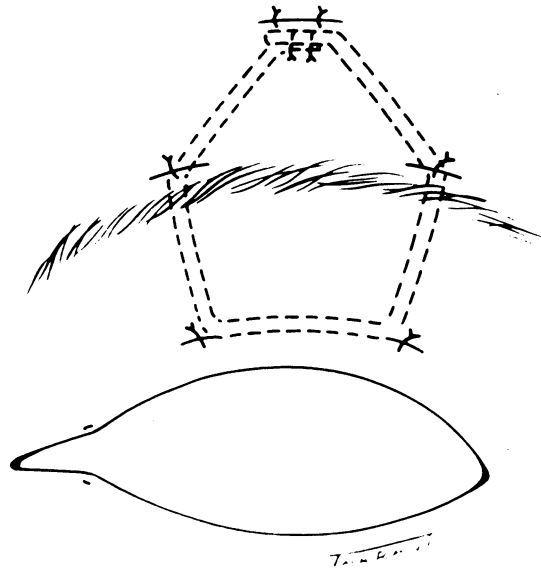


Fig. 3 Diagram illustrating Mersilene sling in position and sutured superiorly.

The mesh is threaded through the lid in the suborbicularis plane with a Wright's fascial needle; the two ends are brought through the superior brow incision. The sling is pulled taut. When the required lid height is achieved, the two strips are held taut, side by side, and secured using two 5 'O' Ethibond sutures passed through the mesh just within the brow incision, care being taken not to catch inadvertently the tissues with the suture. The excess mesh is trimmed and the sling is allowed to retract into the




Fig. 2 Photograph demonstrating dimensions of the Mersilene sling. The long axis along which the mesh should be cut is arrowed.

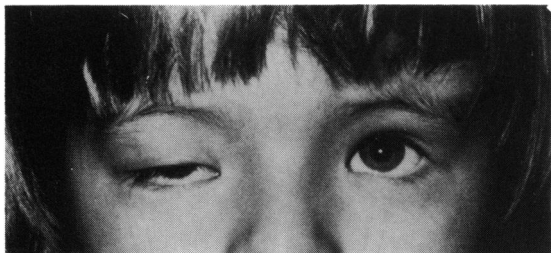

Fig. 4 *Right congenital ptosis preoperatively.*

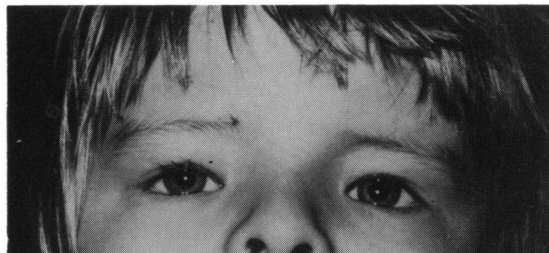


Fig. 5 *Same patient as Fig. 4 postoperatively.*

deep tissues of the brow (Fig. 3). The brow incisions are closed and a Frost suture, if appropriate, applied. Oral broad spectrum antibiotics are prescribed for one week postoperatively. Topical antibiotics and lubricants are routinely used for the first week and then as required.

Results

In all patients a significant improvement in lid height has been achieved. Figs. 4–7 illustrate two such cases. The improvement in the vertical palpebral aperture ranged from 2 to 5 mm (average 3.5 mm). The lid height obtained within one week has been maintained in all patients. The period of follow-up currently ranges from one to six months (average 10 weeks).

We encountered only one significant complication, namely that of a patient in whom a preseptal cellulitis developed several days postoperatively. This settled fully on systemic antibiotics, and removal of the mesh was not required. The case was complicated by two factors. At the time of operation the patient had an early respiratory tract infection and routine post-operative antibiotics were inadvertently not prescribed. β -Haemolytic streptococci of the same strain were grown from sputum and wound cultures. The patient has had no further problems for over three months. Recently a successful and uncomplicated

brow suspension procedure was undertaken with a Mersilene sling for severe contralateral ptosis.

Three patients developed mild exposure keratitis immediately postoperatively. All were successfully treated with topical lubricants, which one patient has continued to use as required.

Discussion

A wide variety of materials has been employed for brow suspension ptosis surgery (Table 2). These may be broadly divided into two groups—grafts and synthetic materials. Fresh autogenous fascia lata is a syngeneic graft and as such provides the best results in terms of both maximal duration of effect and minimal complications.^{4,7} It does, however, have certain disadvantages. The patient's leg needs to be large enough for adequate fascial harvesting, a procedure which in itself involves a separate operation on the leg; controversy exists on the best means of obtaining such tissue to minimise complications. General anaesthesia is invariably required. All the available alternative materials have certain disadvantages in terms of duration of action and/or unacceptable rate of extrusion.^{5,7}

In all our cases the use of fresh autogenous fascia lata was deemed inappropriate. The patients were either too small for adequate fascial harvesting or had requested that the procedure be performed under

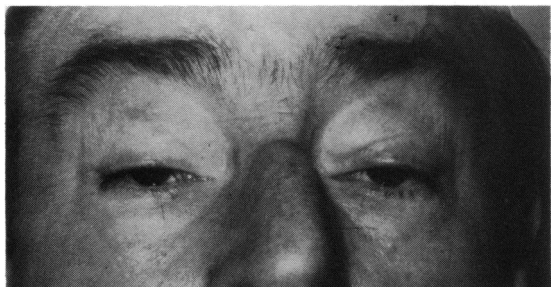

Fig. 6 *Patient with chronic progressive external ophthalmoplegia and bilateral ptosis preoperatively.*

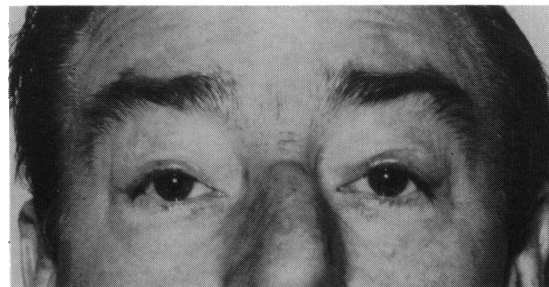


Fig. 7 *Same patient as in Fig. 6 postoperatively.*

Table 2 Brow suspension: materials

| Grafts |
|--|
| Fascia lata: fresh autogenous preserved human bovine |
| Strips of skin/orbicularis/frontalis |
| Strips of fresh/preserved sclera |
| Synthetic materials |
| Silicone rod/band |
| Gold/silver/platinum implants |
| Sutures: Supramid silk polyester |
| Gore-tex soft tissue patch |

local anaesthesia. The use of a general anaesthetic coupled with a separate operation on the leg was thought to be contraindicated in the remaining cases.

Theoretically an inert non-absorbable material which provides a meshwork scaffold for fibrovascular ingrowth and subsequent incorporation into host tissues would be valuable in brow suspension ptosis surgery. Several materials are manufactured in a mesh form. Nylon has been shown to lose strength after implantation and produces less regular collagen adhesions than polyester.⁸ Metallic meshes create a marked tissue inflammatory response, and the sites of fibre junction are subject to stress fatigue. Carbon fibre materials fragment at around three months after implantation, and a progressive resorption of surrounding collagen occurs as a consequence of the inflammation created by this breakdown.²

Gore-tex has recently been used in brow suspension ptosis surgery by Morax and coworkers.⁹ The Gore-tex soft tissue patch is a sheet of expanded polytetrafluoroethylene, a polymer familiar to many as Teflon. The manufacturers claim that the porous microstructure allows cellular penetration and thus incorporation into the surrounding tissues. Morax *et al.* cite a 10% extrusion rate within three months postoperatively in ptosis surgery, which allowed histological examination of the Gore-tex patch. They 'noticed the presence of vascular connective tissue rapidly surrounding the implant, with however, the possibility of separating easily this implant from the sub-cutaneous tissue'. This suggests less than complete tissue integration, with Gore-tex in such a situation acting more as a solid sheet than a true micromesh. If this is indeed the case, then the major advantage of Gore-tex over other synthetic materials would appear to have been lost. In comparison with the Mersilene sling, Gore-tex is significantly more expensive and the surgical technique of implantation more complicated; we do not consider it offers any advantages.

The initial results obtained with the Mersilene sling suggest that it is a real alternative to all those

Table 3 Mersilene mesh

| Advantages | Disadvantages |
|---|---|
| Readily available; inexpensive Easily prepared and implanted | Foreign material ?Long-term results in ptosis surgery |
| Strong, flexible, durable Permanent scaffold for fibrovascular ingrowth Clinically tried and tested | |

materials, both allogeneic and xenogeneic grafts and synthetic substances, available for use in brow suspension ptosis surgery. When analysing the improvement in lid height attained, it must be remembered that an adequate rather than maximal lid position was the aim in those patients with chronic progressive external ophthalmoplegia (over 50% of our cases) in an attempt to minimise or obviate postoperative exposure problems. The only significant complication, namely that of a preseptal cellulitis in one case, might have occurred with any material in the particular circumstances. The advantages and disadvantages of Mersilene mesh are summarised in Table 3.

Further studies are necessary to evaluate the long-term results with the Mersilene sling. In the light of our initially favourable results we are conducting such an evaluation.

The Mersilene mesh sling has been used to correct 17 cases of severe blepharoptosis. The results obtained to date are most encouraging and compare very favourably with currently available materials used in brow suspension ptosis surgery.

References

- 1 *Product sheet—Mersilene mesh*. Revised September 1985. Ethicon Ltd.
- 2 Amis AA. Filamentous implant reconstruction of tendon defects: a comparison between carbon and polyester fibres. *J Bone Joint Surg (Br)* 1982; **64B**: 682.
- 3 Peyman GA, Koziol J, Janevics R. Intraocular lens fixation with Dacron mesh: part II. *Ophthalmic Surg* 1977; **8**: 87–93.
- 4 Collin JRO. *A manual of systematic eyelid surgery*. Edinburgh: Churchill Livingstone: 2: in press.
- 5 Beyer CK, Albert DM. The use and fate of fascia lata and sclera in ophthalmic plastic and reconstructive surgery. *Ophthalmology* 1981; **88**: 869–86.
- 6 Crawford JS. Congenital blepharoptosis. In: Smith BV, Della Rocca RC, Nesi FA, Lisman RD, eds. *Ophthalmic plastic and reconstructive surgery*. St Louis: Mosby, 1987; **1**: 643–5.
- 7 Waller RR. Evaluation and management of the ptosis patient. In: McCord C D Jr, ed. *Oculoplastic surgery*. New York: Raven, 1982: 60–8.
- 8 Adler RH, Fume CN. Use of pliable synthetic mesh in the repair of hernias and tissue defects. *Surg Gynecol Obstet* 1959; **108**: 199–206.
- 9 Morax S, Bok C, Ruban JM. Use of Gore-tex (PTFE) in ophthalmic plastic surgery. Presented to French Ophthalmological Society 3 May 1987, Paris. *Ophthalmology* in press.