

# Purtscher's retinopathy and fat embolism

DERMOT RODEN,<sup>1</sup> GERARD FITZPATRICK,<sup>2</sup> HUGH O'DONOGHUE,<sup>1</sup> AND DERMOT PHELAN<sup>2</sup>

From the <sup>1</sup>Departments of Ophthalmology, and <sup>2</sup>Anaesthesia and Intensive Care, Mater Hospital, Dublin, Ireland

**SUMMARY** A 19-year-old woman who sustained multiple trauma but no head injury developed fulminant fat embolism syndrome (FES). Her neurological deterioration was associated with cerebral oedema and the concomitant Purtscher's type retinopathy. We suggest that the pathogenesis of the retinopathy and of the cerebral oedema are the same and that Purtscher's retinopathy and retinopathy of the FES are indistinguishable.

Retinopathy associated with extraocular trauma was first described by Purtscher.<sup>1</sup> Retinal changes have also been noted to occur in some patients with the fat embolism syndrome.<sup>2</sup> Here we describe a patient with fat embolism syndrome (FES) in whom retinopathy occurred concomitantly with cerebral oedema.

## Case report

A 19-year-old female sustained fractures of her lower limbs and pelvis. She incurred no head injury and was fully alert on admission to hospital. Six hours later her fractures were immobilised under general anaesthesia, from which she recovered completely.

Eight hours postoperatively she began to develop signs of FES, including pyrexia (38°C), tachycardia, skin petechiae, oliguria, hypoxaemia with pulmonary infiltrates on chest X-ray, anaemia, and a coagulopathy. She became rapidly and deeply comatose in association with cerebral oedema, demonstrated by CT scan (Fig. 1). She required tracheal intubation and mechanical ventilation for her cerebral oedema. By the seventeenth day neurological improvement allowed removal of the endotracheal tube. She continued to improve and was discharged from hospital six weeks after the injury with no neurological deficit.

At the time of admission her fundi had been normal, but after 24 hours cotton-wool spots were noted within two disc diameters of the discs. After a

further 48 hours flame shaped haemorrhages appeared adjacent to the cotton-wool spots. The retinopathy remained unchanged for several weeks (Fig. 2) but eventually resolved completely, and both eyes had normal visual acuity on her discharge from hospital.

## Discussion

Purtscher's retinopathy is classically described as consisting of cotton-wool spots and haemorrhages developing within one to two days of extraocular trauma and unaccompanied by systemic manifestations.<sup>1,2</sup> Marr and Marr,<sup>2</sup> in distinguishing between Purtscher's disease and fat embolism, state that the retinopathy of FES occurs after one to two days and consists of cotton-wool spots, haemorrhages, and retinal oedema accompanied by systemic manifestations. It has been suggested that Purtscher's disease follows head and chest injuries and the retinopathy of FES follows fractures of the long bones.

The proposed distinguishing features between Purtscher's retinopathy and fat embolism syndrome appear therefore to relate to the nature of the precipitating trauma and whether or not the systemic features of FES are present. However, it is now realised that FES is not specific to a particular injury and may be precipitated by a variety of injuries, including minor injuries to the head, chest, or even soft tissue.<sup>3</sup> Moreover the clinical syndrome associated with fat embolism is variable: fever, pulmonary infiltrates, neurological changes, and petechiae are the most common features,<sup>4</sup> but there is no pathog-

Correspondence to Dr Dermot Phelan, Department of Anaesthesia and Intensive Care, Mater Hospital, Eccles Street, Dublin 7, Ireland.

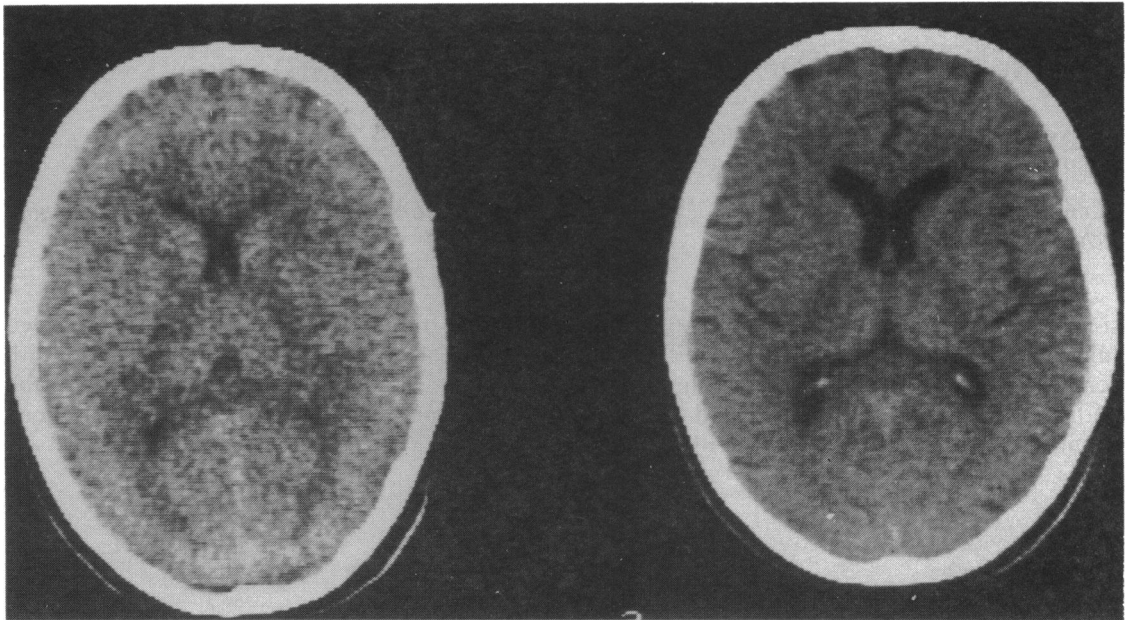


Fig. 1 A CT scan 18 hours after admission to hospital (left) shows an absence of sulci and compression of the lateral ventricles, indicating cerebral oedema. By day 14 the cerebral oedema had resolved (right).

nomonic sign or test. It would appear therefore that the basis for distinguishing between these retinopathies on clinical grounds is tenuous.

The underlying pathology of the FES is incompletely understood, but the evidence suggests that fat

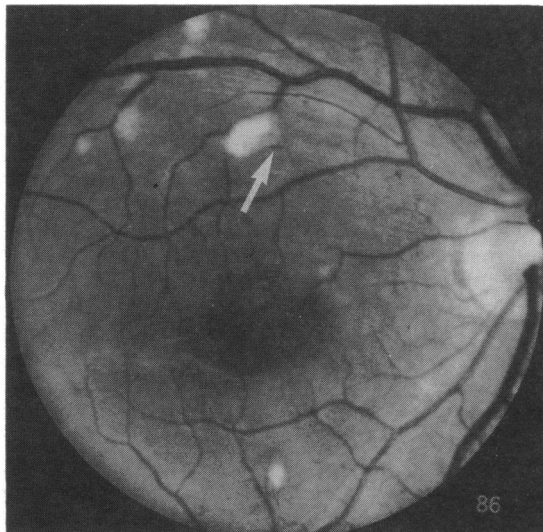


Fig. 2 A fundus photograph taken three weeks after admission to hospital shows areas of cotton-wool spots with adjacent intraretinal haemorrhage (arrow).

emboli result both from the release of fat from damaged long bones and from coalescence of fat globules in the circulation following the disruption of blood lipid stability.<sup>5</sup> Loss of stability appears to be secondary to the neurohumoral stress response, as is also a generalised increase in blood concentration of free fatty acids. Endothelial damage results from toxic free fatty acid and from capillary obstruction by fat globules, with associated platelet aggregation, release of vasoactive substances, and production of a coagulopathy.<sup>5,6</sup> Loss of capillary integrity is the likely cause of the widespread microinfarction and haemorrhage seen in various tissues, including the brain, on post-mortem examination of patients with the fulminant form of FES.<sup>7</sup>

It is now known that the cotton-wool spots of Purtscher's disease are due to microinfarction of the nerve fibre layer of the retina.<sup>8</sup> It is possible therefore that Purtscher's retinopathy consisting of microinfarction and haemorrhages is another tissue manifestation of FES.

In the case reported here Purtscher's type retinopathy, cerebral oedema, and multiple system manifestations of FES developed simultaneously. It is likely the same pathophysiological sequence unfolded in the systemic and cerebral circulation and the retinal microcirculation, the retina providing the classical window to the cerebral vascular bed.

This case suggests that the retinopathy originally

described by Purtscher, which we termed traumatic retinal angiopathy, is indistinguishable from the retinopathy of FES. The simultaneous occurrence of cerebral and retinal microangiopathic disease in this patient with FES suggests they are likely to be the result of the FES pathological process. Retinopathy occurring in this setting may be another tissue manifestation of the FES. We would suggest that the traditional differentiation of retinopathy associated with extraocular trauma into Purtscher's disease and FES is arbitrary and without good clinical or pathological foundation.

We acknowledge the assistance of Mr Niall Mulvihill and Dr S Darby and the helpful discussion of Mr Robert Acheson. We also thank the Mater Medical Illustration Department and Ms Mary Murray for typing the manuscript.

#### References

- 1 Purtscher O. Noch unbekannte Befunde nach Schaedeltrauma. *Ber Ophthalmol Ges* 1910; **36**: 294-310.
- 2 Marr WG, Marr EG. Some observation on Purtscher's disease: traumatic retinal angiopathy. *Am J Ophthalmol* 1962; **54**: 693-705.
- 3 Lessells AM. Fatal fat embolism after minor trauma. *Br Med J* 1981; **282**: 1586.
- 4 Sevitt S. *Fat embolism*. London: Butterworths, 1962.
- 5 Oh MH, Mital MA. Fat embolism: current concepts of pathogenesis, diagnosis and treatment. *Orthop Clin North Am* 1978; **9**: 769-79.
- 6 Hagley SR. The fulminant fat embolism syndrome. *Anaesth Intensive Care* 1983; **11**: 162-5.
- 7 Hagley SR. Fulminant fat embolism - case reports. *Anaesth Intensive Care* 1983; **11**: 167-70.
- 8 Yanoff M, Fine BS. Retina. In: Duane TD, Jaeger EA, eds. *The biomedical foundations of ophthalmology*. Philadelphia: Harper and Row, 1983; **3**: Chapter 13: 9.

Accepted for publication 3 November 1988.