

Acute posterior multifocal placoid pigment epitheliopathy complicated by central retinal vein occlusion

D G CHARTERIS, V KHANNA, AND B DHILLON

From the Princess Alexandra Eye Pavilion, Royal Infirmary of Edinburgh

SUMMARY A case of acute posterior multifocal placoid pigment epitheliopathy (APMPPE) complicated by a central retinal vein occlusion five weeks after presentation is described. After eight months' follow-up there was mild residual visual impairment, macular scarring, and angiographic changes. The association of these two conditions is discussed.

Acute posterior multifocal placoid pigment epitheliopathy (APMPPE) was first described by Gass in 1968.¹ Since then there have been many clinical descriptions of the disease, but the aetiology remains elusive. A substantial proportion of cases have an associated viral-like prodromal illness, and one case of APMPPE associated with confirmed adenovirus type 5 infection has been reported.² Associations have also been made with systemic inflammatory conditions—erythema nodosum,^{3,4} sarcoid,⁵ thyroiditis,⁶ nephritis,⁷ and cerebral vasculitis.⁸⁻¹²

Case report

A 28-year-old woman presented to the eye casualty department with complaints of dull frontal headache of two days' duration and deterioration in central vision in her right eye for 24 hours. She was otherwise well and was not taking any medication. The only significant past history was an episode of parieto-frontal headache eight years previously; investigations at that time, including a CT brain scan, gave normal results.

Examination revealed visual acuities to be 6/36 right eye and 6/4 left eye unaided. The anterior segments appeared normal. The right fundus had cream coloured placoid lesions, ½ to 1 disc diameter, scattered across the posterior pole mainly in the superior half (Fig. 1). The macula was notably oedematous. The left fundus was entirely normal.

A diagnosis of acute posterior multifocal placoid pigment epitheliopathy was made.

Intravenous fluorescein angiography showed early hypofluorescence and late hyperfluorescence of the lesions (Figs. 2, 3) typical of APMPPE. Full and differential blood cell count were normal. The erythrocyte sedimentation rate was 6 mm/h. Radiography of chest, cranial vault, pituitary fossa, orbits, and optic foraminae showed normal appearances. An enzyme linked immunosorbent assay (ELISA) for toxoplasma was negative. Acute and convalescent serum samples did not show a rising titre to adenovirus, measles, herpes simplex, varicella zoster, cytomegalovirus, or leptospira.

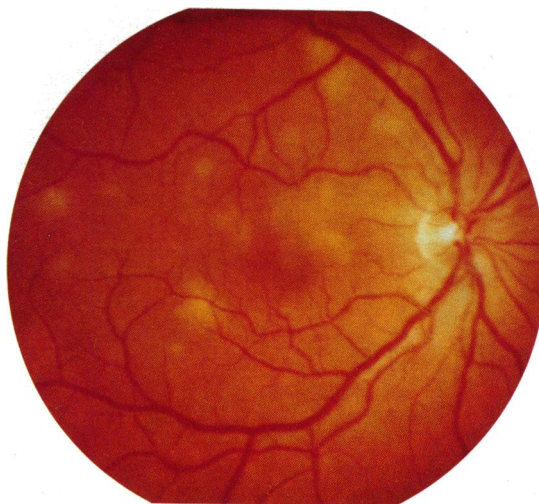


Fig. 1 *Right fundus on initial presentation.*

Correspondence to Mr D G Charteris, Princess Alexandra Eye Pavilion, Royal Infirmary of Edinburgh, Chalmers Street, Edinburgh EH3 9HA.

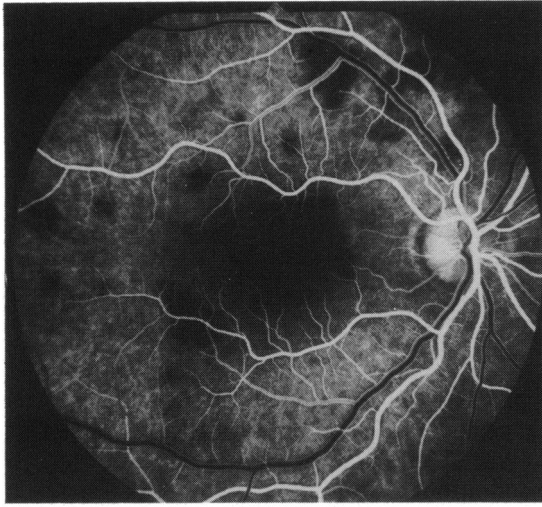


Fig. 2 Early venous phase fluorescein angiogram showing hypofluorescence of placoid lesions.

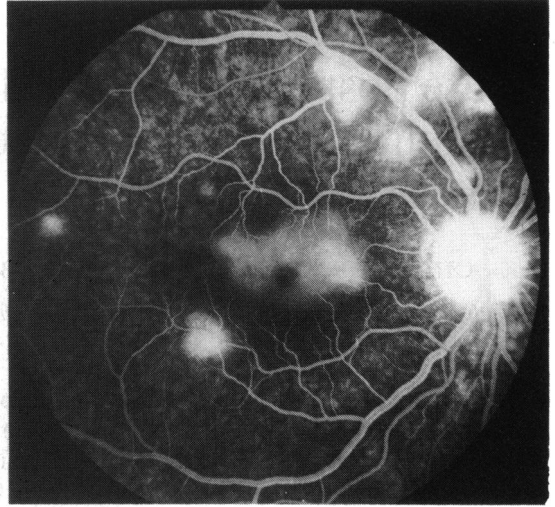


Fig. 3 Late phase fluorescein angiogram showing hyperfluorescence of placoid lesions and macular oedema.

In view of the macular oedema she was started on prednisolone 80 mg per day, which was slowly reduced over four weeks. During this period the placoid lesions were essentially unchanged. The macular oedema showed some resolution, with reactive pigmentary changes, and the visual acuity improved to 6/24.

When she was examined at the clinic five weeks after her initial presentation, her right fundus had the appearance of a central retinal vein occlusion (Fig. 4). The right optic disc was swollen, and there were

flame-shaped haemorrhages extending from the disc and scattered linear and blot haemorrhages in all four quadrants. The placoid lesions were now more widespread and were becoming confluent. There was a right relative afferent pupillary defect, and her vision was 6/36 in this eye. The left eye remained unaffected. Fluorescein angiography confirmed the central retinal vein occlusion and the widespread placoid lesions but showed no evidence of retinal vasculitis (Figs. 5, 6). The fundus was not ischaemic, and no treatment was undertaken. The fundal

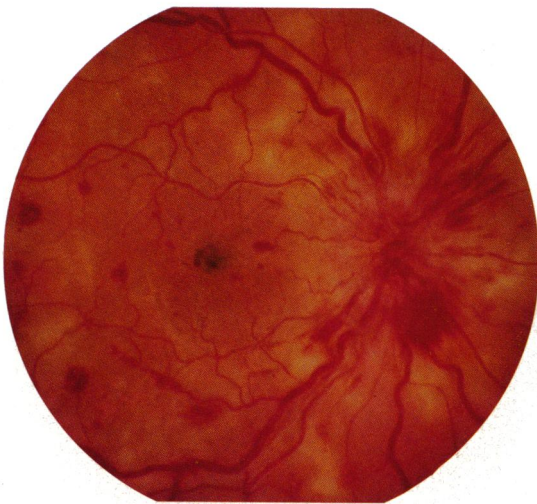


Fig. 4 Right fundus five weeks following initial presentation. A central retinal vein occlusion is superimposed on the placoid lesions.

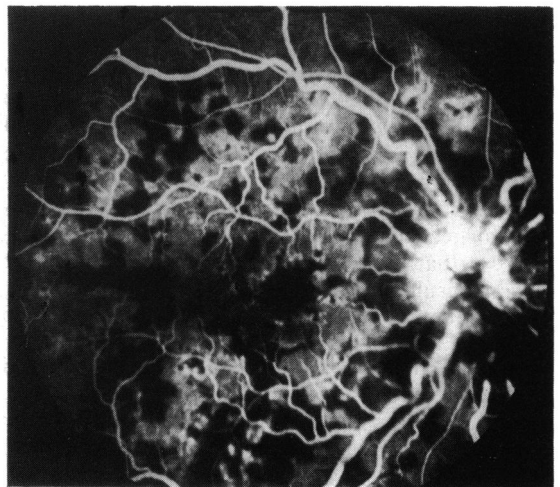


Fig. 5 Venous phase fluorescein angiogram demonstrating masking by retinal haemorrhages and areas of hypofluorescence due to the placoid lesions.

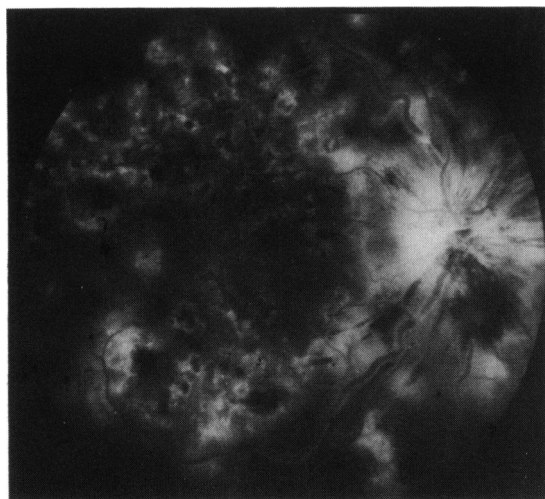


Fig. 6 Late phase angiogram. The placoid lesions now hyperfluoresce at their edges, though some lesions continue to hyperfluoresce centrally.

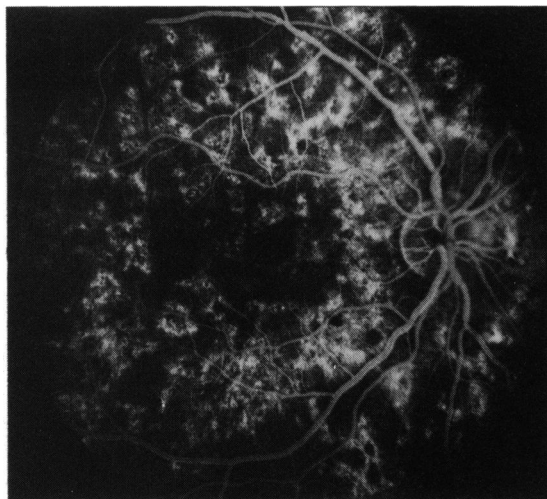


Fig. 7 Fluorescein angiogram eight months after presentation showing patches of hyperfluorescence throughout the posterior pole.

appearance slowly resolved, and the visual acuity improved to 6/9 after eight months' follow-up, when her only complaint was a small central scotoma. Fluorescein angiography at this stage showed patches of hyperfluorescence across the posterior pole (Fig. 7), and the macula had a residual pigmented scar (Fig. 8).

Discussion

The case described showed the typical early features of APMPE—loss of central vision with multiple cream coloured placoid lesions distributed over the posterior pole at the level of the retinal pigment epithelium. Uniocular cases are unusual but have been reported.^{13–16} The initial clinical impression of full visual recovery in APMPE¹ has been questioned in more recent work,^{13 14 17} and the residual impairment of central vision in this case is attributable to the macular involvement.

There have been no previous reports of central retinal vein occlusion occurring in APMPE. The observed changes in this case were typical of a central retinal vein occlusion¹⁸: there was only a minimal effect on vision and no evidence of fundal ischaemia or retinal vasculitis.

The primary site of the inflammatory process in APMPE is debated. Some authorities think that the retinal pigment epithelium is the primary focus,^{1 19 20} while others think that there is a choroidal vasculitis with secondary ischaemic changes in the retinal pigment epithelium due to occlusion of choroidal arterioles supplying individual choroidal

lobules.^{3 4 7 8 15 16 21–24} Many cases of central retinal vein occlusion in young people are thought to be due to inflammation within the vein¹⁸; optic disc vasculitis presents a similar fundal picture.²⁵ The occurrence of the two conditions together lends weight to the theory that APMPE is due to a choroidal vasculitis and is part of a more widespread systemic inflammatory process.^{3–12} The reported association of APMPE with retinal vasculitis and papillitis may be part of the same pathological process.²¹

It is perhaps surprising therefore that central

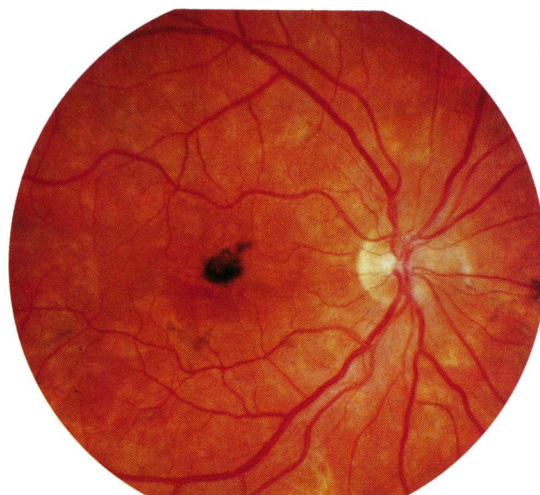


Fig. 8 Fundal appearance eight months after presentation. Note the pigmented macular scar.

retinal vein occlusion has not been previously reported in APMPE. The explanation of this may be that many cases of APMPE are asymptomatic unless there is macular involvement, and when it is complicated by venous occlusion the fundal features of APMPE are masked. In some cases the patchy hypofluorescence of the placoid lesions may be interpreted as capillary closure on fluorescein angiography.

The place of steroids in the treatment of APMPE is unproved. A recurrence following withdrawal of steroids has been reported.²⁶ In the case reported here it is notable that the venous occlusion occurred in the week following withdrawal of systemic steroid treatment. If vasculitis is implicated in the pathogenesis of the condition, steroid treatment may well have a role in the prevention of complications.

References

- Gass JDM. Acute posterior multifocal placoid pigment epitheliopathy. *Arch Ophthalmol* 1968; **80**: 177-85.
- Azar P, Gohd RS, Waltman D, Gitter KA. Acute posterior multifocal placoid pigment epitheliopathy associated with an adenovirus type 5 infection. *Am J Ophthalmol* 1975; **80**: 1003-5.
- Van Buskirk EM, Lessell S, Friedman E. Pigmentary epitheliopathy and erythema nodosum. *Arch Ophthalmol* 1971; **85**: 369-72.
- Deutman AF, Oosterhuis JA, Boen-Tan T, Aan De Kerk AL. Acute posterior multifocal placoid pigment epitheliopathy. *Br J Ophthalmol* 1972; **56**: 863-74.
- Dick DJ, Newman PK, Richardson J, Wilkinson R, Morley AR. Acute posterior multifocal placoid pigment epitheliopathy and sarcoidosis. *Br J Ophthalmol* 1988; **72**: 74-7.
- Jacklin HN. Acute posterior multifocal placoid pigment epitheliopathy and thyroiditis. *Arch Ophthalmol* 1977; **95**: 995-7.
- Priluck IA, Robertson DM, Buettner H. Acute posterior multifocal placoid pigment epitheliopathy. Urinary findings. *Arch Ophthalmol* 1981; **99**: 1560-2.
- Holt WS, Regan CDJ, Trempe C. Acute posterior multifocal placoid pigment epitheliopathy. *Am J Ophthalmol* 1976; **81**: 403-12.
- Sigelman J, Behrens M, Hilal S. Acute posterior multifocal placoid pigment epitheliopathy associated with cerebral vasculitis and homonymous hemianopia. *Am J Ophthalmol* 1979; **88**: 919-24.
- Kersten DH, Lessell S, Carlow TJ. Acute posterior multifocal placoid pigment epitheliopathy and late onset meningoencephalitis. *Ophthalmology* 1987; **94**: 393-6.
- Wilson CA, Choromokus EA, Sheppard R. Acute posterior multifocal placoid pigment epitheliopathy and cerebral vasculitis. *Arch Ophthalmol* 1988; **106**: 796-800.
- Smith CH, Savino PJ, Beck RW, Schatz NJ, Sergott RC. APMPE and cerebral vasculitis. *Arch Neurol* 1983; **40**: 48-50.
- Damato BE, Nanjiani M, Foulds WS. Acute posterior multifocal placoid pigment epitheliopathy. A follow-up study. *Trans Ophthalmol Soc UK* 1983; **103**: 517-22.
- Gass JDM. Acute posterior multifocal placoid pigment epitheliopathy. A long term follow-up. In: Fine SL, Owens SLO, eds. *Management of retinal vascular and macular disorders*. Baltimore: Williams and Wilkins, 1983: 176-81.
- Savino PJ, Weinberg RH, Yassin JG, Pilkerton AR. Diverse manifestations of acute posterior multifocal placoid pigment epitheliopathy. *Am J Ophthalmol* 1974; **77**: 659-62.
- Young NJA, Bird AC, Sehmi K. Pigment epithelial diseases with abnormal choroidal perfusion. *Am J Ophthalmol* 1980; **90**: 607-18.
- Murray SB. Acute posterior multifocal placoid pigment epitheliopathy. Not so benign? *Trans Ophthalmol Soc UK* 1979; **99**: 497-500.
- Hayreh SS. Central retinal vein occlusion. In: Mausolf FA, ed. *The eye and systemic disease*. St Louis: Mosby, 1980: 223-75.
- Ryan SJ, Maumenee AE. Acute posterior multifocal placoid pigment epitheliopathy. *Am J Ophthalmol* 1972; **74**: 1066-74.
- Fishman GA, Rabb MF, Kaplan J. Acute posterior multifocal placoid pigment epitheliopathy. *Arch Ophthalmol* 1974; **92**: 235-8.
- Kirkham TH, Ffytche TJ, Sanders MD. Placoid pigment epitheliopathy with retinal vasculitis and papillitis. *Br J Ophthalmol* 1972; **56**: 875-80.
- Deutman AF, Lion F. Choriocapillaris nonperfusion in acute multifocal placoid pigment epitheliopathy. *Am J Ophthalmol* 1977; **84**: 652-7.
- Wright BE, Bird AC, Hamilton AM. Placoid pigment epitheliopathy and Harada's disease. *Br J Ophthalmol* 1978; **62**: 609-21.
- Isashiki M, Koide H, Yamashita T, Ohba N. Acute posterior multifocal placoid pigment epitheliopathy associated with diffuse retinal vasculitis and late haemorrhagic macular detachment. *Br J Ophthalmol* 1986; **70**: 255-9.
- Hayreh SS. Optic disc vasculitis. *Br J Ophthalmol* 1972; **56**: 652-70.
- Lewis R, Martonyi CL. Acute posterior multifocal pigment epitheliopathy. *Arch Ophthalmol* 1975; **93**: 235-8.

Accepted for publication 9 February 1989.