

CASE REPORTS

Hemifacial atrophy: an unusual cause of enophthalmos

K N Hakin, C Yokoyama, J E Wright

Abstract

We report on two cases of enophthalmos, caused by maxillary atrophy, a rarely reported monostotic forme fruste of hemifacial atrophy.

The commonest causes of enophthalmos are congenital orbital asymmetry, trauma, and malignancy.¹ A rare cause is hemifacial atrophy (Parry-Romberg disease), a disease characterised by progressive atrophy of the subcutaneous tissues and, less frequently, of muscle and bone, usually of one side of the face. We report two cases of enophthalmos caused by an unusual form of hemifacial atrophy, the atrophy localised to the maxilla alone, with no soft tissue involvement.

Case Reports

CASE 1

A 35-year-old woman presented with a one-year history of a 'sunken' right eye. The patient complained of an occasional retrobulbar ache on the right side, but was otherwise healthy, with no relevant medical or ocular history.

On examination there was a relative lowering of the right eyebrow, a deepened right superior sulcus and flattening of the right cheek (Fig 1). The visual acuities were 6/5 in either eye. The right eye was 4 mm enophthalmic and depressed 2 mm, but there was full range of ocular movements. Ocular examination and general exam-

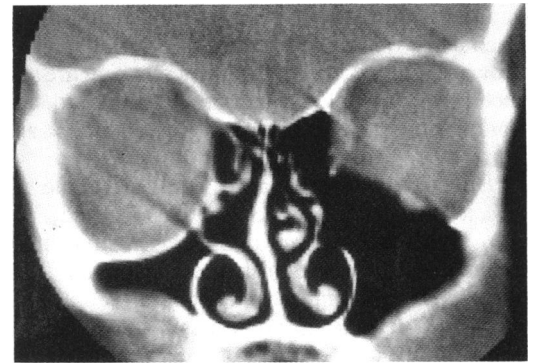


Figure 2: Case 1. CT scan demonstrating imploded right maxillary sinus.

ination, including a full neurological assessment, gave otherwise normal results.

A CT scan showed the right enophthalmos and a shrunken maxillary sinus with smooth concavity of the sinus walls towards the sinus cavity (Fig 2). The orbital floor was intact, with a convexity downwards towards the maxillary sinus. There was no evidence of an inflammatory or neoplastic process.

CASE 2

A 40-year-old woman presented with a six-month history of a 'sunken' left eye, associated with a mild discomfort on attempted movement of that eye. There was no history of head or ocular trauma, though the patient had received dental treatment to the left upper jaw approximately six months before noticing the problem. The right eye had been amblyopic from childhood.

Moorfields Eye Hospital,
City Road, London EC1V
2PD

K N Hakin
C Yokoyama
J E Wright

Correspondence to:
Mr K N Hakin.

Accepted for publication
15 March 1990

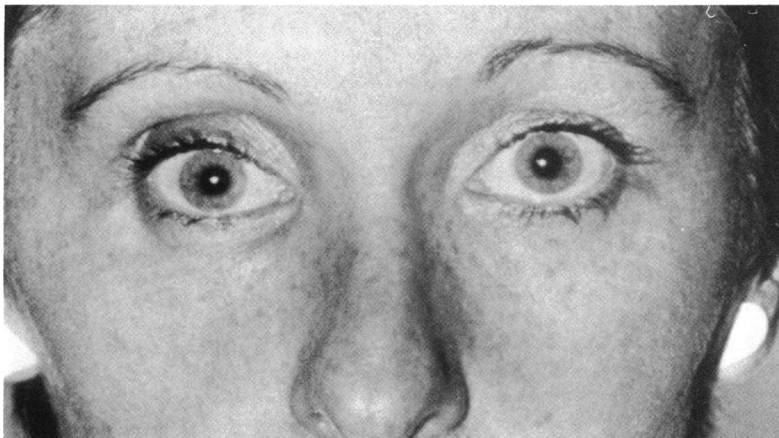

Figure 1: Case 1. Right enophthalmos.

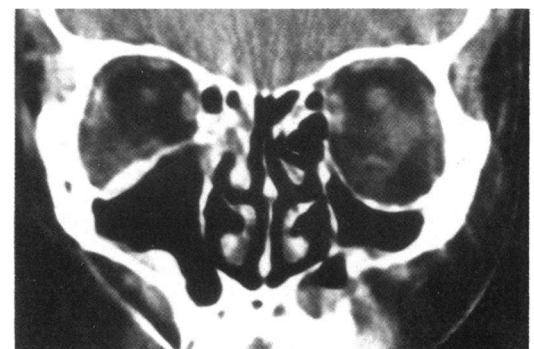

Figure 3: Case 2. CT scan demonstrating imploded left maxillary sinus.

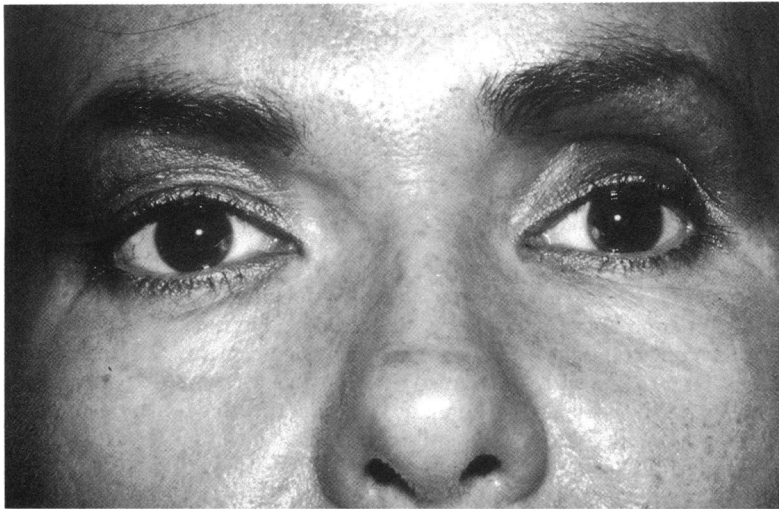

Figure 4: Case 2. Left enophthalmos.

The patient was initially referred to an ear, nose, and throat surgeon. Plain sinus x rays showed an opaque maxillary sinus suggesting possible sinusitis, but a sinus washout, and cytological examination and culture of the washings, gave normal results. A CT scan showed a shrunken maxillary sinus with slightly irregular bony contours, with no evidence of bony destruction (Fig 3).

The patient was referred for an ophthalmological opinion. Visual acuities were 6/18 in the amblyopic right eye and 6/6 in the left eye. There was mild tenderness over the left maxilla, with a deepening of the left superior sulcus (Fig 4). The left eye was 3 mm enophthalmic, but ocular movements were full. Ocular examination was otherwise normal.

To exclude a fungal sinusitis the left maxilla was re-explored through a Caldwell-Luc approach. The maxillary antrum was filled with altered blood and mucus from the washout six weeks previously. The orbital floor was intact, with a downward convexity into the antrum, and the antral walls were noted to be remarkably thin. The mucosa appeared normal. Histopathological examination of the antral contents showed mild chronic mucosal inflammation and blood clot, with no evidence of malignancy. Fungal culture of the contents was negative. A CT scan repeated three months later demonstrated a clear maxillary sinus but was otherwise unchanged.

Discussion

In a review of 26 cases Cline and Rootman reported the commonest causes of enophthalmos to be congenital asymmetry, trauma, and malignancy.¹ They stated that one or more of three mechanisms caused enophthalmos – structural abnormality, fat atrophy, and traction. Our cases were caused by implosion of the maxilla, a structural abnormality. This, however, was not congenital. There was no history of trauma, and radiological examination, with surgical explor-

ation in the second case, excluded any sinus tumour or infection. In the absence of any other disease we considered our cases to be monostotic formes frustes of hemifacial atrophy (Parry-Romberg disease).

Hemifacial atrophy is a disease of unknown aetiology which usually begins in the first or second decade of life, initially with atrophy of fat and subcutaneous tissues of one side of the face. Atrophy of the muscle can follow, but bony involvement is said to be uncommon unless the onset is before the second decade.² An early sign may be a well demarcated furrow on the forehead, the coup de sabre, which marks the boundary between normal and atrophic tissue. There is involvement of the limbs and trunk in about 7% of cases,³ and it may occasionally be bilateral.⁴ It is thought that the condition may be caused by an abnormality in the sympathetic nervous system and that trauma to the affected area, including dental treatment, may be the trigger for the onset of the disease.^{5,6} Our second case had received dental treatment six months prior to the onset of her symptoms.

Ocular involvement in hemifacial atrophy is well recognised and occurs in up to 40% of cases.⁷ Pupil and lid anomalies, extraocular muscle imbalance, hypermetropia, and retinal pigmentary changes may be present,^{2,6-11} but enophthalmos has been reported as the commonest ocular manifestation.⁷ Ocular signs alone, however, are rare; they usually present as part of a spectrum of more extensive face and body changes. There have been two previous reports of hemifacial atrophy in which enophthalmos has been the only sign, occurring as a result of marked bony atrophy in the absence of any soft tissue change.^{12,13}

Hemifacial atrophy should be remembered as a rare cause of acquired enophthalmos, but must always be considered a diagnosis of exclusion.

- 1 Cline RA, Rootman J. Enophthalmos: a clinical review. *Ophthalmology* 1984; **91**: 229-37.
- 2 Miller MT, Sloane H, Goldberg MF, Grisolano J, Frenkel M, Mafee MF. Progressive hemifacial atrophy (Parry-Romberg disease). *J Pediatr Ophthalmol Strabismus* 1987; **24**: 27-36.
- 3 Gorlin RJ, Pindborg JJ. *Syndromes of the head and neck*. 2nd ed. New York: McGraw-Hill, 1976: 341-3.
- 4 Hickman JW, Sheils WS. Progressive facial hemiatrophy. A report of a case with marked homolateral involvement. *Arch Intern Med* 1964; **113**: 716-20.
- 5 Kaufman MD. Masticatory spasm in facial hemiatrophy. *Ann Neurol* 1980; **7**: 585-7.
- 6 Johnson RV, Kennedy WR. Progressive facial hemiatrophy (Parry-Romberg syndrome). Contralateral extraocular muscle involvement. *Am J Ophthalmol* 1969; **67**: 561-4.
- 7 Muchnick RS, Aston SJ, Rees TD. Ocular manifestations and treatment of hemifacial atrophy. *Am J Ophthalmol* 1979; **88**: 889-97.
- 8 Smith B, Guberina C. Coloboma in progressive hemifacial atrophy. *Am J Ophthalmol* 1977; **84**: 85-9.
- 9 Aracena T, Roca FP, Barragan M. Progressive hemifacial atrophy (Parry-Romberg syndrome): report of two cases. *Ann Ophthalmol* 1979; **11**: 953-8.
- 10 Karney H, Baum JL. Refractive change as initial sign of progressive facial hemiatrophy. *Am J Ophthalmol* 1975; **79**: 878-9.
- 11 Sugar SH, Banks TL. Fuchs's heterochromic cyclitis associated with facial hemiatrophy (scleroderma en coup de sabre). *Am J Ophthalmol* 1964; **57**: 627-32.
- 12 Goldhammer Y, Kronenberg J, Tadmor R, Braham J, Leventon G. Progressive hemifacial atrophy (Parry-Romberg's disease), principally involving bone. *J Laryngol Otol* 1981; **95**: 643-7.
- 13 Zafarulla MYM. Progressive hemifacial atrophy: a case report. *Br J Ophthalmol* 1985; **69**: 545-7.