

Closure of leaking filtering blebs with cyanoacrylate tissue adhesive

Alan H Zalta, Richard H Wieder

Abstract

Five leaking filtering blebs, occurring between 10 months and 21 years after trabeculectomy, were closed with cyanoacrylate tissue adhesive. Filtering bleb integrity was preserved in four cases, so that additional microsurgery was avoided. The only problem associated with use of tissue adhesive was the development of corneal abrasions in three cases. Although it is an accepted treatment for these conjunctival fistulas, only nine previous cases have been reported to our knowledge. We strongly recommend the use of tissue adhesive as a presurgical treatment in the management of leaking filtering blebs which present as a late postoperative complication of glaucoma surgery.

A leaking filtration bleb is a serious sight-threatening complication of glaucoma surgery which may lead to hypotony, a flat anterior chamber, cataract, choroidal detachment, macular oedema, failure of the filtration bleb, and endophthalmitis. This complication is routinely managed by pressure patching, medications to reduce aqueous flow, suture repair, wound revision, bandage soft contact lens, scleral shell, collagen shield, and cyanoacrylate tissue adhesive.¹⁻¹⁵ While application of cyanoacrylate tissue adhesive is an accepted treatment for the condition,^{14,15} there have been only nine case reports detailing its effectiveness.¹⁻⁷ To our knowledge the five cases which we describe here represent the largest series of leaking filtering blebs repaired with cyanoacrylate tissue adhesive. We also describe the technique of tissue adhesive application employed.

Materials and methods

These five cases represent all leaking filtering blebs managed by one of the authors (AHZ) within the last five years which occurred as a remote complication of glaucoma surgery. The conjunctival bleb leak was identified and located on Seidel testing by a dramatic change in the colour of applied 2% fluorescein sodium from deep orange to light green. The repair was performed at the surgeon's consulting room under direct visualisation without the use of loupes or a microscope. The patient was placed in a recumbent position and the eye was anaesthetised with topically applied proparacaine. A lid speculum was inserted to prevent lid closure during and after application of the tissue adhesive. The patient was instructed to fixate with the contralateral eye to optimise ocular positioning and to prevent the eyelid from coming into contact with the glue. The eye was positioned

with the wound leak perpendicular to the vertical direction of application so as to prevent misapplication and run-off of the tissue adhesive to other parts of the eye. The conjunctival fistula site was dried with a cotton tip applicator or Weck-cel sponge just prior to application of the tissue adhesive. After securing a 30 gauge needle to a tube of Histoacryl Blue (n-butyl-2-cyanoacrylate) tissue adhesive, one to three drops of tissue adhesive were focally applied to the fistula site. After the tissue adhesive crystallised, the eye was examined at the slit-lamp to ensure proper coverage of the wound leak.

Then, antibiotic and/or antibiotic-steroid ointments were instilled to reduce ocular irritation from the glue. In accordance with the needs of the particular patient the eye was either pressure patched for 24 hours with or without a bandage soft contact lens, treated by ointment instillation every one hour while the patient was awake, or treated with topical antibiotic drops. The site of application of the tissue adhesive was examined the following day for optimal positioning and for presence of the bleb leak by Seidel testing. If the tissue adhesive had become dislodged or if a bleb leak persisted, tissue adhesive was reapplied to the site of leakage.

In using tissue adhesives for this specific purpose we followed some general principles. First, the leakage site was identified at the slit-lamp with a 2% fluorescein sodium solution. Fluorescein sodium strips may further traumatise a compromised and tenous conjunctival epithelium adjacent to the margins of the wound leak and should be avoided if possible. Secondly, a tiny amount of adhesive was used. Even with a 30 gauge needle one drop of tissue adhesive is sufficient to cover not only the leak site but also 1 to 2 mm of surrounding tissue if optimally applied. Thirdly, the leak site was dried prior to application of tissue adhesive. Bubbles were occasionally seen within the tissue adhesive during crystallisation. These bubbles are believed to be due to the tissue adhesive actively 'walling off' externalised aqueous. Fourthly, run-off or extension of tissue adhesive to surrounding tissues was minimised. Proper ocular positioning and alignment before application of the tissue adhesive is critical. Fifth and lastly, a lid speculum is necessary to prevent adherence of the eyelid to the conjunctiva and to prevent blinking while the tissue adhesive is crystallising.

Case reports

CASE I

A 53-year-old black female with advanced primary open-angle glaucoma in the left eye, controlled by a trabeculectomy performed in

Department of
Ophthalmology,
University of Cincinnati
College of Medicine,
Cincinnati, Ohio, USA
A H Zalta
R H Wieder

Correspondence to:
Dr A H Zalta, Mail Location
527, 231 Bethesda Avenue,
Cincinnati, Ohio 45267-0527,
USA.

Accepted for publication
21 September 1990

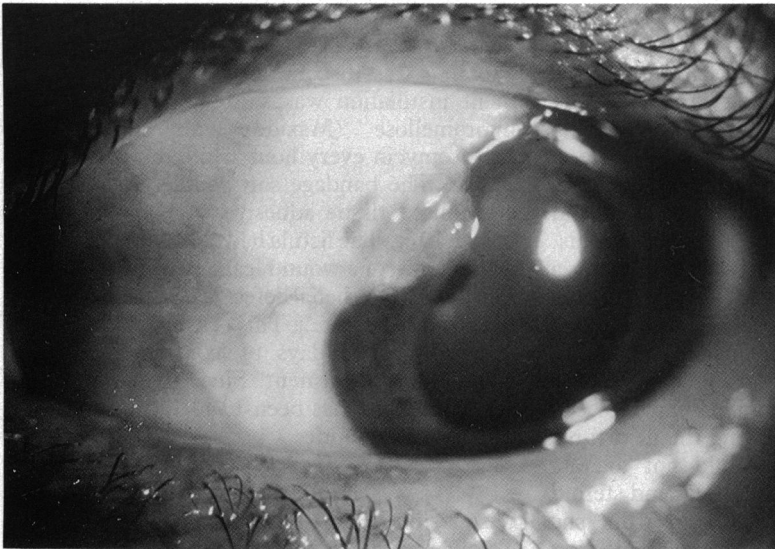


Figure 1 Large multicystic glaucoma filtering bleb with healed conjunctival fistula on the overhanging corneal margin after removal of tissue adhesive.

1971, developed a spontaneous leak of the filtering bleb in 1985. On initial examination a Seidel-positive wound leak was noted through the corneal edge of an overhanging, large, multicystic, superonasal filtering bleb (Fig 1). The intraocular pressure by applanation tonometry was 14 mmHg. The anterior chamber was deep and quiet. Tissue adhesive was applied to the fistula site and the eye was pressure patched over Polysporin (polymyxin B-bacitracin) ointment. On examination the next day the tissue adhesive was in a good position overlying the wound leak, and a Seidel test was negative. The eye was pressure patched again over polymyxin B-bacitracin ointment. On the second day after treatment the glue had become dislodged from the fistula site into the medial cul-de-sac. The site of the wound leak was covered by conjunctiva and a Seidel test was negative. The fistula has subsequently remained closed. A corneal epithelial defect was present adjacent to the healed fistula. This iatrogenic abrasion resolved after pressure patching for three more days. The intraocular pressure was 13 mmHg the day after application of the tissue adhesive and has remained in the low teens without further treatment.

CASE 2

A 60-year-old black male with end-stage primary open-angle glaucoma in his only eye, the right eye, controlled by a trabeculectomy performed in October 1987 developed a spontaneous leak in the filtering bleb in October 1988. On examination the intraocular pressure by applanation tonometry was 4 mmHg. A Seidel-positive wound leak was noted from a thin walled, posterior superotemporal filtering bleb. The anterior chamber was deep and quiet. Tissue adhesive was applied to the fistula site, but the eye was not pressure patched because of a blind fellow eye with no light perception. Tobramycin eye drops, one four times a day, were started. The next day the tissue adhesive was no longer

in place, the intraocular pressure was 6 mmHg, and there was a persistent Seidel positive wound leak. Tissue adhesive was reapplied and the eye was pressure patched over Cortisporin polymyxin B-bacitracin-neomycin-hydrocortisone ointment. The next day the glue was still in place, the intraocular pressure was 9 mmHg, and the site of the wound leak was Seidel negative. Pressure patching was repeated daily for four more days. When the tissue adhesive was removed two days later the conjunctiva had healed over the wound leak and a Seidel test was negative. The conjunctival fistula has subsequently remained closed. A corneal epithelial defect was present where the tissue adhesive had extended from the leaking bleb on to the cornea. The iatrogenic abrasion resolved after pressure patching for two more days. The intraocular pressure increased to 19 mmHg three weeks after the wound leak had sealed, but has been controlled in the low teens since that time with the addition of timolol eye drops 0.5% twice a day.

CASE 3

A 55-year-old black female with end-stage primary open-angle glaucoma in the right eye controlled by a trabeculectomy in 1967 developed a leaking filtering bleb in 1988 during treatment for haemophilus conjunctivitis. Despite two weeks of topical and intravenous antibiotics the filtering bleb flattened, opacified, and developed a Seidel-positive fistula which did not close with several days of pressure patching.

On initial examination there was a Seidel-positive wound leak in a small cystic bleb overhanging the superior limbus and an intraocular pressure of 20 mmHg while the patient was using timolol 0.5% twice a day and methazolamide 50 mg by mouth twice daily. There was no infiltrate in or around the filtering bleb and the anterior chamber was deep. Topical tobramycin twice daily and prednisolone acetate 1% four times a day were being used. Tissue adhesive was applied to the wound leak site, and the eye was pressure patched over polymyxin B-bacitracin ointment. Over the next three days tissue adhesive was reapplied to the leak site twice more. By the fifth day the fistula was closed and was Seidel-negative. However, the intraocular pressure increased to the mid-20s mmHg, requiring the addition of pilocarpine eye drops four times a day. On the eighth day a minute wound leak, with a delayed positive Seidel test by 3 to 4 seconds, was present on the edge of the glue. Tissue adhesive was applied to the new leak site, and the eye was pressure patched over Cortisporin ointment. Two days later the leak site remained Seidel-negative, and topical medications were reinstated. Over the next five weeks the intraocular pressure slowly increased into the mid-30s mmHg despite maximum ocular hypotensive therapy. Six weeks after the last application of tissue adhesive, the crystallised glue was removed from the closed fistula site, and a new trabeculectomy with bleb revision was performed. The intraocular pressure was 9 to 10 mmHg when the patient was on no ocular hypotensive medication for the six months following surgery.

CASE 4

A 77-year-old white female with angle closure glaucoma in the right eye controlled by a Scheie procedure performed in 1984 developed a wound leak in a massive superior thin-walled filtering bleb in 1989 during treatment for *Haemophilus influenzae* and *Staphylococcus aureus* conjunctivitis. Initial treatment consisted of topical and intravenous antibiotics and topical steroids. Although the eye responded well to therapy a tiny Seidel-positive wound leak developed in the filtering bleb on the sixth day in hospital. The intraocular pressure by applanation tonometry was 3 mmHg, and the anterior chamber was shallow but not flat. Tissue adhesive was placed over the fistula site twice during the next three days. Because the patient could not tolerate pressure patching, topical antibiotic and steroid ointments were instilled every hour while she was awake. The day after the second application of tissue adhesive the filtering bleb was Seidel negative. When the tissue adhesive was removed four days later, the conjunctiva had successfully healed over the wound leak. The conjunctival fistula has subsequently remained closed. While the patient was using no glaucoma eye drops, the intraocular pressure was 5 to 6 mmHg for the next two months and 9 to 10 mmHg for the subsequent three months.

CASE 5

A 73-year-old white female with angle closure glaucoma in the left eye controlled by a trabeculectomy performed in July 1989 developed a spontaneous, recurrent wound leak in a small, cystic filtering bleb. The original wound leak, which developed in October 1989, closed after application of a tissue adhesive and a bandage soft contact lens. Two weeks after the tissue adhesive was removed in April 1990 a recurrent fistula developed in the superonasal filtering bleb and did not close with several days of pressure patching. On examination a tiny Seidel-positive wound leak was noted in the portion of the filtering bleb overhanging the cornea. There was no infiltrate in or around the filtering bleb, and the anterior chamber was deep and quiet. The intraocular pressure by applanation tonometry was 12 mmHg while the patient was using timolol eye drops 0.5% twice daily. Tissue adhesive was applied to the wound leak site. The eye was treated with trimethoprim-polymyxin B (Polytrim) twice a day without pressure patching. The next day, the tissue adhesive was found dislodged into the inferior cul-de-sac, and the wound leak was still present. Tissue adhesive was reapplied, and the eye was pressure patched over a bandage soft contact lens. The next day

the tissue adhesive was in good position and a Seidel test was negative. One week later pressure patching was discontinued and frequent ointment instillation was started, dexamethasone-hypromellose (Maxidex) alternating with erythromycin every hour while the patient was awake. The bandage soft contact lens and the crystallised tissue adhesive were removed one month later. The fistula had closed and there was no evidence of a wound leak. However, a 1×1.5 mm corneal epithelial defect was present adjacent to the fistula site. This iatrogenic abrasion resolved in two days by continued frequent instillation of ointment. Since then, the intraocular pressure has been 13 to 14 mmHg while using only Timoptic.

Discussion

To our knowledge these five cases represent the largest reported series of leaking filtering blebs successfully closed with cyanoacrylate tissue adhesive. While it is an accepted treatment approach for this condition,^{14,15} only nine cases have been previously reported.¹⁻⁷ Other techniques for managing conjunctival fistulas in glaucoma filtering blebs have included conservative measures such as pressure patching, medications to decrease aqueous flow, bandage soft contact lens, scleral tamponade shell, collagen shield, and microsurgical suture repair or wound revision.⁸⁻¹⁵ All the surgical options require another invasive procedure with the operating room microscope and possibly retrobulbar or general anaesthesia. In contrast the application of tissue adhesive is easily performed under topical anaesthesia in the surgeon's consulting room without the aid of a microscope. In four of our five cases the tissue adhesive not only stopped the continuous external flow of aqueous humour, allowing the conjunctival defect to heal, but also preserved the integrity of the filtering bleb.

Conjunctival fistulas may develop either during glaucoma filtering surgery or as an early or late postoperative complication. During the operation leakage may result from a conjunctival buttonhole or tearing of the conjunctiva caused by suture tracks or instrument damage.⁸ In the early postoperative period leakage has traditionally been ascribed to inadequate closure of the conjunctival flap or failure to recognise buttonholes during surgery. Recently the use of 5-fluorouracil in high-risk glaucoma filtering surgery has introduced a new means by which these leaks may occur.¹⁶ In the late postoperative period a fistula may develop either spontaneously or from trauma and tends to occur in large, thin-walled blebs.⁹ Of the nine previously reported

Table 1 Clinical features of cases and results of treatment with tissue adhesive

Case	Date of filter surgery	Date of bleb leak	Aetiology of bleb leak	Number of times glue applied	IOP*		Post-treatment medication or surgery	Problems with tissue adhesive
					Pre treatment	Post treatment		
1	1971	1985	Spontaneous rupture	1	14	13	None	Corneal abrasion
2	1987	1988	Spontaneous rupture	2	4	8	Timolol	Corneal abrasion
3	1967	1988	Bacterial conjunctivitis	4	20	31	Repeat filter	None
4	1984	1989	Bacterial conjunctivitis	2	3	6	None	None
5	1989	1990	Spontaneous rupture	2	12	14	Timolol	Corneal abrasion

*Intraocular pressure.

cases treated by tissue adhesives six were of wound leaks occurring in the early postoperative period after glaucoma filtering procedures. In all five of our cases filtering bleb leaks developed as a remote complication following trabeculectomy, occurring anywhere from 10 months to 21 years postoperatively. Two of our patients developed filtering bleb leaks as a complication of bacterial conjunctivitis, while in the three other patients no antecedent cause could be identified.

On examining the clinical features and results of treatment in our five cases (Table 1) we can make several interesting observations. First, four eyes required more than one application of tissue adhesive. It may be necessary to vary the technique used after application to prevent the tissue adhesive from dislodging and to facilitate healing of the bleb leak. As adjuncts, pressure patching with or without bandage soft contact lenses and frequent ointment instillation were all successful in our series. One of the cases previously reported⁶ used tissue adhesive in conjunction with a collagen shield to close a conjunctival wound leak occurring after trabeculectomy. Secondly, three eyes had normal intraocular pressure in the presence of Seidel-positive bleb leak. The tendency was for eyes with multicystic blebs to have normal intraocular pressures, while those with thin, single walled blebs were hypotonous. Thirdly, four anterior chambers were deep in the presence of a Seidel-positive bleb leak. Apparently the breakdown of filtering blebs as a late complication does not immediately lead to hypotony or a flat chamber and may be overlooked on routine follow-up unless the eye is examined closely. Even when the intraocular pressure is normal and the chamber deep, filtering bleb leaks should be repaired to prevent endophthalmitis. Slow, low-flow leaks in old, well developed filtering blebs may be particularly suited for closure with tissue adhesive. Fourthly, three eyes developed corneal erosions at the site of tissue adhesive application adjacent to the leaking blebs. Corneal epithelial defects should be anticipated if the tissue adhesive extends on to the corneal surface.

Cyanoacrylate adhesives have been used in experimental and clinical ophthalmic surgery for almost 30 years.¹⁷ Tissue adhesives provide a valuable, non-surgical adjunct in the manage-

ment of wound leaks associated with penetrating keratoplasty, trauma, corneal thinning disorders, and descemetocoeles, as well as in glaucoma filtering surgery. The liquid adhesive n-butyl-2-cyanoacrylate forms a watertight seal with contacted tissues. This makes the material particularly suitable for certain ophthalmic procedures, including repair of corneal perforations and conjunctival fistulas. Although not a permanent seal, the adhesive maintains an environment that permits wound healing. We strongly recommend its use as a presurgical treatment in the management of leaking filtering blebs which occur as remote complications of glaucoma surgery.

This study was supported in part by a grant from Research to Prevent Blindness Inc, New York.

- 1 Grady FJ, Forbes M. Tissue adhesive for repair of conjunctival buttonhole in glaucoma surgery. *Am J Ophthalmol* 1969; **68**: 656-8.
- 2 Awan KJ, Spaeth PG. Use of isobutyl-2-cyanoacrylate tissue adhesive in the repair of conjunctival fistula in filtering procedures for glaucoma. *Ann Ophthalmol* 1974; **6**: 851-3.
- 3 Aminlari A, Sassani JW. Tissue adhesive for closure of wound leak in filtering operations. *Glaucoma* 1989; **11**: 86-8.
- 4 Bechetoille A, Chabanais JL, Jallet G. Utilisation de la colle isobutyl-2-cyanoacrylate dans le traitement des fistules externes après trabeculectomie. *Bull Soc Ophthalmol Fr* 1977; **77**: 765-7.
- 5 Ginsberg SP, Polack FM. Cyanoacrylate tissue adhesive in ocular disease. *Ophthalmic Surg* 1972; **3**: 126-32.
- 6 Weber PA, Baker ND. The use of cyanoacrylate adhesive with a collagen shield in leaking filtering blebs. *Ophthalmic Surg* 1989; **20**: 284-5.
- 7 Martinez LA, Miller KN, Brown RH, et al. The Nd: YAG laser removal of cyanoacrylate used to repair conjunctival wound leaks. *Am J Ophthalmol* 1989; **108**: 86-7.
- 8 Petrusson GJ, Fraunfelder FT. Repair of an inadvertent buttonhole or leaking filtering bleb. *Arch Ophthalmol* 1979; **97**: 926-7.
- 9 Sugar HS. Complications, repair, and reoperation of anti-glaucoma filtering blebs. *Am J Ophthalmol* 1967; **63**: 825-33.
- 10 Ruderman JM, Allen RC. Simmons' tamponade shell for leaking filtration blebs. *Arch Ophthalmol* 1985; **103**: 1708-10.
- 11 Tomlinson CP, Belcher CD, Smith PD, et al. Management of leaking filtering blebs. *Ann Ophthalmol* 1987; **19**: 405-8.
- 12 Epstein DL. *Chandler and Grant's glaucoma*. 3rd ed. Philadelphia: Lea and Febiger, 1986; 434-50.
- 13 Fourman S, Wiley L. Use of a collagen shield to treat a glaucoma filter bleb leak. *Am J Ophthalmol* 1989; **109**: 673-4.
- 14 Hoskins HD, Kass MA. *Becker-Shaffer's diagnosis and therapy of the glaucomas*. 6th ed. St Louis: Mosby, 1989; 583-604.
- 15 Luntz MH, Harrison R, Schenker HI. *Glaucoma Surgery*. Baltimore: Williams and Wilkins, 1984; 124-44.
- 16 Rockwood EJ, Parrish RK, Heuer DK, et al. Glaucoma filtering surgery with 5-fluorouracil. *Ophthalmology* 1987; **94**: 1071-8.
- 17 Refojo MF, Dohlman CH, Koliopoulos J. Adhesives in ophthalmology: a review. *Surv Ophthalmol* 1971; **15**: 217-36.