



# Thyroid artery embolization of large solitary symptomatic benign thyroid nodules through transradial approach

Kai-Lun Cheng<sup>1,2^</sup>, Keng-Wei Liang<sup>1,2^</sup>, Hsiang-Lin Lee<sup>2,3^</sup>, Hui-Yu Wang<sup>1^</sup>, Chao-Yu Shen<sup>1,2^</sup>

<sup>1</sup>Department of Medical Imaging, Chung Shan Medical University Hospital, Taichung; <sup>2</sup>School of Medicine, Chung Shan Medical University, Taichung; <sup>3</sup>Department of Surgery, Chung Shan Medical University Hospital, Taichung

*Correspondence to:* Chao-Yu Shen, MD, PhD. School of Medicine, Chung Shan Medical University, Taichung; Department of Medical Imaging, Chung Shan Medical University Hospital, No. 110, Sec. 1, Jianguo N. Rd., Taichung. Email: shenchaoyu@gmail.com.

**Abstract:** This study investigated the efficacy and safety of transradial access (TRA) thyroid artery embolization (TAE) for patients with large solitary symptomatic benign thyroid nodules. Six patients with a total of six nodules (three men and three women; mean age, 36.3 years; age range, 23–45 years) underwent TRA TAE between October 2021 and June 2022 and were subsequently followed up three months later, and their cases were retrospectively reviewed. The associated complications were recorded during and after TRA TAE. The volume change and nodule-related symptom score on a 10-cm visual analogue scale (VAS) between baseline, 1- and 3-month follow-up was analyzed using Wilcoxon signed-rank test. The technical success rate of the TRA TAE was 100% without conversion to transfemoral access. The mean volume of the nodules decreased between baseline (84.1 mL; range, 46.1–170.5 mL), 1-month (38.8 mL; range, 17.6–91.5 mL;  $P=0.028$ ) and 3-month (14.8 mL; range, 3.95–26.4 mL;  $P=0.068$ ) at follow-up after TRA TAE. The mean volume reduction rate was 54.9% (range, 45.2–71.8%) at 1-month follow-up and 81.8% (range, 62.0–92.0%) at 3-month follow-up. The VAS score was reduced at 1-month ( $P=0.028$ ) and at 3-month follow up ( $P=0.068$ ). Radial artery spasm ( $n=1$ ) was noted during TRA TAE, and neck pain ( $n=5$ ) and voice change ( $n=1$ ) occurred within 1 week after the procedure and resolved with conservative treatment. No major complications were reported. TRA TAE may be a promising alternative therapy for the management of large solitary thyroid nodules.

**Keywords:** Thyroid nodules; transradial access (TRA); embolization

Submitted Dec 13, 2022. Accepted for publication May 08, 2023. Published online May 30, 2023.

doi: 10.21037/qims-22-1385

**View this article at:** <https://dx.doi.org/10.21037/qims-22-1385>

## Introduction

Partial thyroidectomy is currently the standard therapy for benign nodules greater than 3 or 4 cm in size resulting in cosmetic or compressive symptoms. However, surgery-related complications, such as cervical scars, hypothyroidism requiring lifelong hormone replacement, or recurrent laryngeal nerve palsy may occur even after hemithyroidectomy. Therefore, the latest international

multidisciplinary consensus statement recommends ultrasound-guided ablation procedures as a first-line alternative to surgery for patients with benign thyroid nodules contributing to compressive or cosmetic symptoms (1). Ablation procedures for large nodules with a volume of >20–30 mL may be less effective or more time-consuming than those for smaller nodules (2–4). Alternative therapies other than ablation procedures or thyroidectomy may be offered for patients with large thyroid nodules.

<sup>^</sup> ORCID: Kai-Lun Cheng, 0000-0003-3883-2104; Keng-Wei Liang, 0000-0001-9124-4737; Hsiang-Lin Lee, 0000-0003-1422-1042; Hui-Yu Wang, 0000-0002-8409-693X; Chao-Yu Shen, 0000-0003-3571-0697.

Yilmaz *et al.* (5) successfully used transfemoral thyroid artery embolization (TAE) to treat large thyroid nodules with considerable volume reduction. Compared with transfemoral access (TFA), transradial access (TRA) is becoming more widely accepted for various neurointerventional diagnoses and therapy procedures (6-8). TRA has been associated with reduced complication rates (6-8) and improved patient satisfaction (9) compared with TFA. Because of the advantages of TRA, TRA TAE may be an alternative therapy for large thyroid nodules. This study evaluated the short-term safety and efficacy of TRA TAE for the treatment of large thyroid nodules.

## Methods

This study included six patients who underwent TAE with local anesthesia between October 2021 and June 2022 for solitary thyroid nodule (all TAE were performed by CY Shen with 15-year neurointerventional experience). The included patients had unilateral dominant solitary large (>20 mL) solid (solid portion >90% under ultrasound) nodules, were not willing to receive radiofrequency ablation (RFA), with compressive or cosmetic symptoms, and with results from two separate sessions of Bethesda-category-2 (benign) fine-needle aspiration-biopsy or core-needle biopsy. All patients in the present study were previously offered surgery, but they all refused to receive lobectomy. Before embolization, all patients were examined with ultrasound, computed tomography (CT), or magnetic resonance imaging (MRI) to determine the size and location of the nodules. This retrospective study was conducted in accordance with the Declaration of Helsinki (as revised in 2013) and was approved by the Institutional Review Board of Chung Shan Medical University Hospital (No. CS2-22091). All patients were informed about the risks and potential benefits of the embolization and of alternative treatments, and they signed an informed consent form.

For TRA, both a Barbeau test and ultrasound of the approach side distal radial artery were performed, and only patients whose Barbeau test indicated A, B, or C patterns and a radial arterial diameter  $\geq 2$  mm were selected as candidates.

After 3-mL 1% lidocaine subcutaneous injection, the radial artery was punctured at approximately 5 cm cephalic to the styloid process with a 21-G Micropuncture system (Cook, Bloomington, IN, USA) under ultrasound guidance, and a 5-F sheath (Terumo, Tokyo, Japan) was exchanged using the Seldinger technique. Subsequently, a radial artery cocktail composed of 3,000 units of heparin,

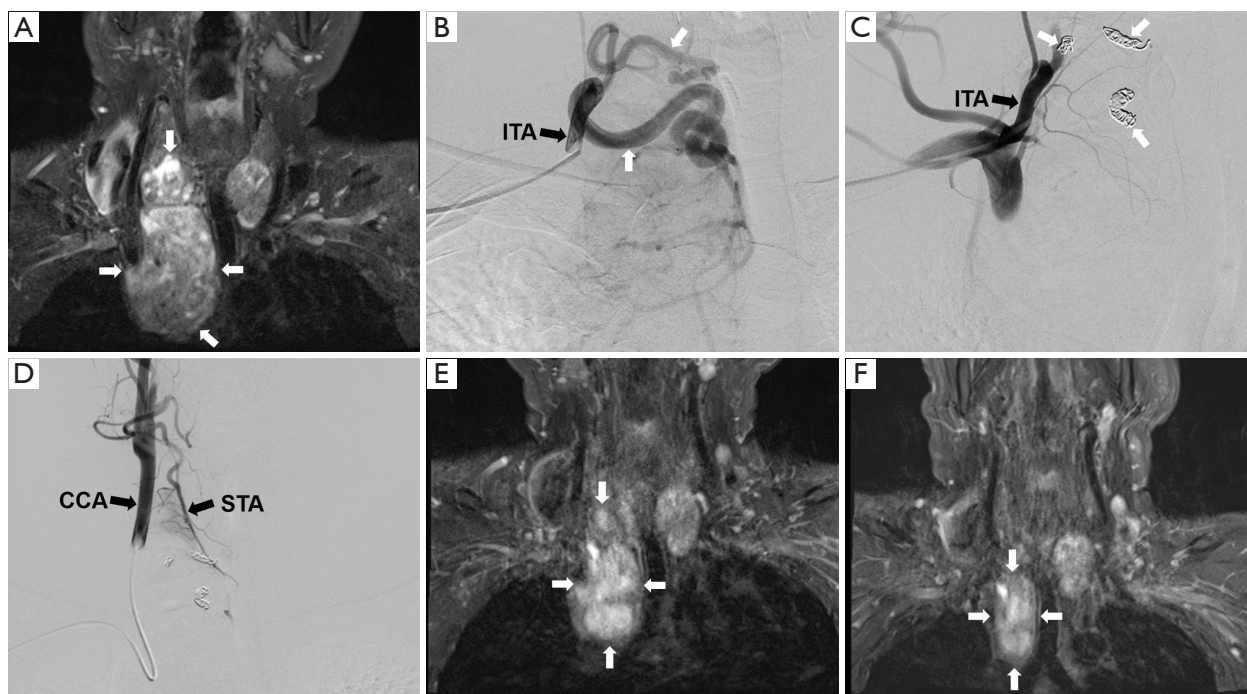
1.25 mg verapamil, and 500 mcg nitroglycerin was slowly administered through the radial sheath.

Under fluoroscopic guidance, a 0.035" Guidewire (Terumo) was smoothly advanced from the radial artery to the brachial artery. Then, a 5-F Simon II catheter (Cook) was introduced over the wire. Both the wire and the 5-F Simon II catheter were subsequently advanced to the ascending aorta and reversed at the aortic valve for reforming the distal reverse curve of the Simon II catheter.

Using Simon II catheter, unilateral digital subtraction angiography (DSA) of common carotid artery and thyrocervical trunk (or proximal subclavian artery) were performed to identify the thyroid nodular feeding arteries. Under fluoroscopic road map or overlay controlled, a Synchro-14 microwire and an Excelsior 1018 microcatheter (Stryker, Kalamazoo, MI, USA) were advanced to the feeding arteries. Embosphere microspheres (300–500 or 500–700  $\mu\text{m}$ ) (Merit Medical, South Jordan, UT, USA) mixed with iodinated contrast media (1-to-1) was gently injected with a 3-mL syringe by pulsing motion in free flow fashion until stagnation. The proximal parts of the feeding arteries were also occluded by pushable coils (Cook) at the end of the TRA TAE procedure.

Post-TAE, controlled angiography of the common carotid and the thyrocervical trunk were performed for confirmation of occlusion of the thyroid feeding arteries and obliteration of the thyroid tumor stains. Finally, hemostasis of the radial arterial puncture wound was performed with a rigid TR band (Terumo Interventional, Somerset, NJ, USA) for a duration of two hours (10). Patients were ambulated and discharged as their medical condition permitted on the same day after 1- to 2-hour observation. Images from the representative case are displayed in *Figure 1*.

After discharge, patients were prescribed an oral nonsteroidal anti-inflammatory drug (mefenamic acid, 500 mg, four times daily) and oral steroid drugs (prednisolone, 20–30 mg, once daily) for 7 days to reduce the postoperative edema and inflammation of thyroid. No prophylactic antibiotic was used before, during, or after TAE. The thyroid hormones were studied at baseline and 1 month after TAE. At 1 month and 3 months, follow-up ultrasound, CT, or MRI was performed, and the images were compared with the pre-embolization images. On these images, regions of interest (ROI) were manually defined on CT or MRI. ROI area measurements for each slice were multiplied by the image-slice thickness and summed to generate volumes (11-13). For ultrasound, the nodule volume was calculated as  $V = \pi abc/6$  (where  $V$  is the



**Figure 1** A 42-year-old man with a large solitary nodule in the right thyroid lobe receiving transradial approach thyroid artery embolization. (A,E,F) MRI T2WI coronal image of the treated thyroid nodule. (B,C,D) Angiogram of transradial approach thyroid artery embolization. The MRI T2WI image (A) indicates a nodule (white arrows) measuring 5.2 cm × 5.5 cm × 11.2 cm (volume, 170.5 mL). Transradial access selective anteroposterior right ITA angiogram (black arrow) (B) indicates two feeding arteries (white arrows) from right ITA and then embolized with particle and coils (C, white arrows). The post-embolization angiogram from right ITA (C, black arrow) indicates total occlusion of feeding arteries. (D) Selective anteroposterior right CCA angiogram indicates no blood supply from right STA of the thyroid nodule. At 1 month (E) and 3 months (F), the follow-up MRI T2WI indicates shrinkage of the nodule in the right lobe measuring 3.9 cm × 5.5 cm × 8.2 cm (E, white arrows, volume, 91.5 mL; VRR, 46.4%) and 3.4 cm × 2.1 cm × 5.3 cm (F, white arrows, volume, 22.9 mL; VRR, 86.6%), respectively. Volume is calculated as follows: ROI is manually defined on MRI. ROI area measurements for each slice are multiplied by the image slice thickness and sum to generate volumes. MRI, magnetic resonance imaging; ITA, inferior thyroid artery; CCA, common carotid artery; STA, superior thyroid artery; VRR, volume reduction rate; ROI, regions of interest.

volume,  $a$  is the largest diameter, and  $b$  and  $c$  are the two perpendicular diameters). The volume reduction rate (VRR) was calculated by applying the following formula:  $VRR = (\text{Volume}_{\text{baseline}} - \text{Volume}_{\text{follow-up}}) / \text{Volume}_{\text{baseline}} \times 100\%$  (14).

The complications were assessed according to the standard terminology of the Society of Interventional Radiology (SIR) (15). A major complication was defined as one that, if left untreated, could be life threatening, could lead to minor or prolonged hospital stay, or could result in permanent adverse sequelae with substantial morbidity and disability. All other complications were considered minor. Complications were classified as intraprocedural, periprocedural (within 24 hours after TAE) and delayed (in the 30 days following treatment).

All patients were asked to rate their nodule-related

symptom score on a 10-cm visual analogue scale (VAS) (0–10) before the TRA TAE and follow-up.

### Statistical analysis

Statistical analysis was performed using MedCalc Statistical Software version 20.014 (MedCalc Software, Ostend, Belgium; <https://www.medcalc.org>; 2021). Comparisons of VAS score and volume change between baseline, 1- and 3-month follow-up were performed using Wilcoxon signed-rank test.

### Results

TRA TAE was performed on six solitary large thyroid nodules (mean volume: 84.1 mL; range, 46.1–170.5 mL)

**Table 1** Details of thyroid artery embolization procedures and complications

No./Age/ Sex	Nodule site	TRA site	Radial artery diameter (mm)	Barbeau test	Target vessel	Embosphere size (µm)	Intraprocedural complication	Periprocedural complication	Delayed complication
1/30/F	Right	Right	2.3	A*	STA	500–700	Radial artery spasm	No	Pain
2/45/M	Right	Right	3.0	A	STA/ITA	300–500	No	No	No
3/45/F	Left	Left	2.4	A	STA/ITA	300–500	No	No	Pain
4/33/F	Left	Right	3.2	A	STA/ITA	300–500	No	Vomiting	Pain
5/23/M	Right	Right	2.8	A	STA/ITA	300–500	No	No	Pain/voice change
6/42/M	Right	Right	2.0	A	ITA	300–500	No	No	Pain

\*, Barbeau test A: no damping of the pulse tracing immediately after compression. Periprocedural complication: happened within 24 hours after TAE; Delayed complication: happened in the 30 days following treatment. TRA, transradial access; STA, superior thyroid artery; ITA, inferior thyroid artery.

**Table 2** Details of patient demographics and treatment outcomes

No.	Volume (mL)			VRR (%)		VAS score			TSH (µIU/mL)		Free T4 (ng/dL)		T3 (ng/dL)	
	Baseline	1 M*	3 M**	1 M	3 M	Baseline	1 M*	3 M**	Baseline	1 M	Baseline	1 M	Baseline	1 M
1	69.3	38.0	26.3	45.2	62.0	8	3	1	0.942	1.233	1.217	1.211	90.1	89.5
2	100.1	28.2	–	71.8	–	8	3	–	1.812	2.443	0.896	0.880	95.1	82.4
3	46.1	17.6	6.18	61.8	86.6	7	2	1	<0.03	0.622	2.002	0.812	134.0	78.6
4	49.2	19.9	3.95	59.6	92.0	8	3	1	1.370	1.435	0.965	1.976	88.6	85.1
5	69.3	37.4	–	46.0	–	7	3	–	2.653	3.896	1.311	1.575	88.7	105.3
6	170.5	91.5	22.9	45.2	86.6	8	3	1	0.520	1.290	1.15	1.033	83.2	139.9

\*, size observed significantly decreased in size with Wilcoxon signed-rank test ( $P=0.028$ ). \*\*, size observed decreased in size without significance with Wilcoxon signed-rank test ( $P=0.068$ ). \*, VAS significantly decreased with Wilcoxon signed-rank test ( $P=0.028$ ). \*\*, VAS decreased without significance with Wilcoxon signed-rank test ( $P=0.068$ ). VRR (%): volume reduction rate =  $(\text{Volume}_{\text{baseline}} - \text{Volume}_{\text{follow-up}}) / \text{Volume}_{\text{baseline}} \times 100$ . VAS score, visual analogue scale (0–10); TSH, thyroid-stimulating hormone; M, month(s).

and the pre-TAE DSA showed prominent and tortuosity of the thyroid nodular feeders with strong tumor stain and without obvious arteriovenous shunts. The average patient age was 36.3 years old (range, 23–45 years old). The subjects comprised of three women and three men. Five patients were euthyroid, and one (No. 3) was hyperthyroid and treated with propylthiouracil before TAE. Each patient was evaluated using ultrasound to check their thyroid nodules and radial artery and was deemed eligible for TRA.

The details of the TAE procedures and complications are summarized in *Table 1*. Each patient had a radial artery diameter between 2.0 and 3.2 mm. Only one patient (No. 3) received left radial artery access because of a right aberrant subclavian artery. In one patient (No. 1), intraprocedural complication with radial artery spasm was observed during catheterization, which resolved with administration of

intra-arterial calcium channel blocker. Conversion to TFA was not necessary. Each patient achieved hemostasis after application of a rigid TR band over the puncture site. With the exception of one patient (No. 4) who had periprocedural complication with temporary vomiting, no neurologic symptoms or blurred vision were noted, and all patients were discharged on the same day. Delayed minor complications were noted in five patients. One patient (No. 5) experienced considerable hoarseness following TAE that resolved after oral corticosteroid treatment for 7 days. Neck pain occurred in five patients and resolved after oral mefenamic acid treatment. No overt or subclinical hyperthyroidism and no major complications were noted.

The 1-month clinical and radiological evaluations were available for all of the patients and two patients (No. 2 and No. 5) lost follow up at 3 months (*Table 2*). Imaging findings

indicated statistically significant volume reduction in the nodules at 1 month follow-up and kept decreasing size at 3 months follow-up. The mean volume of the nodules was reduced from 84.1 to 38.8 mL at 1 month ( $P=0.028$ ) and 14.8 mL at 3 months ( $P=0.068$ ), with the mean VRR of 54.9% at 1 month and 81.8% at 3 months. The VAS score was reduced at 1-month ( $P=0.028$ ) and at 3-month follow up ( $P=0.068$ ). One patient (No. 4) exhibited mild elevation free thyroxine with normal thyroid-stimulating hormone, and no signs of hyperthyroidism were noted. The patient with hyperthyroidism (No. 3) stopped antithyroid medication after TAE and then came to have euthyroid at 1 month follow up.

## Discussion

To our knowledge, this is the first case series to demonstrate the usefulness and safety of radial access for thyroid TAE. The results indicate that TRA TAE may effectively decrease the volumes of large thyroid nodules at 3-month follow-up; this may result in considerable improvements in quality of life and clinical symptoms. The procedures were well tolerated by the patients and were not associated with major complications after TAE. Therefore, TRA TAE may be a good alternative therapy to surgery or percutaneous ablation in selected patients with a large thyroid nodule.

Traditionally, unilateral lobectomy has been the most effective therapeutic choice for benign thyroid nodules, but a cervical scar, potential hypothyroidism, and the need to undergo general anesthesia are thought to be some of the reasons for patient reluctance to receive surgery. Minimally invasive thermal ablation procedures, such as RFA (16), microwave (17), or high-intensity focused ultrasound (HIFU) (18), can significantly reduce nodule volume and nodule-related symptoms, and are regarded as safe and effective alternatives to treat benign thyroid nodules. The VRR of thermal ablation for nodules  $>30$  mL is generally regarded to be less than that of smaller nodules (4). By contrast, Lim *et al.* (3) has reported that thyroid nodules  $>20$  mL can achieve similar VRR compared with those smaller than 20 mL with  $3.8\pm 1.5$  times of RFA. However, the administration of numerous instances of thermal ablation may be time-consuming, expensive, and a detriment to the patient's quality of life. The mean volume of the embolized nodules in this series was much higher (84.1 mL) than the threshold of large thyroid nodules, and TAE resulted in a mean volume reduction of 54.9% in large nodules at 1-month follow-up, which is superior to the 45.3% volume reduction

obtained after 1 month using percutaneous ablation in large nodules (2). These results suggest that embolization may be a potentially more effective treatment option to percutaneous ablation for large thyroid nodules.

TAE has been used for the management of Graves' disease, mainly with the embolization of three thyroid feeding arteries (19). Unlike studies of Graves' disease, the present study investigated only solitary large thyroid nodules; blood is usually supplied to these nodules from the ipsilateral superior and inferior thyroid arteries. Before embolization, angiography was used to identify the major feeding branch of the superior and inferior thyroid artery; this allowed the target nodules to be exposed to as much treatment as possible and allowed the normal thyroid parenchyma to be unaffected. Determination of the precise feeding artery embolization allows for personalized treatment; this allows for greater volume reduction with a lower risk of hypothyroidism.

Yilmaz *et al.* (5) have already reported embolization for 20 patients with a solitary or dominant nodule, which is similar with the present study (*Table 3*). The major difference between these two studies was the approach method for TAE. Instead of the transfemoral approach, this study used TRA. In recent years, in addition to diagnostic cerebral angiography, TRA for neurointervention has rapidly become more popular for the treatment of brain vascular malformation, aneurysms, carotid artery stenosis, intracranial vessel stenosis, mechanical thrombectomy, and tumor embolization (7). Our preliminary result further expands the utility of TRA to treat thyroid nodules.

Compared with traditional TFA, TRA has numerous benefits, including a lower incidence of access-site hemorrhagic complications and greater likelihoods of early ambulation without post-procedure bedrest and early discharge without hospital admission (9). However, complications, such as radial artery spasm (20), may be encountered when TRA is performed. Slowing the intra-arterial injection of vasodilatory cocktails with heparin, verapamil, and nitroglycerin can prevent spasms during TRA (21). One of our patients still encountered significant spasms after routine intra-arterial vasodilatory cocktail injection. Although the spasms subsided after additional calcium channel blocker injection, we only performed superior thyroid artery TAE because of the patient's discomfort. The exact mechanism causing radial artery spasm is unclear, and the reported incidence ranges from 4% to 20% in the literature (20). Spasms can cause patient discomfort, reduce the procedural success rate, and are the main cause of

**Table 3** Literature review of thyroid artery embolization for thyroid nodules

First author, year (Ref.)	Access method	Patient No.	Age, year	Sex (F:M)	Nodule type	No. of embolized feeders			Volume, mL				Complications	
						1	2	3	Baseline	1 month	3 months	6 months	Minor	Major
Present study	Trans radial	6	36.3 [23–45]	3:3	Solitary (n=6)	2	4	0	84.1±46.5	38.8±27.2	14.8±11.4	–	5*	0
Yilmaz 2021 (5)	Trans femoral	56	51.2 [23–86]	33:23	Group A [Solitary (n=20)]	–	18	2	80.2±46.7	–	–	25.0±15.3	25**	2***
					Group B [MGN (n=36)]	–	5	31	147.0±85.9	–	–	62.6±31.9		

Data are presented as number, median [range] or mean ± SD. \*, refer to *Table 1* for detailed data. \*\*, 1 patient: blurred vision; 2 patients: significant hoarseness; 22 patients: neck pain or subclinical hyperthyroidism. \*\*\*, 1 patient: groin hematoma; 1 patient: symptomatic hyperthyroidism that required extended (>48 h) hospitalization. MNG, multiple nodular goiter.

access-site crossover (7).

The major limitations of this study are the small sample size and short follow-up time. Future studies should investigate potential advantages of transradial TAE compared with current thermal treatments or surgery in terms of safety, efficacy, and durability. Additionally, longitudinal research is necessary to assess the durability of TAE because of the possibility of nodular regrowth.

## Conclusions

Despite these limitations, the present study demonstrated that TRA TAE is effective for the treatment of large thyroid nodules. A significant reduction in the volume of the nodules was observed in four out of six patients, partially measured by differing pre- and post-interventional imaging modalities, and conceded predominantly minor complications. TRA TAE may be considered as an alternative therapy when providing treatment choices to patients with larger thyroid nodules.

## Acknowledgments

This manuscript was edited by Wallace Academic Editing.

*Funding:* None.

## Footnote

*Conflicts of Interest:* All authors have completed the ICMJE uniform disclosure form (available at <https://qims.amegroups.com/article/view/10.21037/qims-22-1385/coif>). The authors have no conflicts of interest to declare.

*Ethical Statement:* The authors are accountable for all aspects of the work in ensuring that questions related to the accuracy or integrity of any part of the work are appropriately investigated and resolved. This retrospective study was conducted in accordance with the Declaration of Helsinki (as revised in 2013) and was approved by the Institutional Review Board of Chung Shan Medical University Hospital (No. CS2-22091). All patients were informed about the risks and potential benefits of the embolization and of alternative treatments, and they signed an informed consent form.

*Open Access Statement:* This is an Open Access article distributed in accordance with the Creative Commons Attribution-NonCommercial-NoDerivs 4.0 International License (CC BY-NC-ND 4.0), which permits the non-commercial replication and distribution of the article with the strict proviso that no changes or edits are made and the original work is properly cited (including links to both the formal publication through the relevant DOI and the license). See: <https://creativecommons.org/licenses/by-nc-nd/4.0/>.

## References

- Orloff LA, Noel JE, Stack BC Jr, Russell MD, Angelos P, Baek JH, et al. Radiofrequency ablation and related ultrasound-guided ablation technologies for treatment of benign and malignant thyroid disease: An international multidisciplinary consensus statement of the American Head and Neck Society Endocrine Surgery Section with the Asia Pacific Society of Thyroid Surgery, Associazione Medici Endocrinologi, British Association of Endocrine

- and Thyroid Surgeons, European Thyroid Association, Italian Society of Endocrine Surgery Units, Korean Society of Thyroid Radiology, Latin American Thyroid Society, and Thyroid Nodules Therapies Association. *Head Neck* 2022;44:633-60.
2. Ji X, Sun W, Lv C, Huang J, Zhang H. Meta-analysis of the efficacy and safety of thermal ablation for treating large benign thyroid nodules. *Clin Endocrinol (Oxf)* 2022;97:654-63.
  3. Lim HK, Lee JH, Ha EJ, Sung JY, Kim JK, Baek JH. Radiofrequency ablation of benign non-functioning thyroid nodules: 4-year follow-up results for 111 patients. *Eur Radiol* 2013;23:1044-9.
  4. Trimboli P, Castellana M, Sconfienza LM, Virili C, Pescatori LC, Cesareo R, Giorgino F, Negro R, Giovannella L, Mauri G. Efficacy of thermal ablation in benign non-functioning solid thyroid nodule: A systematic review and meta-analysis. *Endocrine* 2020;67:35-43.
  5. Yilmaz S, Habibi HA, Yildiz A, Altunbas H. Thyroid Embolization for Nonsurgical Treatment of Nodular Goiter: A Single-Center Experience in 56 Consecutive Patients. *J Vasc Interv Radiol* 2021;32:1449-56.
  6. Tso MK, Rajah GB, Dossani RH, Meyer MJ, McPheeters MJ, Vakharia K, Waqas M, Snyder KV, Levy EI, Siddiqui AH, Davies JM. Learning curves for transradial access versus transfemoral access in diagnostic cerebral angiography: a case series. *J Neurointerv Surg* 2022;14:174-8.
  7. Joshi KC, Beer-Furlan A, Crowley RW, Chen M, Munich SA. Transradial approach for neurointerventions: a systematic review of the literature. *J Neurointerv Surg* 2020;12:886-92.
  8. Li Y, Chen SH, Spiotta AM, Jabbour P, Levitt MR, Kan P, et al. Lower complication rates associated with transradial versus transfemoral flow diverting stent placement. *J Neurointerv Surg* 2021;13:91-5.
  9. Cooper CJ, El-Shiekh RA, Cohen DJ, Blaesing L, Burket MW, Basu A, Moore JA. Effect of transradial access on quality of life and cost of cardiac catheterization: A randomized comparison. *Am Heart J* 1999;138:430-6.
  10. Pancholy SB, Patel TM. Effect of duration of hemostatic compression on radial artery occlusion after transradial access. *Catheter Cardiovasc Interv* 2012;79:78-81.
  11. Cheng KL, Lu HJ, Lin X, Wang HY, Chou YH, Tyan YS, Tsai PH. Interval changes of histogram-derived diffusion indices predict treatment response to induction chemotherapy in head and neck cancer: a feasibility study. *Quant Imaging Med Surg* 2022;12:5383-93.
  12. Wang J, Shan Q, Liu Y, Yang H, Kuang S, He B, Zhang Y, Chen J, Zhang T, Glaser KJ, Zhu C, Chen J, Yin M, Venkatesh SK, Ehman RL. 3D MR Elastography of Hepatocellular Carcinomas as a Potential Biomarker for Predicting Tumor Recurrence. *J Magn Reson Imaging* 2019;49:719-30.
  13. Yang YT, Dong SY, Zhao J, Wang WT, Zeng MS, Rao SX. CT-detected extramural venous invasion is correlated with presence of lymph node metastasis and progression-free survival in gastric cancer. *Br J Radiol* 2020;93:20200673.
  14. Lee J, Shin JH, Hahn SY, Park KW, Choi JS. Feasibility of Adjustable Electrodes for Radiofrequency Ablation of Benign Thyroid Nodules. *Korean J Radiol* 2020;21:377-83.
  15. Sacks D, McClenny TE, Cardella JF, Lewis CA. Society of Interventional Radiology clinical practice guidelines. *J Vasc Interv Radiol* 2003;14:S199-202.
  16. Lin WC, Wang CK, Wang WH, Kuo CY, Chiang PL, Lin AN, Baek JH, Wu MH, Cheng KL. Multicenter Study of Benign Thyroid Nodules with Radiofrequency Ablation: Results of 762 Cases over 4 Years in Taiwan. *J Pers Med* 2022.
  17. Yue W, Wang S, Wang B, Xu Q, Yu S, Yonglin Z, Wang X. Ultrasound guided percutaneous microwave ablation of benign thyroid nodules: safety and imaging follow-up in 222 patients. *Eur J Radiol* 2013;82:e11-6.
  18. Chung SR, Baek JH, Suh CH, Choi YJ, Lee JH. Efficacy and safety of high-intensity focused ultrasound (HIFU) for treating benign thyroid nodules: a systematic review and meta-analysis. *Acta Radiol* 2020;61:1636-43.
  19. Zhao W, Gao BL, Yang HY, Li H, Song DP, Xiang ST, Shen J. Thyroid arterial embolization to treat Graves' disease. *Acta Radiol* 2007;48:186-92.
  20. Ho HH, Jafary FH, Ong PJ. Radial artery spasm during transradial cardiac catheterization and percutaneous coronary intervention: incidence, predisposing factors, prevention, and management. *Cardiovasc Revasc Med* 2012;13:193-5.
  21. Chen CW, Lin CL, Lin TK, Lin CD. A simple and effective regimen for prevention of radial artery spasm during coronary catheterization. *Cardiology* 2006;105:43-7.

**Cite this article as:** Cheng KL, Liang KW, Lee HL, Wang HY, Shen CY. Thyroid artery embolization of large solitary symptomatic benign thyroid nodules through transradial approach. *Quant Imaging Med Surg* 2023;13(8):5355-5361. doi: 10.21037/qims-22-1385