

North Carolina's dominant progressive foveal dystrophy: how progressive is it?

Kent W Small, John Killian, Walter C McLean

Abstract

We studied 34 family members at risk of having dominant progressive foveal dystrophy of Lefler, Wadsworth, and Sidbury (also called North Carolina macular dystrophy) and found 17 to be affected. Fifteen of these affected subjects were observed over at least a 10-year period for evidence of progressive macular degeneration. Only one subject showed objective evidence of progressive deterioration in only one eye. Our findings further substantiate that this dystrophy generally has a stable course, contrary to its original description.

which were said to progress from one stage to the next. Stage 1 maculae were described as 'scattered drusen and pigment dispersion'; stage 2 as 'confluent drusen'; and stage 3 as 'choroidal atrophy'. Additional testing disclosed normal results on electroretinography, electro-oculography, and colour vision tests. However, the progressive nature of the maculopathy was not well documented. The aminoaciduria was found to segregate separately from the macular abnormalities, suggesting that the urine and macular conditions were genetically unlinked and/or inherited as different Mendelian traits.

Two further observations recorded by Frank and associates² subsequently became controversial. Their description of the stage 3 macular lesion did not mention the staphylomatous or colobomatous-type appearance of the macula, previously noted by Lefler and associates.¹ They also recorded the peripheral retina as 'normal'. These points helped to confuse its nosology when similar diseases were later reported.

Lefler, Wadsworth, and Sidbury¹ in 1971 reported on 25 affected members of a family with a dominantly inherited macular dystrophy. They described marked ophthalmoscopic variability from one individual to another. Asymptomatic subjects had only 'mild pigmentation' in the macula, while those subjects with subnormal visual acuity all had ophthalmoscopically obvious macular abnormalities. The most severe cases were described as having macular 'colobomas'. In addition many of the family members had an associated aminoaciduria.

Frank and colleagues² further studied this same family and called the disease 'dominant progressive foveal dystrophy'. They reported on a total of 50 affected subjects and categorised the macular appearance into three clinical stages

Gass,³ who later examined an unspecified number of affected subjects, called this disease 'North Carolina macular dystrophy (NCMD)'. He questioned whether or not the maculopathy was progressive, and he described the most severe lesions as 'staphylomatous appearing' and the peripheral retina as abnormal. His observations were in apparent conflict with those of the earlier reports.²

Duke University Medical Center
J Killian
W C McLean

Center for Genetic Studies of Ophthalmological Disorders, Charleston, SC 29425, USA
K W Small

Correspondence to: Kent W Small, MD, Department of Ophthalmology, Medical University of South Carolina, 171 Ashley Avenue, Charleston, SC 29425-2236, USA.

Accepted for publication 4 October 1990

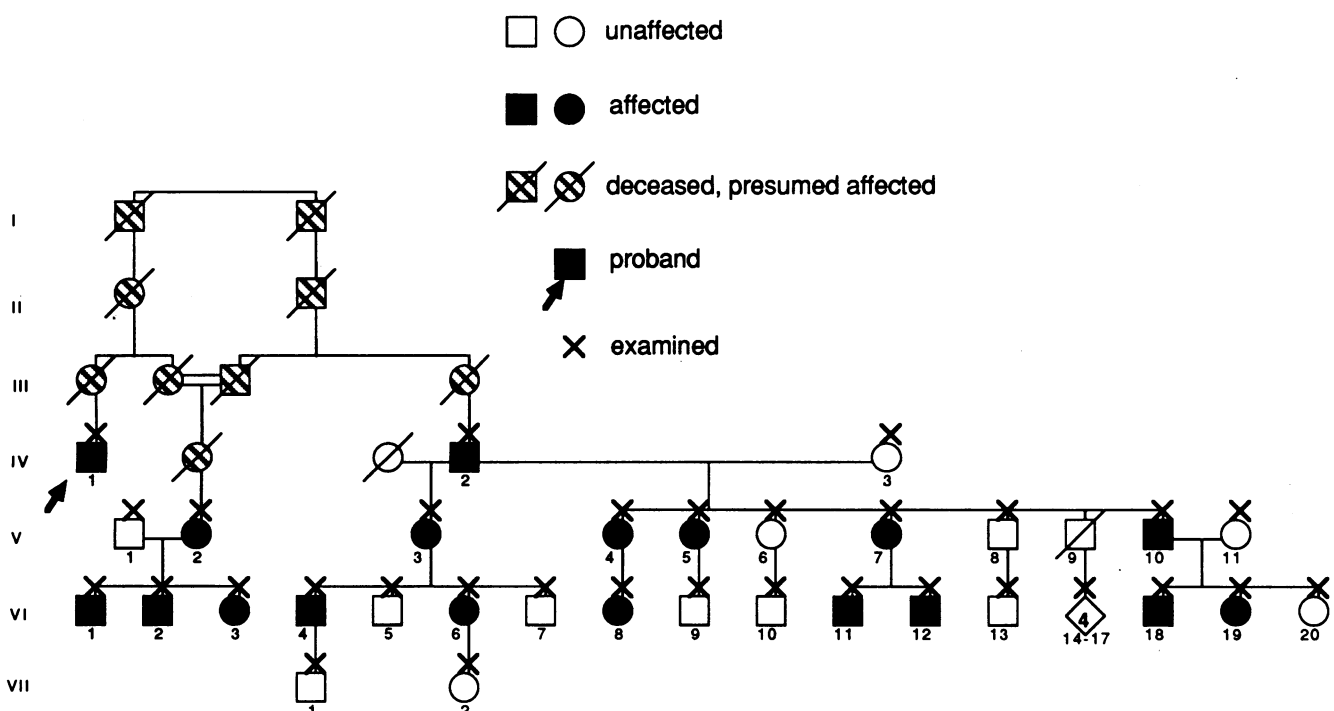


Figure 1 Abbreviated pedigree, relationship of original NCMD proband to remainder of family shown.

Table 1 Summary of results

Pedigree	Grade of macular lesion	Age at 1st examination	VA at 1st examination	Age at latest examination	VA at latest examination	Progression
VI-11	1	6	20/20-	16	20/20-	No
VI-6	1	28	20/20-	38	20/20-	No
VI-7	1	7	20/20	17	20/20	No
V-7	1	22	20/20-	33	20/20	No
VI-8	2	7	20/20-	17	20/25	No
V-5	2	16	20/20-	27	20/20	Subjective
V-4	2	27	20/100	38	20/200	No
VI-19	2	5	20/30	16	20/30	No
VI-4	2	18	20/30	29	20/25	No
VI-1	2	6	20/40	27	20/40	Subjective
VI-18	2	3	20/25	14	20/20-	Objective
V-10	3	29	20/30	40	20/30	No
VI-2	3	6	20/30	26	20/30	No
V-2	3	25	20/60	51	20/50	No
VI-3	3	6	20/50	30	20/40	No
IV-2	3		20/90	80	20/100	No
V-3	3		20/50	56	20/80-	No
					20/60	
					20/50	
					20/50	

Pedigree=individual in figure 1. VA=Snellen visual acuity, age in years.

From 1974 to 1989 no further reports of studies of this family appeared. We recently reascertained the original NCMD family to begin clearing up some of these controversies. In our preliminary report⁴ of 22 affected family members who had been examined 15-20 years earlier by Lefler *et al*¹ and Frank *et al*² we found only one subject who showed evidence of progressive visual deterioration in one eye. In the remaining 21, clinical course was stable. Furthermore, our fundus findings corroborated those of Gass.³ The severe cases were clearly excavated, colobomatous, or staphylomatous in appearance when examined with binocular methods. The peripheral retinae had yellow specks at the level of the retinal pigment epithelium which resembled drusen. We now report our findings in an additional 17 affected family members to provide additional data on the clinical course of NCMD.

Materials and methods

An extensive family history was obtained from 34 family members (17 affected) who were not initially known to be related to the original NCMD kindred. It became apparent that these subjects were direct descendants of the same three Irish brothers who brought NCMD to the United States some time before 1790. Therefore these 17 affected family members were afflicted with NCMD as well. The relationship of the proband of the original NCMD pedigree to these newly found NCMD family members is shown in Figure 1.

Fifteen of the 17 affected family members were initially examined by us at least 10 years ago and followed up to the present time. The ophthalmic examinations performed 10 years ago consisted in recording best corrected visual acuity at a distance of 20 feet (60 cm), pupillary

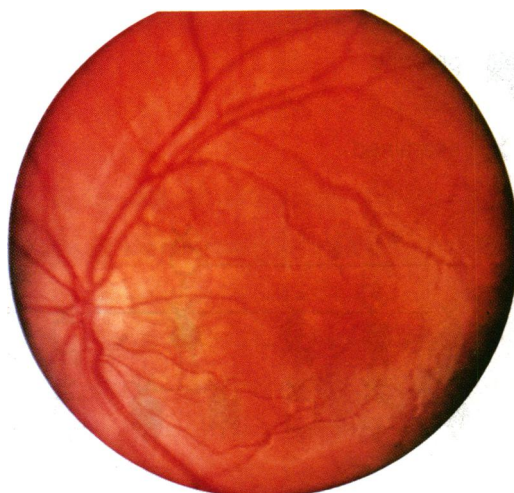


Figure 2A Right macula, grade 1, 6-year-old-male, VI-11, 20/20.

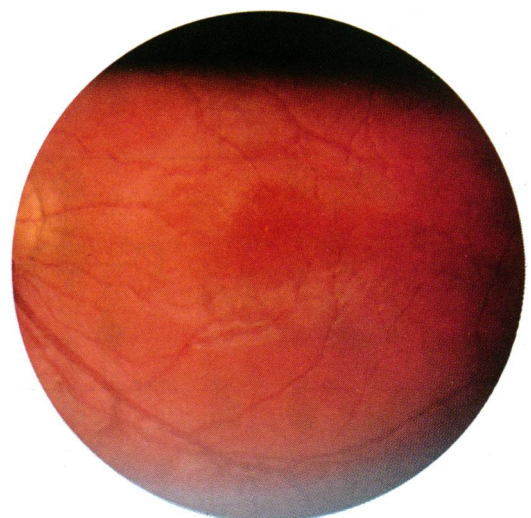


Figure 2B Unchanged at 16 years old.

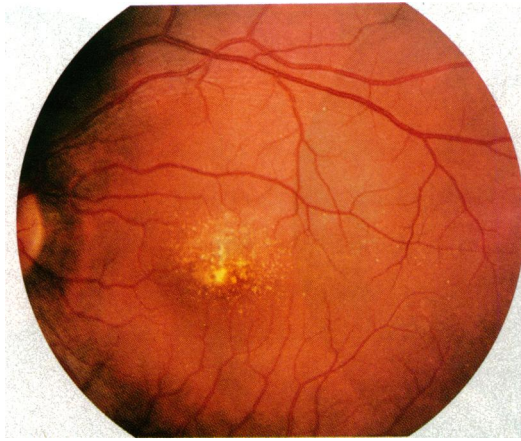


Figure 3A Left macula, grade 1, 28-year-old female, VI-6, 20/30.

reaction, slit-lamp examination, dilated fundus examination, and fundus photography. A fluorescein angiogram was performed on one subject. We performed the most recent ophthalmic examinations at home visits, recording visual acuity at near, namely 13 inches (33 cm) with the present spectacle correction, pupillary reactions, findings on dilated binocular indirect ophthalmoscopy, and the appearances on fundus photography with a hand held fundus camera. All affected subjects were asked whether they thought their vision had changed or been stable during their lifetime. Their visual acuities and fundus photographs from 10 years ago were compared with the recent findings for objective evidence of progressive macular changes.

Results

The results are summarised in Table 1. Fourteen of the affected subjects' ages ranged from 3 years to 29 years at the time of the initial examination. Ten of them were 18 years old or less at the time of their initial examination and therefore presumably at the greatest risk of having advancing disease.

We categorised the maculopathy according to a similar classification system used in our recent report.⁴ However, we are now referring to the gradation of the macular severity as 'grades' instead of 'stages' to emphasise further the stable

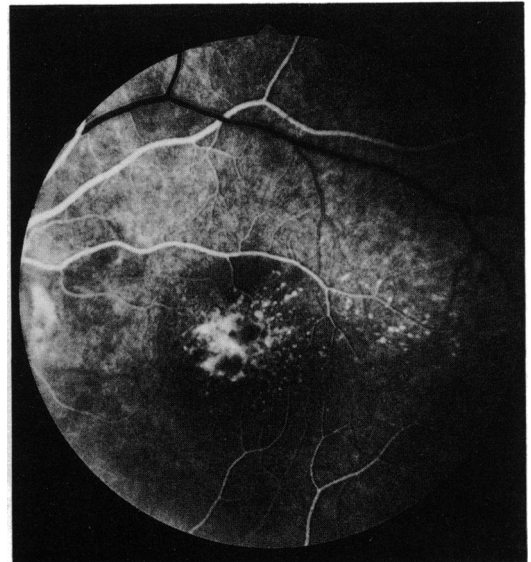


Figure 3B Fluorescein angiogram, early phase with window defects which did not spread in later frames.

nature of this disease. Four of the 17 affected subjects had grade 1 NCMD (Figs 2, 3) which consisted of only a few small flat yellow specks at the level of the retinal pigment epithelium. This was variably associated with pigment irregularity in the fovea. Grade 2 dystrophy (Figs 4-7) showed as confluent yellow specks at the level of the retinal pigment epithelium in the central macula. This was present in seven subjects. In the more severely affected grade 2 eyes (figs 6, 7), the maculopathy had a disciform appearance.

Grade 3 maculopathy (Figs 8, 9), present in six subjects, consisted of a discrete, well circumscribed, single, large (1-2 disc diameters) central macular excavation. The overlying neurosensory retina appeared intact as shown by the retinal vasculature draping over the sharp edge and dipping down into the crater. The absent or depigmented retinal pigment epithelium in the centre of the lesion was well demarcated. The only remnant of the choroid consisted of a few large choroidal vessels. The peripheral retinae of all affected subjects showed variable yellow specks and pigment irregularities also at the level of the pigment epithelium. Their visual acuities ranged from 20/20 to 20/200, median 20/30.

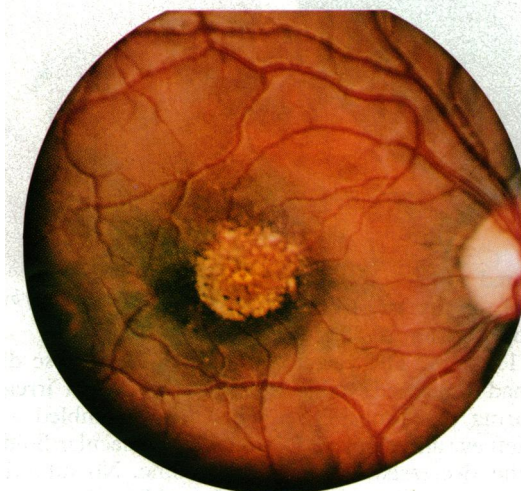


Figure 4A Right macula, grade 2, 7-year-old female, 20/30, VI-8.

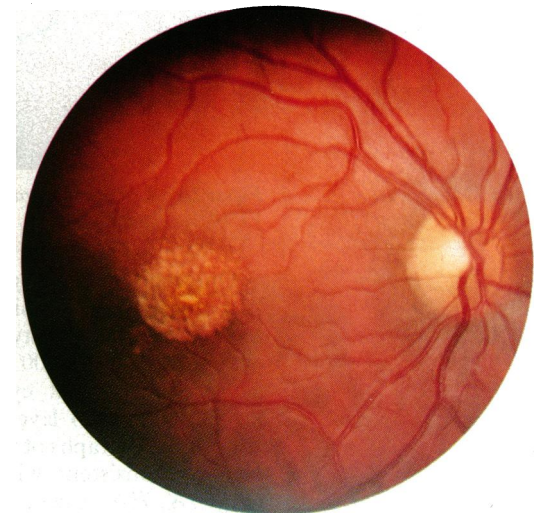


Figure 4B Unchanged at 17 years old.

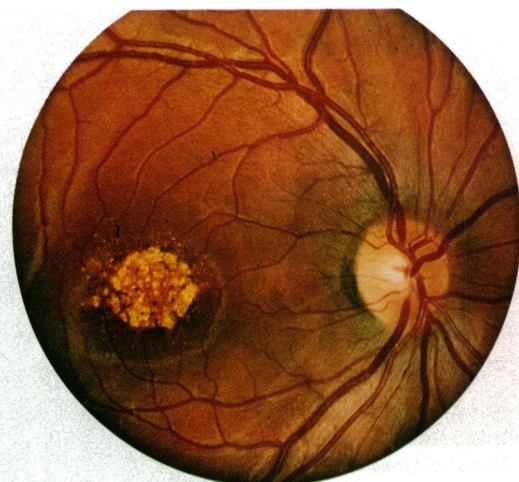

Figure 5A Right macula, grade 2, 16-year-old female, 20/30, V-5.

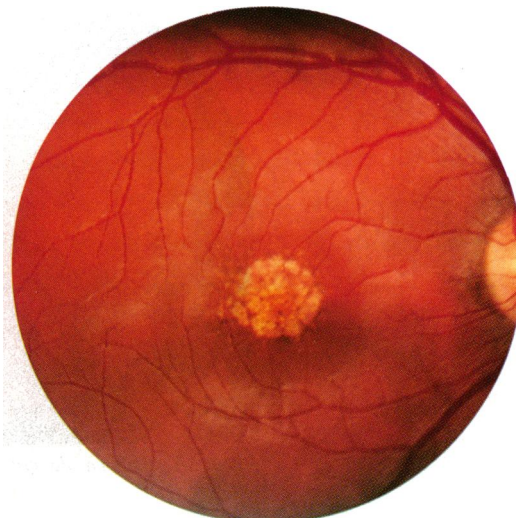


Figure 5B Unchanged at 27 years old.

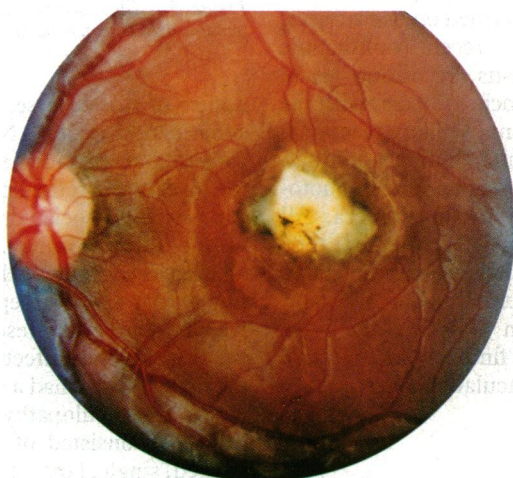


Figure 6A Left macula, grade 2, 16-year-old female, 20/100, V-5.

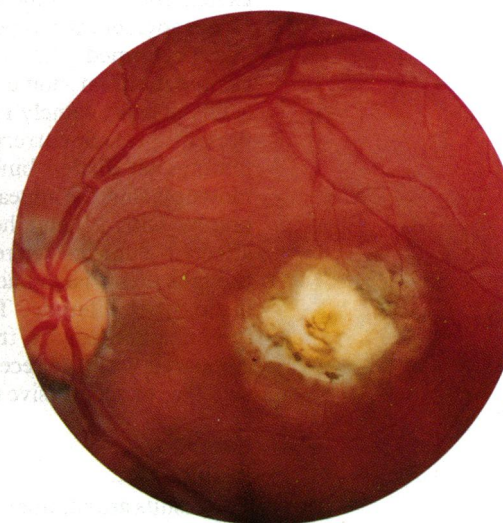


Figure 6B At 27 years old, minimally increased pigmentation.

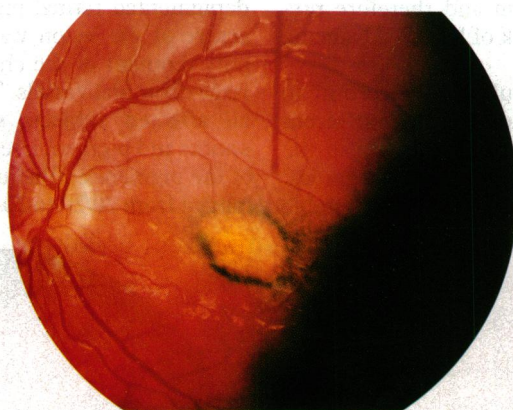


Figure 7A Left macula, grade 2, 3-year-old male, 20/30 VI-18.

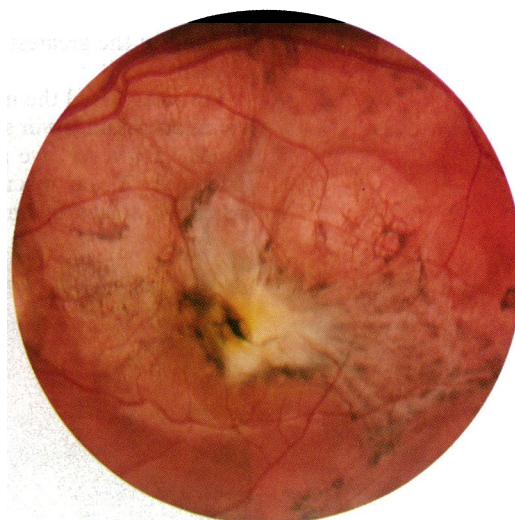

Figure 7B Marked change by 14 years old, 20/200.

Only one of the 17 affected subjects (VI-18) had objective progression of the disease. In his left eye the visual acuity dropped from 20/50 at 3 years of age to 20/200 by 13 years. The visual acuity in his right eye had remained stable around the 20/40 level during this time. The fundus photographs of the left eye also displayed changes consistent with the decreased vision (Figs 7A, 7B). A central white disciform lesion enlarged somewhat but probably more significant

was the large (1 disc diameter) halo of retinal pigment epithelial irregularity surrounding it. This halo resembled a 'high water mark', as though submacular fluid had been present at an earlier time. No subretinal blood, exudates, or fluid could be found as evidence of an active choroidal neovascular membrane.

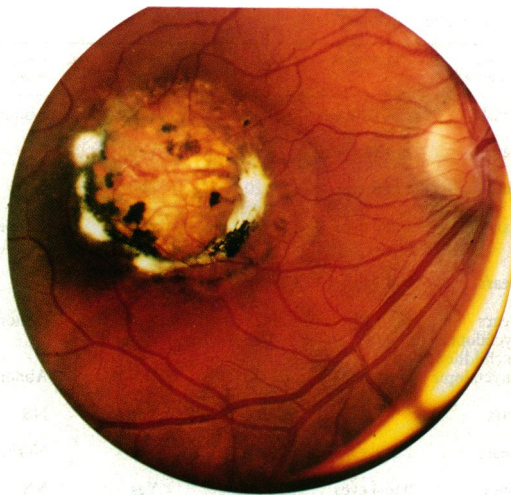

Figure 8A Right macula, grade 3, 29-year old male, 20/30-, V-10.

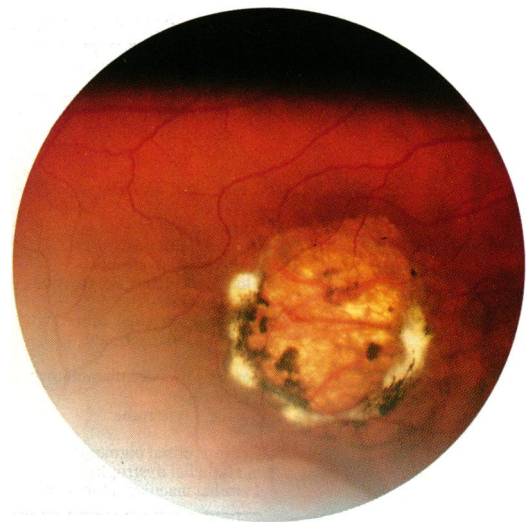

Figure 8B Unchanged at 40 years old.

Our previously reported subject whose disease progressed was 17 years old at the time. From only these two subjects we cannot pinpoint the age at greatest risk for the rare event of disease progression any better than 'early in life'.

The remaining subjects had no objective change in either their visual acuity or the appearance of the macular lesions as judged by comparing the recent and the old fundus photographs. However, subjective change in visual acuity was noted by two subjects who complained of a brief period (1-2 weeks) during which they described a change in the size or shape of a previously noted central scotoma. These perceived changes did not, however, affect their Snellen visual acuity. Particularly noteworthy was that none of the 17 affected subjects experienced a continual progressive downhill course of their vision.

Discussion

Dominant progressive foveal dystrophy of Lefler, Wadsworth, and Sidbury,¹ more recently called North Carolina macular dystrophy (NCMD)^{3,4} (McKusick No 136550),¹⁵ is an autosomal dominant macular dystrophy with complete penetrance and highly variable expressivity. This dystrophy has its onset during infancy or possibly even in utero as shown by a 3-month-old boy who had been previously found

to have the grade 3 macular lesion. Those affected may range from being completely asymptomatic with 20/20 visual acuity to have a central scotoma with 20/200 visual acuity in the worse cases.

From this longitudinal study of 17 affected family members, our report provided further evidence that 'dominant progressive foveal dystrophy' of Lefler, Wadsworth, and Sidbury (NCMD) generally has a stable clinical course and is not progressive as originally described by Frank *et al*.² The results of our present study combined with the results of the 22 affected original NCMD family members we recently reported⁴ revealed a 5% (2 of 37) incidence of affected individuals who experienced progressive macular deterioration in one eye. These two subjects, who experienced further deterioration, had grade 2 disease with a hypertrophic disciform appearance. Despite this, we have been unable to witness an active choroidal neovascular membrane or its sequelae such as subretinal blood or exudates in any of the 37 affected subjects. We suspect that these severe grade 2 lesions are somehow unstable, teetering between a grade 2 and grade 3 lesion. Perhaps this more severe macular dysfunction is caused by transudation of fluid across developmentally compromised retinal pigment epithelium and/or Bruch's membrane. Although age related macular

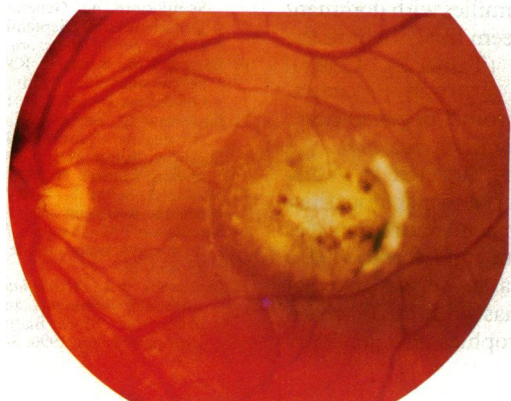


Figure 9A Left macula, grade 3, 20-year-old male at time of photograph, 20/60, VI-2.

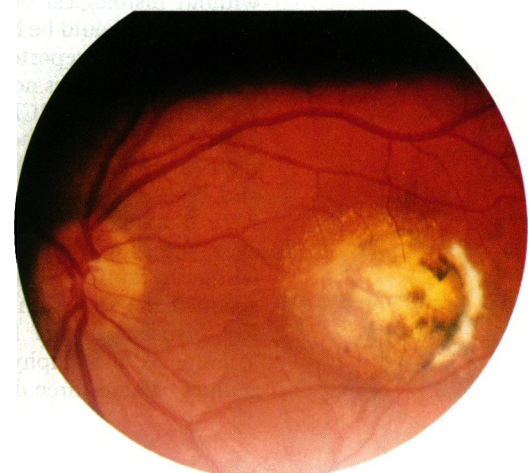


Figure 9B Unchanged at 26 years old.

Table 2 Review of similar dominant macular dystrophies

Disease	Youngest age detected	Progression	VA	Staphyloma macular	Peripheral retina	ERG	Colour vision
North Carolina ¹⁻⁴ macular dystrophy	3 months	2 of 78 eyes	20/20 to 20/20	Yes	Abnormal	Normal	Normal
CAPED ⁵	1 year	2 of 14 eyes	20/20 to 6/200	Yes	NS	Normal	Normal
Dominant CAPED ⁶	7 years	1 of 8 eyes	20/20 to 20/200	Yes?	NS	Normal	Normal
Autosomal dominant central pigment epithelial dystrophy ⁷	6 years	1 of 8 eyes	20/20 to 10/200	NS?	Abnormal	Normal	Normal
Dominant slowly progressive macular dystrophy ¹¹	46 years	5 of 35 eyes	20/20 to 20/200	No	NS	Normal to abnormal	Normal
Dominant macular subretinal neovascularisation ¹⁰	26 years	10 of 10 eyes	20/25 to HM	No	Abnormal	Abnormal	Normal
Sorsby's pseudoinflammatory dystrophy ^{12,13}	20s nyctopia	Uniformly	20/20 to CF	No	Abnormal	Normal to abnormal	Tritan defect
Sorsby's syndrome ¹⁴	7 years	6 of 6 eyes	20/120 to 20/180	Yes	NS	NS	NS
Central retinal pigment epithelial dystrophy ⁸	17 years	2 of 8 eyes	20/16 to 20/200	No	Normal	Normal	Normal to abnormal
Familial macular coloboma ⁹	Infancy	0 to 4 eyes	20/200	Yes	NS	Abnormal	Abnormal

CAPED=central areolar pigment epithelial dystrophy. VA=visual acuity. ERG=electroretinogram. HM=hand motions. CF=counting fingers. NS=not stated in article.

degeneration is a phenocopy of grade 1 and 2 NCMD, we are reluctant to presume that the hypertrophic lesions (Figs 6, 7) were in fact due to a neovascular process.

We propose that the name 'dominant progressive foveal dystrophy'²² is not appropriate. After our genealogical research into the original NCMD family the pedigree now consists of over 1400 individuals who are either affected or who are at risk of having NCMD. Because over 80% of this pedigree consists of Irish descendants living in North Carolina, we suggest that the proper designation for this dystrophy should be 'North Carolina macular dystrophy (NCMD)'. If a patient with this disease is found living in Ireland, then the name should probably be changed to Ireland/North Carolina macular dystrophy. With this name for the disease a patient encountered with a similar dominant macular dystrophy would more likely be questioned for relatives in Ireland or the North Carolina mountains. This additional family history might contribute to making the correct diagnosis.

Other possible names for NCMD are presumptive, such as 'central areolar pigment epithelial dystrophy'.⁵⁻⁷ Equivalent names imply that the primary tissue affected is already known. Although clinically NCMD appears to be an abnormality of the retinal pigment epithelium, without histological or molecular confirmation such names should be held in reserve.

Three⁵⁻⁷ other reported families with dominant macular dystrophies now seem likely to have the same disease as NCMD (Table 2). Central areolar pigment epithelial dystrophy,^{5,6} central pigment epithelial and choroidal degeneration,⁷ and NCMD had many common features. All were dominantly inherited, detected at young ages, and showed highly variable maculopathies within the families. These macular abnormalities spanned the spectrum from mild forms with a few 'drusen' in the fovea to severe macular 'colobomas' and 'staphylomas' with 20/200 visual acuities. These three dystrophies also generally

had a stable clinical course. In central pigment epithelial and choroidal degeneration⁷ the peripheral retina was abnormal, similar to that in NCMD. In the other two dystrophies^{5,6} no mention was made of the appearance of the peripheral retinae. In all three⁵⁻⁷ of these dystrophies the findings on electroretinography, electro-oculography, and dark adaptation and colour vision testing were also normal.

Other dominantly inherited macular dystrophies⁸⁻¹⁴ clinically distinct from NCMD have a later age of onset.¹⁰⁻¹² Abnormal findings in electrophysiological and colour vision tests were also helpful in distinguishing these other dystrophies from NCMD.^{8, 10, 12-14}

- Lefler WH, Wadsworth JAC, Sidbury JB Jr. Hereditary macular degeneration and amino-aciduria. *Am J Ophthalmol* 1971; 71: 224-30.
- Frank HR, Landers MB III, Williams RJ, Sidbury JB. Dominant progressive foveal dystrophy. *Am J Ophthalmol* 1974; 78: 903-16.
- Gass JDM. *Stereoscopic atlas of macular diseases*. 3rd ed. St Louis: Mosby, 1987: 98-9.
- Small KW. North Carolina macular dystrophy, revisited. *Ophthalmology* 1989; 96: 1747-54.
- Hermesen VM, Judisch GF. Central areolar pigment epithelial dystrophy. *Ophthalmologica* 1984; 189: 69-72.
- Fetkenhour CL, Gurney N, Dobbie JG, Chromokos E. Central areolar pigment epithelial dystrophy. *Am J Ophthalmol* 1976; 81: 745-53.
- Leveille AS, Morse PH, Kiernan JP. Autosomal dominant central pigment epithelial and choroidal degeneration. *Ophthalmology* 1982; 89: 1407-13.
- Miller SA, Bresnick G. Familial bilateral macular colobomata. *Br J Ophthalmol* 1978; 62: 261-4.
- Klein R, Bresnick G. An inherited central retinal pigment epithelial dystrophy. In: Cotlier E, Maumenee IH, Berman ER, eds. *Genetic eye diseases: retinitis pigmentosa and other inherited eye disorders*. Proceedings of the International Symposium on Genetics and Ophthalmology held in Jerusalem Israel, September 1981. New York: Liss, 1982: 281-96. *Birth Defects: original article series*: 18 (6).
- Balyeat RM, Kingsley RM. Dominant macular subretinal neovascularization with peripheral retinal degeneration. *Ophthalmology* 1987; 94: 1140-7.
- Singerman LJ, Berkow JW, Patz A. Dominant slowly progressive macular dystrophy. *Am J Ophthalmol* 1977; 83: 680-93.
- Sorsby A, Mason MEJ, Gardner N. A fundus dystrophy with unusual features. *Br J Ophthalmology* 1949; 33: 67-97.
- Hoskin A, Sehmi K, Bird AC. Sorsby's pseudoinflammatory macular dystrophy. *Br J Ophthalmol* 1981; 65: 859-65.
- Thompson EM, Baraitser M. Sorsby syndrome: a report on further generations of the original family. *J Med Genet* 1988; 25: 313-21.
- McKusick VA. *Mendelian Inheritance in man*: Catalogue autosomal dominant, autosomal recessive and X-linked phenotypes. 9th ed. Baltimore and London: Johns Hopkins University Press, 1990: 340.