

## CASE REPORTS

## Orbital xanthogranuloma in adults

Geoffrey E Rose, Bhupendra C Patel, Alec Garner, John E Wright

## Abstract

The onset of periorbital xanthogranuloma in adults is rare and may be accompanied by haematological abnormalities and malignancy. The appearance of the eyelid lesions is virtually diagnostic, producing readily recognisable diffuse, yellow plaques, and affected patients should be investigated and reviewed regularly for systemic disease. Three cases are described, in which periorbital cutaneous plaques were associated with abnormal tissues in the superior part of the orbit; these abnormal tissues caused displacement or restricted movement of the globe or upper eyelid. The possibility that two cases represent a necrobiotic type of xanthogranuloma is presented. Nine years after the onset of xanthogranuloma one patient developed non-Hodgkin's lymphoma. A multiple-drug regimen of systemic chemotherapy, given for lymphoma, caused a marked clinical reduction in the periorbital xanthogranuloma.

Periorbital xanthogranulomas arising in adults are rare and may be associated with the presence,

or subsequent development, of a paraproteinaemia,<sup>1-10</sup> myeloma,<sup>169</sup> or leukaemia.<sup>16</sup> Local or systemic steroids, chemotherapy, radiotherapy, and plasmapheresis have been used to treat these lesions or any underlying haematological abnormality. The response to different modes of therapy are reported as being somewhat variable.

Intraorbital involvement in adult-onset xanthogranuloma has been reported in only a few cases. In this paper we present three cases of adult-onset xanthogranuloma, each with orbital involvement as shown by computed tomography (CT) (two cases) and at anterior orbitotomy. Two had features of necrobiotic xanthogranuloma.

## Case reports and histopathology

## CASE 1

A 22-year-old Greek male developed progressive, painless swelling of both upper eyelids. Biopsy showed idiopathic orbital inflammation. There was some subjective improvement with systemic steroid therapy, though this was discontinued because of the onset of grand mal epilepsy. A year earlier he had developed adult-onset asthma, for which he received inhaled salbutamol and weekly injections of Alavac-S (a desensitising vaccine). There was a past history of mild poliomyelitis at the age of 3 and petit mal at 7 years.

On referral to this hospital at the age of 24 the patient had normal vision and ocular motility. Prominent raised yellow plaques, involving the skin and underlying tissues of both upper eyelids, were present (Fig 1). The masses caused bilateral gravitational ptosis, though levator function was good. There was no relative proptosis, but both eyes were somewhat prominent (Hertel readings: 21 mm either eye). There was no regional

Orbital Clinic, Moorfields Eye Hospital, City Road, London EC1V 2PD  
G E Rose  
B C Patel  
J E Wright

Institute of Ophthalmology, Cayton Street, London EC1V 9AT  
A Garner

Correspondence to:  
Mr G E Rose, FRCS,  
Moorfields Eye Hospital, City Road, London EC1V 2PD.

Accepted for publication  
11 April 1991

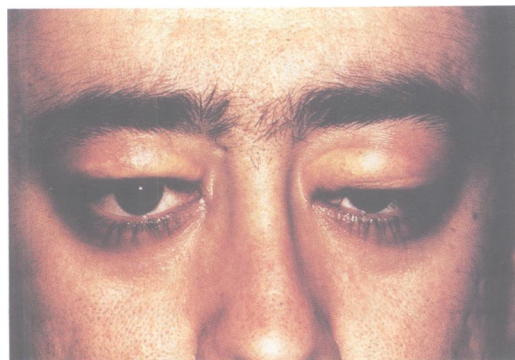

Figure 1 Case 1 at presentation.

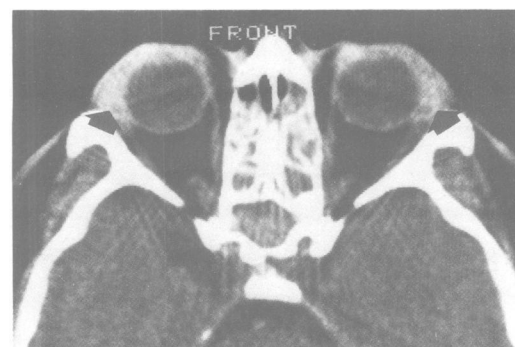


Figure 2A

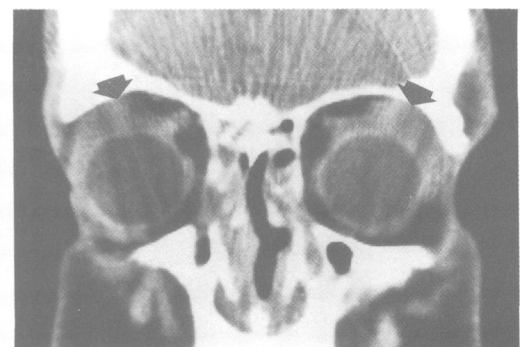


Figure 2B

Figures 2A, B Case 1. Orbital computed tomography, showing soft-tissue masses anteriorly in the upper parts of the affected orbits (arrows).

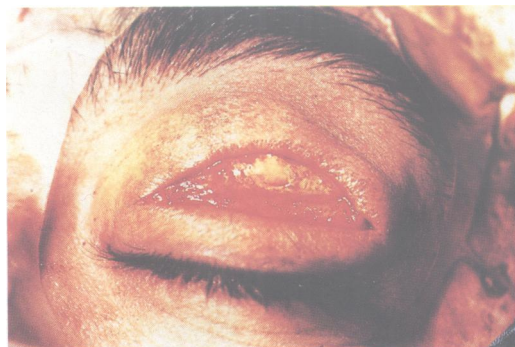

Figure 3  
Case 1. Intraoperative view  
of xanthogranuloma  
involving postseptal orbital  
tissues.

lymphadenopathy, and systemic examination gave normal results.

Orbital CT scans showed a diffuse infiltration of the eyelids and the upper part of each orbit (Figs 2A, B). Chest radiographs showed slight enlargement of the left hilum, not typical of sarcoidosis.

There was a mild eosinophilia ( $0.56 \times 10^9/l$ ) and the erythrocyte sedimentation rate was 43 mm in the first hour (Westergren). With the exception of raised serum globulins (53 g/l; normal range 18–32), the levels of serum electrolytes, hepatic enzymes, and lipids were normal. Plasma protein electrophoresis showed a marked and polyclonal increase of gammaglobulins and a mildly raised  $\alpha$ -2 globulin concentration. Serum IgG concentration was raised (36.4 g/l), IgA slightly low (0.65 g/l), and IgM within normal range (0.62 g/l). Urinary protein concentrations were normal and no Bence-Jones proteins were detected. There were no detectable circulating autoantibodies, and serum concentration of the third component of complement was normal (C3=0.7 g/l). The fourth component was, how-

Figure 4 Case 1. Together  
with large numbers of cells  
with voluminous foamy  
cytoplasm (closed arrow)  
there are scattered  
inflammatory cells and foci  
of necrotic fibrous tissue  
(open arrow). (H-E,  $\times 450$ .)

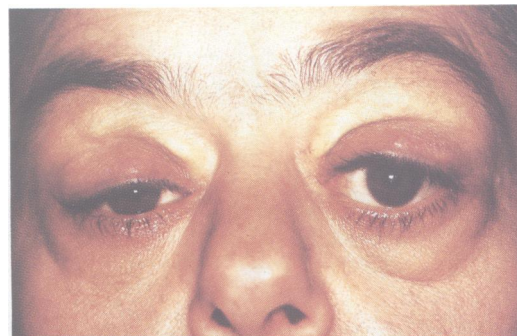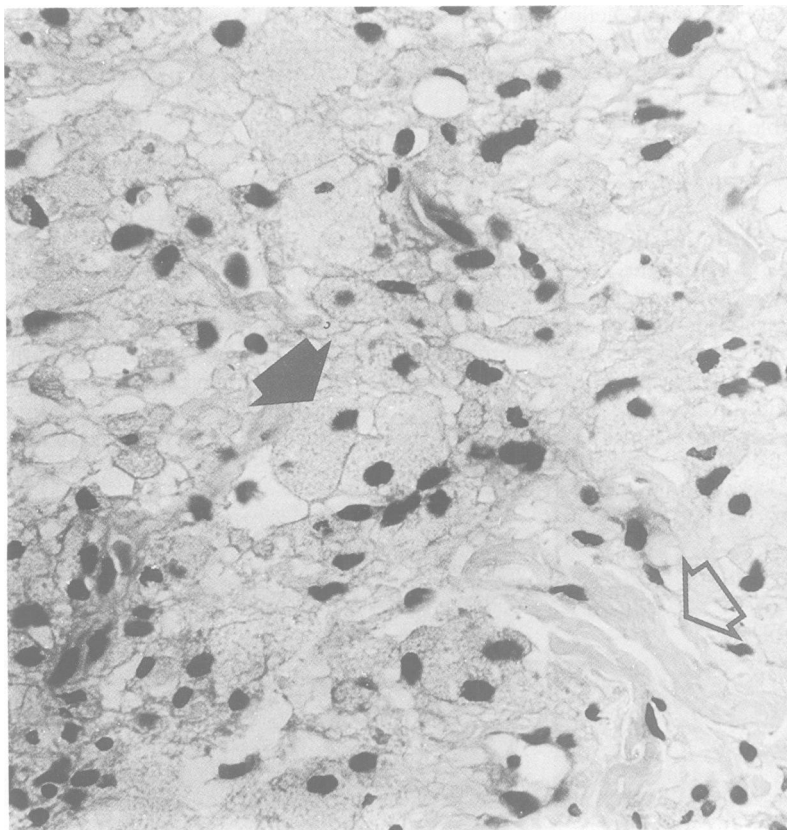


Figure 5 Case 2 at presentation.

ever, slightly reduced (serum C4=80 mg/l), and C-reactive proteins were slightly increased (11.2 mg/l; normal range <10). The *Treponema pallidum* haemagglutination test (TPHA) and venereal disease research laboratory test (VDRL) were negative, and fasting serum triglycerides and cholesterol were within normal limits. The findings on bone marrow biopsy were normal.

At orbital biopsy an abnormal yellow material was present in eyelid skin, subcutaneous tissues, and orbicularis oculi, extending into the orbital fat and connective tissues (Fig 3). The fascia around the lacrimal glands was affected, but there was no involvement of the gland.

#### PATHOLOGY

Histological examination of several biopsy specimens revealed extensive infiltration of eyelid dermis and anterior orbital tissues with histiocytes, many of which had voluminous, foamy cytoplasm (Fig 4). Scattered Touton giant cells were present, especially within the deep tissues, and there was patchy lymphocytic and plasma cell infiltration. The collagenous stroma showed foci of necrosis in the form of hyalinisation, fragmentation, and acellularity. Eosinophils were extremely rare and there were no neutrophils. Immunohistochemical staining reactions disclosed a polyclonal B-cell presence, with both  $\kappa$  and  $\lambda$  light chains being demonstrable, while occasional IgM-forming cells complemented the predominantly IgG-related plasma cells.

#### CASE 2

A 37-year-old Caucasian female developed diffuse swelling and yellow deposits within the skin and deeper tissues of both upper eyelids. At

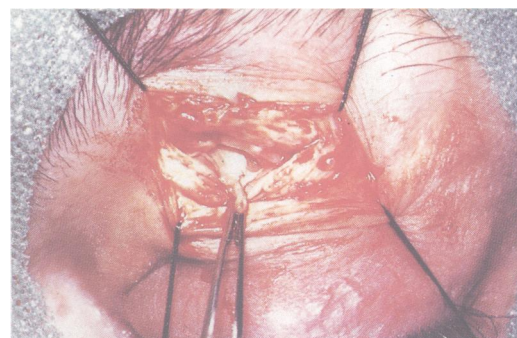


Figure 6 Case 2. Intraoperative view of xanthogranuloma  
involving postseptal orbital tissues.



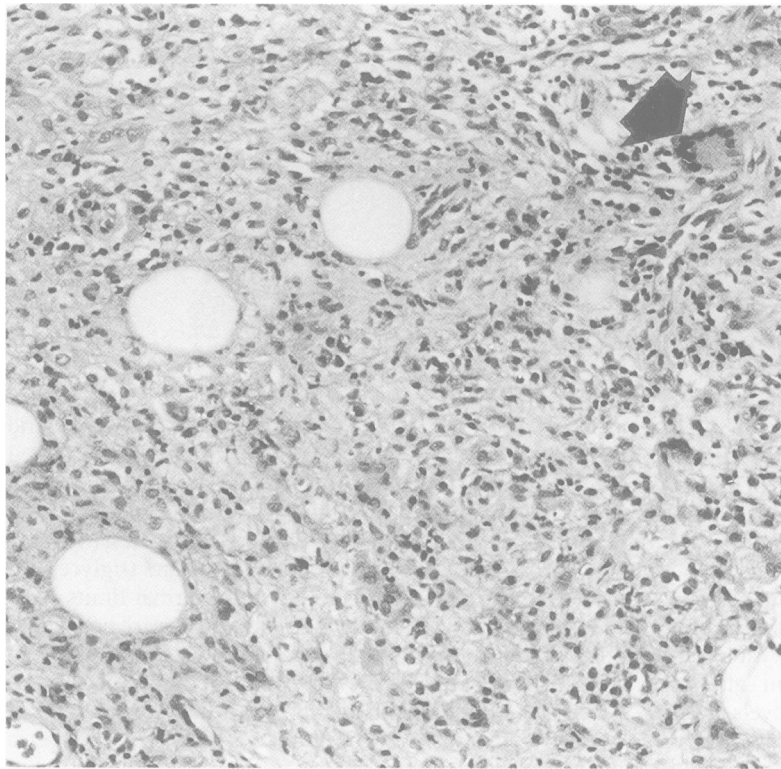


Figure 7 Case 2. The orbital fat is infiltrated and largely replaced by histiocytes and scattered lymphocytes. Occasional giant cells are also present (arrow). (H-E,  $\times 180$ .)

the referring hospital the condition was thought to be 'pseudotumour' (idiopathic orbital inflammatory disease), and she was treated with systemic steroids, without improvement.

On referral, at age 43, she had yellow plaques extending widely over both upper eyelids. There was bilateral ptosis, greater on the right, levator palpebrae superioris function was moderate, and changes in skin creases of the upper lid were suggestive of bilateral disinsertion of the levator muscle aponeurosis (Fig 5).

Orbital biopsy revealed abnormal yellow material in the eyelid skin, in the orbicularis oculi muscles and in the orbital fat and connective tissues (Fig 6). The results of systemic investigation are not available for review.

#### **PATHOLOGY**

Microscopy showed massive infiltration and replacement of orbital fat by histiocytes, with occasional foreign-body and Touton giant cell forms (Fig 7). Intercellular borders were frequently indistinct and many histiocytes had abundant foamy or vacuolated cytoplasm. There was a patchy lymphocytic infiltration, with occasional germinal centres, but plasma cells

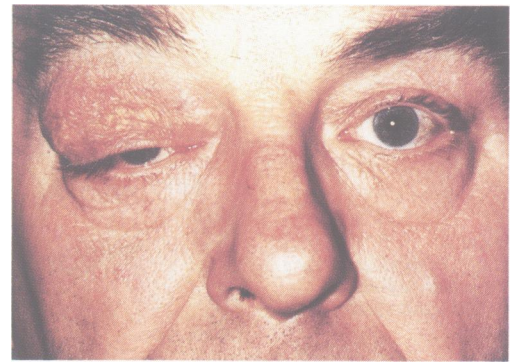


Figure 8 Case 3. Extensive xanthogranuloma of right upper eyelid and orbit, causing 4 mm relative proptosis.

were sparse and eosinophils not observed. Stromal necrosis was not a conspicuous feature.

#### **CASE 3**

The right upper lid of a 50-year-old Caucasian male developed a painless and slowly enlarging yellow lesion over a four-year period. This was thought to be a xanthelasma and was partially resected.

When first seen at this hospital at the age of 56 the right eye was displaced downwards by 2 mm, with 4 mm of relative proptosis. Supraduction and abduction of the right globe was slightly restricted. A large yellow plaque extended widely across the right upper lid, associated with poor function of the levator muscle, 7 mm of relative ptosis, and secondary brow elevation on the affected side (Fig 8). A mass was palpable, and visible through conjunctiva, in the supero-temporal quadrant of the orbit. CT scans showed that it extended widely across the roof of the orbit (Figs 9A, B). Systemic examination, chest x ray, and serum electrolytes and lipids were all normal. The leucocyte count was  $10 \times 10^9/l$ , with a relative lymphocytopenia ( $1 \times 10^9/l$ ) and eosinophilia ( $1.5 \times 10^9/l$ ).

At the age of 58, following transconjunctival biopsy, the patient underwent debulking of the lesion. Abnormal yellow tissue extended throughout upper lid skin, orbicularis oculi, and into the orbital fat and periorbital fascia.

Eighteen months later there was no progression of the eyelid lesion, but the patient developed extensive abdominal non-Hodgkin's lymphoma. The lymphoma was treated with multiple cycles of systemic cyclophosphamide, vincristine, doxorubicin (Adriamycin), prednisolone, and methotrexate. Following systemic

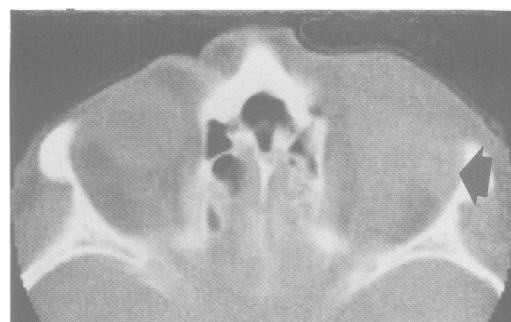

Figure 9A

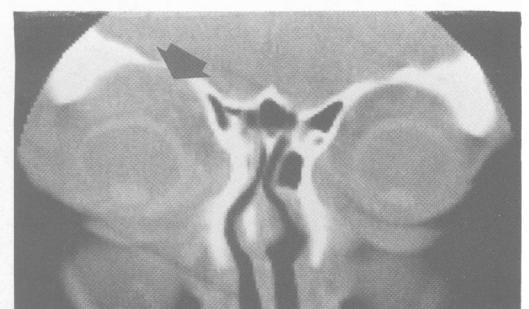
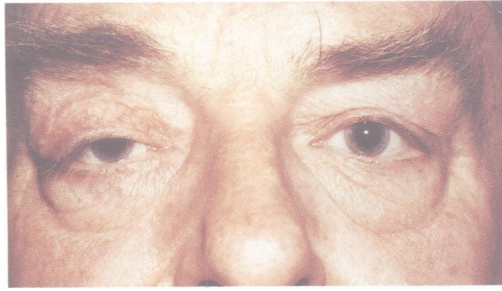


Figure 9B

Figures 9A, B Case 3. Orbital computed tomography, showing soft-tissue masses anteriorly in the upper parts of the affected orbit (arrows).



**Figure 10** Case 3. Resolution of proptosis and marked regression of eyelid lesion after systemic chemotherapy for abdominal non-Hodgkin's lymphoma.



chemotherapy, there was a resolution of the proptosis and a marked reduction of the xanthogranuloma (Fig 10). A minor ptosis persisted and levator muscle function remained very poor.

#### **PATHOLOGY**

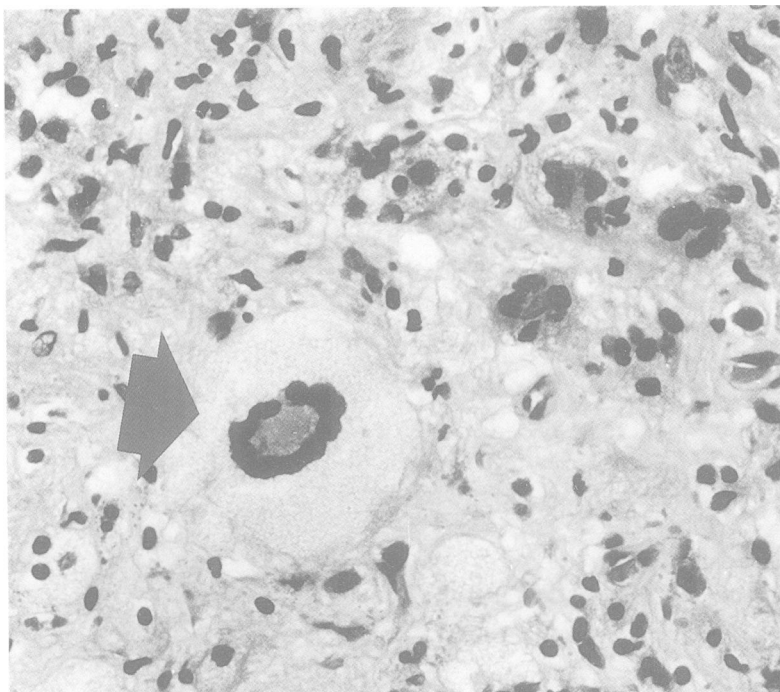
Histology of the excised tissue showed multiple foci of lymphocytic infiltration with occasional germinal centres. Plasma cells, together with considerable numbers of eosinophils, surrounded the centres of lymphoid activity, while the intervening stroma was largely replaced by histiocytes with generally voluminous, foamy cytoplasm (Fig 11). Touton giant cells were a conspicuous finding and there was moderate stromal necrosis (Fig 12).

#### **Discussion**

Xanthogranulomas are granulomas in which the constituent histiocytes are filled with a lipid material. This material imparts a yellow coloration, both clinically for superficial lesions and on gross examination of resected specimens. Touton giant cells are also characteristic, these multinucleate cells having nuclei arranged in a 'wreath' round a nidus of eosinophilic cytoplasm and separated from the cell membrane by a rim of translucent, foamy cytoplasm.

Several histiocytic tumour-like lesions have

**Figure 11** Case 3. Orbital biopsy showed histiocyte infiltration with occasional chronic inflammatory cells and Touton giant cell (arrow). (H-E,  $\times 450$ .)



been described, including the various forms of histiocytosis-X, generalised eruptive histiocytoma, reticulohistiocytoma, and some types of fibrous histiocytoma that may appear xanthomatous. Periocular xanthomatous lesions, with prominent Touton giant cells, form three categories – juvenile xanthogranuloma, necrobiotic xanthogranuloma, and Erdheim-Chester disease.

Juvenile xanthogranuloma presents as multiple skin or intraocular lesions and tends to resolve, either spontaneously or after systemic steroid treatment or radiotherapy.<sup>11-13</sup> Occasionally the lesions may occur in adults,<sup>14</sup> but orbital involvement, which is exceptionally rare, has been reported almost exclusively in children.<sup>11-15</sup>

Adult-onset xanthogranulomas may be associated with extensive systemic disease, involving particularly skeletal, renal, and hepatic tissues, being Erdheim-Chester disease or lipid granulomatosis.<sup>16</sup> Periocular involvement is unusual with Erdheim-Chester disease, though cases with proptosis have been reported.<sup>17-19</sup>

In contrast, periorbital lesions, with a tendency to ulceration, are a predominant feature of necrobiotic xanthogranuloma.<sup>1-10</sup> These lesions display, between the areas of histiocytic accumulation and granuloma formation, a patchy hyaline necrobiosis with collagen destruction.<sup>20</sup>

Haematological abnormalities are common with necrobiotic xanthogranuloma and may include leucopenia, eosinophilia, a raised erythrocyte sedimentation rate, low serum complement, and occasionally a mild hyperlipidaemia.<sup>1-10</sup> Dysproteinaemia is almost universal, often with a monoclonal IgG paraprotein and occasionally with cryoglobulinaemia.<sup>16</sup> Indeed, Bullock and associates<sup>7</sup> suggest that serum immunoglobulins react with tissue lipids, these complexes being deposited in skin and eliciting a giant-cell foreign body reaction. Myeloma or chronic lymphatic leukaemia have also been reported in association with this condition.<sup>16-9</sup>

It is possible that the three cases reported here represent the necrobiotic type of xanthogranuloma, though the evidence is not conclusive. None had the systemic involvement or the widespread cutaneous lesions of Erdheim-Chester disease. Two patients (cases 1 and 3) had leucopenia or lymphocytopenia, eosinophilia, and a raised erythrocyte sedimentation rate. Case 1 also showed a polyclonal increase of serum immunoglobulin G, and, within the biopsies which displayed necrobiotic foci, there was a polyclonal lymphoid infiltration;  $\kappa$  and  $\lambda$  light chains, frequent IgG-forming plasma cells and occasional IgM-forming cells were identified. The third patient (case 3) had multiple areas of necrobiosis in the orbital biopsies and subsequently developed an intra-abdominal non-Hodgkin's lymphoma.

Reported treatment for necrobiotic xanthogranuloma includes local excision, radiotherapy, plasmapheresis, locally injected or systemic steroids, and the use of systemic or topical chemotherapy, such as chlorambucil, nitrogen mustard, cyclophosphamide, or melphalan.<sup>1-10 21</sup> The orbital xanthogranuloma in our case 3 resolved almost completely after potent multiple

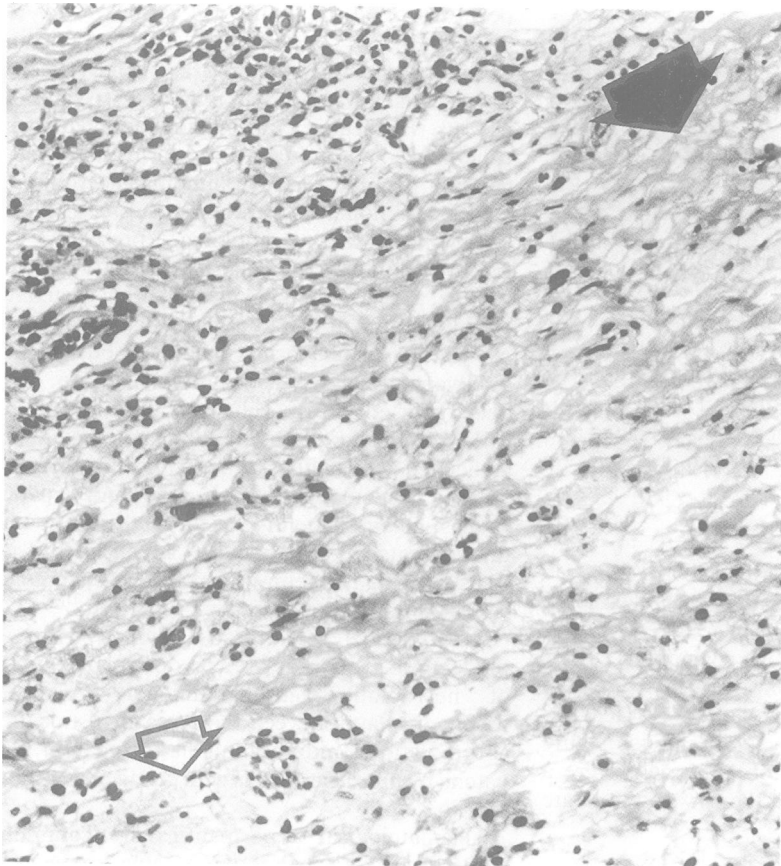


Figure 12 Case 3. Foci of stromal necrosis are seen (closed arrow), along with diffuse lymphocytic infiltration and aggregates of foamy histiocytes (open arrow). (H-E,  $\times 180$ .)

drug chemotherapy (Figs 8, 10), this being in contrast to the rather variable response reported after other types of therapy.

It is imperative that the periorbital plaques of xanthogranuloma are recognised, because they may be part of a widespread systemic disease (Erdheim-Chester disease) or linked to a plasma cell dyscrasia or malignancy (necrobiotic xanthogranuloma). Unlike the thin lesions of periocular xanthelasma, periorbital xanthogranulomas are often thicker, larger, and may extend deeply into orbital tissues. Patients with xanthogranuloma should undergo systemic investigation, and, particularly where biopsy of the

lesions shows hyaline necrobiosis, they should have continued clinical review for the development of plasma protein or other haematological abnormalities.

We thank the surgeons who referred the cases, and the staff of the Department of Medical Illustration, Moorfields Eye Hospital, for the clinical illustrations.

- 1 Kossard S, Winkelmann RK. Necrobiotic xanthogranuloma with paraproteinaemia. *J Am Acad Dermatol* 1980; **3**: 257-60.
- 2 Codere F, Lee RD, Anderson RL. Necrobiotic xanthogranuloma of the eyelid. *Arch Ophthalmol* 1983; **101**: 60-3.
- 3 Robertson DM, Winkelmann RK. Ophthalmic features of necrobiotic xanthogranuloma with paraproteinaemia. *Am J Ophthalmol* 1984; **97**: 173-83.
- 4 MacFarlane AW, Verbov JL. Necrobiotic xanthogranuloma with paraproteinaemia. *Br J Dermatol* 1985; **113**: 339-43.
- 5 Holden CA, Winkelmann RK, Wilson-Jones E. Necrobiotic xanthogranuloma: a report of 4 cases. *Br J Dermatol* 1986; **114**: 241-50.
- 6 Finan MC, Winkelmann RK. Necrobiotic xanthogranuloma with paraproteinaemia. A review of 22 cases. *Medicine* 1986; **65**: 376-88.
- 7 Bullock JD, Bartley GB, Campbell RJ, Yanes B, Conelly PJ, Funkhauser JW. Necrobiotic xanthogranuloma with paraproteinemia. Case report and a pathogenetic theory. *Ophthalmology* 1986; **93**: 1233-6.
- 8 Char DH, LeBoit PE, Ljung B-ME, Wara W. Radiation therapy for ocular necrobiotic xanthogranuloma. *Arch Ophthalmol* 1987; **105**: 174-5.
- 9 Venencie PY, Puissant A, Verola O, *et al.* Necrobiotic xanthogranuloma with myeloma. A case report. *Cancer* 1987; **59**: 588-92.
- 10 Scupham RK, Fretzin DF. Necrobiotic xanthogranuloma with paraproteinaemia. *Arch Pathol Lab Med* 1989; **113**: 1389-90.
- 11 Zimmerman LE. Ocular lesions of juvenile xanthogranuloma: neovoxanthoendothelioma. *Trans Am Acad Ophthalmol Otolaryngol* 1965; **69**: 412-39.
- 12 Gaynes PM, Cohen GS. Juvenile xanthogranuloma of the orbit. *Am J Ophthalmol* 1967; **63**: 755-7.
- 13 Sanders TE. Infantile xanthogranuloma of the orbit: a report of three cases. *Am J Ophthalmol* 1966; **61**: 1299-306.
- 14 Tahan SR, Pastel-Levy C, Bhan AK, Mihm MC Jr. Juvenile xanthogranuloma: clinical and pathological characterisation. *Arch Pathol Lab Med* 1989; **113**: 1057-61.
- 15 Shields CL, Shields JA, Buchanon HW. Solitary orbital involvement with juvenile xanthogranuloma. *Arch Ophthalmol* 1990; **108**: 1587-9.
- 16 Molnar CP, Gottschalk R, Gallagher B. Lipid granulomatosis: Erdheim-Chester disease. *Clin Nucl Med* 1988; **13**: 736-41.
- 17 Palmer FJ, Talley NJ. Erdheim-Chester disease with bilateral exophthalmos and liver cell adenoma. *Australas Radiol* 1984; **28**: 305-10.
- 18 Rozenberg I, Wechsler J, Koenig F, *et al.* Erdheim-Chester disease presenting as malignant exophthalmos. *Br J Radiol* 1986; **59**: 173-7.
- 19 Alper MG, Zimmerman LE, La Piana FG. Orbital manifestations of Erdheim-Chester disease. *Trans Am Ophthalmol Soc* 1983; **81**: 64-85.
- 20 Finan MC, Winkelmann RK. Histopathology of necrobiotic xanthogranuloma with paraproteinaemia. *J Cutan Pathol* 1987; **14**: 92-8.
- 21 Finelli LG, Ratz JL. Plasmapheresis: a treatment modality for necrobiotic xanthogranuloma. *J Am Acad Dermatol* 1987; **17**: 351-4.