

X-linked retinitis pigmentosa

ALAN C. BIRD

Department of Clinical Ophthalmology, Institute of Ophthalmology, University of London

Introduction

FREQUENCY

Nettleship (1908) published a careful analysis of the relative frequencies of male and female involvement in retinitis pigmentosa. Of 1,381 affected individuals which he collected from the previous literature, 61.2 per cent. were male and 38.8 per cent. female. He felt that this preponderance of males was not due to failure of affected females to seek advice, since the same frequency distribution was recorded in families in which the complete sibship was known. Neither was this discrepancy due to an excess of males to females born to families, and Nettleship thought that the preponderance of affected males reflected, in some way, the greater susceptibility of men to suffer disease. This excess of males was seen in all age groups up to the age of 70 years, but above that age the sex distribution was equal. This sex distribution of the disease has been found by several other workers (Bell, 1922; Usher, 1935; Kjerrumgaard, 1948), and recent surveys of blind populations confirm this trend. Sorsby (1966) found that 59.5 per cent. of the population of England and Wales registered as blind or partially sighted because of retinitis pigmentosa and allied disorders were male. The discrepancy was most marked in the third and fourth decades of life at which ages the difference reached the 0.001 level of significance. Fine (1968), in a survey of blind and partially sighted children, found a similar excess of males over females with inherited retinal disease.

Such an excess of males over females suggests that a significant proportion of cases had X-linked disease (Duke-Elder and Dobree, 1967). However, most studies on the relative frequency of different genetic types appear to demonstrate that X-linked disease is rare. Ammann and co-workers estimated that only 1 per cent. of cases had inherited retinitis pigmentosa in an

X-linked manner (Ammann, Klein, and Franceschetti, 1965), and François (1961) reported the frequency to be 4.5 per cent.

Preliminary investigations in London (Jay and Bird, 1973) indicated a much higher frequency of X-linked disease than that found in previous studies, and corresponded well with the figure of 25 per cent. that one might expect from the sex distribution of the disease found by Nettleship (1908). It was the purpose of this study to verify the frequency distribution of this genetic type of retinitis pigmentosa in London.

In order to test X-chromosome linked inheritance, it is essential to identify accurately and completely the distribution of the abnormal gene in the family. This is particularly important in families in which the known pedigree is small. Unfortunately the distribution of this X-linked gene within a family cannot be documented by testing for the blood group Xg since the locus for Xg is not close to that of retinitis pigmentosa (Klein, Franceschetti, Hussels, Race, and Sanger, 1967). Men who are hemizygous for the abnormal gene have severe disease and can be easily recognized by examination and from information of relatives, but it is equally important to be able to recognize women who are heterozygous for the abnormal gene.

PHENOTYPE IN HETEROZYGOUS FEMALES

According to classical mendelian genetic theory, females with a single abnormal X-linked gene should show no phenotypic changes in respect of that gene, if it is recessive to the normal allele. Recently, however, several examples have been described of structural and functional abnormalities in females which can be ascribed to a single abnormal X-linked gene (McKusick, 1962).

Before 1948 few families with X-linked retinitis pigmentosa were described (Seggel, 1884; Gonin, 1902; Nettleship, 1909; Diem, 1914; Bell, 1922; Gasalla, 1931; McQuarrie, 1935; Usher, 1935; Janssen, 1938). The first family to appear in the English literature

was described by Nettleship (1909). Bell (1922) added another affected member to this pedigree and Usher (1935) a further five. In this family, no retinal degeneration was recorded in the heterozygous females to indicate the presence of the abnormal gene, though it was noted that some were myopic. From Usher's pedigree (1935, Fig. 79) it is evident that myopia did not necessarily accompany the gene for retinitis pigmentosa, and was not a sign of the heterozygous state, since one unaffected male (IV/11) was myopic and three heterozygous females were not myopic. However, in a few of the early families, heterozygous females appeared to have pigmentary degeneration in the fundus (McQuarrie, 1935; Janssen, 1938).

There was renewed interest in this condition after the report of Falls and Cotterman (1948), in which a family with twelve heterozygous females was described. All these heterozygotes had a prominent "tapetal reflex", and peripheral pigment epithelial thinning was seen in seven. Profound visual loss in heterozygous women was first recorded by McKenzie (1951). He studied a family in which there was very strong evidence that retinitis pigmentosa had been inherited as an X-linked disease, and yet there were two females who became blind in the ninth decade of life, and two younger women with less severe but symptomatic visual loss. Eight females in this family appeared to have transmitted the gene to their sons without themselves having symptoms of visual loss. McKenzie concluded that the gene was usually recessive in the female, but was of sufficiently high penetrance to cause the disease to appear in a proportion of the females carrying it. He also noted that the disease appeared later and developed more slowly in females than in affected males.

Kobayashi (1960) described a family with even more frequent involvement of the females by the disease. In this family, five heterozygous women had retinitis pigmentosa, eleven had some stigmata of the disease, though in an attenuated form, and at least four were normal. No accurate analysis was made of the comparative severity of the disease in men and women, though he stated that female patients were affected more mildly than males. Kobayashi thought that the gene involved was dominant in character, and distinct from the X-linked gene which usually transmits retinitis pigmentosa.

Equal affection in males and females was found by Heck (1963) in a family with retinitis pigmentosa which he thought was inherited in an X-linked manner. However, conclusive genetic data is lacking, since affected males in the family had only four sons. The disease could equally well have been due to an autosomal dominant gene with reduced penetrance, since presumed heterozygous females had 24 male children of whom only five were affected. The difference between the number of affected and non-affected sons of affected women is statistically highly significant

(probability less than 0.001).

With the growth of genetic counselling, several workers have tried to identify more accurately the nature of the retinal abnormalities in heterozygous women. The need to identify the heterozygous state has been stimulated by the increasing desire of women in these families to know whether or not they were at risk of having affected children.

As early as 1914, Diem reported abnormal fundus reflexes in females heterozygous for X-linked retinitis pigmentosa. In subsequent years, abnormal fundus reflexes were reported in different genetic forms of retinitis pigmentosa and were referred to as "tapetal reflexes" (Mann, 1937).

Falls and Cotterman (1948) found that this abnormal tapetal reflex was the most common expression of the heterozygous state in their family, and others have emphasized the importance of this ophthalmoscopic sign (Weiner and Falls, 1955; Roberts, 1959; François, 1962; Ricci, Ammann, and Franceschetti, 1963; Goodman, Ripps, and Siegel, 1965; Hussels, 1967; Warburg and Simonsen, 1968; Krill, 1969). Ricci and others (1963) reported that this reflex could not be seen after exposure of the fundus to light, and reappeared after a period of darkness. They called this the *phénomène de Mizuo inverse*.

However, Schappert-Kimmijser (1963), in the largest study to date, could identify this abnormal reflex in females of only one family out of eight, and concluded that, while this sign might be useful when present, no conclusions could be drawn when the reflex could not be identified. An attenuated form of the retinal degeneration was a much more common finding in heterozygotes who were frequently asymptomatic. The ocular defects recorded included fundus changes, visual field defects, abnormal final dark adaptation thresholds, and reduction of both electroretinogram potential and light-induced rise in the standing ocular potential. Of the 57 heterozygous females documented, 22 were normal in all respects, eighteen had minor changes without visual loss, fourteen had significant visual defects and obvious ocular changes, and three were approaching blindness.

Hoare (1965) came to the same conclusions 2 years later. Three out of six proven heterozygotes had pigmentary fundus changes, though only one was symptomatic. He noticed no abnormal tapetal reflex in any of the proven heterozygotes, or in twelve daughters of the heterozygotes. (This family is of interest in that a member presented at the Genetic Clinic of Moorfields Eye Hospital, and is included in this study: P392).

More recently Imaizumi, Takahashi, Atsumi, Takahashi, Shoji, Yamada, Imaizumi, and Mita (1970) found a much higher incidence of abnormalities in heterozygous females. They examined six heterozygous females in a single family, and all had mild fundus changes though none had symptoms of visual loss.

During the last 4 years more sophisticated tests of function have been carried out in order to detect mild retinal dysfunction in heterozygous females. Berson and Goldstein (1970) measured the early receptor potential (ERP) in two heterozygotes with only minor peripheral pigmentary changes and slightly elevated final dark adaptation thresholds. In both females the ERP was reduced by 50 per cent. While this may be instructive in localizing the level of the early disease, changes in the ERP have not yet been shown to indicate the presence of the abnormal gene at a time when there were no other detectable structural or functional ocular changes.

Attempts have been made to estimate rhodopsin concentration in the retina of heterozygous females (Bird and Highman, 1972; Highman and Weale, 1973). In one female (Bird and Highman, 1972) this undoubtedly indicated abnormal retinal function when there were minimal fundus changes to indicate that she was heterozygous for the abnormal gene.

It would appear that improved examination techniques in recent years have resulted in the detection of ocular abnormalities in a higher proportion of females who are heterozygous for the X-linked gene for retinitis pigmentosa. In these females pigmentary retinal degeneration tends to be localized until late in life, occurring in the pre-equatorial fundus and corresponding to field defects peripheral to the characteristic ring scotoma seen in retinitis pigmentosa (Berson, Gouras, Gunkel, and Myrianthopoulos, 1969). With only minor changes in the fundus, the implicit time and amplitude of the *a*-wave and *b*-wave of the electroretinogram are normal, suggesting localized rather than generalized retinal dysfunction (Berson, and others, 1969). Pronounced elevation of the final threshold of dark adaptation has rarely been recorded in early disease, and Krill (1967) could detect no evidence of localized deficit of dark adaptation by scanning.

In female heterozygotes, the retinal dystrophy is usually remarkably symmetrical (Warburg, 1971), though gross asymmetry has been described (McKenzie, 1951; Jay and Bird, 1973).

A large part of this study was concerned with documentation of the ocular status of heterozygous women and subsequently, by using this knowledge, to document gene distribution within each family and to prove X-linked inheritance of the disease.

Material

During the period between July, 1969, and August, 1973, 655 patients were referred to the Genetic Clinic at Moorfields Eye Hospital. The patients were referred by colleagues in Moorfields Eye Hospital or from ophthalmologists and family doctors in South-east England. Of these, 107 either had retinitis pigmentosa with a typical history of poor dark adaptation early in the disease followed by

symptoms of field loss, and in severe cases by loss of visual acuity, or had relatives with retinitis pigmentosa.

A diagnosis of autosomal dominant disease was made in 28 families, autosomal recessive in thirteen, and X-linked in 23. In 43 cases the mode of inheritance was uncertain because the family history was not known (for example, the family included adopted children), or no other affected members of the family were known and there was no consanguinity of the parents.

The families of the 23 patients with apparent X-linked retinitis pigmentosa were the subject of this study. In thirteen families the propositus was a male with symptoms of retinitis pigmentosa, and in ten the propositus was a female, presenting late in life with visual loss or in the second or third decade of life wishing to know her chances of having affected children. In eighteen families both males and females were examined. In two families females only were examined. In one of these (P458), retinitis pigmentosa had been diagnosed elsewhere in a male, and in the other there were many males with a typical history of retinitis pigmentosa. In three families, males only were seen, in one of these other males and females had been seen elsewhere (P392), and in the other two there were apparently unaffected females who had transmitted the disease.

A total of 42 affected males and 61 proven, presumed, and possible heterozygous females were examined.

Methods

At the Genetic Clinic the family history of the disease was recorded from information given by the propositus. Further details of the pedigree were obtained at the time of a second visit by the propositus, by postal enquiry of relatives, or by house visits to relatives.

Those relatives of the propositus likely to provide information about the nature of the disease were invited to attend the Genetic Clinic and inquiries continued until a firm generic and genetic diagnosis had been made.

Affected males over the age of 10 years could usually be recognized from the history given by a relative, and could always be recognized after a brief clinical evaluation.

Identification of heterozygous females was much more difficult. Females with affected sons were designated proven heterozygotes, daughters of affected males were designated presumed heterozygotes, and daughters of heterozygous females were designated possible heterozygotes. Ocular function and fundus morphology were recorded as carefully as possible to verify the presence or absence of the abnormal gene, and to determine the phenotypic expression of the heterozygous state.

VISUAL ACUITY

This was measured with appropriate spectacle correction, using a Snellen's test chart at 6 metres.

VISUAL FIELDS

These were recorded using a Goldmann perimeter. All fields were recorded with a 1/4 white kinetic target whenever possible, and larger or dimmer targets were used subsequently as appropriate.

FUNDUS MORPHOLOGY

The fundi were examined with the pupil dilated by direct and indirect ophthalmoscopy, and the following features were recorded:

- Presence or absence of a tapetal reflex;
- Irregularity of the background fundus colour due to pigment epithelial changes;
- Presence or absence of pigment migration into the retina.

In cases in which there was doubt as to normality of the pigment epithelium, fluorescein fundus angiography was performed. 5 ml. 20 per cent sodium fluorescein were injected into the antecubital vein, and photographs were taken at intervals of 1 second during the initial transit, with a Zeiss fundus camera using Ilford FP4 film. A Baird Atomic B4 interference filter with an 80 per cent transmission at 4,800 Å and a broad transmission band of 400 Å was used for excitation, and an Ilford 110 gelatin filter was used as a barrier.

DARK ADAPTATION

This was measured in the Electrodiagnostic Clinic, Moorfields Eye Hospital, using a Goldmann-Weekers dark adaptometer. The test was performed with the pupils dilated. Both eyes were preadapted for 5 min. using two 60-watt bulbs to illuminate the bowl of the adaptometer. One eye was then covered while the threshold of the other was measured with a white circular stimulus which subtended an angle of 11° at fixation, and which flashed once per second in an otherwise darkened room. Testing continued for at least 25 min. until the final threshold had been reached. At this point the threshold of the other eye was measured.

A threshold of 0.5 log units (Goldmann-Weekers chart) was considered normal, and abnormal levels were noted in log units above the normal final threshold.

ELECTRO-OCULOGRAPHY (EOG)

The light-induced rise in ocular potential was measured in the Electrodiagnostic Clinic, Moorfields Eye Hospital, using the technique described by Arden, Barrada, and Kelsey (1962).

Each eye was monitored using silver/silver chloride electrodes over the orbital margin opposite the medial and lateral canthi. The potential changes were recorded by a Medilec MS6 using a low frequency cut-off of 0.8 Hz (equivalent to a time constant of 200 msec.), and a high frequency cut-off of 16 Hz (equivalent to a time constant of 10 msec.). The potential changes were measured during 30° eye movements for 10 sec. in each minute for 12 min. in darkness, and subsequently for 12 min. whilst illuminated by eight 80-watt universal white fluorescent bars at 2 metres.

The light rise was noted as a comparison of the lowest potential in darkness and the highest in light, the second being quoted as a percentage of the first.

After the original survey of Arden and Barrada (1962), it was thought that 185 per cent. was the lower limit of normality, though Kelsey (1969) suggested a less rigid approach. He stated that a light rise greater than 185 per

cent. was normal, between 185 and 150 per cent. was subnormal, and below 150 per cent. was abnormal.

ELECTRORETINOGRAPHY (ERG)

The electroretinograms were recorded in the Electrodiagnostic clinic, Moorfields Eye Hospital. The test was performed with the pupil dilated. The sensing electrode was silver wire in the limbal area of a haptic contact lens which was soaked in a 0.9 per cent. solution of sodium chloride in 1 per cent. methyl cellulose. Reference and indifferent electrodes were silver/silver chloride skin electrodes attached respectively over the lateral orbital margin of the same eye and in the centre of the forehead. The signal was amplified and recorded by a Medilec MS6 which was triggered by the flash, using a high frequency cut-off of 32 Hz (equivalent to a time constant of 5 msec.), and a low frequency cut-off of 0.8 Hz (equivalent to a time constant of 200 msec.). Single sweeps and averages of ten sweeps at 1 Hz were recorded. The stimulus was a xenon flash of 0.22 joules output with a peak illumination lasting 4 µsec. and an exponential decay of 25 µsec., which was placed 30 cm in front of the eyes. The ERG was recorded in light conditions, and then after 5 min. and 10 min. in darkness. Only the 10-minute record was used in this study.

The amplitudes of the *a*-waves were measured. Kelsey (1969) thought that the great variability of the *a*-wave potential precluded the determination of a lower limit of normal. He thought that a *b*-wave of less than 150 µvolts was probably abnormal and that a *b*-wave of less than 100 µvolts was certainly abnormal. These criteria were used in this study.

As the study progressed, it became evident that ocular dysfunction would not be detected by ERG if other tests were normal. Since this examination caused more discomfort than other tests it was not performed on all patients.

RETINAL RHODOPSIN CONCENTRATION ESTIMATION

This was performed by Dr. V. Highman and Prof. R. A. Weale in the Department of Visual Sciences, Institute of Ophthalmology, London; the technique used has been fully described (Highman and Weale, 1973).

After 30 min. dark adaptation, a strip of retina 18° from the fovea was bleached for 10 sec. using a xenon lamp. Immediately after the bleaching, the optogram was photographed through blue-green filters (Ilford 302 and 102). Retinal rhodopsin concentration was estimated by measuring the double density difference between bleached and non-bleached retina as recorded on the photograph.

Results

The pedigrees of the families studied are shown in Fig. 1, and examples of the fundus changes and visual fields of heterozygotes from P22 and P396 are illustrated in Figs 2 and 3 (all overleaf).

Ocular disease in hemizygotes and heterozygotes

Hemizygous males had visual loss of early onset. Symptoms due to loss of dark adaptation occurred

within the first decade of life, reduction of visual field was noticed in the second decade, and loss of visual acuity by 20 years. Severe visual incapacity was almost universal by the age of 40 years. One male (P596/IV/12) was a unique exception in this series and yet his disease was much worse than that of his female relatives.

All males had typical retinitis pigmentosa with pigment epithelial atrophy, migration of pigment-laden cells into the retina, optic atrophy, and narrowed retinal blood vessels. Atrophy of the choriocapillaris occurred late in the evolution of the disease at a time when the patient was blind or nearly blind.

Of the 61 females seen, nineteen were proven heterozygotes and fifteen presumed heterozygotes, and all of them had evidence of fundus disease.

Of 23 possible heterozygotes, fourteen had evidence of fundus disease and nine were normal. Of the fourteen with fundus changes, three presented with symptoms related to retinal degeneration.

One female seen was the daughter of a possible heterozygote who was not examined and she was normal.

The remaining three were daughters of possible heterozygotes in whom no abnormality had been shown and these three were also normal.

Results of a detailed analysis of fundus morphology and ocular function in the 48 heterozygotes are shown in Table I and a summary is shown in Table II.

In mildly-affected subjects, fundus changes were restricted to the peripheral fundus, and consisted of irregularity of pigmentation in the pigment epithelium in restricted segments with or without associated migration of pigment-laden cells into the retina (Figs 2*b*, 3*d*). In the least severe cases the changes were restricted to the pre-equatorial fundus. Fluorescein angiography proved helpful in confirming loss of pigment of the pigment epithelium in affected areas (Figs 2*c*, 2*f*, 3*e*, 3*f*). In more severe cases widespread abnormalities were seen, which in some were restricted to a single sector or hemisphere (Fig. 2*e*). Profound and localized atrophy of the choroid was seen in the peripheral fundus in some advanced cases (Fig. 3*b*). A prominent fundus reflex was seen in several young heterozygotes but was indistinguishable from the normal fundus reflex of the young. In only one case (P633/IV/13) was a prominent reflex seen in an older heterozygote which was undoubtedly abnormal. In one family (P336) glistening white reflexes were seen in the midperipheral fundus of some heterozygotes (IV/3, V/1, and V/7), but this change was not seen in all heterozygotes in this family. Though the most severe disease was seen in older women, two of five in the second decade of life and two of nine in the third decade of life had more extensive changes than simple peripheral pigment epithelial atrophy.

Field loss was found in 35 of 36 heterozygotes tested. The visual loss corresponded to the visible fundus abnormalities, and consisted most commonly of irregu-

lar peripheral loss (Figs 2*a*, 3*c*), with mid-zone loss, sectoral loss (Fig. 2*d*), and severe restriction (Fig. 3*a*) in the more severe cases. The most severe loss was seen in older women, though two heterozygotes in the second, and two in the third decades of life, had more than peripheral loss.

Dark adaptation was abnormal in 32 out of 37 heterozygotes tested. Normal dark adaptation was not restricted to the young, since normal final thresholds were found in one of four in the fourth decade of life and two of eight in the fifth decade.

The EOG was less helpful, since fifteen of 42 tested had a normal light-induced rise in potential even in cases in whom fundus abnormalities, field loss, and loss of dark adaptation had been recognized.

In no case did depression of the *b*-wave potentials alone indicate abnormal ocular function. All eleven with depression of the ERG had easily recognizable fundus changes, field loss, and abnormal dark adaptation.

Fundus examination, visual field testing, and rise in the final threshold of dark adaptation were found to be most common indices of involvement by the disease, whereas electro-oculography and electroretinography were relatively less helpful.

While the disease was more severe with increasing age, great variability of severity was recorded from one heterozygote to another at similar ages. No obvious association such as refractive error or iris colour was noted with severe disease, which was present in heterozygotes in all large families and all had mildly affected heterozygous relatives.

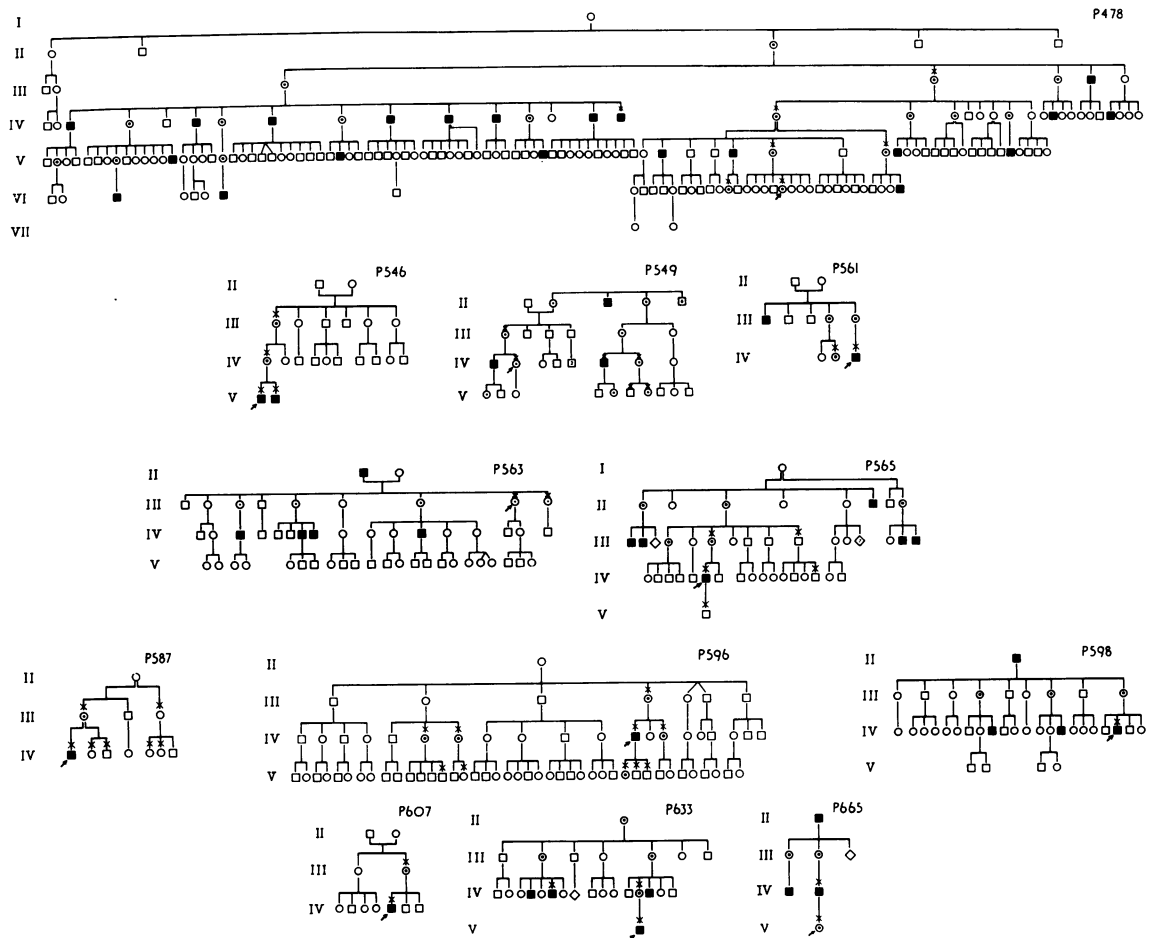
The severity and pattern of disease was remarkably symmetrical in all heterozygotes except one (P563/III/9), who had severe disease in both eyes but loss of central retinal function in one eye only. Two heterozygotes (P439/V/3; P396/V/7) appeared to have retinal degenerative changes in one eye only, and those were very mild.

Retinal rhodopsin concentration was estimated and the following results were obtained:

P336/IV/3: 66 per cent. below normal levels;
 P336/V/1: 50 per cent. below normal levels;
 P336/V/2: 50 per cent. below normal levels;
 P396/V/7: 40 per cent. below normal levels;
 P478/V/69: 60 per cent. below normal levels;
 P478/VI/25: 60 per cent. below normal levels;
 P546/IV/1: 90 per cent. below normal levels.

A chromosome count was performed by Prof. P. E. Polani at Guy's Hospital on P336/V/4 and a normal complement of chromosomes was found.

A comparative analysis was made of ocular involvement by the disease in heterozygotes and hemizygotes using visual acuity as an index of involvement. Reduced acuity indicates a distinct stage of the disease at which the cones become affected in sufficient numbers to depress form vision. The results (Fig. 4) demon-



strate the rapid loss of visual acuity during the third and fourth decades of life in hemizygotes. By contrast, only a few heterozygotes lost visual acuity and then only in late life. Of the 48 female heterozygotes seen, only three had vision worse than 6/9 in both eyes, and they were all over 50 years of age.

Gene transmission

The results of an analysis of the inheritance are shown in Table III.

(i) Affected males had 66 male children, none of whom inherited the disease.

(ii) 44 female children of affected males, either had male descendants or were examined. There was evidence that 41 of these 44 female children had inherited the abnormal gene, either because they had affected

male offspring or because they were examined and found to have ocular abnormalities. The remaining three have not been examined and have unaffected male descendants.

(iii) Of 181 male children of heterozygous females who had reached the age of 10 years, 94 were affected and 87 appeared to be normal.

(iv) 99 daughters of heterozygous females either had male descendants, or were examined, or both. There was evidence that 55 of these 99 female children were heterozygotes, either because they produced affected male offspring, or because they had been examined and found to have ocular abnormalities. In 44 female children no such evidence was found. The difference between the number of affected daughters of heterozygous females is not statistically significant (probability greater than 0.3).

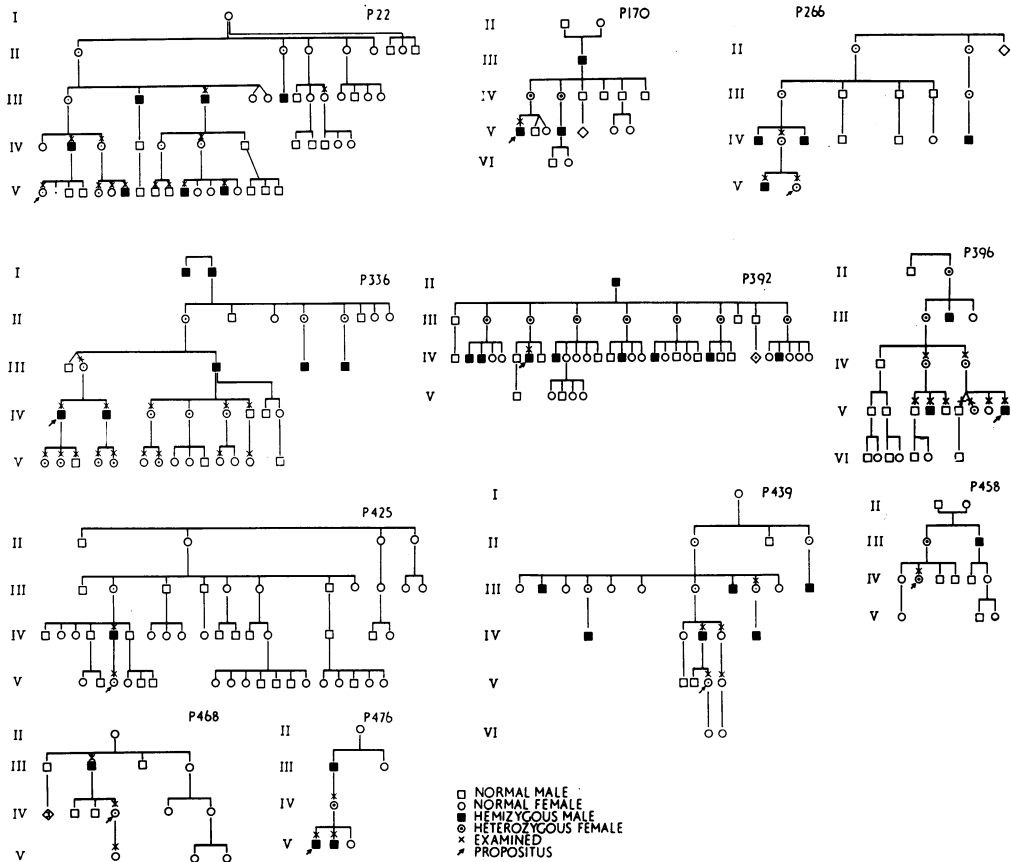


FIG. 1 Pedigrees of families with X-chromosome linked retinitis pigmentosa (see key)

Discussion

EVIDENCE OF X-LINKED TRANSMISSION

In a condition transmitted as a presumed X-linked trait, where heterozygous females demonstrate some abnormality, the confirmation of X-linked inheritance depends upon an analysis of the offspring of hemizygous (affected) males.

In this series, affected males had 66 male children, none of whom inherited the disease. The absence of father-to-son transmission is statistically highly significant and is characteristic of X-linked inheritance. 44 daughters of affected males either had male descendants or were themselves examined. Of these, 41 were either examined and found to have retinal abnormalities or were known to have produced affected male offspring. The remaining three have not been examined and have so far had no affected sons; of the three, one had only one son (P336/IV/4) and one had

one son, one daughter, and no grandsons (P563/III/2). Therefore all daughters of affected males, for whom sufficient data are available, inherited the abnormal gene. This is also statistically highly significant evidence of X-linked disease.

Recognition of heterozygous females allows further analysis of the gene distribution within the families, and also permits the transmission of the disease to be characterized. An analysis of the descendants of heterozygous (mildly affected) females is shown in Table III.

Heterozygous females had 179 sons over the age of 10 years, of whom 92 were affected and 87 were apparently normal. The difference between numbers of affected and non-affected sons is not statistically significant (probability greater than 0.8).

99 daughters of heterozygous females either had male descendants or were themselves examined. There was evidence that 55 of these 99 female children were heterozygous either because they had produced affec-

Table I *Ocular function in heterozygous females*

Pedigree no.	Subject	Age (yrs)	Visual acuity		Visual fields		Fundus		Dark adaptation		EOG		ERG	
			R	L	R	L	R	L	R	L	R	L	R	L
22	V/1	22	6/6	6/6			+	+	1	$\frac{1}{2}$	-	-	-	-
	V/5	24	6/6	6/6			+	+	1	$\frac{1}{2}$	-	-	-	-
	IV/6	41	6/6	6/6	++	++	++	++	$\frac{3}{4}$	$\frac{3}{4}$	++	+++	+	+
	IV/3	52	6/6	6/6	+	+	+	+	$\frac{1}{4}$	$\frac{1}{4}$	+	+	-	-
266	V/2	10	6/6	6/6			+	+	1	1	++	+	+	+
	IV/2	47	6/6	6/6	++	++	++	++	2	$1\frac{1}{2}$	++	++	+	+
336	V/7	12	6/6	6/6			+	+	-	-	-	-		
	V/2	13	6/6	6/6	++	++	++	++	$\frac{1}{4}$	-	++	+	-	-
	V/1	18	6/6	6/6	+	+	+	+	$\frac{1}{2}$	$\frac{1}{4}$	+	+	-	-
	V/5	18	6/6	6/6	++	++	++	++	$\frac{1}{4}$	$\frac{1}{4}$	++	+	+	+
	V/4	22	6/6	6/6	++	++	++	++	1	1	+++	+++	+	+
	IV/5	39	6/6	6/6	+	+	+	+	$\frac{1}{2}$	$\frac{1}{2}$	-	-		
	IV/3	42	6/6	6/6	+	+	+	+	1	1	-	-	+	-
	III/2	68	6/6	6/6	++	++	++	++						
396	V/7	28	6/6	6/6	-	-	+	-	$\frac{1}{2}$	-	-	-	-	-
	IV/3	56	6/6	6/6	+	+	+	+	1	$\frac{1}{2}$	-	-	+	-
	IV/2	60	6/18	6/18	++	++	++	++	1	1	+++	++	+++	+
425	V/3	25	6/6	6/6	++	++	++	++	1	1	+++	+++	+	+
439	V/3	21	6/6		+	-	+	-	$\frac{1}{2}$	-	-	-	-	-
458	IV/2	43	6/5	6/5	+	+	+	+	-	-	+	+	-	-
468	IV/6	46	6/9	6/9	++	++	++	++	2	2	+++	+++	+	+
476	IV/1	52	6/6	6/6	+	+	+	+			+	-		
478	VI/25	8	6/9	6/9			+	+			-	-		
	VI/19	9	6/6	6/9	+	+	+	+			+	+		
	V/71	27	6/6	6/6	+	+	+	+	$\frac{1}{2}$	$\frac{1}{2}$	-	-		
	V/69	34	6/9	6/9	+	+	+	+	$\frac{1}{2}$	$\frac{1}{2}$	+	++		
	IV/17	66	6/60	6/60	++	++	+++	+++	$2\frac{1}{2}$	$2\frac{1}{2}$	++	++		
	III/4	86	NPL	HM	+++	+++	+++	+++						
540	III/1	60	6/9	6/9			+	+						
546	IV/1	37	6/9	6/9	+	+	+	+	1	1	-	-		
	III/1	66	6/9	6/9			+	+						
549	V/7	7	6/6	6/6			+	+			+	+		
	IV/8	26	6/5	6/5	+	+	+	+	$\frac{1}{3}$	$\frac{1}{3}$	+	+		
	IV/2	33	6/6	6/6	+	+	+	+	$\frac{1}{3}$	$\frac{1}{3}$	+	+		
	III/1	57	6/9	6/9			+	+						
561	IV/2	34	6/4	6/4			+	+			-	-		
563	III/9	58	HM	6/9	+++	+++	+++	+++		$\frac{1}{3}$	+++	+++		
	III/8	61	6/9	6/9	++	++	++	++	$\frac{1}{3}$	$\frac{1}{2}$	+++	+++		
565	III/6	54	6/9		++	++	++	++	$\frac{1}{2}$	$\frac{1}{2}$	++	++	-	-
587	III/1	43	6/6	6/6	+	+	+	+	$\frac{1}{2}$	$\frac{1}{2}$	++	++		

Table I (contd.)

Pedigree no.	Subject	Age (yrs)	Visual acuity		Visual fields		Fundi		Dark adaptation		EOG		ERG	
			R	L	R	L	R	L	R	L	R	L	R	L
596	V/31	7	6/6	6/6			+	+	-	-	-	-		
	IV/14	33	6/6	6/6	+	+	+	+	½	½	+++	+++	-	-
	IV/7	39	6/5	6/5	+	+	+	+	-	-	-	-		
	IV/6	44	6/5	6/5	+	+	+	+	-	-	-	-		
	III/4	69	6/6	6/6	+	+	+	+	1	1	++	++	-	-
607	III/2	23	6/6	6/6	+	+	+	+	½	½	+	+		
633	IV/13	49	6/5	6/5	+	+	+	+	½	½	-	+		
665	V/1	15	6/5	6/5	+	+	+	+	½	½	+	-		

Visual acuity	Snellen types Hand movements No perception of light	6/4 to 6/60 HM NPL
Visual fields	Normal Peripheral loss only Confluent mid-zone loss Severe mid-zone and peripheral loss	- + ++ +++
Fundi	Normal Peripheral changes Peripheral and mid-zone changes Advanced retinitis pigmentosa	- + ++ +++
Dark adaptation	Normal Abnormal	- log units above normal final threshold
EOG	Normal 180 to 150 per cent light-induced rise in potential 150 to 130 per cent light-induced rise in potential Less than 130 per cent light-induced rise in potential	- + ++ +++
ERG	Normal potentials Subnormal potentials Non-recordable potentials	- + +++

Table II Ocular function in heterozygous females (Ratio of abnormal to total)

Age range (yrs)	Fundi	Visual fields	Dark adaptation	EOG	ERG
1-10	5:5	1:1	1:2	3:5	1:1
11-20	5:5	4:4	4:5	4:5	1:3
21-30	9:9	6:7	9:9	4:9	2:7
31-40	9:9	6:6	5:6	3:7	
41-50	8:8	8:8	6:8	6:8	4:5
51-60	6:6	5:5	4:4	4:5	2:4
61+	6:6	5:5	3:3	3:3	1:1
All ages	48:48	35:36	32:37	27:42	11:21

Table III Analysis of gene transmission

Descendants	Of hemizygotes		Of heterozygotes		
	Male	Female	Male	Female	
Evidence of abnormal gene inheritance	Present	0	41	94	55
	Absent	66	3*	87	44
Total		66	44	181	99

* But not examined

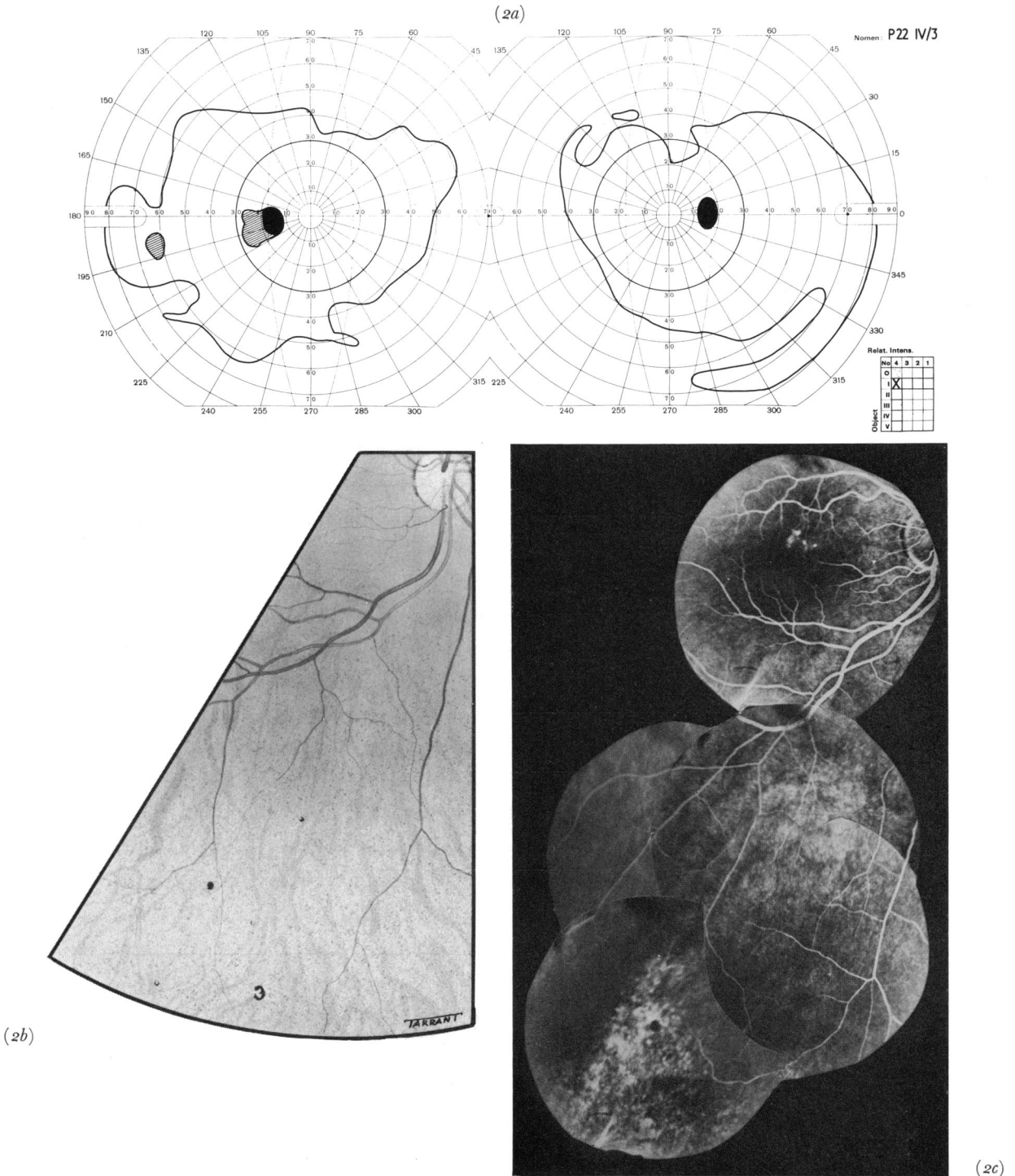
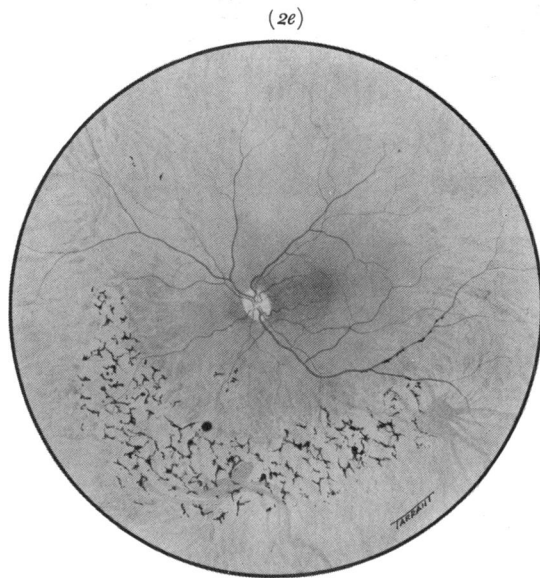
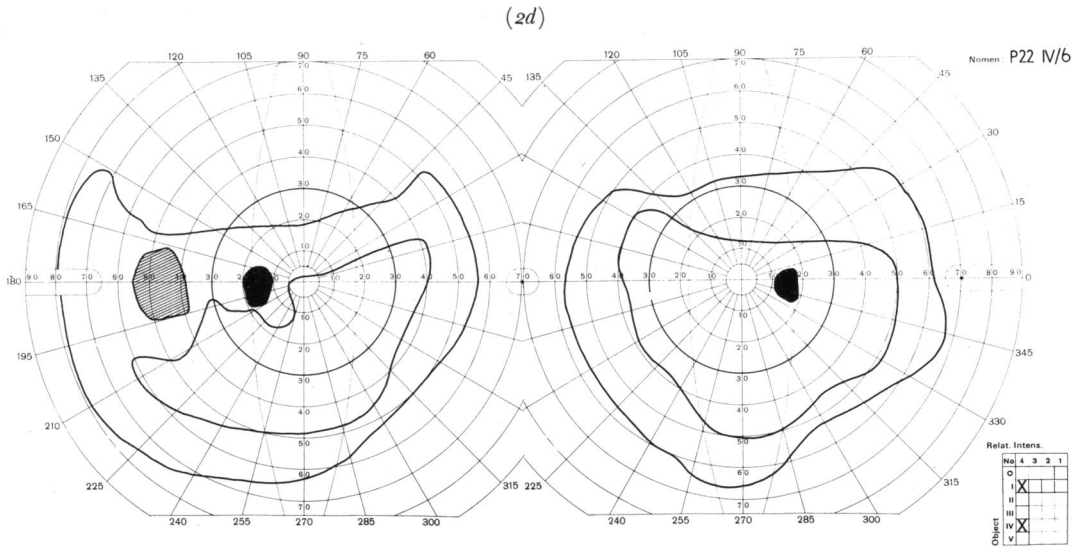


FIG. 2 *Visual fields and fundus appearances of two heterozygous females in Pedigree 22 IV/3* A 52-year-old female with an affected son (V/7). She had no symptoms and a visual acuity of 6/6 in each eye. Visual fields showed peripheral loss (2a). The fundus showed peripheral pigment disturbance with migration of pigment-containing cells into the retina (2b). This was confirmed by fluorescein fundus angiography (2c)
 Figs 2(b) and (c) reproduced by courtesy of the editor of *Trans. Amer. Acad. Ophthalm. Otolaryng.* (1973) **77**, p. OP 644, figs 3 and 4



IV/6 A 41-year-old female with two affected sons (V, 11 and 14). She had no symptoms and a visual acuity of 6/6 in each eye. Visual fields showed upper half loss (2d). The fundus showed retinitis pigmentosa in the lower half (2e). This was confirmed by fluorescein fundus angiography (2f, overleaf)

Figs 2(d), (e), and (f) reproduced by courtesy of the editor of *Trans. Amer. Acad. Ophthalm. Otolaryng.* (1973) 77, pp. OP 644 and 645, figs 5, 6, and 7

ted male offspring or because they had been examined and found to have retinal abnormalities. In the other 44 daughters no such evidence was found. The difference between the numbers inheriting and not inheriting the gene is not statistically significant (probability greater than 0.3). It would appear that half the daughters and half the sons of heterozygous females inherited the abnormal gene. This is characteristic of X-chromosome linked inheritance although on its own it does not exclude all other forms of inheritance.

On the evidence of the different affection of males and females with the abnormal gene, and of the inheritance characteristics of the disease, there is little doubt that the families in this study have X-chromosome linked disease.

RELATIVE FREQUENCY OF X-LINKED TRANSMISSION

The 23 families with X-linked retinitis pigmentosa represent 21.5 per cent. of the total number of families with retinitis pigmentosa referred to the Genetic Clinic at Moorfields Eye Hospital during a period of 3½ years. This greatly exceeds the frequency of this type of retinitis pigmentosa recorded in previous studies (4.5 per cent. François, 1961; 1 per cent. Ammann and others, 1965).

There are several possible explanations for this high incidence of X-linked retinitis pigmentosa. There is no evidence to suggest that families with this condition were preferentially referred to the Genetic Clinic because of the interest generated by their supposed rarity.

(2f)

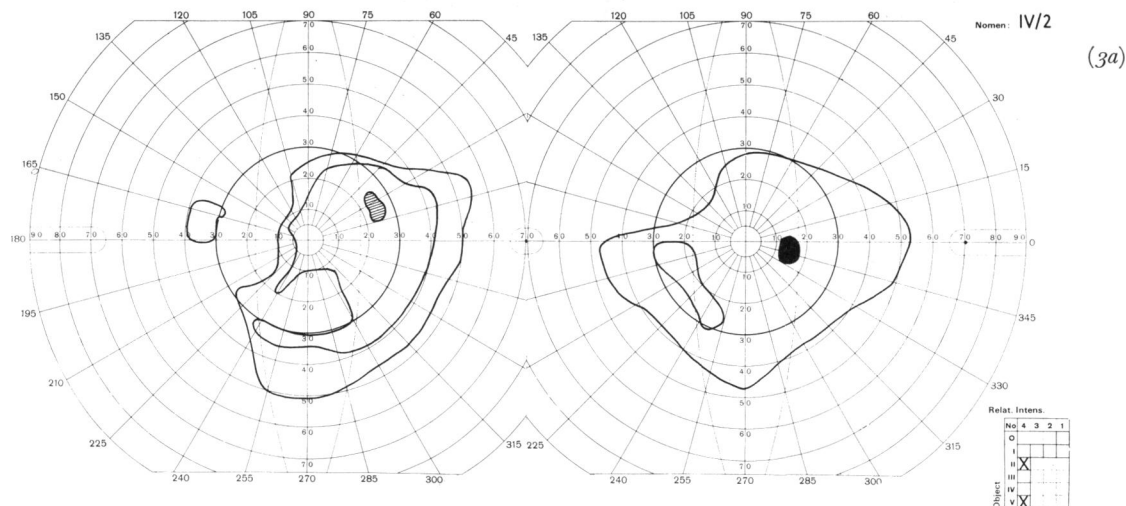
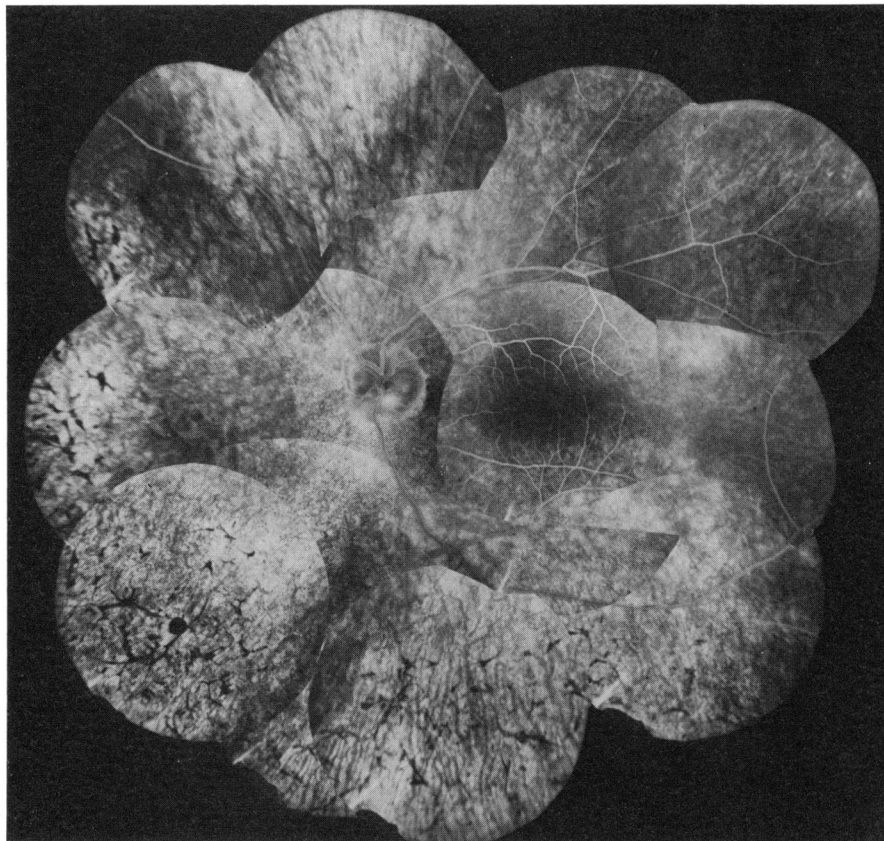
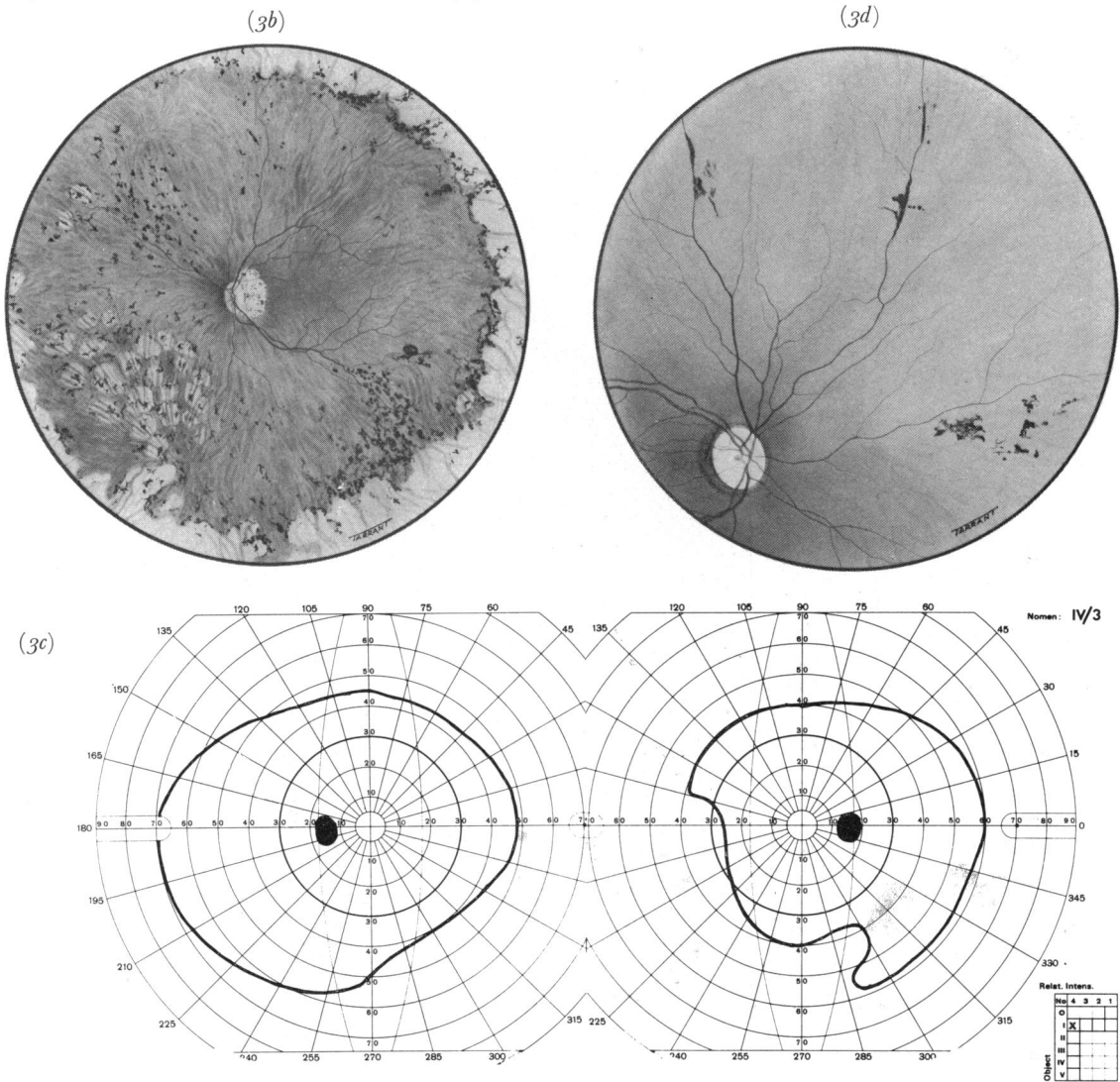


FIG. 3 *Visual fields and fundus appearances of three heterozygous females in Pedigree 396*
IV/2 A 60-year-old female with an affected son (V, 4). She had noticed loss of dark adaptation for 5 years, visual field changes for 3 years, and reduced visual acuity for 1 year. The visual acuity was 6/18 in each eye. The visual fields were severely restricted (3a). Both fundi showed retinitis pigmentosa with severe choroidal atrophy in restricted patches at the periphery (3b)

Figs 3a and b reproduced by courtesy of the editor of *Trans. Amer. Acad. Ophthalm. Otolaryng.* (1973) **77**, pp. OP 648, figs 12 and 13

IV/3 A 56-year-old female with an affected son (V, 9). She had no symptoms and a visual acuity of 6/6 in each eye. The visual fields showed peripheral loss (3c). There was segmental retinitis pigmentosa (3d). This was confirmed by fluorescein fundus angiography (3e, overleaf)

Figs 3(c), (d), and (e) reproduced by courtesy of the editor of *Trans. Amer. Acad. Ophthalm. Otolaryng.* (1973) **77**, p. OP 646, fig. 9, and p. OP 647 figs, 10 and 11

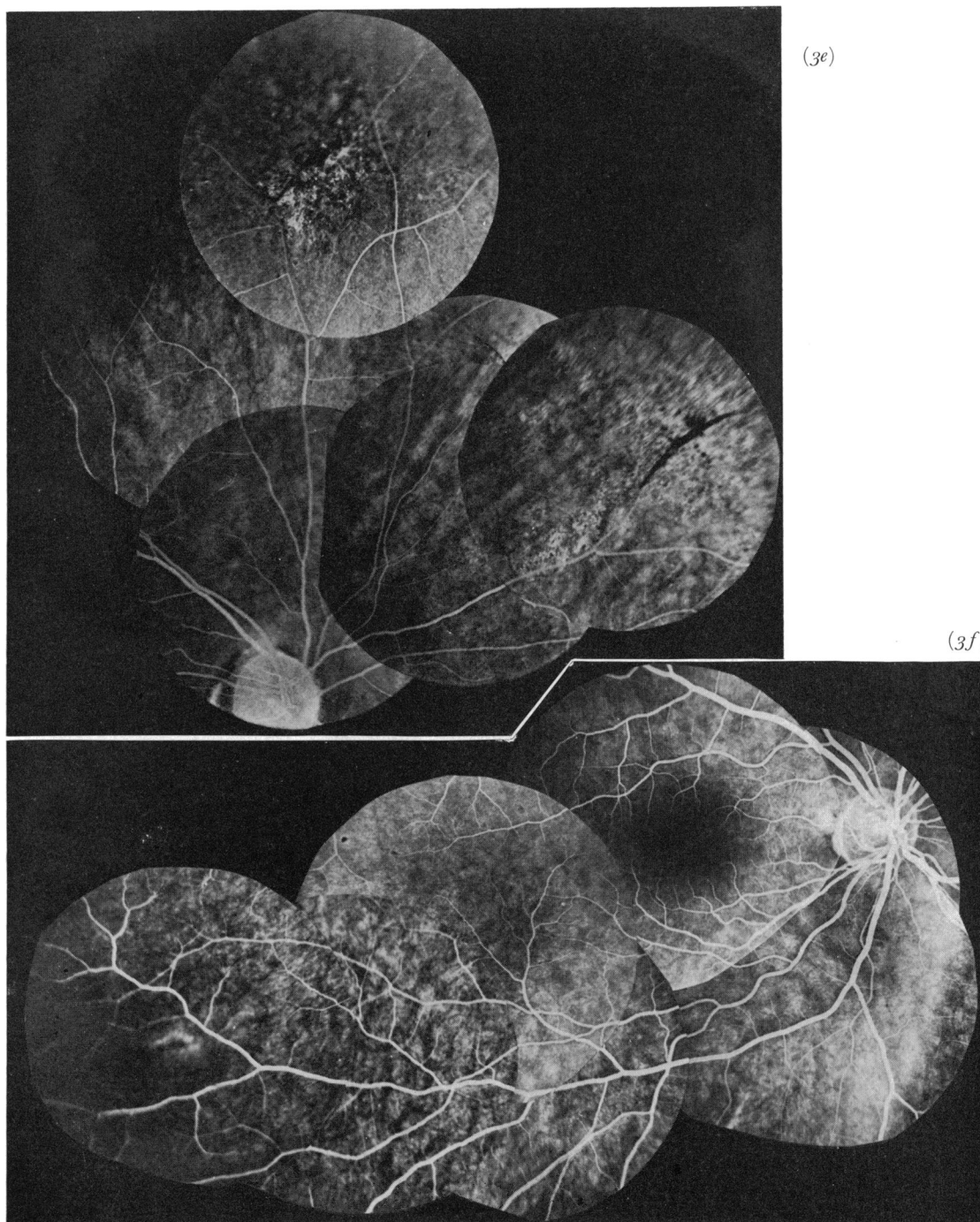


At the time when most families were referred, the mode of inheritance had not been identified or had been identified wrongly. It is easy to envisage how a pedigree can be wrongly interpreted. Fig. 5a shows part of P478 with heterozygotes and hemizygotes identified. If the females are shown as affected (Fig. 5b), as indeed they are in old age, the inheritance appears to be autosomal dominant. If the females are shown as unaffected (Fig. 5c), as they may appear to be if not examined or if they die in early or middle life, the inheritance appears to be autosomal recessive. Failure to interpret the pedigree correctly may well account to some extent for the low frequency of X-linked disease reported in previous studies.

Families with X-linked disease may have been preferentially referred to the Genetic Clinic because of the severity of the disease, though this seems unlikely,

since in ten out of the 23 families reported in this series the propositus was a female without visual symptoms, or at most, mild disease. Such a biased referral would cause a smaller number of families with dominant disease to be referred than occurs in the general population, since the dominant disease is mild (Jay and Bird, 1973). However, 25.5 per cent. of the families referred with retinitis pigmentosa had dominantly inherited disease, which is not less than the previously published figures of frequency in the general population (19.5 per cent., François, 1961; 9 per cent. Ammann and others, 1965).

It is possible that the families with X-linked and autosomal dominant disease would present preferentially since they had large pedigrees and referral of any one of many affected members would cause the family to be studied. Such a tendency would also



V/7 A 28-year-old female with an affected brother (V, 9). She had no symptoms, the visual acuity was 6/6 in each eye, and the visual fields were normal. The peripheral pigment epithelium appeared mottled and the periphery of the right fundus showed a small atrophic patch with migration of pigmented cells into the retina. This was illustrated by fluorescein fundus angiography (3f). Abnormal function was confirmed by estimation of retinal rhodopsin concentration, which was reduced by 40 per cent.

Fig. 3(f) reproduced by courtesy of the editor of the *Trans. Amer. Acad. Ophthalm. Otolaryng.* (1973) **77**, p. OP 649, fig. 14

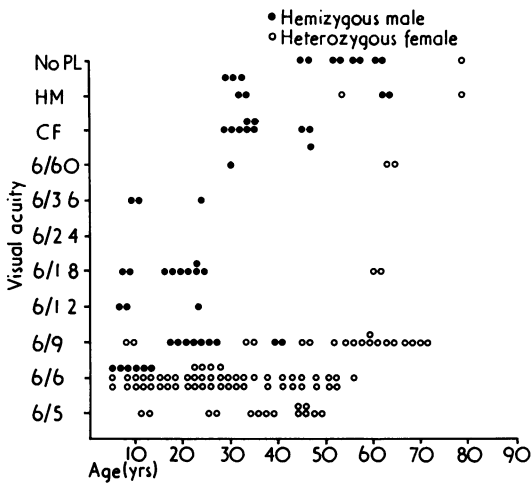


FIG. 4 Best visual acuity of each eye in hemizygous males and heterozygous females, by age

cause the number of autosomal recessive families to be relatively less. Families with dominant disease were seen more frequently than would have been predicted by François (1961) and by Ammann and others (1965) although the excess over François' figure is not great. The ratio of relative frequencies of dominant disease between François' figures and those in this study (19.5%: 25.5%) is quite different from the ratio relating to X-linked disease (4.5%: 21.5%). In addition, it is evident that many of the X-linked pedigrees are not large. The frequency of families with autosomal recessive disease was much less than found by François (1961) and by Ammann and others (1965): 12 per cent. in this study compared with 39 per cent. by François and 90 per cent. by Ammann and others.

That the excess of families with X-linked disease may have been caused by biased referral is thus unlikely, and it is much more likely to be due to different genetic pools in different countries and other socio-economic factors. In particular, it is well recognized that the prevalence of consanguineous marriages in the isolated communities of the Swiss valleys has resulted in high incidences of autosomal recessive disease. This has undoubtedly affected the results of the Swiss study (Ammann and others, 1965). In England, as in most of Western Europe, 1 per cent. of marriages are consanguineous (Bell, 1940; Shields and Slater, 1954; Freire-Maia, 1957) while in Switzerland the rate may be as high as 15 per cent. (Egenter, 1934; Ruepp, 1935).

It is likely that the families in this study are more representative of the genetic pool and clinical experience in Western Europe, and therefore of North America, than those in the Swiss study. Moorfields Eye Hospital does not drain a selected genetic pool, since London is not an isolated community and its

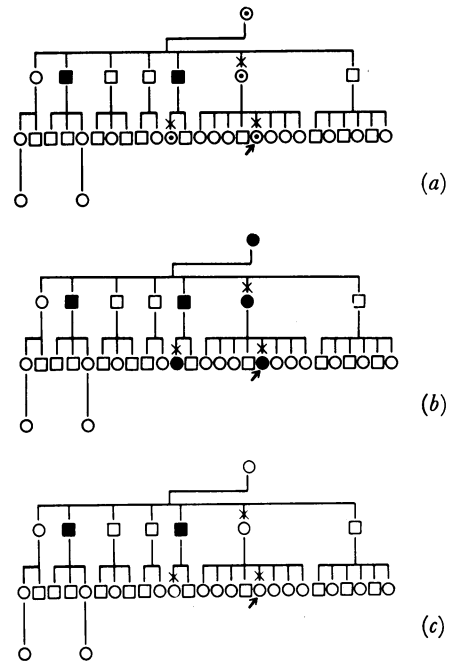


FIG. 5 Part of P478 (shown in full in Fig. 1)
(a) Heterozygotes and hemizygotes identified
(b) Heterozygotes and hemizygotes shown as affected
(c) Hemizygotes only shown as affected

population is relatively mobile. Many of the families originated from outside South-east England, and in three families only one member resided in the home counties of London.

The preponderance of males with retinitis pigmentosa compared with females found by Nettleship (1908) indicates that the high frequency of X-linked disease is not a recent development in England, but dates back at least 100 years.

MORPHOLOGY AND OCULAR FUNCTION

Hemizygous males

In the 23 families studied, 42 affected males were seen and the functional loss recorded. Details of visual loss were obtained in a further 69 cases from their relatives. There was little variation in the severity of the disease from one family to another, and from one member of a large family to another. It was clear that the dystrophy was severe in all males, though one (P596/IV/12) was less severely affected than the others. Loss of dark adaptation was documented within the first decade of life in all affected males, symptoms referable to field loss occurred within the second decade, most noticed difficulty in reading by the age of

20 years, and severe incapacity was almost universal by the age of 40 years. All affected males, even the young, had typical retinitis pigmentosa, and marked choroidal atrophy was not seen except in middle or late life.

Some authors have emphasized that there may be atrophy of the choroid in late disease (Falls and Cotterman, 1948; François, 1962) which may be so severe as to resemble choroideremia. This led some authors to distinguish between X-linked retinitis pigmentosa and X-linked choroido-retinal atrophy (Sorsby and Savory, 1956) and to suggest that the genes for X-linked retinitis pigmentosa, choroideremia, and X-linked choroidal sclerosis, though distinct, may be allelemorphic.

The presence of choroidal atrophy late in the disease does not justify separating the disease in these families from retinitis pigmentosa, as has been suggested in the past (Falls and Cotterman, 1948; Sorsby and Savory, 1956; François, 1962; Hoare, 1965), for several reasons. Only three males in families with X-linked retinitis pigmentosa have been described with severe choroidal atrophy (Sorsby and Savory, 1956; François, 1962) and affected male relatives had typical retinitis pigmentosa. The reported atrophy in other families (Falls and Cotterman, 1948; Hoare, 1965) was localized and, in most, the easy visualization of the choroidal blood vessels could be ascribed to the combination of myopia with thin choroidal pigment in eyes with blue irides. It would seem that choroidal atrophy is not prominent or consistent in affected males in these families and is seen only in far advanced disease.

It should be emphasized that retinitis pigmentosa is not a single disease but a generic term used to describe several diseases which share certain morphological similarities, but which are distinct one from the other, and which can be sub-divided on the basis of inheritance and severity. In addition, choroidal atrophy has been well described in advanced typical retinitis pigmentosa (Lister, 1903; Gonin, 1903; Wolter, 1957). The presence of choroidal atrophy is probably a reflection of the severity of the disease, rather than an indication of a completely separate disease category. The reports of atrophy have led to some confusion, and families with probable choroideremia have been discussed in the same context as those with X-linked retinitis pigmentosa (Jacobson and Stephens, 1962).

There is little doubt that choroideremia is distinct from X-linked retinitis pigmentosa, as choroidal atrophy occurs in the second decade of life in the former disease, and a unique retinal appearance is found in females heterozygous for choroideremia (Krill, 1969; Bird and Blach, 1970). Therefore the characteristics of the disease in males reported here suggest that this is a single entity, retinitis pigmentosa, which is quite distinct from choroideremia and other X-linked fundus dystrophies.

Heterozygous females

Particular attention was paid to the individual presentation of affected women, and morphological and functional ocular abnormalities were analysed.

Contrary to the experience of several investigators (Falls and Cotterman, 1948; Weiner and Falls, 1955; Roberts, 1959; François, 1962; Ricci and others, 1963; Goodman and others, 1965; Hussels, 1967; Warburg and Simonsen, 1968; Krill, 1969), albeit with small numbers of cases, the presence of a prominent tapetal reflex was not found to be a particularly helpful sign of the heterozygous state in this series. While prominent reflexes were seen in the young, it was found impossible to differentiate this from the normal retinal reflex of young fundi. This is illustrated in P22 in which there was a prominent reflex in both V/5 and V/6, and yet by other criteria it seemed likely that V/5 was heterozygous for X-linked retinitis pigmentosa and V/6 was not. In their mother, who undoubtedly had the abnormal gene, there was no tapetal reflex. One heterozygote (P633/IV/13) had prominent "tapetal" reflexes at the age of 49 years, which were undoubtedly abnormal and presumably due to her heterozygous state. Multiple small white retinal bodies were seen in members of P336 (IV/3, V/1, and V/7) giving the retina a distinctive sheen, but this feature was unique to this family in the present series, and was not even common to all affected women in the same family. These white bodies were very similar to those described by Falls and Cotterman (1948).

Peripheral pigment epithelial loss was found to be a much more common and easily recognizable change than abnormal reflexes in heterozygous females. In mildly affected females this presented as well-defined patches of pre-equatorial pigment epithelial thinning and was associated with migration of pigment-laden cells into the retina in some cases. When changes were particularly difficult to identify, fluorescein angiography was used to verify the finding. It should be emphasized that the abnormal areas of fundus presented a slightly grey appearance as opposed to the orange/red colour of the normal fundus. The change was a subtle one which could be recognized only by indirect ophthalmoscopy by which large areas of fundus can be seen in a single field. This is a much earlier morphological change in retinitis pigmentosa than pigment migration into the retina, as has been emphasized in the past (Zeavin and Wald, 1956). In the more advanced disease two distinct changes were seen: well-defined atrophy of pigment epithelium and choroid occurred in the pre-equatorial fundus associated with marginal hyperpigmentation (*e.g.* P396/IV/2), and the typical findings of retinitis pigmentosa were seen posterior to the equator. Both patterns of change were seen in the same fundus in some females (P563/III/9).

With one exception (P396/V/7), visual field loss

was always found in women with fundus abnormalities. These field defects corresponded well with the areas of fundus change, and were found by conventional testing with a kinetic perimeter. The field defects were frequently found peripheral to the mid-zone field defects usually associated with retinitis pigmentosa, though this was not always the case. Establishing that there was field loss proved useful on several occasions when there was doubt as to the significance of peripheral fundus changes.

It was unusual for a female to complain of difficulty with vision at night, unless there was elevation of the dark adaptation threshold by at least one log unit. However, a raised final dark adaptation threshold was found almost universally by paying particular attention to the final log unit of dark adaptation. In many, the deficit was of doubtful significance, and in isolation this finding was of little value. With the only apparatus available (Goldmann-Weekers adaptometer), there is a variation amongst normal subjects of 0.5 log unit, which represents 70 per cent. of dark adaptation. Therefore the difficulty in using this test relates to the circumstances of testing rather than to the maintenance of rod function until late in the disease. By using strict criteria for normality, minor changes were detected with little other evidence of retinal degeneration. That these minor abnormalities reflect dysfunction is shown by measurement of rhodopsin concentration in the retina; this is related in a linear fashion to the final dark adaptation threshold (Highman and Weale, 1973), so that slight elevation of this threshold is associated with marked, and easily detectable, reduction of retinal rhodopsin concentration (Bird and Highman, 1972; Highman and Weale, 1973). This was particularly useful in one patient (P396/V/7) in whom other deficits were difficult to detect. The limited experience to date suggests that measurement of rhodopsin kinetics may provide a very sensitive index of early retinal dysfunction in retinitis pigmentosa.

Reduction of light-induced rise in ocular potential proved to be a useful test to confirm ocular abnormalities which were otherwise only suspected, but on no occasion did it reveal dysfunction of an otherwise normal eye. It is of interest that a normal light-induced rise in potential was recorded in the presence of easily detectable fundus abnormalities and functional deficit in fifteen out of 42 heterozygous females, and a reduced but present light-induced rise in potential was recorded in the presence of advanced retinal dystrophy (P336/V/5). Both these findings are unusual in hemizygous males and in other genetic forms of retinitis pigmentosa, and their significance will be discussed.

The *a*-wave and *b*-wave potentials on electroretinography were reduced in females with advanced changes, but were normal in the majority of cases. The amplitudes were never abnormal in the presence of a normal light-induced rise in ocular potential.

The conclusion that the most sensitive fundoscopic evidence of the heterozygous state was pigment epithelial changes in the peripheral fundus, rather than the presence of a "tapetal reflex", is at variance with the findings of most other authors. In only two families was an abnormal reflex recognized. However, it should be emphasized that of the thirty families previously reported with X-linked retinitis pigmentosa, nineteen were published as single family studies (Gonin, 1902; Nettleship, 1909; Bell, 1922; Gasalla, 1931; Usher, 1935; McQuarrie, 1935; Janssen, 1938; Falls and Cotterman, 1948; McKenzie, 1951; Weiner and Falls, 1955; Wolter, 1957; Roberts, 1959; Kobayashi, 1960; François, 1962; Ricci and others, 1963; Hoare, 1965; Goodman and others, 1965; Hussels, 1967; Warburg and Simonsen, 1968; Berson and others, 1969; Imaizumi and others, 1970; Warburg, 1971). Many were reported because of the tapetal reflex and it is clear that the collective experience contained in these reports does not give a good indication of the relative frequency of different morphological features that may present in heterozygotes for X-linked retinitis pigmentosa. Three further families were reported by one author (Krill, 1967, 1969), but only four heterozygotes were examined. The only investigator who examined a large number of families was Schappert-Kimmijser (1963) who saw the remaining eight families. Abnormal reflexes were found in heterozygotes of only one family, and it was concluded that this sign may be helpful when present, but that its absence is of no significance. It was also found that pigmentary changes were a much more reliable index of the heterozygous state. It is significant that these findings correspond well with the evidence from this study.

With slight modification, measurement of dark adaptation might prove to be important in detecting the heterozygous state. By altering the neutral density wedge, more accurate measurement of the last log unit of dark adaptation might be made more accurate. It is unfortunate that in this study dark adaptation was measured in the central field only. Zeavin and Wald (1956) showed that peripheral rod function becomes affected long before central rod function, and they concluded that loss of dark adaptation in the peripheral field occurred before ophthalmoscopic abnormalities were detectable. However, they used the presence of pigment in the retina as an index of ophthalmoscopically detectable retinal disease. Since this is not the earliest detectable morphological change, their conclusion has yet to be proved.

It is hoped that, with further experience, retinal rhodopsin concentration measurements will provide the most sensitive index of retinal dysfunction.

Considerable variation in the severity of the disease was recorded from one woman to another. Since the dystrophy was progressive, severe dysfunction was more common in old age, and blindness occurred only

after the seventh decade of life (P₄₇₈/III/4 and IV/17). The degree of visual loss was not, however, related to age alone. The most advanced degeneration in a young woman was seen in P₃₃₆/V/5, in whom there was considerable upper half visual field loss before the age of 20 years. The extent of degeneration approached that seen in hemizygous men, but the relative preservation of dark adaptation distinguished her disease from that seen in her male relatives. That her sister was also fairly severely affected may be significant, although other females in the family were only mildly affected.

There appeared to be no great variation in the severity of the dystrophy in females from one family to another, since severely affected females were found in all families with moderate or large pedigrees. They were not more common in one family than in any other.

Of interest is the apparent symmetry of involvement between the two eyes which has been remarked upon in the past (Warburg, 1971). Only in one case (P₅₆₃/III/9) was there a marked difference in the extent of the dystrophy between the two eyes, although both had severe disease.

All females who from genetic evidence must have been heterozygous for X-linked retinitis pigmentosa, because they had either affected sons (19 individuals) or affected fathers (15 individuals), and who were old enough to test, had some recognizable fundus abnormality whether morphological or functional. Of the 23 who had a 50 per cent. chance of being heterozygous because they had a heterozygous mother, and did not have male descendants, fourteen had detectable changes. The excess of abnormal to normal may be due to the fact that three of the possible heterozygotes presented with visual symptoms caused by retinal degeneration.

It is clear that most if not all heterozygous females in this series had retinal changes and ocular functional deficits and that the manifestations of the disease in women are quite different from those in men.

More significant, perhaps, is the fact that no proven heterozygous female had normal eyes, so that it is likely that an accurate prediction could be made by childbearing age of the chance of any possible heterozygote having affected children.

This conclusion is at variance with the findings of previous authors, except Imaizumi and others (1970), whose family, significantly, is the most recent but one to be reported. It is likely that the increased sensitivity of examiners and of examination methods accounts for the discrepancy in reports. In many previous studies, migration of pigmented cells into the retina has been considered to be the hallmark of retinitis pigmentosa and has been used as a criterion of retinal disease. However, this feature is not an essential part of the disease, and probably occurs years after outer segment loss and receptor cell death (Zeavin and

Wald, 1956). If pigmentation were used alone as a criterion of disease, many heterozygous females would not be recognized. Of particular importance in this study was fluorescein fundus angiography, by which the significance of mild peripheral pigment epithelial changes could be assessed.

The loss of visual function and the fundus morphology in heterozygous females is quite unlike the phenotype of heterozygotes for choroideremia. This provides further evidence to distinguish the disease in the families in this study from choroideremia in which heterozygotes have a distinctive fundus appearance and no functional loss (Krill, 1967, 1969; Bird and Blach, 1970).

EXPRESSION OF THE HETEROZYGOUS STATE

In the families under study, the severe retinopathy in males can be ascribed to their hemizygous state for the abnormal gene, while the milder involvement of the females is due to their being heterozygous for this gene. That the disease in females represents a mild form of the male disease is possible, though there are certain indications that there may be qualitative differences between the two. The selective involvement of pre-equatorial retina in many women is not seen in men. Maintenance of a large intact central visual field, rod function, and light-induced rise in ocular potential in the presence of advanced peripheral retinal and choroidal atrophy is quite unlike the dystrophy of males with X-linked disease and of patients with other forms of genetically-determined retinitis pigmentosa.

The lack of correlation in genetically-determined retinitis pigmentosa between apparent loss of receptor function and reduction of ERG potentials and the light-induced rise in ocular potential led to the suggestion that factors other than receptor cell death were responsible for the changes in the electrical behaviour of the eye. Riggs (1954) suggested that changes in the peripheral fundus caused alterations of the resistive membrane, resulting in an electric short circuit between the retina and choroid. Later work on electro-oculography showed loss of potential which was also apparently excessive when compared with visual sensory loss (Arden and Fojas, 1962); this gave further support to Riggs' hypothesis. It was concluded that dramatic reduction of the recorded electrical responses of the eye to light was an essential association with early genetically-determined retinitis pigmentosa.

Preservation of electrical responses in patients with non-genetically determined pigmentary retinal degeneration is well documented (Björk and Karpe, 1951), and has been used as evidence to show that the disease process in secondary retinal degeneration is basically different from that in genetically determined retinitis pigmentosa (Carr and Siegel, 1973). On the same grounds it could be argued that there is a qualitative difference between the disease in heterozygotes

for X-linked retinitis pigmentosa and in their hemizygous relatives. Fifteen out of 42 heterozygotes in this series had a normal light-induced rise in ocular potential and eleven of 21 had normal ERG potentials despite unequivocal evidence of genetically-determined retinal degeneration. However, it should be borne in mind that dark adaptation and visual field testing do not necessarily give an accurate indication of the number of surviving receptor cells, and the original premise, which assumed lack of correlation between sensory loss and electrical responses, may be at fault. Loss of half the receptor cells evenly throughout the retina would cause little detectable sensory deficit because of the neural anatomy of the retina, whilst loss of all receptors in 50 per cent. of the retina would result in easily detectable visual field loss. If electrical responses of the eye to light were directly related to the size of the receptor cell population, 50 per cent. receptor cell death would have an equal effect on the electrical ocular responses however they were lost.

The significance of field loss in patients with genetically-determined retinitis pigmentosa sufficient to cause symptoms, but without reduction of light-induced rise in ocular potential or ERG potentials (P458/IV/2), must remain in doubt, though it is possible that it indicates patchy rather than diffuse disease. Patchy disease in heterozygous women would reduce the amount of receptor cell death necessary to cause detectable visual loss and would result in apparent preservation of the ocular electrical responses to light.

Alternatively, the disease of the heterozygotes in this series may be milder than that of patients in previous studies, since many women in this study did not present with visual loss, but were invited to come as part of a family survey or were seeking genetic advice. The apparent discrepancy between results in this series and other series may be due to this alone. The normal light-induced rise in ocular potential may be in excess of 300 per cent. and halving of the potential change by disease would still leave the figure within normal limits. A recorded light rise of 180 per cent. may or may not be normal for any particular patient, and ignorance of the premorbid light rise prevents more critical appraisal of these results.

The variability of deficit from one female to another and the symmetrical involvement of the two eyes of the same female were very striking. It was suspected that the young woman with severe dysfunction (P336/V/5) might have had an abnormal complement of sex chromosomes, but the chromosome count was found to be normal. Her sister was also severely affected, though other females in the family, who were presumably heterozygous for the same gene, had little dystrophy. The phenotypic expression of a gene is modified by its allele, and also by the total genetic pool, and it is possible that the two severely affected sisters had the same normal allele which allowed greater expres-

sion of the gene for retinitis pigmentosa than other normal alleles in other females of the family.

Whilst it is possible that other distinct genetic and non-genetic factors may influence the dystrophy in women, the severity of the disease could not be related to easily identifiable genetically-determined factors, such as refractive error or iris colour, or to non-genetic factors. Renewed interest has been shown recently by Berson (1971) in the importance of light in the pathogenesis of retinitis pigmentosa, though Weale (1972) argued that the case was not proven. There is no evidence to suggest that the severely affected female (P336/V/4) had been exposed to greater ambient light than had her sister or female cousins. If light played an important part in the pathogenesis of the dystrophy one would expect the lower fundus to show a greater degree of involvement than the upper fundus, since in most circumstances of life illumination from above is far greater than from below. While in the severely affected women (P336/V/4 and V/5; P22/IV/6) the dystrophy appeared to be greater in the lower retina, in most women this was not the case. It is therefore possible that, in women destined for severe visual loss, light exposure plays a part in hastening the degeneration, but it is unlikely to be an important factor in most patients.

Importance of X-chromosome inactivation

In an attempt to explain the phenomenon of attenuated disease in heterozygotes of an X-linked characteristic, Lyon (1961) proposed the hypothesis of random inactivation of X-chromosomes. Non-random inactivation of paternal X-chromosomes and of structurally abnormal X-chromosomes has been suggested (Cooper, 1971; Hirschhorn and Firschein, 1964; Polani, Angell, Giannelli, Della Chapelle, Race, and Sanger, 1970; Hamerton and Giannelli, 1971).

Inevitably, inactivation of one X-chromosome has been suggested as an important influence in determining the expression of the gene for retinitis pigmentosa (Krill, 1967; Berson and others, 1969; Warburg, 1971). Most features of the disease seen in heterozygous women have now been explained on the basis of inactivation though none gives direct support to Lyon's hypothesis. The apparent patchy nature of the disease in some cases has been claimed as evidence of two cell populations in the retina (Schappert-Kimmijser, 1963; Goodman and others, 1965; Hoare, 1965; Hussels, 1967; Berson and others, 1969; Berson and Goldstein, 1970; Imaizumi and others, 1970), though Krill (1967) could find no greater variability in the dark adaptation thresholds of different parts of the retina in heterozygotes than in normal subjects. Functional and morphological studies in patients reported here suggest that the disease is patchy. Many heterozygotes showed severe functional loss in the peripheral fundus with marked atrophy of the retina

and choroid, while function in the posterior retina was well preserved. In some of these the presence of a light-induced rise in potential was striking, suggesting preservation of ocular function as a whole. These features are quite atypical of the disease in men or of other forms of retinitis pigmentosa. However, Grüneberg (1967) thought that patchy disease did not present *prima facie* evidence to support Lyon's hypothesis. No careful studies have yet been performed on affected males at an equivalent stage of evolution of the disease, since an equivalent stage would occur in the first 5 years of life. Therefore it is impossible to be certain whether or not patchy disease may be found in affected young males, though this seems unlikely. The great variability in functional loss from one heterozygote to another has also been claimed to support Lyon's hypothesis. For similar reasons uncertainty must exist whether heterozygotes present greater variability than hemizygotes, though it appears likely that affected women present a less uniform disease than affected men. Even if greater variability were proved in heterozygotes, it appears that direct support for Lyon's hypothesis cannot be adduced from this evidence (Grüneberg, 1967). On the other hand, the remarkably symmetrical involvement of the two eyes in heterozygous females and the preponderance of apparently normal over abnormal areas of the retina has been considered difficult to explain on the basis of random inactivation (Krill, 1967). If inactivation is to explain the pattern of retinal degeneration in heterozygous females, both these objections would have to be satisfied. Krill (1967) thought that the inactivation hypothesis could still explain gene effects in retinal degeneration if certain assumptions were made. A preponderance of normal cells would occur if the cell with the normal gene had selective advantage over the cell with the abnormal gene. Thorough mixing of normal and abnormal cells during development would explain his failure to find patches of normal and abnormal retina. Symmetrical involvement between the two eyes could also be explained if inactivation of one X-chromosome occurred before lateralization of the embryo (Warburg, 1971). Barr bodies appear in cultured fertilized human eggs $6\frac{1}{2}$ days after fertilization, (Steptoe, Edwards, and Purdy, 1971), whereas lateralization occurs at 11 to 12 days (Arey, 1965). During this interval there may be a mixture of the different clones, so that an equal number of abnormal cells would pass to either side.

While some features of the disease in heterozygotes suggest inactivation, and others, in particular the symmetry of the disease in the two eyes, can be explained by inactivation after making certain assumptions, they do not test or support Lyon's hypothesis in any way. In particular, it is possible that the primary abnormality in X-linked retinitis pigmentosa may be distant from the eye and that the eye is a target organ

for the disease affected by humoral factors. If this were the case, to seek features of the ocular disease by which Lyon's hypothesis could be tested would be rendered futile.

One factor which has not been taken into account is the preferential involvement of peripheral retina with apparent sparing of the central retina until late in the disease. This feature, above all others, characterizes the degeneration seen in heterozygous women and cannot be explained on a genetic basis. It must have some anatomical or physiological explanation related to the factors influencing peripheral as opposed to central retinal function.

It is likely that the expression of the heterozygous state is governed by many factors, including the influences of the normal allele and chromosome inactivation, ambient illumination of the retina, and anatomical and physiological factors affecting the retina. The findings in the families studied do nothing to identify the factors important in this regard.

GENETIC TRANSMISSION OF X-LINKED RETINITIS PIGMENTOSA

Evidence has been put forward on two grounds that the phenotypic expression of the heterozygous state indicates that more than one gene is involved in transmitting the disease, and this has been widely accepted (Roberts, 1959; McKusick, 1971).

Both McKenzie (1951) and Kobayashi (1960) thought that the families they described had a different disease from that in families reported by previous authors, since there was easily detectable and often severe retinal degeneration in females, although in McKenzie's family severe visual loss was not experienced until the eighth decade of life. However, retinal degeneration in heterozygotes had been described as early as 1935 by McQuarrie, and it now appears to be the opinion of most authors that minor affection of heterozygous females is not rare (Schapert-Kimmijser, 1963; Hoare, 1965; Krill, 1967; Berson and Goldstein, 1970; Imaizumi and others, 1970). This led Berson to conclude that no subdivision of X-linked retinitis pigmentosa into dominant, recessive, and intermediate could be made on the basis of differential severity of involvement of heterozygous females. The results of this study support Berson's conclusion, in that all degrees of severity were seen in heterozygous females in all large pedigrees, and that most if not all heterozygotes were affected to some degree.

Also, it is possible that more subtle features of the retinopathy in women may provide a basis for postulating that more than one gene is involved. The only feature unique to one family was the white bodies seen in three members of P336 (IV/3, V/1, and V/7), a feature not found in other heterozygous women of this family. The presence of these white bodies may be

significant in view of previous reports of this finding (Diem, 1914; Falls and Cotterman, 1948), and may indicate different genetic influences in this family as compared with others.

Evidence of heterogeneity in affected males is inconclusive. With the exception of a single male (P596/IV/12), all hemizygotes had equally severe disease and no subdivision can be made on the basis of the severity of the disease. As has already been argued, it is not justifiable to differentiate the disease in some families from that in others because of choroidal atrophy seen in affected men in old age. While none of the evidence supports the contention that more than one gene is involved, it certainly does not refute it, and the number of genes involved must remain in doubt.

Without evidence to support the concept of heterogeneity, discussion concerning the number of loci involved must be futile.

Summary

Of 107 consecutive patients with genetically-determined retinitis pigmentosa, 23 were provisionally diagnosed as having inherited the disease in an X-linked fashion. 42 affected males and 61 females were examined, and from the data obtained the following conclusions were drawn:

- (1) X-linked retinitis pigmentosa exists and is distinct from choroideremia.
- (2) In contrast to the results of previous surveys, X-linked retinitis pigmentosa is a common form of this disease and over 20 per cent. of retinitis pigmentosa is probably transmitted in an X-linked manner.
- (3) (a) In contradistinction to the findings of previous investigators, most if not all adult heterozygous

females have detectable degenerative changes in the ocular fundus.

(b) The ocular changes in heterozygous females are most easily detected by fundus examination, visual field testing, dark adaptation measurements, and estimation of retinal rhodopsin concentration. The single most frequent abnormality is peripheral retinal pigment epithelial atrophy, which is found in all adult heterozygous females.

(c) The pattern of retinal dysfunction in heterozygous females, and in particular preservation of the ocular electrical responses, suggests that the disease in women is qualitatively different from that in men and in other genetic forms of retinitis pigmentosa. There is some evidence that the disease in heterozygous women is patchy.

(d) Degeneration in heterozygous females is usually symmetrical, but great variation was found in the severity of degeneration amongst heterozygotes of similar ages. No non-genetic influences were found to account for this. No evidence came to light by which the importance of X-chromosome inactivation could be assessed in determining the phenotype of heterozygous women.

- (4) No evidence is available to determine the number of X-linked genes transmitting the disease.

I should like to thank the consultant ophthalmologists who referred patients for study and Mr. Barrie Jay who supervised the study and advised on the preparation of the manuscript. I am grateful to Prof. G. B. Arden and Mr. J. H. Kelsey for allowing electro-oculography, electroretinography, and dark adaptation measurements to be performed in the Electrodiagnostic Department at Moorfields Eye Hospital, and to Dr. V. N. Highman and Prof. R. A. Weale, who performed the rhodopsin concentration measurements. I am also grateful to Miss J. Lace and Miss A. M. Rutter for secretarial help.

References

- AMMANN, F., KLEIN, D., and FRANCESCHETTI, A. (1965) *J. neurol. Sci.*, **2**, 183
- ARDEN, G. B., and BARRADA, A. (1962) *Brit. J. Ophthalm.*, **46**, 468
- , ———, and KELSEY, J. H. (1962) *Ibid.*, **46**, 449
- and FOJAS, M.R. (1962) *Arch. Ophthalm. (Chicago)*, **68**, 369
- AREY, L. B. (1965) "Developmental Anatomy. A Textbook and Laboratory Manual of Embryology". Saunders, Philadelphia and London
- BELL, J. (1922) "Retinitis pigmentosa and allied diseases", in "Treasury of Human Inheritance", ed. K. Pearson, vol. 2, pt. 1, fig. 156. Cambridge University Press, London
- (1940) *Ann. Eugen.*, **10**, 370
- BERSON, E. L. (1971) *Arch. Ophthalm. (Chicago)*, **85**, 521
- and GOLDSTEIN, E. B. (1970) *Invest. Ophthalm.*, **9**, 58
- , GOURAS, P., GUNKEL, D., and MYRIANTHOPOULOS, N. C. (1969) *Arch. Ophthalm. (Chicago)*, **81**, 215
- BIRD, A. C., and BLACH, R. K. (1970) *Trans. ophthalm. Soc. U.K.*, **90**, 127
- and HIGHMAN, V. (1972) *Ibid.*, **92**, 221

- BJÖRK, A., and KARPE, G. (1951) *Acta ophthal. (Kbh.)*, **29**, 361
- CARR, R. E., and SIEGEL, I. M. (1973) *Arch. Ophthal. (Chicago)*, **90**, 21
- COOPER, D. W. (1971) *Nature (Lond.)*, **230**, 292
- DIEM, M. (1914) *Klin. Mbl. Augenheilk.*, **53**, 371
- DUKE-ELDER, S., and DOBREE, J. H. (1967) "Diseases of the retina", in "System of Ophthalmology", vol. 10, p. 577. Kimpton, London
- EGENTER, A. (1934) *Arch. Julius Klaus Stift.*, **39**, 365
- FALLS, H. F., and COTTERMAN, C. W. (1948) *Arch. Ophthal. (Chicago)*, **40**, 685
- FINE, S. R. (1968) "Blind and Partially Sighted Children". Education Survey no. 4, Department of Education. HMSO, London
- FRANÇOIS, J. (1961) *Proc. roy. Soc. Med.*, **54**, 1109
- (1962) *Docum. Ophthal.*, **16**, 111
- FREIRE-MAIA, N. (1957) *Eugen. Quart.*, **4**, 127
- GASALLA, W. (1931) *Bull. Soc. franç. Ophtal.*, **44**, 169
- GONIN, J. (1902) *Ann. Oculist. (Paris)*, **128**, 90
- (1903) *Ibid.*, **129**, 24
- GOODMAN, G., RIPPS, H., and SIEGEL, I. M. (1965) *Arch. Ophthal. (Chicago)*, **73**, 387
- GRÜNEBERG, H. (1967) *Ann. hum. Genet.*, **30**, 239
- HAMERTON, J. L. and GIANNELLI, F. (1971) *Nature (Lond.)*, **228**, 1322
- HECK, A. F. (1963) *Arch. Ophthal. (Chicago)*, **70**, 143
- HIGHMAN, V. N., and WEALE, R. A. (1973) *Amer. J. Ophthal.*, **75**, 822
- HIRSCHHORN, K., and FIRSCHEIN, I. L. (1964) *Trans. N.Y. Acad. Sci.*, ser. 2, **26**, 545
- HOARE, G. W. (1965) *Brit. J. Ophthal.*, **49**, 449
- HUSSELS, I. E. (1967) *J. Génét. hum.*, **16**, 106
- IMAIZUMI, K., TAKAHASHI, R., ATSUMI, K., TAKAHASHI, F., SHOJI, U., YAMADA, K., IMAIZUMI, S., and MITA, K. (1970) *Jap. J. clin. Ophthal.*, **24**, 465
- JACOBSON, J. H., and STEPHENS, G. (1962) *Arch. Ophthal. (Chicago)*, **67**, 321
- JANSSEN, O. (1938) "Zur Erbbiologie der Retinitis pigmentosa", Inaug. Diss., Munster i. Westf. (Quoted by François, 1962)
- JAY, B. S., and BIRD, A. C. (1973) *Trans. Amer. Acad. Ophthal. Otolaryng.*, **77**, 641
- KELSEY, J. H. (1969) *Int. Ophthal. Clin.*, **9**, 883
- KJERRUMGAARD, E. (1948) *Acta ophthal. (Kbh.)*, **26**, 55
- KLEIN, D., FRANCESCHETTI, A., HUSSELS, I., RACE, R. R., and SANGER, R. (1967) *Lancet*, **1**, 974
- KOBAYASHI, F. (1960) *Jap. J. Ophthal.*, **4**, 82
- KRILL, A. E. (1967) *Amer. J. Ophthal.*, **64**, 1029
- (1969) *Trans. Amer. ophthal. Soc.*, **67**, 535
- LISTER, W. T. (1903) *Roy. Lond. ophthal. Hosp. Rep.*, **15**, 254
- LYON, M. F. (1961) *Nature (Lond.)*, **190**, 372
- MCKENZIE, D. S. (1951) *Trans. ophthal. Soc. N.Z.*, **5**, 79
- MCKUSICK, V. A. (1962) *Ann. intern. Med.*, **56**, 991
- (1971) "Mendelian Inheritance in Man", 3rd ed. Johns Hopkins Press, Baltimore
- MCQUARRIE, M. D. (1935) *J. Genet.*, **30**, 147
- MANN, I. (1937) "Developmental Abnormalities of the Eye", Fig. 105. Cambridge University Press, London
- NETTLESHIP, E. (1908) *Roy. Lond. ophthal. Hosp. Rep.*, **17**, 333
- (1909) *Trans. ophthal. Soc. U.K.*, **29**, 57
- POLANI, P. E., ANGELL, R., GIANNELLI, F., DE LA CHAPELLE, A., RACE, R. R., and SANGER, R. (1970) *Nature (Lond.)*, **227**, 613
- RICCI, A., AMMANN, F., and FRANCESCHETTI, A. (1963) *Bull. Soc. franç. Ophtal.*, **76**, p. 31
- RIGGS, L. A. (1954) *Amer. J. Ophthal.*, **38**, 708
- ROBERTS, J. A. F. (1959) "An Introduction to Medical Genetics", p. 180. Oxford University Press, London
- RUEPP, G. (1935) *Arch. Julius Klaus-Stift.*, **10**, 193
- SCHAPPERT-KIMMIJSER, J. (1963) *Bull. Soc. franç. Ophtal.*, **76**, p. 122
- SEGEL (1884) *Dtsch. militärztl. Z.*, **13**, 213 (Quoted by Schappert-Kimmijser, 1963)
- SHIELDS, J., and SLATER, E. (1954) *Acta genet. statist. med.*, **6**, 60
- SORSBY, A. (1966) "The Incidence and Causes of Blindness in England and Wales 1948-1962". Reports on Public Health and Medical Subjects, no. 114. HMSO, London
- and SAVORY, M. (1956) *Brit. J. Ophthal.*, **40**, 90

- STEPTOE, P. C., EDWARDS, R. G., and PURDY, J. M. (1971) *Nature (Lond.)*, **229**, 132
- USHER, C. H. (1935) *Trans. ophthal. Soc. U.K.*, **55**, 164
- WARBURG, M. (1971) *Ibid.*, **91**, 553
- and SIMONSEN, S. E. (1968) *Acta ophthal. (Kbh.)*, **46**, 494
- WEALE, R. A. (1972) *Vision Res.*, **12**, 747
- WEINER, R. L., and FALLS, H. F. (1955) *Arch. Ophthal. (Chicago)*, **53**, 530
- WOLTER, J. R. (1957) *Ibid.*, **57**, 539
- ZEAVIN, B. H., and WALD, G. (1956) *Amer. J. Ophthal.*, **42**, 253s