

Lens fringe in homocystinuria

MICHAEL S. RAMSEY¹ AND D. HOWARD DICKSON*²

From the Departments of Ophthalmology, Pathology, and Anatomy,* Dalhousie University, Halifax, Nova Scotia, Canada

Homocystinuria, an inborn error of metabolism, was first described by Carson and Neill (1962). At least three biochemical abnormalities may give rise to this disease (Mudd, Finkelstein, Irreverre, and Laster, 1964; Mudd, Levy, and Morrow, 1970; Mudd, Ulendorf, Freeman, Finkelstein, and Shih, 1972). The clinical features may include malar flush, skeletal abnormalities, mental retardation, and thromboembolic phenomena. The principal ocular abnormality is ectopia lentis, with the lens frequently becoming dislocated anteriorly giving rise to acute glaucoma.

The ocular histopathology described by Henkind and Ashton (1965) and Ramsey, Yanoff, and Fine (1972) revealed the breakdown of the zonular filaments.

A lens fringe of zonular remnants has recently been described in two patients with homocystinuria by Ramsey, Daitz, and Beaton (1975). The present study reports the findings of a transmission and scanning electron microscopical evaluation of a lens from one of these patients.

Clinical summary

A 14-year-old mentally retarded female presented at the emergency department of the Izaak Walton Killam Hospital for Children. Examination revealed bilateral anterior dislocation of the lenses. Investigation of this patient and her 9-year-old sister revealed that both had homocystinuria.

A detailed description of these two patients and their management is to be published elsewhere (Beaton, Ramsey, and Daitz).

The equatorial regions of the lenses from both patients showed the presence of white zonular remnants which undulated freely with movement of the eye (Fig. 1). The

right lens of the 14-year-old patient was removed by intracapsular extraction without the use of α -chymotrypsin, and no intact zonules were noted during surgery.

Material and methods

The lens was fixed in 10 per cent neutral, buffered formalin, and segments were prepared for both scanning and transmission electron microscopy. Following dehydration in graded alcohols and propylene oxide, samples for transmission electron microscopy were embedded in Epon 812, sectioned, and examined on a Philips 300 electron microscope. Tissue samples for scanning electron microscopy were similarly dehydrated and dried following the camphene sublimation technique of Watters and Buck (1971). This tissue samples were then glued on to specimen stubs, rotary coated with a thin conducting layer of gold *in vacuo*, and examined in a Cambridge (Stereoscan) Mark IIa scanning electron microscope, operated at 10 KV.

Results

The appearance of a fringe of zonular remnants at the equator of the lens and the insertion of these zonules into the lens capsule is demonstrated by scanning electron microscopy, Figs 2(a) and (b). All the zonular tags which comprised the lens fringe were observed to arise from the anterior lens capsule (Fig. 2a). None of the zonules was found to take its origin from the posterior lens capsule, although clumps of disorganized zonular material were present on the posterior capsule surface (Fig. 2b).

The zonules, even under moderate magnification, appeared to be normal (Fig. 3); however, under high magnification, all of the zonular remnants had an abnormal, porous, sponge-like appearance (Fig. 3, inset).

Transmission electron microscopy revealed the zonular remnants to be composed of masses of short filaments in disarray (Fig. 4), together with the presence of occasional bundles of normal-appearing zonular filaments (Fig. 4, inset). The disorganized structure of the zonular tags was observed throughout their length up to and including their termination in

Address for reprints: Dr Michael S. Ramsey, Department of Ophthalmology, 5788 University Avenue, Halifax, Nova Scotia, Canada B3H 1V8

¹ Aided by a grant from the Canadian National Institute for the Blind out of the E.A. Baker Foundation for the Prevention of Blindness.

² Supported by grants from the Medical Research Council of Canada and the Canadian National Institute for the Blind out of the E.A. Baker Foundation for the Prevention of Blindness.

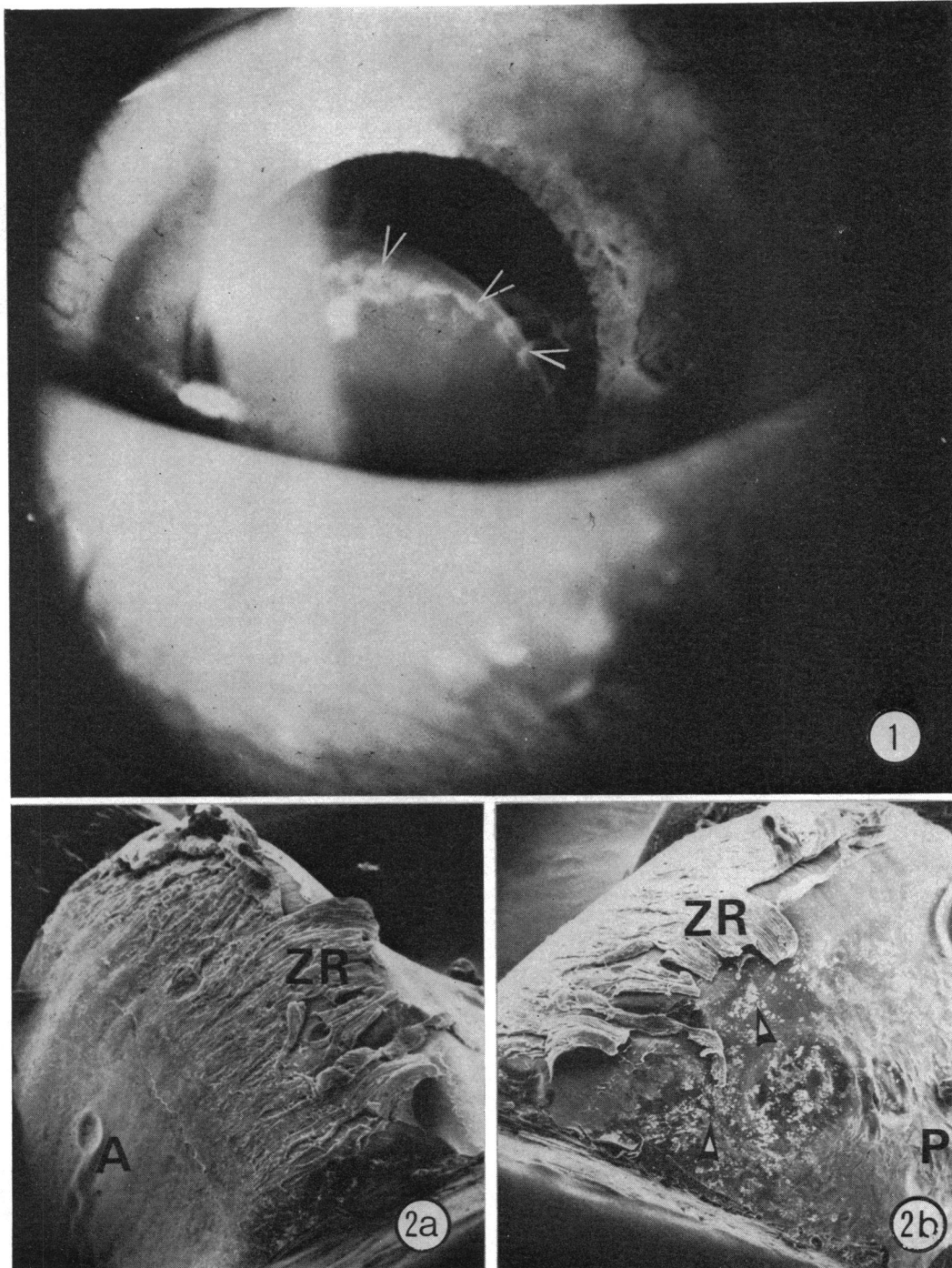


FIG. 1 Right eye of 14-year-old patient with homocystinuria. Superior pole of the subluxated lens shows presence of white zonular remnants (arrows)

FIG. 2(a) and (b) Low power scanning electron micrograph of one quarter of homocystinuric lens, from Fig. 1. FIG. 2(a) View of anterior (A) lens surface, where fringe of zonular remnants (ZR) is observed at equator, with insertions into anterior lens capsule. $\times 45$. FIG. 2(b) View of the posterior (P) lens surface. The anterior zonular remnants (ZR) viewed in Fig. 2(a) can be seen at the lens equator. No zonules were found to take their origin from posterior lens capsule, although small white clumps of disorganized zonular material were present on posterior surface (arrows). $\times 45$

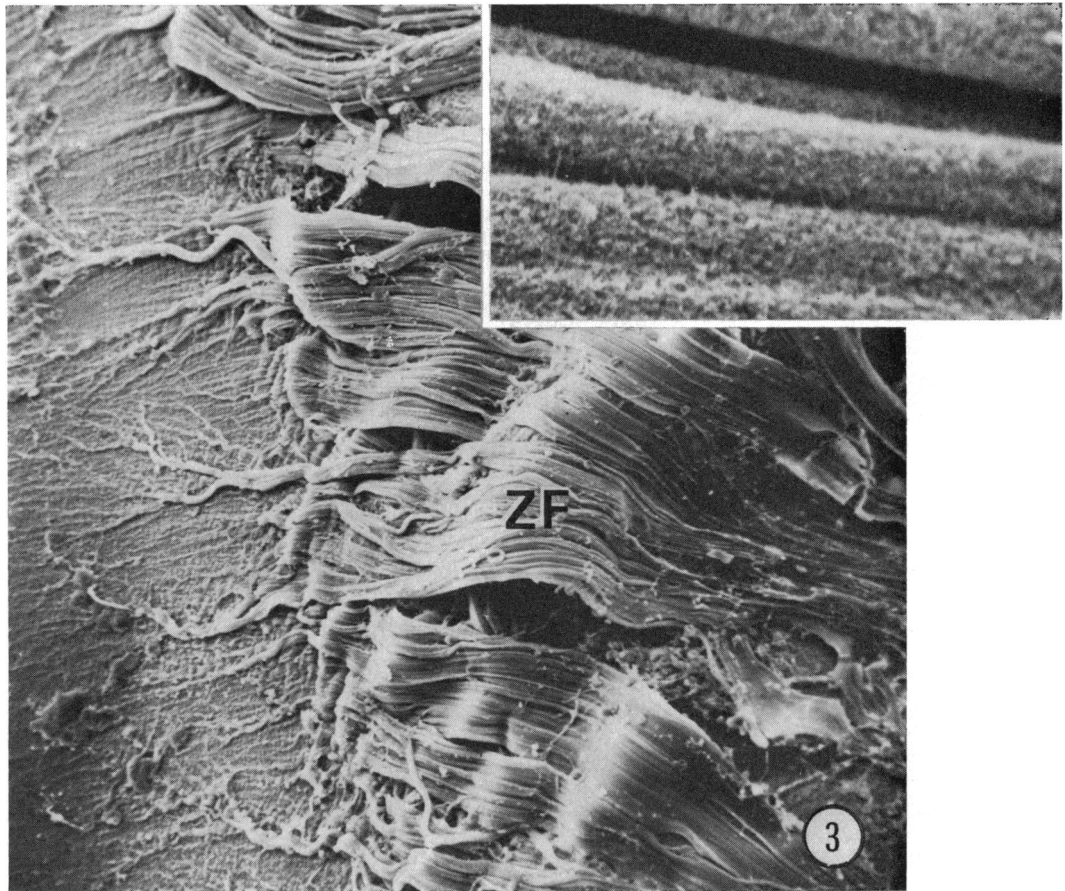


FIG. 3 Scanning electron micrographs of zonular remnants from dislocated homocystinuric lens of Fig. 1. At moderate magnification, the zonular fibres (ZF) appeared normal, however when viewed at higher magnification (inset), all zonular remnants had abnormal porous, sponge-like appearance. $\times 175$ (Inset $\times 4200$)

the lens capsule (Figs 4 and 5). Although a pericapsular membrane (zonular lamella) could not be identified, the remainder of the lens capsule and epithelium appeared unremarkable (Fig. 5).

Discussion

Ramsey and others (1972) have demonstrated that the zonules in homocystinuria undergo degeneration, resulting in a mixture of very short, disorganized filaments, together with a few aligned groups of filaments similar to those present in normal zonules. Their study suggested that age is a factor in the makeup of the mixture. As the patient age increased, fewer normal appearing aligned filaments were observed. The studies of both Henkind and Ashton (1965) and Ramsey and others (1972) have looked at the zonular remnants attached to the ciliary body. The present study reveals that the fringe-like zonular remnants on the lens have a similar structure

characterized by very short filaments in disarray, with occasional normal appearing zonular filaments. Furthermore, it is observed that these zonules are abnormal in appearance throughout their length, up to and including their insertions into the lens capsule.

It is believed that the structural change from highly aligned filaments to short disorganized fragments would account for the opaque, white appearance of the zonular fringe. This is substantiated by the fact that the zonule in ectopia lentis, associated with the Marfan syndrome, does not appear to undergo degeneration (Ramsey, Fine, Shields, and Yanoff, 1973) and usually remains transparent.

Since a pericapsular membrane could not be identified in this homocystinuric lens, it is assumed that it has undergone degeneration similar to the zonular ligaments and is therefore not separately identifiable from the altered zonular remnants. This evidence may support the hypothesis that the pericapsular membrane is zonular in origin (Duke-

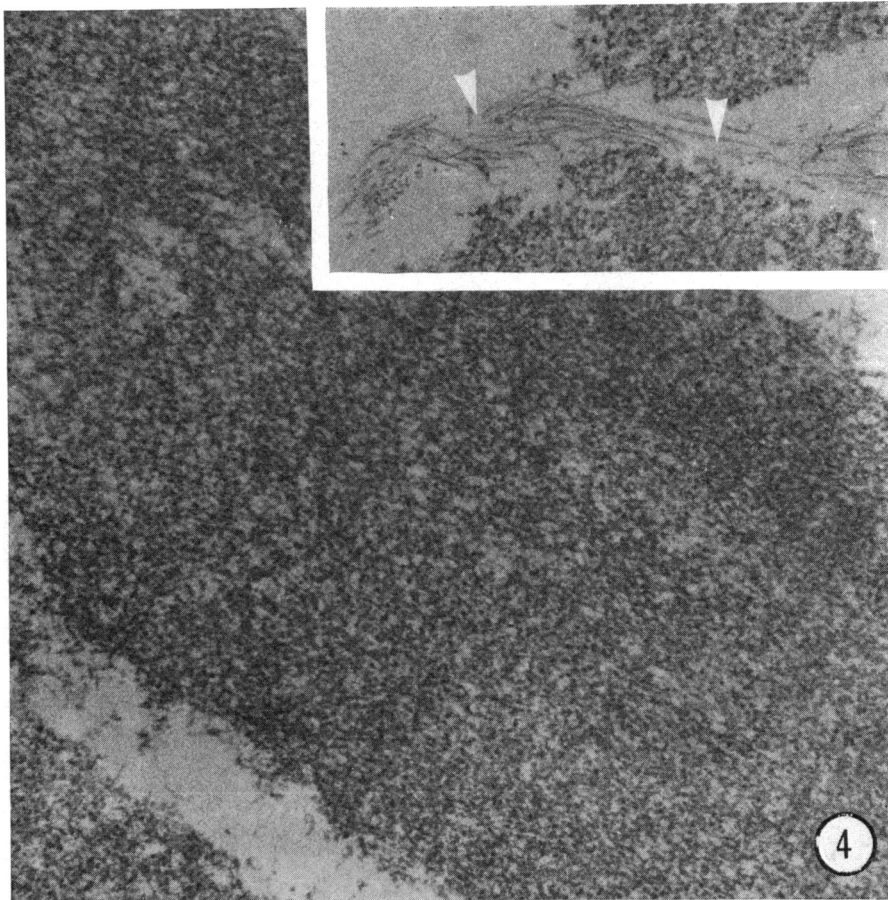


FIG. 4 Transmission electron micrographs of homocystinuric zonular remnants from Fig. 3. Zonular material is composed of masses of short disorganized filaments; occasional bundles of normal-appearing zonular filaments are observed (inset-arrows). $\times 49\ 300$ (Inset $\times 32\ 500$)

Elder and Cook, 1963) and not derived from the lens epithelium as has been suggested by Mann (1964).

It is difficult at this point to speculate about the factors which cause zonular breakages, resulting in a lens fringe of opaque zonular remnants. This fringe may however be characteristic, if not pathognomonic, for homocystinuria.

Summary

The lens from a patient with homocystinuria was

examined by scanning and transmission electron microscopy. A fringe of zonular remnants was found attached to the anterior lens capsule, and was observed to be composed of masses of short filaments in disarray, together with occasional bundles of normal-appearing zonular filaments. Although a pericapsular membrane (zonular lamella) was not observed, the remainder of the lens capsule and epithelium appeared unremarkable. The lens fringe of white zonular remnants may be characteristic, if not pathognomonic, for homocystinuria.

References

- BEATON, J. W., RAMSEY, M. S., and DAITZ, L. D.—In preparation for submission to *Canad. J. Ophthalm.*
 CARSON, N. A. J., and NEILL, D. W. (1962) *Arch. Dis. Childh.*, **37**, 505
 DUKE-ELDER, S., and COOK, C. (1963) 'System of Ophthalmology', vol. 3, Pt. 1, Kimpton, London
 HENKIND, P., and ASHTON, N. (1965) *Trans. ophthal. Soc. U.K.*, **85**, 21
 MANN, I. (1964) 'The Development of the Human Eye', 3rd ed., BMA, London

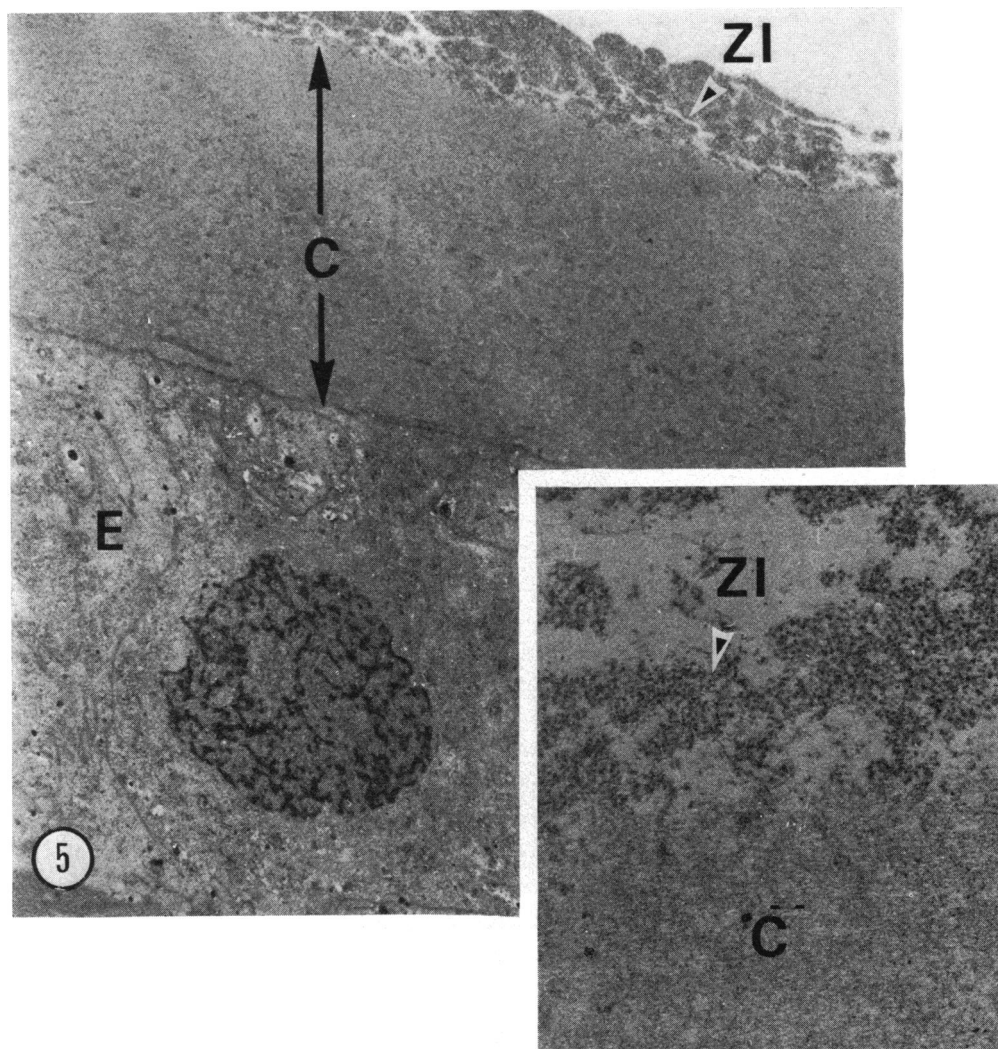


FIG. 5 Transmission electron micrographs of homocystinuric lens from Fig. 1, showing a normal epithelium (E) and capsule (C). However, zonular insertions (ZI) into capsule are abnormal, being composed of masses of short, disorganized filaments; as well, a distinct pericapsular membrane was not observed (inset). $\times 8900$ (Inset $\times 32\ 580$)

MUDD, S. H., FINKELSTEIN, J. D., IRREVERRE, F., and LASTER, L. (1964) *Science*, **143**, 1443

———, LEVY, H. L., and MORROW, G. (1970) *Biochem. Med.*, **4**, 193

———, ULENDORF, B. W., FREEMAN, J. M., FINKELSTEIN, J. D., and SHIH, V. E. (1972) *Biochem. biophys. Res. Com.*, **46**, 905

RAMSEY, M. S., DAITZ, L. D., and BEATON, J. W. (1975) *Arch. Ophthalm. (Chicago)*, **93**, 318

———, FINE, B. S., SHIELDS, J. A., and YANOFF, M. (1973) *Amer. J. Ophthalm.*, **76**, 102

———, YANOFF, M., and FINE, B. S. (1972) *Ibid.*, **74**, 377

WATTERS, W. B., and BUCK, R. C. (1971) *J. Microsc.*, **94**, 185