

Ross' syndrome (tonic pupil plus)

THOMAS R. HEDGES AND EDWARD W. GERNER

From the Pennsylvania Hospital and the Department of Ophthalmology, University of Pennsylvania, Philadelphia

The tonic pupil is generally defined as a pupil that is:

- (a) found usually in 20 to 40-year-old women,
- (b) unilateral in 90 per cent of cases,
- (c) larger than the uninvolved pupil in lighted surroundings and smaller in unlighted surroundings,
- (d) essentially unresponsive or sluggish to light and with a stronger reaction to near,
- (e) often associated with altered deep tendon reflexes (Hedges, 1968).

It has often been emphasized that the tonic pupil is a benign condition without systemic implications (Holmes, 1931; Scheie and Albert, 1969). Recent descriptions of segmental anhidrosis or hypohidrosis in patients with tonic pupils and altered deep tendon reflexes (Ross' syndrome) (Ross, 1958) and the examination of two patients with these findings have prompted this report and a consideration of the place of Ross' syndrome with the other dysautonomias ranging from the isolated and uncomplicated tonic pupil through the Shy-Drager syndrome and the syndrome of pan-dysautonomia.

Report of cases

PATIENT 1

A 35-year-old woman was referred to one of us (TRH) by Dr Albert Wagman of Abington Hospital, Abington, Pennsylvania in May 1972 for anisocoria with an unreactive pupil on the right, first noted in April 1971. The patient had been aware of excessive sweating, particularly when upset, over the right brow. When aged 31 years, after the birth of a child by Caesarean section, she became aware of the absence of sweating on the upper part of the trunk on the right, including the right arm. There was no history of bladder or bowel dysfunction, heat intolerance, or orthostatic hypotensive symptoms. At the time of the onset of the anhidrosis the patient was 'depressed' and sought psychiatric consultation. The family history was non-contributory. Physical examination revealed that there was no sweating on the right side of the face (except for the right brow) and none on the upper trunk on the right to T-7 level and the right arm. The knee and ankle jerks were absent bilaterally even with reinforcement. The remainder of the general physical and neurological

examination was normal. When seen in May 1972, the right pupil was smaller than the left in dim illumination and larger in a well-lighted room, and did not respond to light either directly or consensually (Fig. 1). The left pupil was also very sluggish in response to light. Both pupils responded to near (Fig. 2) but the reaction on the right was sluggish. Near points of accommodation were equal. A 2.5 per cent solution of methacholine chloride caused marked miosis bilaterally and pilocarpine 0.25 per cent also showed a very positive response bilaterally (Fig. 3). Neosynephrine 10 per cent resulted in dilatation bilaterally. The serology, blood sugar, protein-bound iodine, spinal tap, skull and cervical spine x rays, and electroencephalogram were all normal. There has been no change in the patient's status during the past 2 years. She was last seen in April 1974.

PATIENT 2

This 60-year-old woman was seen in consultation by one of us (TRH) on 11 November 1973 for anisocoria. She had been aware of the left pupil being larger and not responsive to light ever since childhood. At the age of 46 years, after severe emotional trauma (mother's suicide), she noted decreased sweating on the right side of the body and excessive sweating on the left. There were no symptoms of heat intolerance, bladder or bowel dysfunction, or orthostatic hypotension. She has two children and no other members of the family have similar difficulties. On examination, blood pressure was normal without orthostatic changes. She had decreased sweating over the entire right side of the body. The knee jerks were hypoactive bilaterally and the ankle jerks were absent bilaterally even with reinforcement. The left pupil was smaller than the right in room light but larger in dim light and did not react to light either directly or consensually (Fig. 4). The left pupil was sluggishly reactive to near and re-dilated very slowly. Near points of accommodation were equal. The methacholine chloride (2.5 per cent) test and the 0.25 per cent pilocarpine test showed a positive reaction on the left (Fig. 5). The serology, blood sugar, and skull x rays were normal. This patient's signs have not 'progressed' or altered in any way in the 15 years since the anhidrosis was superimposed upon the pupillary anomaly noted since childhood.

Discussion

Strasburger (1902) described a non-syphilitic young man with a unilateral dilated pupil which constricted slowly to both light and near, and dilated slowly

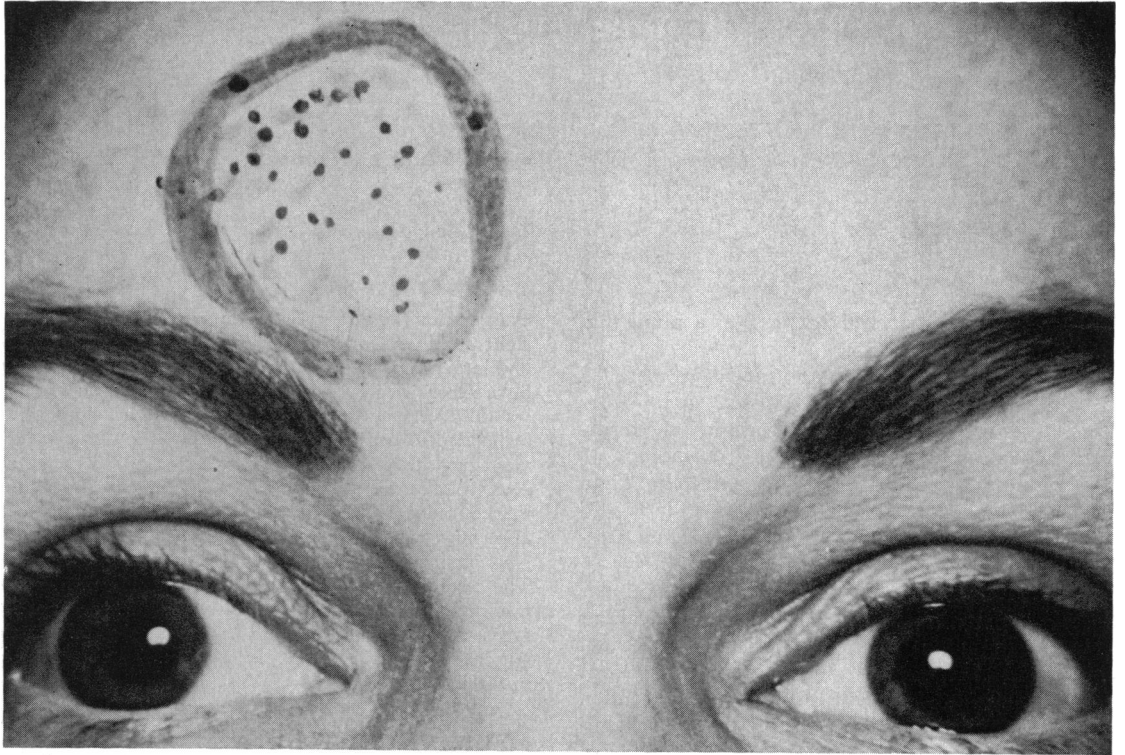


FIG. 1 *Patient 1. Dim illumination—right pupil smaller than left. Stippled area shows area of hyperhydrosis in facial area of anhydrosis on the right*

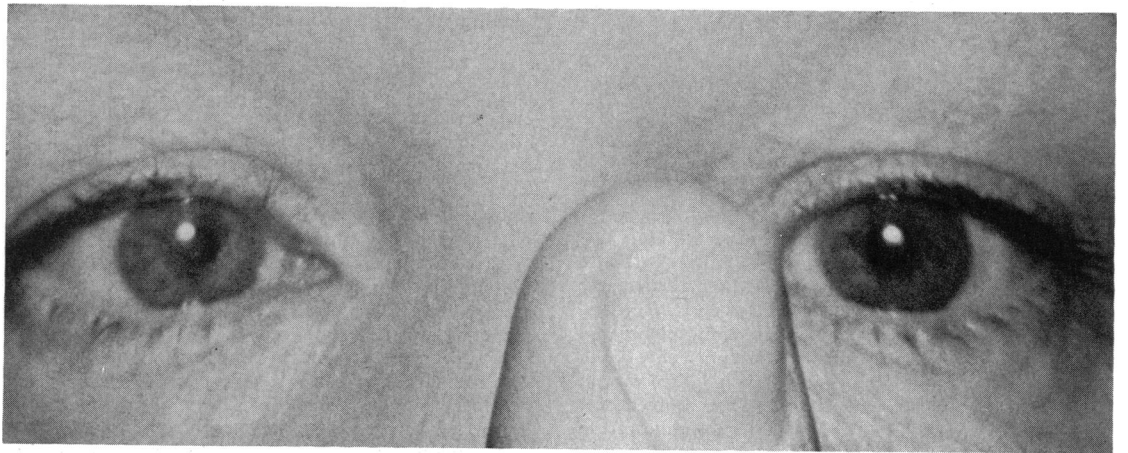


FIG. 2 *Patient 1. Light—near dissociation showing good reaction to near*

when the stimuli were removed. Nonne (1902) and then Markus (1906) described this peculiar pupillary movement and noted its association with absent ankle and knee jerks. This association of absent deep tendon reflexes with a myotonic pupil is most widely known by the eponym of Adie's syndrome after the

man who emphasized the relationship between these two findings. Adie (1932) in his original paper, also emphasized the benign, non-progressive nature of this condition—an idea which has persisted to the present day.

After Adie's report, additional cases were added to

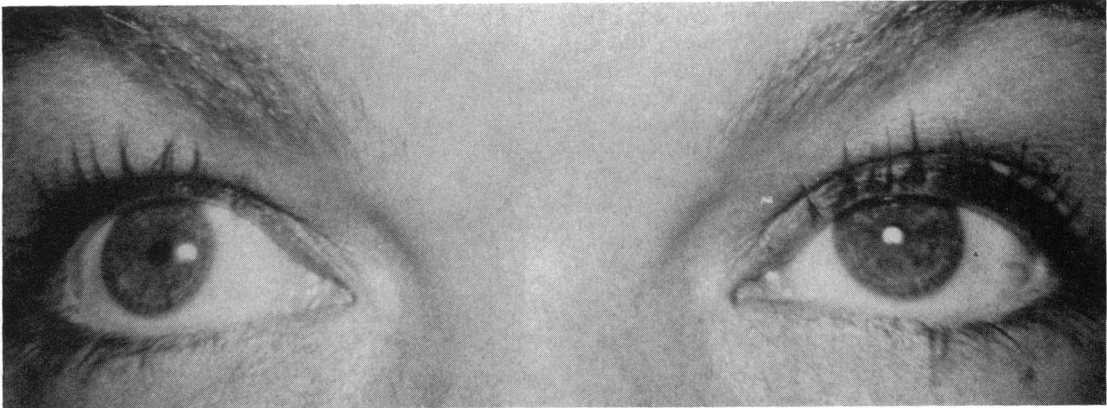

FIG. 3 Patient 1. Positive reaction (moiosis) to 2.5 per cent mecholyl and $\frac{1}{4}$ per cent pilocarpine bilaterally

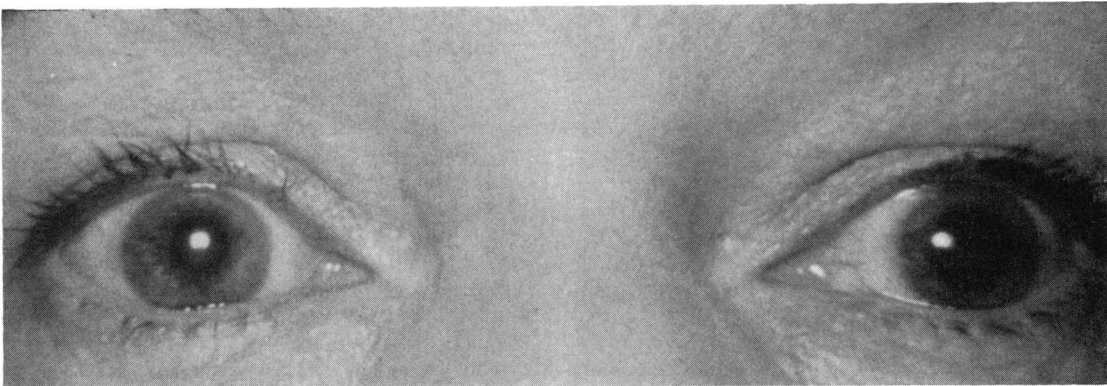

FIG. 4 Patient 2. Left pupil in dim light larger than right (reverse in bright light) did not react to light directly or consensually

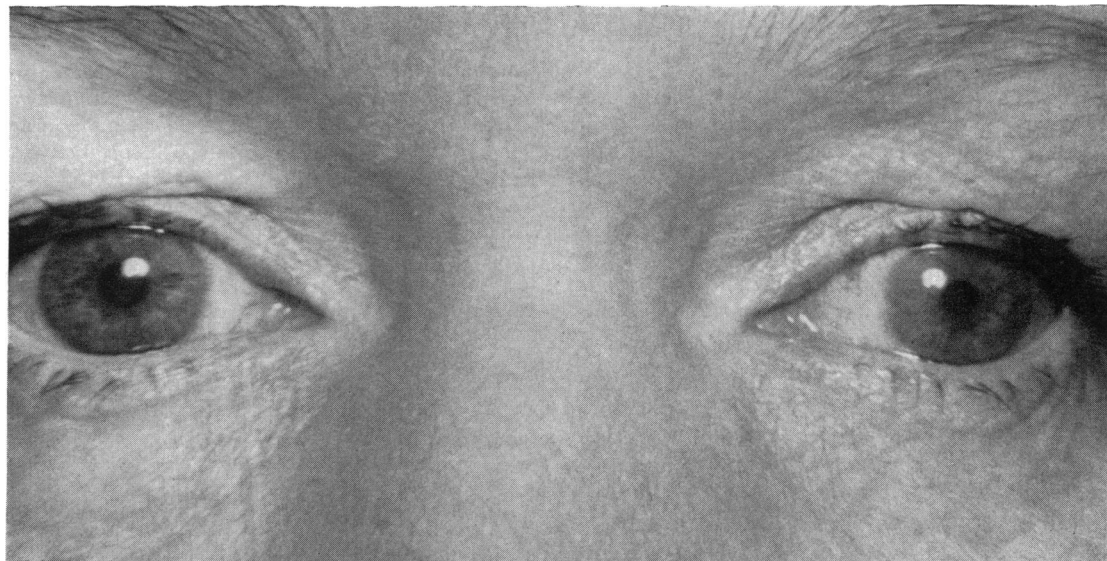

FIG. 5 Patient 2. Positive miotic reaction on the left to mecholyl $\frac{1}{4}$ per cent and pilocarpine $\frac{1}{4}$ per cent

the literature but of particular interest were the occasional findings, as noted by Kennedy, Wortis, Reichard, and Fair (1938) of vasomotor instability, absent oculo-cardiac reflex, and emotional instability in some of these patients. Indeed, these findings were so prominent in some of his patients that Kennedy postulated a lesion in the hypothalamus.

Starting from a solid understanding of pharmacology and the classic work in denervation hypersensitivity, Scheie (1940) described the use of a 2.5 per cent solution of methacholine chloride to demonstrate denervation hypersensitivity in tonic pupils. The positive response of tonic pupils to this weak solution led the author to postulate that the lesion in Adie's syndrome was situated either in the ciliary ganglion or in the post-ganglionic fibres. Subsequent pathological studies demonstrated neuronal degeneration in the ciliary ganglion in Adie's syndrome and thus supported his postulate (Harriman and Garland, 1968). The lesion responsible for the absence of deep tendon reflexes in Adie's syndrome has never been clearly delineated. However, physiological studies (Walsh and Hoyt, 1969) point to a segmental spinal cord lesion. It was curious, therefore, that more extensive symptoms were not associated with the syndrome.

When Ross (1958) first noted segmental anhidrosis in a patient with a tonic pupil and hyporeflexia, he believed it to be only a chance association, particularly since the patient had had the tonic pupil for 21 years before developing the anhidrosis. Petajan, Danforth, D'Allesio, and Lucas (1965), in a subsequent case report of Ross' syndrome, suggested that the relationship of progressive segmental loss of sweating with Adie's syndrome was, in fact, not fortuitous. This opinion has been supported by additional case reports (Bonnin, Skinner, and Whelan, 1961; Hardin and Gay, 1965; Lucy, Van Allen, and Thompson, 1967; Esterly, Cantolino, Alter, and Brusilow, 1968). Moreover, the fact that sweat glands are cholinergically innervated (although part of the sympathetic nervous system) would point to an, as yet, undefined degenerative process of the autonomic nervous system (Petajan and others, 1965). This is not to suggest, however, that the symptoms need be serious or that the process is invariably progressive. Long-term reports of patients

with Adie's syndrome suggest that longevity is not incompatible with the condition nor is it necessarily progressive (Weber, 1933; Laties and Scheie, 1965). However, it would now appear that the condition may not be benign in all individuals and long-term follow-ups may be necessary to determine the eventual outcome.

In addition to the three primary findings constituting Ross' syndrome (tonic pupil, progressive segmental hypohidrosis, and hyporeflexia), orthostatic hypotension has been associated with the condition (Croll and Duthie, 1935; Laufer, 1942; Barnett and Wagner, 1958). In reviewing the case reports, it was of interest to note that several of the patients may have had even more extensive evidence of autonomic dysfunction. Indeed, Bradbury and Eggleston (1925) speculated that there might be 'some extensive and peculiar disturbance in the functional activity of the vegetative nervous system'. These findings shade into even more extensive conditions. Diseases of the autonomic nervous system such as Shy-Drager syndrome (Shy and Drager, 1960) and acute autonomic or pan-dysautonomic neuropathy (Thomashefsky, Horwitz, and Feingold, 1972; Young, Asbury, Adams, and Corbett, 1969; Wichser, Vijayan, and Dreyfus, 1972; Appenzellar and Kornfeld, 1973; McIlwain, 1966) cause incapacitating widespread difficulty as well as being associated with a tonic pupil (Table). Neither of our patients, however, had overt evidence of more extensive autonomic nervous system dysfunction at this time.

The association of emotional instability with Adie's syndrome in some patients has been commented upon (Kennedy and others, 1938; Laufer, 1942). In both our cases there seems to have been a large emotional component in the history. The second patient associated the onset of the hypohidrosis with a psychiatrically traumatic event. This is not conclusive, however, as the patient may only have become aware of the hypohidrosis at that time and it may, in fact, have preceded the trauma. The association with emotional instability in the first patient is more convincing as the onset of the hypohidrosis was noted by the patient's husband and, also at this time, the patient sought psychiatric help for an apparently transient emotional problem. Perhaps the association of the peripheral autonomic dysfunction with emotion-

Table *Tonic pupil plus*

<i>Syndrome</i>	<i>Tonic pupil</i>	<i>Mecholyl test</i>	<i>Decreased deep tendon reflexes</i>	<i>Orthostatic hypotension</i>	<i>Psychiatric difficulty</i>
Adie	+	+	+	-	+
Ross	+	+	+	+	+
Shy-Drager	+	?	-	+	-
Acute pan-dysautonomia	+	+	-	+	-

al instability is not as remote as it initially appears when it is recalled that acetylcholine is a transmitter within the brain as well as in the peripheral nervous system (Young and others, 1969).

The ophthalmologist, when confronted with patients with a tonic pupil, therefore, should not necessarily dismiss them all as cases of Adie's syndrome and assume they are benign. Inquiry into orthostatic hypotensive symptoms, emotional states, and sweating difficulties should be made. In addition, the finding of bilaterality of tonic pupils should alert the ophthalmologist to the possibility of more widespread problems. Loewenfeld and Thompson (1967), in an extensive review of the tonic pupil, noted that while only 11 per cent of cases of unilateral tonic pupil were 'complex', fully 60 per cent of bilateral cases were 'complex'. In the cases of Ross' syndrome reported to date only the original case had a unilateral tonic pupil; the remainder had bilateral involvement

(Esterly and others, 1968). In our cases, one patient had unilateral involvement while the other had bilateral involvement. Thus it would appear that bilaterality should further heighten the suspicion of a more extensive disease process.

Summary

Two cases of tonic pupil, hyporeflexia, and segmental hypohidrosis (Ross' syndrome) are reported. The relationship of this syndrome to other autonomic dysfunctions is discussed. Those symptoms (emotional instability, loss of sweating, orthostatic hypotensive symptoms, and signs of bilaterality of the tonic pupil) which should alert the clinician to more extensive disease states are noted. It is suggested that these conditions may represent a continuum or spectrum of disorders with a widespread degree of severity and progression.

References

- ADIE, W. J. (1932) *Brit. J. Ophthalm.*, **16**, 449
 APPENZELLAR, O., and KORNFELD, M. (1973) *Arch. Neurol.*, **29**, 334
 BARNETT, A. J., and WAGNER, A. R. (1958) *Amer. Heart J.*, **56**, 411
 BONNIN, M., SKINNER, S. L., and WHELAN, R. F. (1961) *Austr. Ann. Med.*, **10**, 304
 BRADBURY, S., and EGGLESTON, C. (1925) *Amer. Heart. J.* **1**, 73
 CROLL, W. F., and DUTHIE, R. J. (1935) *Lancet*, **1**, 194
 ESTERLY, N. B., CANTOLINO, S. J., ALTER, B. P., and BRUSILOV, S. W. (1968) *J. Pediat.*, **73**, 852
 HARDIN, W. B., and GAY, A. J. (1965) *Neurology (Minneap.)*, **15**, 613
 HARRIMAN, D. G. F., and GARLAND, H. (1968) *Brain*, **91**, 401
 HEDGES, T. R. (1968) *Arch. Ophthalm.*, **80**, 21
 HOLMES, G. (1931) *Trans. ophthal. Soc. U.K.*, **51**, 209
 KENNEDY, F., WORTIS, H., REICHARD, J. D., and FAIR, B. B. (1938) *Arch. Ophthalm.*, **19**, 68
 LATIES, A. M., and SCHEIE, H. G. (1965) *Ibid.*, **74**, 458
 LAUFER, S. T. (1942) *Canad. med. Ass. J.*, **46**, 160
 LOEWENFELD, I. E., and THOMPSON, H. S. (1967) *Amer. J. Ophthalm.*, **63**, 46
 LUCY, D. D., VAN ALLEN, M. W., and THOMPSON, H. S. (1967) *Neurology (Minneap.)*, **17**, 763
 MCILWAIN, H. (1966) 'Biochemistry and the Central Nervous System', 3rd ed., p. 300. Churchill, London
 MARKUS, C. (1906) *Trans. ophthal. Soc. U.K.*, **26**, 50
 NONNE, V. (1902) *Neurol. Zbl.*, **21**, 1000
 PETAJAN, J. H., DANFORTH, R. C., D'ALLESIO, D., and LUCAS, G. J. (1965) *Neurology (Minneap.)*, **15**, 172
 ROSS, A. T. (1958) *Ibid.*, **8**, 809
 SCHEIE, H. G. (1940) *Arch. Ophthalm.*, **24**, 225
 ——— and ALBERT, D. (1969) 'Adler's Textbook of Ophthalmology', 8th ed., p. 328. Saunders, Philadelphia
 SHY, G. M., and DRAGER, G. A. (1960) *Arch. Neurol.*, **2**, 511
 STRASBURGER, I. (1902) *Neurol. Zbl.*, **21**, 738
 THOMASHEFSKY, A. J., HORWITZ, S. J., and FEINGOLD, M. H. (1972) *Neurology (Minneap.)*, **22**, 251
 WALSH, F. G., and HOYT, W. F. (1969) 'Clinical Neuro-ophthalmology', 3rd ed., p. 498. Williams & Wilkins, Baltimore
 WEBER, F. PARKES, (1933) *Proc. roy. Coll. Med.*, **26**, 530
 WICHSER, J., VIJAYAN, N., and DREYFUS, P. M. (1972) *Calif. Med.*, **117**, 28
 YOUNG, R. R., ASBURY, A. K., ADAMS, R. D., and CORBETT, J. L. (1969) *Trans. Amer. neurol. Ass.*, **94**, 355