

Unsuspected fungal endophthalmitis diagnosed in vitrectomy specimen

BARBARA PERINA, GEORGE H. KURZ, AND RAINER N. MITTL
From the Department of Ophthalmology, New York University Medical Center

Mycotic infections of the eye, as in other areas of the body, have been increasing. Nearly 100 different fungal species have been reported in ocular infection (Jones, 1975). This trend has been attributed to many factors including the use of corticosteroids and antibiotics and also to conditions causing decreased host resistance (Anderson, Roberts, Gonzalez, and Chick, 1959; Veirs and Davis, 1958; Rheins, Suie, Van Winkle, and Havener, 1966; Ley and Sanders, 1956; François and Rysselaere, 1972; Wolter, 1962).

The observation of multiple septate hyphae in the microscopical examination of a vitrectomy specimen from a patient in whom endophthalmitis was not suspected before surgery prompted the present report. To our knowledge this is the first account of mycotic endophthalmitis diagnosed from material obtained by vitrectomy.

Report of a case

A 47-year-old White man with diabetes mellitus and mild congestive heart failure had an ocular history which included advanced diabetic retinopathy, recent vitreous haemorrhage, and neovascular glaucoma. The glaucoma was controlled medically and with penetrating cyclotherapy of the left eye in November 1972. A mild anterior segment reaction followed this procedure and was treated intermittently with topical corticosteroids until January 1974.

On examination in January 1974, the vision was right eye: hand movements, and left eye: perception of light with projection. The right eye had rubeosis iridis and proliferative diabetic retinopathy. In the left eye there were minor areas of rubeosis, cataractous changes of the lens, and a dense vitreous haemorrhage. The fundus could not be seen. Ultrasound study of the left eye revealed relatively dense opacities and membranes within the vitreous. Vitrectomy was suggested for the left eye and performed in July 1974, using the roto-extractor (Douvas, 1975).

During the procedure a peculiar dense-white rubbery substance was encountered in multiple areas of the vitreous cavity. Some of this material was submitted to the pathology laboratory. Microscopical examination revealed patches of proteinaceous exudate with large

numbers of closely packed septate fungal hyphae (Figs 1 and 2). A few mycotic granules were observed (Figs 1 and 3). These were considered suggestive, but not diagnostic of coccidioidomycosis. Scattered lymphocytes were noted in some areas in association with the hyphae (Figs 2 and 4). Cultures for fungi were not done.

After this unexpected finding, the patient was put in hospital for a complete medical examination. He denied having any systemic symptoms, and his diabetes and congestive failure were well under control. He denied past or present ocular pain and the general physical examination was unremarkable except for moderate obesity. On examination of the eyes the vision was right eye: perception of light; left eye: no perception of light. Intraocular pressure was right eye 16 and left eye zero by applanation. The right eye had otherwise remained essentially unchanged since January 1974. In the left eye the lids and adnexa were normal. There was marked injection of the conjunctiva, mild microcystic oedema of the cornea, and an organizing haemorrhage involving approximately 90 per cent of the anterior chamber. These findings had been present since the vitrectomy. The blood in the anterior chamber prevented further examination of the eye.

In an attempt to find a possible source of the fungal infection, extensive laboratory studies were done in addition to the medical examination. Complete blood count, urine analysis, and blood cultures were negative. Serum profile was normal except for a raised level of glucose. Conjunctival cultures were negative for fungi. Anterior chamber and vitreous taps were not done. Skin tests for histoplasmosis and coccidioidomycosis were negative. Chest, skull, and sinus x-rays showed no abnormalities. A liver scan revealed an enlarged spleen for which no explanation was found. Microscopical slides from the vitrectomy were reviewed by several mycologists, but the species of fungus could not be positively identified.

During the patient's stay in hospital no evidence of fungal infection could be found elsewhere in the body and two years later he was healthy without systemic complaints. The left eye was phthisical. A follow-up medical examination failed to reveal any coccidioidal lesions.

The patient's record for the two years before the vitrectomy showed no sign of endophthalmitis, although he had been examined by numerous ophthalmologists during the period. An infection of the external ocular structures, specifically corneal ulcer, was never present. There was no history of accidental trauma. The cyclotherapy, which was followed by a mild anterior segment

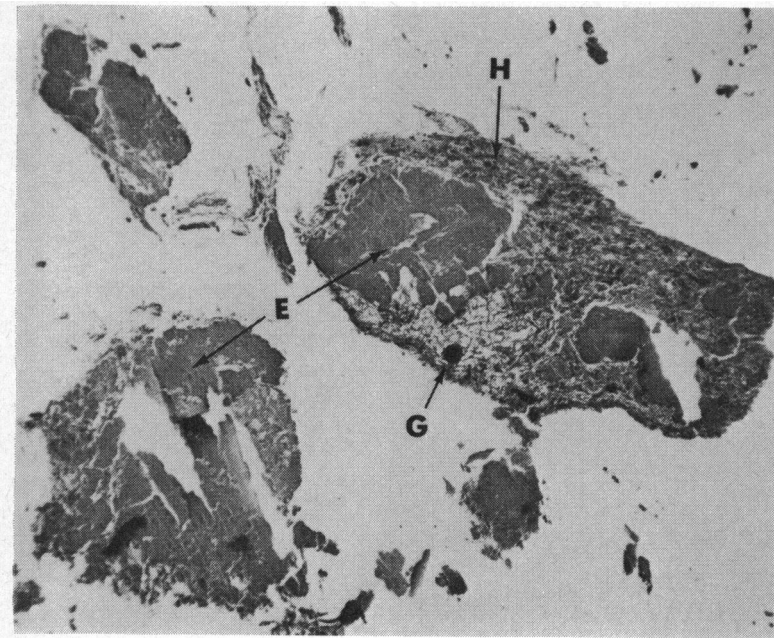


FIG. 1 *Matted hyphae (H), surrounding patches of proteinaceous exudate (E). Mycotic granule (G). Haematoxylin and eosin. × 35*

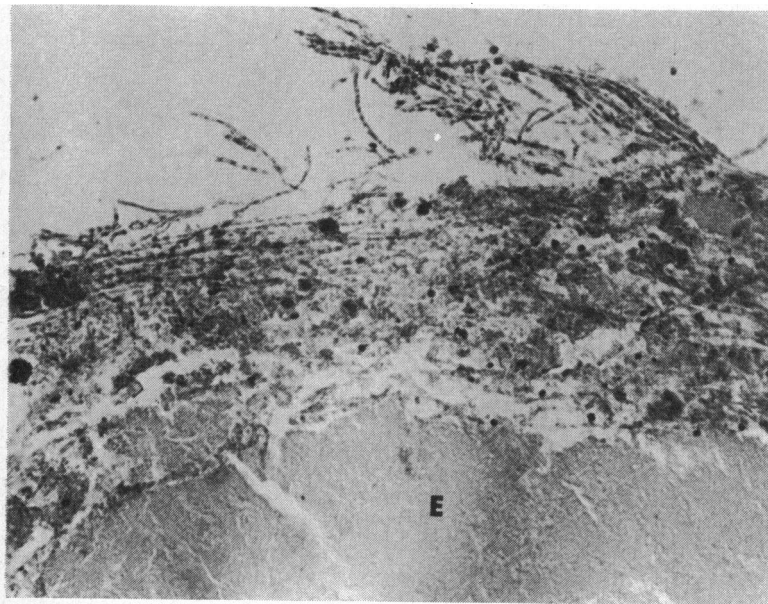


FIG. 2 *Densely packed septate hyphae with scattered lymphocytes Exudate (E). Haematoxylin and eosin. × 224*

reaction, preceded the vitrectomy by 20 months. Fungal endophthalmitis after cyclodiathermy has not been reported to our knowledge. We believe it unlikely, although not inconceivable, that the fungi gained entrance to the eye at the time of the cyclodiathermy in this case.

Discussion

The hyphae encountered in the microscopical

sections are believed to reflect the true disease rather than a contaminant for the following reasons: their presence on all slides of this case; their intimate association with the eosinophilic exudate; their large number; absence of fungal contamination of other cases concurrently processed in the laboratory; the presence of mycotic granules; the presence of lymphocytes, and the unusual density and difficulty cutting the membranes encountered

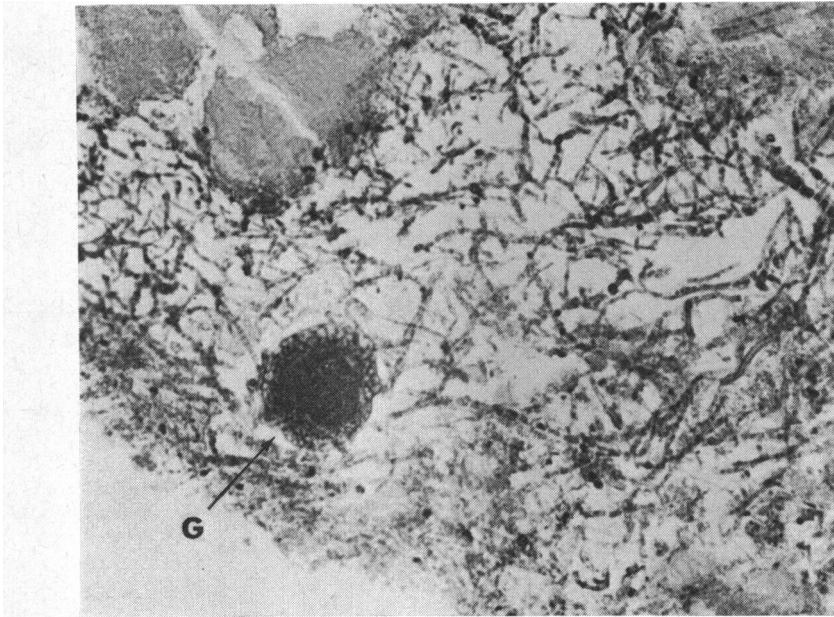


FIG. 3 *Mycotic granule (G) amid multiple septate hyphae. Haematoxylin and eosin. × 224*

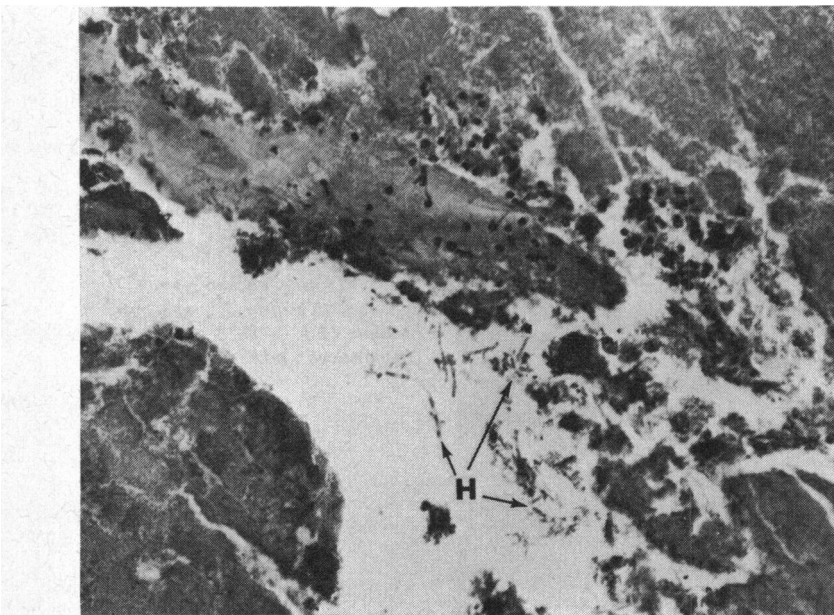


FIG. 4 *Scattered lymphocytes in proteinaceous exudate. Small number of hyphae (H). Haematoxylin and eosin. × 224*

during surgery, making the procedure much longer than anticipated.

Intraocular infections caused by fungus (McClellan, 1963) may result from:

1. Direct invasion of the external ocular structures with resulting fungal conjunctivitis, fungal keratitis, and fungi in the lacrimal passages. Infection may then spread to deeper tissues.

2. Extension from neighbouring areas, such as the skin of the face, nasopharynx or sinus, extending into the orbit.
3. Exogenous route: or direct introduction intraocularly, either traumatic or surgical, most commonly after cataract surgery.
4. Endogenous route: or haematogenous route. This may be considered in cases in which there is no infection of the cornea or adnexa

and there is no history of ocular surgery or trauma. It may be subdivided into two types:

- A. Ocular involvement with an overt source.
- B. Ocular involvement with an occult source.

Oculomycosis, as a complication of intraocular surgery (Theodore, Littman, and Almeda, 1961; 1962) and traumatic injury (Fine and Zimmerman, 1959), is being recognized with increasing frequency. Endogenous endophthalmitis is less frequently recognized (Bonatti, Jaeger, and Frayer, 1963; Harley and Mishler, 1959). Our case appears to fall into the last category: endogenous intraocular infection without apparent systemic involvement.

Intraocular infections caused by coccidioidomycoses have been reported as cases of uveitis and chorioretinitis (François and Rysselaere, 1972). In 1958, a case was presented of a patient with generalized coccidioidomycosis with a granulomatous uveitis (Brown, Kellenberger, and Hudson, 1958). Histopathological examination revealed granulomatous inflammatory nodules in the iris and ciliary body. These nodules contained giant cells with spherules, surrounded by an infiltrate of lymphocytes, plasma cells, and epithelioid cells. Another interesting case of iridocyclitis with iris nodules was reported in 1967 (Pettit, Learn, and Foos, 1967). Cultures of aqueous grew *Coccidioides immitis*. Of note in this case is that there was no evidence of disseminated coccidioidomycosis.

Iris nodules were not noted clinically in our patient before the vitrectomy. After that procedure the patient had almost a total hyphaema, and the iris could not be visualized.

Endogenous intraocular infection due to fungi was considered very rare 15 to 20 years ago. Harley and Mishler (1959) pointed out that only 14 such cases had been reported in the literature and added one case of their own. Fungi were grown from a

systemic site in only one of these cases. In more recent years these infections are being reported more frequently. Freeman, Davis, and Maclean (1974) reviewed the literature on *Candida* endophthalmitis. There were 49 cases and all were reported during the 10-year period 1962-72. Systemic involvement was found in 14 patients and was questionable in 5; 30 had no evidence of systemic fungal involvement. Ocular symptoms were present in most of the cases. Naidoff and Green (1975) reviewed the literature on 17 patients reported with endogenous *Aspergillus* endophthalmitis. Fourteen of 16 on whom this information was available had some underlying predisposing disease. Ocular symptoms were present in most of the patients.

The most common cause of endogenous fungal endophthalmitis today are the *Candida* species, followed by the genus *Aspergillus*. Some patients with infections secondary to *Candida*, *Aspergillus*, or other mycotic organisms do not have rapidly fatal diseases and may even be asymptomatic. As pointed out recently in the literature, some of the earlier reported cases in which no systemic source was identified, as well as our present case, undoubtedly fit into this category.

Summary

A vitrectomy specimen obtained with the roto-extractor from a diabetic patient with vitreous haemorrhage revealed fungal endophthalmitis on microscopical examination. Endophthalmitis was not suspected before the procedure. Extensive medical examinations failed to reveal any evidence of systemic fungal disease. The case exemplifies endogenous mycotic endophthalmitis of occult origin, the first of its kind, we believe, to be diagnosed in this manner.

References

- ANDERSON, B., ROBERTS, S. S., GONZALEZ, C., and CHICK, E. W. (1959) *Arch. Ophthalm.*, **62**, 169
- BONATTI, W. D., JAEGER, E. A., and FRAYER, W. C. (1963) *Ibid.*, **70**, 772
- BROWN, W. C., KELLENBERGER, R. E., and HUDSON, K. E. (1958) *Amer. J. Ophthalm.*, **45**, 102
- DOUVAS, N. G. (1975) *Mod. Probl. Ophthalm. (Basel)*, **15**, 253
- FINE, B. S., and ZIMMERMAN, L. E. (1959) *Amer. J. Ophthalm.*, **48**, 151
- FRANÇOIS, J., and RYSSELAERE, M. (1972) 'Oculomycoses, Factors Which Favor Mycotic Infection'. Thomas, Springfield
- FREEMAN, J. B., DAVIS, P. L., and MACLEAN, L. D. (1974) *Arch. Surg.*, **108**, 237
- HARLEY, R. D., and MISHLER, J. E. (1959) *Trans. Amer. Acad. Ophthalm. Otolaryng.*, **63**, 264
- JONES, B. R. (1975) *Ibid.*, **79**, 15
- LEY, A. P., and SANDERS, T. E. (1956) *Arch. Ophthalm.*, **56**, 257
- MCCLEAN, J. M. (1963) *Amer. J. Ophthalm.*, **56**, 537
- NAIDOFF, M. A., and GREEN, W. G. (1975) *Ibid.*, **79**, 502
- PETTIT, T. H., LEARN, R. N., and FOOS, R. Y. (1967) *Arch. Ophthalm.*, **77**, 655
- RHEINS, M. S., SUIE, T., VAN WINKLE, M. G., and HAVENER, W. H. (1966) *Brit. J. Ophthalm.*, **50**, 533
- THEODORE, F. H., LITTMAN, M. L., and ALMEDA, E. (1961) *Arch. Ophthalm.*, **66**, 163
- , ———, and ——— (1962) *Amer. J. Ophthalm.*, **53**, 35
- VEIRS, E. R., and DAVIS, C. T. (1958) *Arch. Ophthalm.*, **59**, 172
- WOLTER, J. R. (1962) *Ibid.*, **68**, 337