

## Uveal colobomata and Klinefelter syndrome

M. S. HASHMI AND A. G. KARSERAS

*From the University Department of Ophthalmology Welsh National School of Medicine*

Most multiple congenital abnormality syndromes associated with uveal colobomata have their origins dating from before intrauterine development. Causative genetic and chromosomal influences were reviewed (James, Karseras, and Wybar, 1974), but associated abnormalities of the sex chromosomes were not observed in their series and are a rare occurrence in the literature. It is of interest therefore to record uveal colobomata occurring in a patient with Klinefelter syndrome and to discuss the possible implications. This association has not been recorded in Britain previously.

### Material and methods

#### CASE REPORT

A 17-year-old White youth presented with concern about the lack of development of his external genitalia. Bilateral iris colobomata had been noted at birth and he had attended an ophthalmologist from that time. He had been wearing contact lenses for three years.

The parents were unrelated and there was no family history of ocular abnormality. Examination of both parents revealed normal eyes. The father and mother were both 45 years old at the time of his conception.

There was one normal brother, three years older, and the mother had had a diagnostic x-ray of the pelvis during the pregnancy of this child.

#### CLINICAL FINDINGS

The patient was of normal intelligence, pleasant personality, and heavily built (Figs 1 and 2). He weighed 79.3 kg and was 5 ft 8½ in (175 cm) in height. He did not shave and had a high-pitched 'unbroken' voice. Axillary hair was scanty and pubic hair had a female distribution (Fig. 3). There was a mild gynaecomastia (Fig. 2). The penis was 6 cm in length, the testes 2.5 cm (Figs 3 and 4). Hormonal investigation revealed a pattern characteristic of late Klinefelter syndrome:

Plasma testosterone 167 mg/100 ml (normal 300 to 1200 mg/100 ml)

Plasma follicle stimulating hormone 19 units/litre (normal 5 to 10 units/litre)

Plasma luteinizing hormone 22.5 units/litre (normal 5 to 10 units/litre).

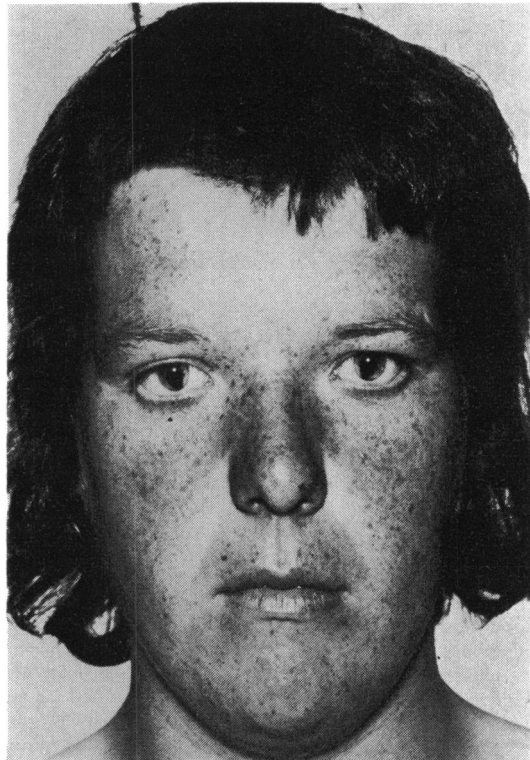

FIG. 1 *The patient*

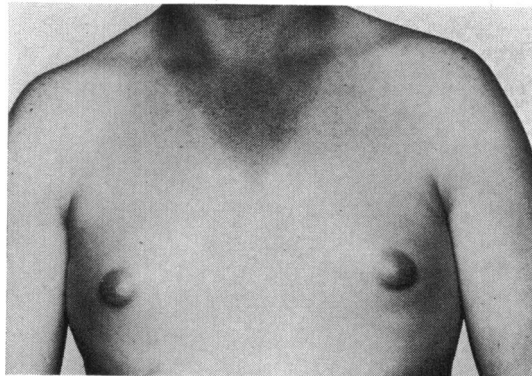
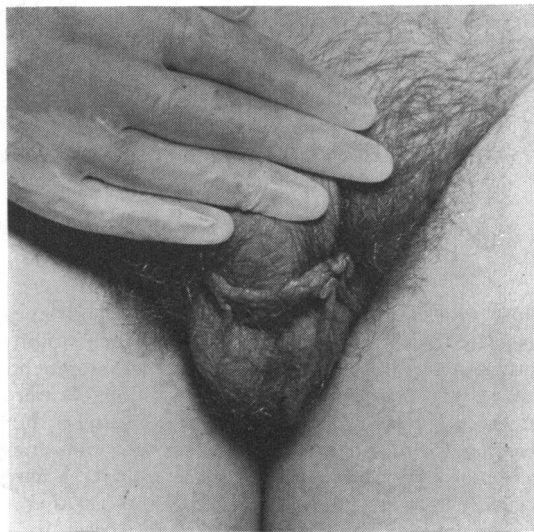
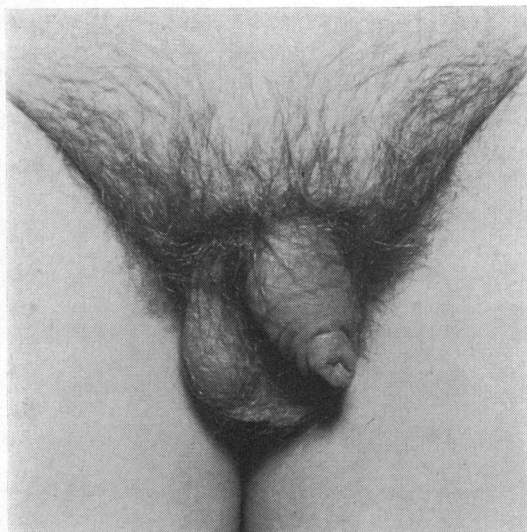
FIG. 2 *Photograph showing physique of patient*



FIGS 3 and 4 Photographs showing underdeveloped genitalia

**OPHTHALMIC FINDINGS**

A right/alternating divergent squint was present. There were bilateral colobomata involving the iris and choroid (Figs 1 and 5). Although the choroidal colobomata did not quite extend to the optic discs, both discs were abnormal. The right disc and approximating colobomata are shown in Figs 6 and 7. Corrected visual acuity with -2.5D contact lenses was 6/36 right eye and 6/9 left.

**CYTOGENETIC FINDINGS**

The chromosomes of lymphocytes of a 72-hour peripheral blood culture were examined. One hundred satisfactory metaphase spreads were counted. In 98 cells there were 47 chromosomes (Fig 8). The extra chromosome belonged to the C group, and was identified as an X-chromosome by the trypsin Giemsa banding technique.

Two counts revealed 46 chromosomes, one was minus a G-group chromosome (? 46 XX) one was minus a C-group chromosome (? 46 XY). These were felt to be due to random loss rather than mosaicism.

**Discussion**

The association of Klinefelter syndrome and uveal

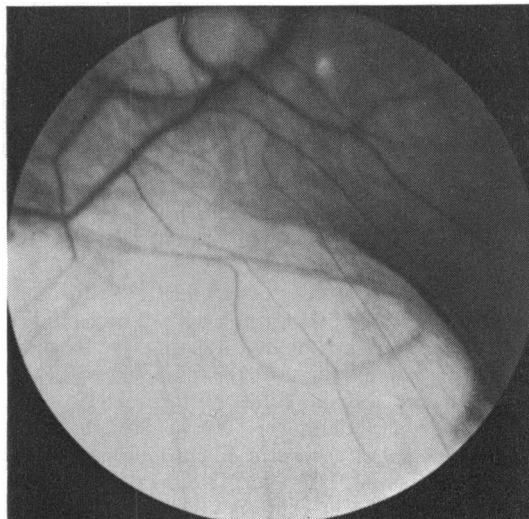
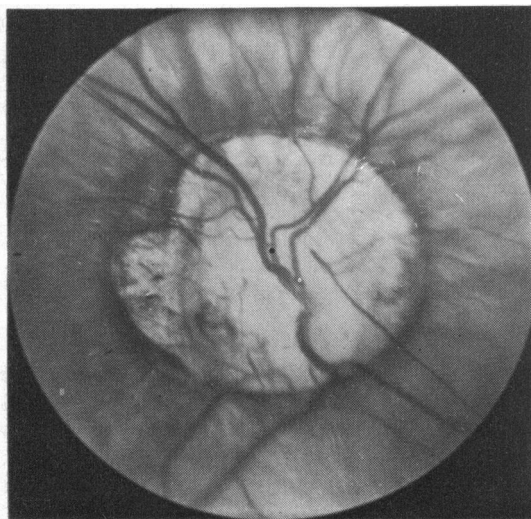
colobomata has been recorded previously (François, Matten-Van Leuven, and Gombault, 1970). It is a rare association but these authors recorded the fourth case in the literature, and after reviewing the incidence of uveal colobomata and Klinefelter syndrome as separate entities, they concluded that the probability of a chance association was in the region of one in six million. They felt that the coloboma might occasionally be part of the phenotypic expression of Klinefelter syndrome. The association of two preuterine induced conditions (see below) enhances the view that this is not a chance association.

The theoretical possibilities which might explain the association of uveal colobomata with Klinefelter syndrome are:

1. The mother may have been a carrier of the X-linked gene for uveal colobomata, and the patient may have been homozygous for this gene ( $X^{M1}X^{M1}Y$ ). However, there was no family history of colobomata in the mother's family and the other manifestations of this X-linked gene (Goldberg and McKusick, 1971) such as mental

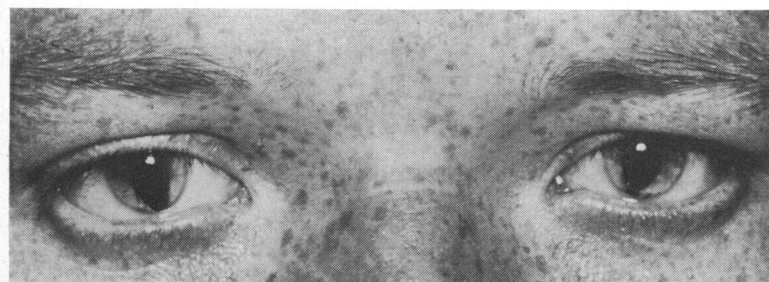

FIG. 5 Photograph showing bilateral colobomata involving the irides



FIGS 6 and 7 *The right disc and approximating colobomata*

retardation were absent. Furthermore, only 10 per cent of Klinefelter patients have identical X chromosomes from the mother (Hamerton, 1971).

2. The extra X chromosome may occasionally influence the genetic mechanisms involved in the closure of the optic cleft. This theory is supported by the known quantitative effect of heterochromatin on cell growth and development (Mittwoch, 1967) and the association of other closure defects with diverse chromosomal aberrations.

3. The environmental influence which occasioned gametogenetic non-dysjunction may also have had a mutagenic effect on the genetic mechanisms involved in the closure of the optic cup.

Either of the last two possibilities would explain the occasional but not fortuitous association of uveal colobomata with Klinefelter syndrome.

The chromosomes of the patient have been shown to be XXY. Forty per cent of such patients have the extra chromosome derived from non-dysjunction of the male parent during spermatogenesis. In 50 per cent of patients both (non-identical) X chromosomes are derived from the mother indicating that non-dysjunction must have occurred during the primary division of oogenesis (Hamerton, 1971). In the 10 per cent of Klinefelter patients with identical X chromosomes from the mother, non-dysjunction could have occurred during the second

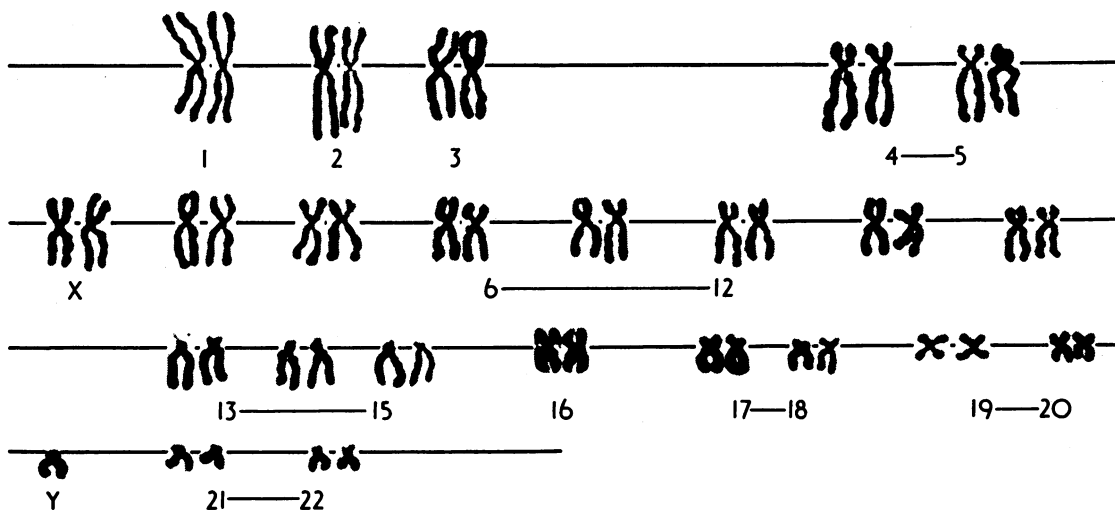


FIG. 8 *Cytogenetic findings*

meiotic division of oogenesis or early after zygote formation. In the latter instance mosaicism would be produced and the non-viable X O cell line would leave an XXY constitution. (François and others (1970) had to consider the possibility of a post-zygotic origin in their case as an apparent mosaicism was present. If the mosaicism was not a cultural artefact, their acknowledged possibility of the mosaicism arising from an imbalanced gamete would seem most likely.)

Thus over 90 per cent of Klinefelter syndromes have an established preuterine origin. These studies have been undertaken by investigating the distribution of the dominant X-linked blood group (Xg) in the parents and the child. Unfortunately, both parents of our patient were Xg negative and the parental source of the extra X chromosome could not be ascertained. However, it remains extremely likely that the patient exhibits yet another example of the association of a preuterine induced, congenital syndrome with the uveal colobomata.

It is of interest to discuss the environmental influences which have been alleged to cause uveal colobomata during early pregnancy. Cullen (1964) described uveal colobomata usually with major limb dysgenesis, occurring as a result of thalidomide. In the absence of a definite thalidomide history (Cullen, 1964—Case 2) major limb defects have been taken as presumptive evidence of a thalidomide origin. However, such defects occurred before the advent of thalidomide (Gilkes and Strode, 1963; Case 7—Table I), and limb abnormalities have often been described in systemic syndromes associated with uveal colobomata (James and others, 1974). Many of the series of patients with limb defects and uveal colobomata reviewed by Cullen (1967) may not be attributable to thalidomide; and Case 2 (Table III) particularly fitted all the clinical criteria for the 'oculo-anal' syndrome and the absence of thalidomide was notable. The 'oculo-anal' syndrome has been shown to have an abnormal chromosomal complement (Schachen-

mann, Schmid, Fraccaro, Mannini, Tiepolo, Perona, and Sartori, 1965).

It may be, as Cullen (1967) suggested, that thalidomide acts primarily not as a teratogenic agent, but in an immunosuppressive capacity and allows normally aborted pregnancies to proceed to term. Such abortions often have chromosomal abnormalities (Howard, Boué, Deluchat, Albert, and Lahov, 1974). It would be interesting, therefore, if chromosomal studies could be undertaken on thalidomide babies, particularly those with colobomatous defects.

The occasional reports of infections, such as herpes simplex during pregnancy, as a cause of uveal colobomata may be chance associations and remain to be substantiated (Fraser and Friedmann, 1967).

The likelihood is that very few uveal colobomata have their primary origin during embryogenesis, and that most arise from inherited genetic, sporadic (mutational) genetic, or chromosomal abnormalities during spermatogenesis and oogenesis. Inquiry into possible environmental agents must therefore include these periods of gametogenesis in the male and female as well as the period of intrauterine development of the fetus.

Treatable endocrine dysgenesis occurring in syndromes where uveal colobomata can occur has been emphasized previously (Karseras and Laurence, 1975). The present patient has suffered great emotional trauma from his defective gonadal development. Fortunately, much of the abnormality of his primary and sexual development is reversible with the administration of testosterone. Sterility, but not impotence, will persist. Earlier diagnosis would have removed much of the patient's concern.

We thank Dr Ruth Sanger for establishing the Xg blood groups in this study, Dr Peter Harper for his helpful criticism of genetic concepts, and Mr Selwyn Roberts for undertaking the cytogenetic analysis. We are grateful to Dr J. Picton Thomas for his permission to publish this case and for his helpful discussion of the endocrine features.

## References

- CULLEN, J. F. (1964) *Brit. J. Ophthalm.*, **48**, 151  
 — (1967) *Brit. orthopt. J.*, **24**, 2  
 FRANÇOIS, J., MATTEN-VAN LEUVEN, M. TH., and GOMBAULT, PH. (1970) *J. med. Genet.*, **7**, 213  
 FRASER, G. R., and FRIEDMANN, A. I. (1967) 'The Causes of Blindness in Childhood: a Study of 776 Children with Severe Visual Handicaps', p. 184. Johns Hopkins Press, Baltimore  
 GILKES, M. J., and STRODE, M. (1963) *Lancet*, **1**, 1026  
 GOLDBERG, M. F., and MCKUSICK, V. A. (1971) *Amer. J. Ophthalm.*, **71**, 1128  
 HAMERTON, J. L. (1971) 'Human Cytogenetics', vol. 1, p. 215. Academic Press, New York and London  
 HOWARD, R. D., BOUÉ, J., DELUCHAT, C., ALBERT, D. M., and LAHOV, M. (1974) *Amer. J. Ophthalm.*, **58**, 917  
 JAMES, P. L. M., KARSERAS, A. G., and WYBAR, K. C. (1974) *Brit. J. Ophthalm.*, **58**, 917  
 KARSERAS, A. G., and LAURENCE, K. M. (1975) *Ibid.*, **59**, 462  
 MITTWOCH, U. (1967) 'Sex Chromosomes', pp. 229, 231. Academic Press, New York and London  
 SCHACHENMANN, G., SCHMID, W., FRACCARO, M., MANNINI, A., TIEPOLO, L., PERONA, G. P., and SARTORI, E. (1965) *Lancet*, **2**, 290