

The optic disc in glaucoma

1: Classification

R. A. HITCHINGS

Moorfields Eye Hospital, City Road, London

AND

G. L. SPAETH

Wills Eye Hospital, Spring Garden Street, Philadelphia 19130, USA

The pale, cupped disc found in the final stages of glaucomatous disease has been known from the time of Von Graefe (1854). Since then many observers have described changes that occur at the optic disc in chronic, simple glaucoma. There has been particular interest in changes which may occur in the early stages of the disease.

Studies of the normal population have shown that while there is a wide diversity in the appearance of the normal optic disc, in a single subject (Armaly, 1969; Fishman, 1970; Kolker and Hetherington, 1970; Portnoy, 1973) the two discs are remarkably similar (Witsiuk, 1966; Kronfeld, 1970; Woodruff, 1970; Portnoy, 1973). In contrast, individuals with glaucomatous disease usually show manifest asymmetry of the two optic discs (Fishman, 1970; Kolker and Hetherington, 1970).

Many criteria have been used to describe the glaucomatous optic disc. Important among these is the ratio of the cup diameter to the diameter of the entire disc (Pickard, 1923; Snyderaker, 1964; Hollows and McGuinness, 1967; Armaly, 1967, 1968; Schwartz, 1973; Tomlinson and Phillips, 1974). This was initially measured horizontally, but recently measurement of the vertical cup to disc (C/D) ratio has been stressed, after recognition that changes in the optic cup tend initially to affect the vertical diameter (Chandler and Grant, 1965; Kronfeld, 1967; Kirsch and Anderson, 1973; Weisman, Assif, Phelps, Podos, and Becker, 1973).

Stereoscopic examination of the optic disc in early glaucoma reveals signs which help to distinguish the normal from the glaucomatous cup (Anderson, 1975; Reed and Spaeth, 1974). These signs are evidence for acquired tissue loss and account for the asymmetry previously noted. Tissue loss may appear in a variety of forms: thinning of the neuroretinal rim, either localized or generalized; depression or steepening of the walls of the cup (the tinted hollow (Reed and Spaeth, 1974) or saucer);

deepening of the cup exposing the lamina cribrosa (the 'laminar dots' sign (Reed and Spaeth, 1974)); and change in the course of the retinal vessel which is seen as a sharp change in direction ('kinking' or bayoneting (Reed and Spaeth, 1974)). In addition, the presence of localized regions of nerve fibre loss or 'gutters' has been demonstrated in some cases of early glaucoma by Hoyt, Frisen, and Neuman (1973).

The aim of this paper was to assess systematically glaucomatous discs and look for those features that are commonly associated. As a result, five different types of optic disc appearance are described.

In this paper the term glaucoma has been used for all cases in which the intraocular pressure exceeded 22 mmHg and glaucomatous cupping was visible on stereoscopic examination of the disc. This has meant including cases in which the optic disc appeared normal by unocular ophthalmoscopy, and even cases in which glaucomatous cupping was visible without detectable field loss.

Material and methods

This study was based on analysis of stereoscopic disc photographs of 252 patients from the files of the Glaucoma Clinic at Wills Eye Hospital. The patients were mostly cases of known or suspect glaucoma attending the Glaucoma Service. In addition, 25 normal patients on the files of the Glaucoma Service were included. The diagnosis was unknown at the time of analysis of the stereophotographs.

Most photographs were taken within an 18-month period using a Zeiss fundus flash II camera with a $\times 2.0$ adaptor. Stereoscopic photographs were obtained after maximal pupillary dilatation by photographing the clear optic disc images obtained at each end of a horizontal traverse of the camera body. This traverse was usually 3 to 4 mm.

Slides were examined with a stereoscopic viewer. The stereo pairs of the two eyes were directly compared. Special note was made of identifying characteristics suggestive of tissue loss.

The following criteria were analysed:

THE VERTICAL CUP/DISC (C/D) RATIO

The 'cup' was defined in terms of configuration; its extent was determined by drawing a hypothetical line vertically on the anterior surface of the disc from the most superior to the most inferior aspect of the disc margin; the segment of the line not in contact with the disc surface was considered to be 'the cup'. The ratio (expressed in tenths) of that segment to the length of the entire line was the 'cup/disc ratio' (C/D). Pallor of the optic disc played no part in the assessment of the C/D ratio (Schwartz, 1973).

THE WALLS OF THE OPTIC CUP

The specific points checked were: degree of inclination in the walls, variation in the slope of the walls of any one cup, and difference between cups of the two eyes in each patient. The presence of a more steeply-sided cup despite identical C/D ratios was considered suspicious of enlargement of the cup.

THE DEPTH OF THE OPTIC CUP

The depth of the optic cup was described as 'normal', 'deep', or 'bean-pot'. 'Normal' depth referred to an optic cup which did not show evidence of actual posterior bowing of the lamina cribrosa itself; the cup, however, could extend as far posteriorly as the 'laminar dots' (taken to represent the lamina cribrosa) described by Reed and Spaeth (1974). In a 'deep' cup the lamina cribrosa appeared posteriorly bowed. A 'bean-pot' cup, so called because of its likeness to a spherical clay pot, was diagnosed when posterior displacement of the lamina cribrosa coexisted with undermining of the neuroretinal rim; in transverse section the walls and base of the cup formed the major part of a circle. There was usually little difficulty distinguishing between a flat or a posteriorly-bowed lamina cribrosa. Similarly, although there was clearly a spectrum of changes, differentiation between the 'deep' and the 'bean-pot' cup was usually fairly straightforward. In those few cases where differentiation between two descriptive types was not easy, the shallower type of cup depth was chosen.

THE NEURORETINAL RIM

The pallor and the width of the neuroretinal rims were graded. The colour achieved with transparencies was not an exact match with the colours seen on stereoscopic examination, and pallor of the rim could not always be differentiated from the normal pinkish colour. As a result, comments on colour were restricted to recording whether the neuroretinal rim was pale or pink. Thinning of the neuroretinal rim was far more easily quantitated, and ranged from being just noticeable to a complete absence of rim tissue with extension of the cup to the outer disc margin. The size of the arc involved in thinning ranged from a localized segment (producing a 'notch') to circumferential thinning of the entire neuroretinal rim.

DISPLACEMENT OF THE RETINAL VESSELS

Distinction was made between a gradual curve of a

retinal vessel as it passed over the surface of the optic disc and a sharp 'kinking' or change in the vessel's direction either in the same plane as the disc surface or at an angle to it. The gradual curve was considered normal; the kink was thought to be an acquired change that occurred secondary to enlargement of the optic cup. Kinking resulted in nasal displacement of the vessels, and was of most significance when it occurred at the outer margin of the disc.

PIGMENT CLUMPING

The presence or absence of pigment clumping around the margin of the optic disc was noted.

NERVE FIBRE LAYER

The nature of the nerve fibre layer was observed as far as possible within the limits of the examination technique. Where refractile lines taking the known pattern of the nerve fibre layer (NFL) were visible the NFL was thought to be present. If none of the gutters or grooves described by Hoyt and others (1973) was visible the NFL was called 'intact'. If such a gutter was observed it was listed as a nerve fibre bundle defect (NFBD). If no NFL could be seen at all it was called 'invisible'.

Results

Stereoscopic photographs from 504 eyes of 252 patients were analysed. The optic discs were divided into two groups, normal and pathological, this second being subdivided into five types of glaucomatous cupping (overpass, cupping without pallor of the neuroretinal rim, cupping with pallor of the neuroretinal rim, focal notching of the neuroretinal rim, and bean-pot cupping), whose characteristics will be described. The overall numbers and characterizing features are seen in the Table. Stereophotographs illustrating each of these examples may be seen in Figs 1-5.

CHARACTERISTICS OF DISC SUBTYPES

Normal disc

A disc was considered 'normal' in appearance if the neuroretinal rim was pinkish and of equal thickness throughout, or with its thinnest portion at the temporal margin on the horizontal meridian of the disc. There were no sharp deviations of any retinal vessel where it traversed the disc surface. This type of disc usually had a C/D ratio of less than 0.5, an optic cup of 'normal' depth (as defined above), and a visibly intact nerve fibre layer. When the two optic discs from any patient were highly symmetrical, they were considered 'normal'; this latter definition allowed optic discs with a C/D ratio greater than 0.5, a sharply deviating retinal vessel, or a poorly visualized nerve fibre layer to be included in this normal group. The optic discs of

Table *Clinical features of glaucomatous discs*

Type	No.	Percentage of total	Vertical C/D			Cup depth	Bean-pot	Incidence of overpass (No.)	Rim notch (No.)	Rim pallor (No.)	Vessel displacement (Bayoneting) (No.)	Pigment clumping		Nerve fibre bundle defect (No.)
			Range	Mean	Normal							Deep	(No.)	
1. Normal	231	46	0-0.6	0.3	223	6	—	27	0	0	6	27	(11)	222 Intact 9 Invisible
2. Overpass vessels	44	9	0.2-0.9	0.6	42	2	—	44	3	3	13	21	(65)	24 Intact 17 Invisible 3 NFB
3. Cupping without pallor of rim	124	25	0.3-0.9	0.7	44	76	4	12	0	0	122	74	(61)	82 Intact 30 Invisible 12 NFB
4. Cupping with pallor of rim	68	12	0.7-0.9	0.85	11	57	—	10	20	68	68	58	(82)	60 Invisible 8 NFB
5. Focal notching	23	5	0.4-0.3	0.7	23	—	—	—	25	21	21	21	(91)	1 Intact 3 Invisible 19 NFB
6. Bean-pot	14	3	0.9	0.9	—	—	14	0	0	13	14	13	(92)	13 Invisible 1 Intact

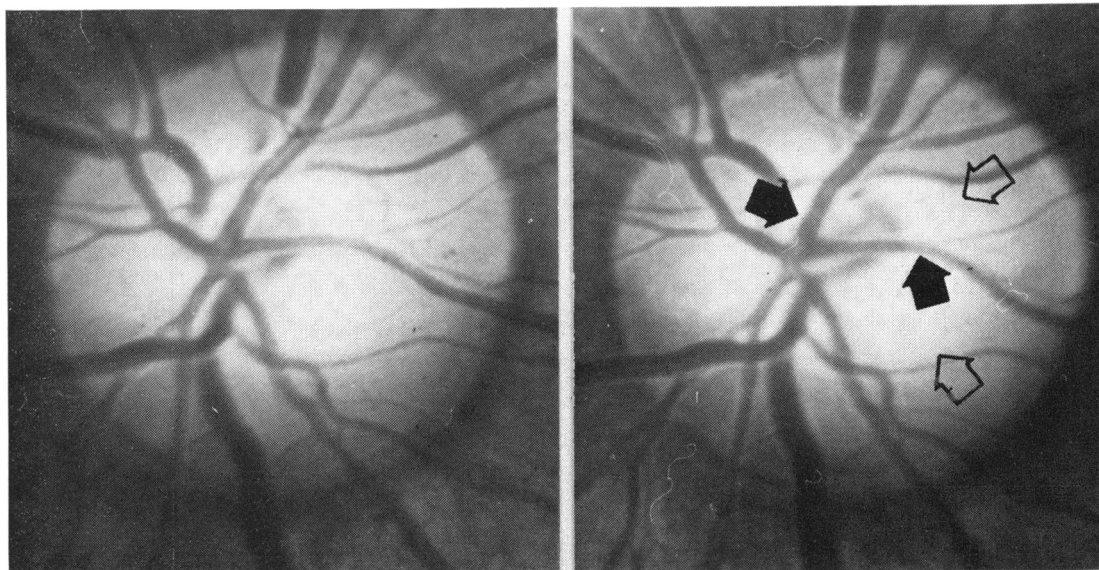


FIG. 1 *Overpass cupping*; retinal vessels (dark arrows) pursuing a relatively undeviated course over the optic cup (hollow arrows)

For satisfactory viewing these stereo pairs should be examined using a suitable convex sphere. With higher powers of sphere, fusion may be obtained by decentering the spheres. To do this, increase the distance between them

all 25 patients clinically considered normal fell into this category.

Overpass cupping (Kronfeld, 1967; Spaeth and Hitchings, 1975)

Where tissue loss within the optic nerve papilla was visible on stereoscopic examination, but *without*

gross enlargement of the optic cup, the phrase 'overpass cupping' was used. This type of intrapapillary tissue loss occurred to a minor degree in some discs classed as 'normal'. More frequently, it involved the disc extensively, and the two discs asymmetrically, being the major anatomic abnormality visible on stereoscopic examination. In these cases the retinal vessels could be seen pursuing a

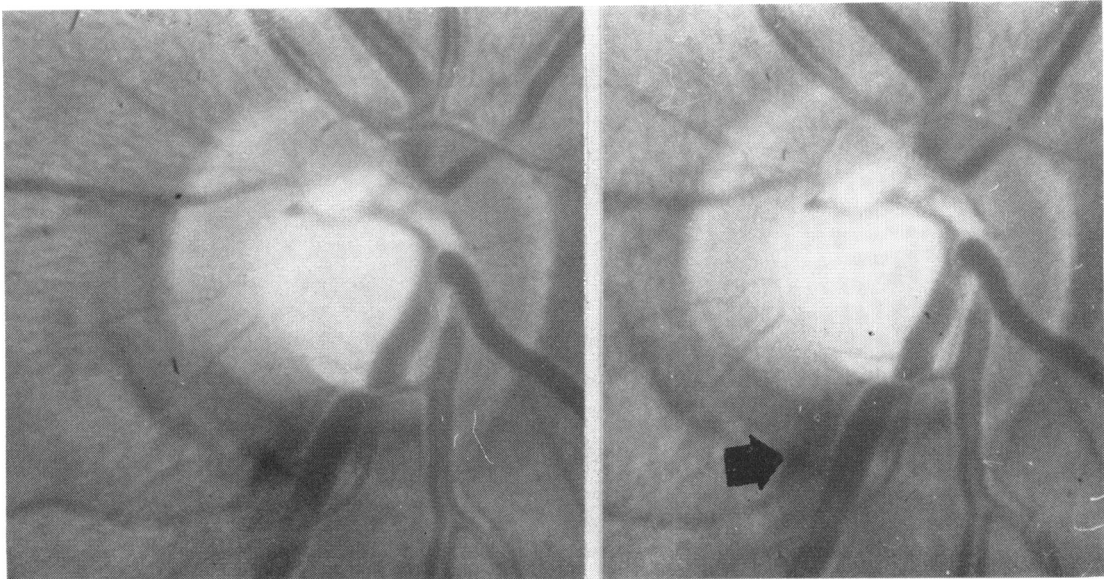


FIG. 2 Cupping without pallor of the neuroretinal rim; glaucomatous cupping is suggested by localized (inferior) thinning of neuroretinal rim, steeply-sided walls to cup, an angulated course followed by infero-temporal vein around rim of cup, and, in this case, a splinter haemorrhage (arrow)

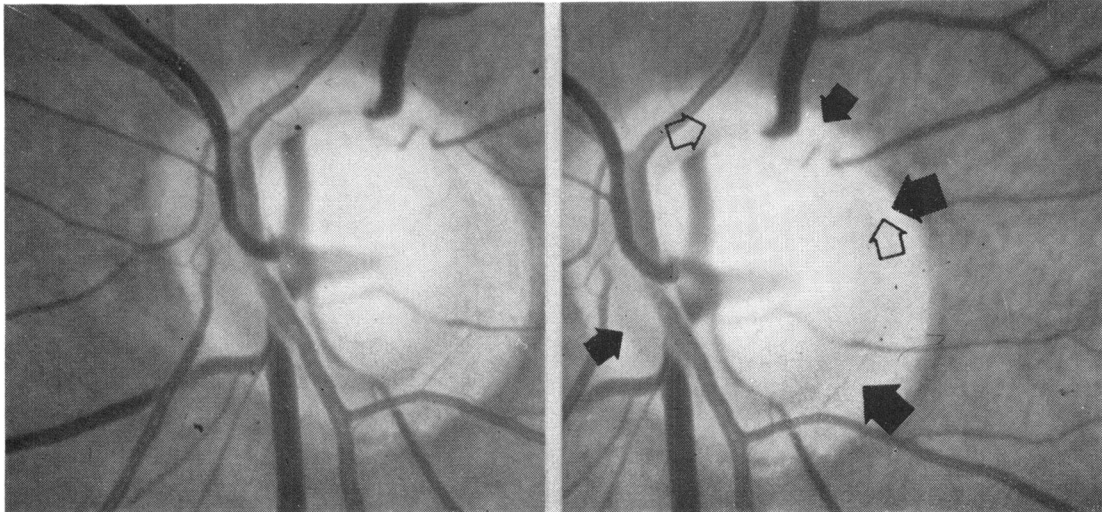


FIG. 3 Cupping with pallor of the neuroretinal rim; glaucomatous cupping associated with pallor of all or part of neuroretinal rim. In this example neuroretinal rim (black arrows) has to be differentiated from adjacent peripapillary atrophy. Pallor of neuroretinal rim may be seen in one segment (hollow arrows)

relatively undeviated course across the disc surface, apparently unsupported by disc tissue (this characteristic of retinal vessels 'bridging' an optic cup resembles the 'flyovers', or overpasses at road junctions, hence the name). On direct ophthalmoscopic examination, the optic cup with overpass cupping did not appear particularly enlarged as a major uniocular clue to the size of the optic cup is

displacement of retinal vessels. The true size of the optic cup was only apparent on stereoscopic examination. This type of tissue loss (overpass cupping) was considered as a separate class.

Cupping without pallor of the neuroretinal rim

An optic disc with a pinkish neuroretinal rim but

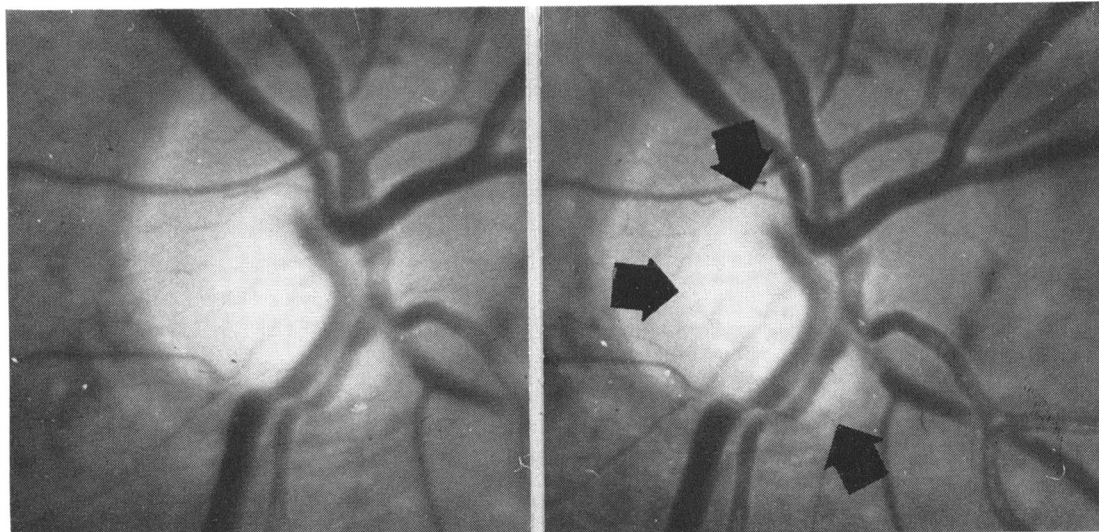


FIG. 4 *Focal notching of the neuroretinal rim; neuroretinal rim is very thin in one localized segment. This is associated with localized enlargement of optic cup (arrowed). There is no evidence elsewhere on optic disc of enlargement of optic cup*

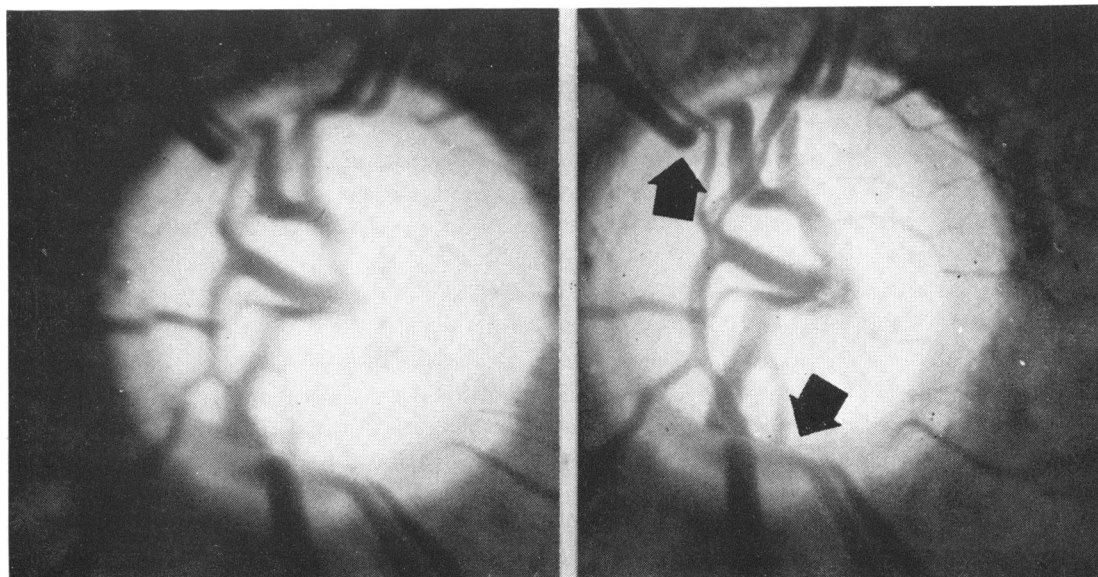


FIG. 5 *Bean-pot cupping; enormous size of optic cup, together with posterior bowing of lamina cribrosa and undermining of the neuroretinal rim resembles a 'bean pot' or gourd. Undermining of neuroretinal rim is emphasized by the retinal vessels 'disappearing' behind the rim for part of their course (arrows)*

with apparent enlargement of the optic cup was considered to have cupping without pallor of the neuroretinal rim. The pertinent clues were marked thinning of the neuroretinal rim together with steeply-sided walls to the optic cup and sharply angulated vessels, resulting in an oval cup out of proportion to that expected from the shape of the optic disc (Portnoy, 1973). This appearance was in

some cases considered distinctive enough to indicate acquired glaucomatous cupping. In other cases the changes were less marked, evidence for glaucomatous cupping being obtained by comparison of the two optic discs from one subject. Here the following were taken as evidence for enlargement: asymmetry of the surface area of the cup (a difference of ≥ 0.2 in the C/D ratio was considered

significant); the steepness of the slope of the walls of the cup, or the depth of the cup. These signs, taken to indicate an acquired change, were most frequently noted at the infero-temporal part of the cup. The supero-temporal area was the next most frequently affected, while enlargement in other directions occurred less often.

Many of these optic discs could have been considered normal if examined individually without evaluation of the fellow disc. It was only by comparing the two discs that asymmetry became apparent.

Cupping with pallor of the neuroretinal rim

In certain optic discs, cupping was combined with pallor of the neuroretinal rim—that is reduced vascularity of the neuroretinal rim which affected part or all of its extent. Also present were those signs described that suggested enlargement of the optic cup and thinning of the neuroretinal rim secondary to raised intraocular pressure. The nerve fibre bundle layer was usually invisible.

Focal notching of the neuroretinal rim

In some eyes localized enlargement of the optic cup with thinning of the neuroretinal rim was present (notching), but *without* apparent cup enlargement elsewhere. This appearance was sufficiently distinctive to justify a separate category. In this series, the notch was usually in the infero-temporal quadrant. These eyes had the highest incidence of visible nerve fibre bundle defects.

Bean-pot cupping

Bean-pot cupping referred to the extreme enlargement of the optic cup already described. This occurred with or without pallor of the neuroretinal rim.

There was a general tendency for the two optic discs of any one patient to exhibit the same optic disc type. This was especially true for those cases with localized, or focal, notching and those with 'bean-pot' cupping. When the same optic disc types were not found, the following combinations occurred: normal + cupping with or without neuroretinal rim pallor; overpass + cupping with or without neuroretinal rim pallor.

Discussion

The proportional representation of each type in this series does not necessarily reflect the overall incidence in a glaucoma population. In the first place the population was highly selected because of the referral nature of the practice of one of us

(GLS). Furthermore, only those patients with technically excellent photographs were chosen for analysis.

There appear to be distinct morphological disc types occurring in glaucomatous disease. Although clearly there was a definite overlap between groups, and some features were found common to more than one type it was still possible to classify the discs into five distinct morphological types. It was the predominant feature (overpass, bean-pot, etc.) which decided placement. Different optic disc types could have similar degrees of visual field loss and therefore be at the same stage of glaucomatous disease from the functional point of view (Hitchings and Spaeth, in preparation).

It is always slightly suspect to state that an individual optic cup has enlarged without documentation in a longitudinal study. The inference that such enlargement does occur is based on previous studies which reveal striking symmetry between the two discs in any one person (Fishman, 1970; Portnoy, 1973). Furthermore, there is evidence that the normal cup is horizontally oval or circular (Kirsch and Anderson, 1973; Weisman and others, 1973). Vertical ovality of the cup which exceeds that which could be explained on the basis of the vertical ovality of the disc itself suggests an acquired change (Kirsch and Anderson, 1973; Portnoy, 1973; Weisman and others, 1973).

An alternative explanation for an acquired enlargement of the optic cup is that it is age related. It seems likely that the optic cup may enlarge with age. Pickard (1948) noted this from a longitudinal study, while Schwartz, Reuling, and Garrison (1975) demonstrated an increase in the horizontal C/D ratio with age by examining stereophotographs of the optic disc. This is at variance with the earlier work of Armaly (1967) who felt, on the basis of unicocular ophthalmoscopy, that the optic cup did not increase with age. Although Schwartz and others (1975) did not specifically measure it, it seems possible that the vertical C/D ratio does not enlarge more than the horizontal C/D ratio.

The existence and extent of peripapillary pigment clumping was noted (Primrose, 1972), but the present study shows that it is not pathognomic for glaucoma as it was found in 27 cases (11 per cent) of normal discs and in nine of these it occurred in eyes that were considered clinically normal. However, in agreement with the finding of Wilensky and Kolker (1976) the incidence of pigmentary clumping rose considerably with glaucomatous disease, occurring in over 90 per cent of eyes with notching of the optic cup and bean-pot cupping. In addition, in cases with bilateral glaucomatous disease, the eye with the more advanced changes

tended to show a greater amount of pigmentary clumping.

In those cases where it was possible to re-examine the patients with red-free light (Hoyt and others, 1973), we found that examination of stereophotographs for defects with nerve fibre layer appeared to be just as accurate. Care was taken to differentiate true from pseudo 'gutters'. All cases in this series with nerve fibre bundle defects had glaucomatous cupping. The nerve fibre layer could not be visualized at all in many patients with glaucoma, notwithstanding the presence of normal fields (on kinetic Goldmann field testing). Visibility was not improved with red-free light. There would appear to be a non-specific depression of light reflexes arising from this layer which is associated with, and possibly related to, raised intraocular pressure, and/or age.

The highest incidence of nerve fibre bundle defects was seen in cases with localized notching of the neuroretinal rim. There was always a corresponding 'dense' field defect on Goldmann perimetry, in marked distinction from discs in other groups where it could be difficult to state whether a field defect was present at all. In the group of eyes with cupping without neuroretinal rim pallor, it was possible to detect changes in the appearance of the optic nerve that suggested glaucoma, *before* nerve fibre bundle defects could be seen. It appeared that visualization of the nerve fibre layer was a valuable guide when present. That it could not be seen in many cases, despite full fields, suggests its value in diagnosis is limited.

The variable appearance of the optic nerve in glaucoma suggests a different response of the nerve to differing disease processes. This may reflect anatomical differences between optic nerves, variation in the duration of the height of the raised intraocular pressure and coexistence of cardio-

vascular and haematological disease. These factors may act singly or in varying combinations. This is borne out to some extent by our knowledge of the natural course of glaucomatous disease. Children and young adults are known to develop glaucomatous cupping and visual field loss after a comparatively short time. The flame-shaped haemorrhage may indicate sudden visual field loss (Drance and Begg, 1970). Conversely some nerves appear capable of withstanding many years of increased intraocular pressure without damage. The appearance of the glaucomatous disc may be affected by many factors. Recognition of differing morphological types may be a step towards recognizing the predominating factors in each case.

Summary

Five different descriptive types of glaucomatous optic discs are described, based on the examination of $\times 2$ magnification stereophotographs of 252 patients from the files of the Glaucoma Service at Wills Eye Hospital. The method of analysis is described in detail. These types include: overpass cupping, cupping without pallor of the neuroretinal rim, cupping with pallor of the neuroretinal rim, focal notching of the neuroretinal rim, and bean-pot cupping.

These morphological types may be caused by variations in factors contributing to the pathogenesis of glaucomatous eyes. Recognition of these differing types may help in determining the factors in each case.

We thank Mr R. J. Smith, and Professor J. Gloster for their advice.

The investigation was supported by National Institute of Health Research Grant No. EY0067704 from the National Eye Institute.

References

- ANDERSON, D. R. (1975) 'Transactions of the New Orleans Academy of Ophthalmology: Symposium on Glaucoma', chap. 7 Clinical evaluation of the glaucomatous fundus, p. 95. Mosby, St Louis
- ARMALY, M. F. (1967) *Arch. Ophthalmol.*, **78**, 35
- (1968) *Amer. J. Ophthalmol.*, **68**, 401
- (1969) *Trans. Amer. Acad. Ophthalm. Otolaryng.*, **73**, 898
- CHANDLER, P. A., and GRANT, W. M. (1965) 'Lectures on Glaucoma', chap. 1. Kimpton, London
- DRANCE, S. M., and BEGG, I. S. (1970) *Canad. J. Ophthalmol.*, **5**, 137
- FISHMAN, R. S. (1970) *Arch. Ophthalmol.*, **84**, 590
- HITCHINGS, R. A., and SPAETH, G. L. (1977) The optic disc in glaucoma: 2. Disc-field correlation (in preparation)
- HOLLOWS, F. E., and MCGUINNESS, R. (1967) *Trans. ophthalm. Soc. Aust.*, **25**; *Trans. ophthalm. soc. N.Z.*, **19**, 33
(Combined vol., *Trans. 2nd Conjoint Meeting Ophthalm. Soc. of Aust. and N.Z.*, 1966)
- HOYT, W. F., FRISEN, L., and NEUMAN, N. (1973) *Invest. Ophthalmol.*, **12**, 814
- KIRSCH, R. F., and ANDERSON, D. R. (1973) *Amer. J. Ophthalmol.*, **75**, 442
- KOLKER, A. E., and HETHERINGTON, J. (1970) 'The Diagnosis and Therapy of the Glaucomas', 3rd ed., chap. 9, Optic discs, p. 143. Mosby, St Louis
- KRONFELD, P. C. (1967) 'Symposium on Glaucoma', chap. 3, The optic nerve, p. 62. Mosby, St Louis
- (1970) *J. Amer. optom. Assoc.*, **23**, 156

- PICKARD, R. (1923) *Brit. J. Ophthalm.*, **7**, 81
——— (1948) *Ibid.*, **32**, 355
- PORTNOY, G. L. (1973) *Amer. J. Ophthalm.*, **76**, 655
- PRIMROSE, J. (1972) Clinical evaluation of glaucomatous discs, in J. S. Cant, 'The Optic Nerve' (Proc. 2nd William MacKenzie Memorial Symposium, 1971). Kimpton, London
- REED, R. M., and SPAETH, G. L. (1974) *Trans. Amer. Acad. Ophthalm. Otolaryng.*, **78**, 225
- SCHWARTZ, B. (1973) *Arch. Ophthalm.*, **89**, 272
- SCHWARTZ, J. T., REULING, F. H., and GARRISON, R. J. (1975) *Brit. J. Ophthalm.*, **59**, 216
- SNYDACKER, D. (1964) *Amer. J. Ophthalm.*, **58**, 958
- SPAETH, G. L., and HITCHINGS, R. A. (1975) Overpass: Is this an early sign of glaucoma? Read at the *Trans. Amer. Acad. Ophthalm. Otolaryng.*, Dallas
- TOMLINSON, A., and PHILLIPS, C. I. (1974) *Brit. J. Ophthalm.*, **58**, 543
- VON GRAEFE, A. (1854) *v. Graefes Arch. Ophthalm.*, **1**, 371
- WEISMAN, R. L., ASSIF, C. P., PHELPS, C. D., PODOS, S. M., and BECKER, B. (1973) *Trans. Amer. Acad. Ophthalm. Otolaryng.*, **77**, 157
- WILENSKY, J. T., and KOLKER, A. E. (1976) *Amer. J. Ophthalm.*, **81**, 341
- WITSUOK, W. (1966) *Ophthalmologica (Basel)*, **152**, 57
- WOODRUFF, M. E. (1970) *Amer. J. Optom.*, **47**, 315