

Posterior polymorphous keratopathy

G. M. LIAKOS AND T. A. CASEY

From the Queen Victoria Hospital, East Grinstead

SUMMARY Seven cases with posterior polymorphous changes of the cornea are reported. After clinical and pathological examination of the above cases, as well as a short review of the literature, the following points are made: (1) Some cases are congenital, being either familial or sporadic, but others are acquired. (2) The term 'posterior polymorphous keratopathy' covers all the variants of the condition and is preferred to the traditional 'posterior polymorphous dystrophy'. (3) The congenital type is a mild variant of the mesodermal dysplasia, whereas the acquired type follows local disease. (4) The condition can be static, but over 50% of cases are slowly progressive, calling for penetrating keratoplasty.

The condition of posterior polymorphous keratopathy is rare, and only a few cases have been reported. General conclusions on the heredity, the histological picture, and the course of the disease cannot be drawn, mainly because the number of cases reported each time is insufficient. Here we present 7 cases of posterior polymorphous dystrophy seen in our clinic over a period of 6 years. The family history, clinical associations, and, where possible, the histology are analysed.

Case reports

CASE 1

A man aged 45 was first diagnosed as having a corneal dystrophy in 1960 when he was 32 years old. This progressed until 1969, when he was referred to our unit. Slit-lamp examination revealed bullous keratopathy in the right eye, with deeper layer changes consisting of whorl-like opacities, vesicles, irregularities, and folds. Owing to corneal oedema the gonioscopic view of the anterior chamber angle was limited; however, in a few places goniosynechiae were evident. In the left eye the anterior corneal layers were normal, but posterior polymorphous changes were easily seen. A band of peripheral anterior synechiae was seen between 4 and 6 o'clock and confirmed by gonioscopy (Fig. 1). Visual acuity was recorded as 6/60 in the right eye and 6/9 in the left. A full-thickness corneal graft restored visual acuity of 6/6 for 2 years but was finally rejected, and 2 subsequent grafts had the same fate.

Address for reprints: Dr G. M. Liakos, Queen Victoria Hospital, Holtze Road, East Grinstead, Sussex RH19 3DZ

Examination of the immediate relatives established a dominant transmission, as several members of the family were similarly affected (Fig. 2). Light and electron microscopy of the corneal disc confirmed the diagnosis (Fig. 3).

CASE 2

A man aged 62 was first seen in 1965 complaining of blurred vision. The visual acuity was recorded at that time as 6/9, 6/18, and polymorphous changes involving the posterior layers of both corneas were diagnosed (Fig. 4). The right eye showed no other abnormality, but a peripheral synechia was present in the left eye. By 1967 the left visual acuity deteriorated to 6/60, and a full-thickness graft improved it to 6/18 for 4 years. The graft had to be repeated in 1973, remaining clear since then, and permitting a visual acuity of 6/12. Unfortunately neither a painting nor histological record of the original left cornea are available.

Examination of the immediate relatives established the dominant inheritance (Fig. 5).

CASE 3

A woman aged 55 was first seen as a case of unilateral herpetic keratitis. This responded successfully to local antiviral treatment, and at that time changes occupying the posterior corneal layers became evident (Fig. 6). The fellow cornea was normal and so was a gonioscopic examination. Visual acuity was 6/9 in the affected eye and 6/6 in the normal one. Examination of the relatives revealed no corneal pathology. (The unilaterality of the condition and the absence of family history

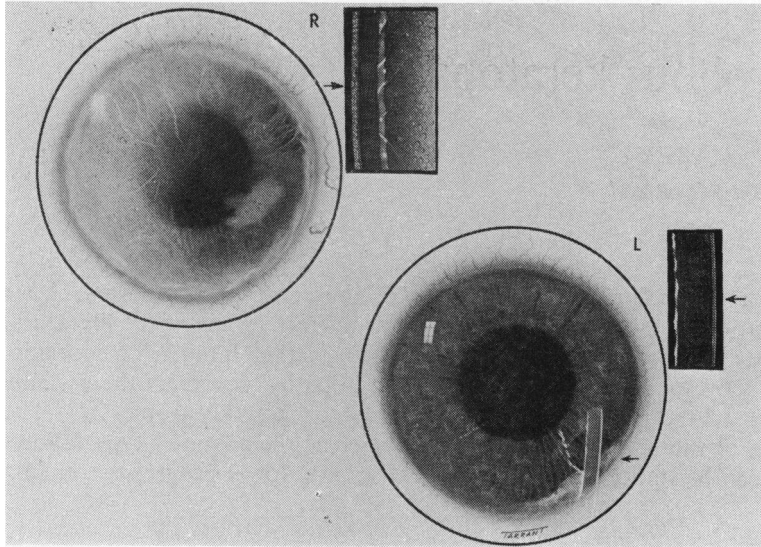


Fig. 1 Artist's impression of the cornea of case 1. Note extensive oedema in the right eye and peripheral synechiae in the left

Fig. 2 Family tree of case 1

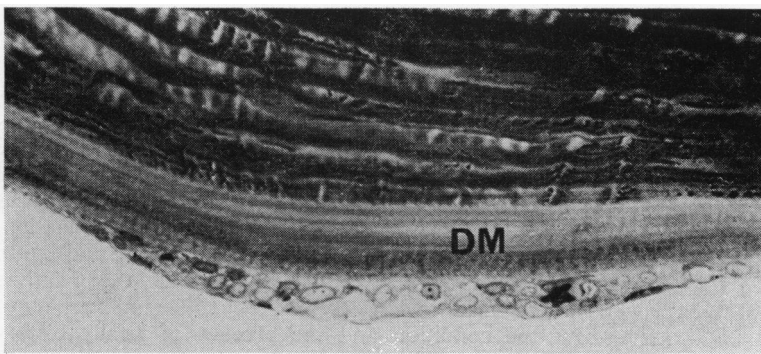
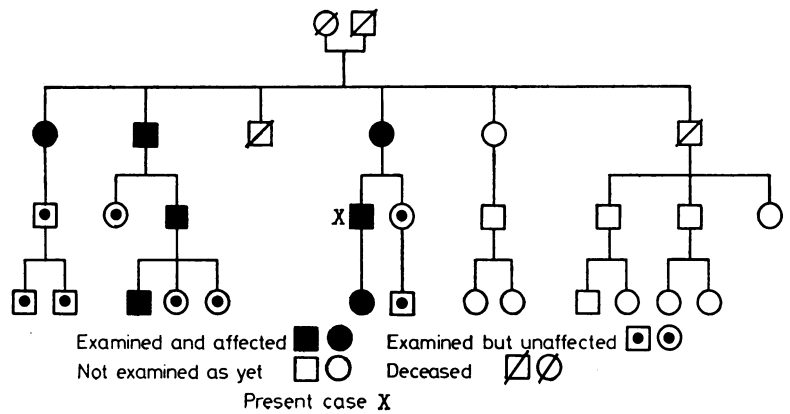


Fig. 3 Light photomicrograph of the posterior cornea. Note thickened and laminated Descemet's membrane (DM) covered by hyperplastic endothelium. Toluidine blue stain ($\times 220$)

point towards a more localised acquired disease, possibly associated with the herpetic infection.)

CASE 4

A woman aged 45 had a long history of bilateral

recurrent uveitis followed by bilateral cataract extraction and later aphakic bullous keratopathy in the left eye, for which she had 2 grafts. When first seen in our unit the clinical findings were as follows: the right cornea was normal in the anterior layers, but with posterior polymorphous changes. A sector iridectomy was present with extensive anterior synechiae, and the eye was aphakic (Fig. 7). The left cornea showed evidence of the 2 previous grafts, which were oedematous, and so was the host cornea. Sector iridectomy and aphakia were present. Visual acuity was recorded as 6/36 and hand movements. A full-thickness graft encompassing the previous grafts in the left eye was performed but was rejected. Histology of the rim of the host cornea showed no posterior changes.

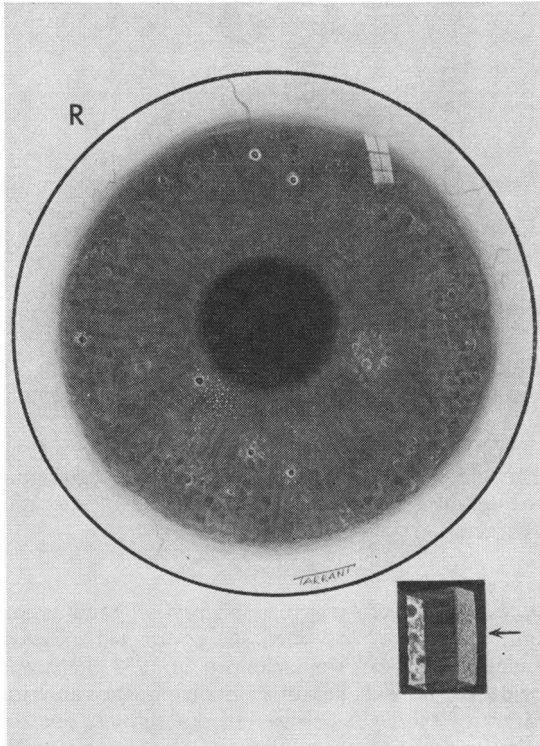


Fig. 4 Right cornea of case 2

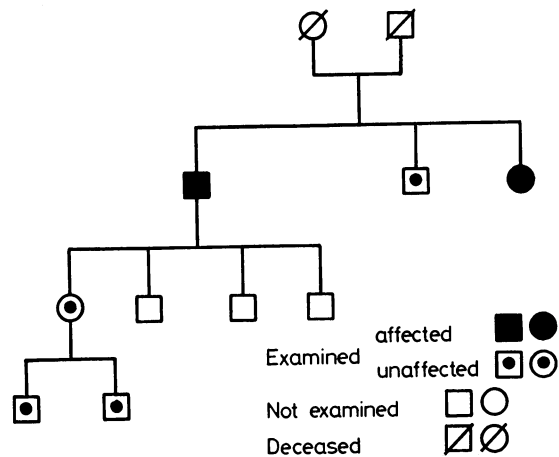
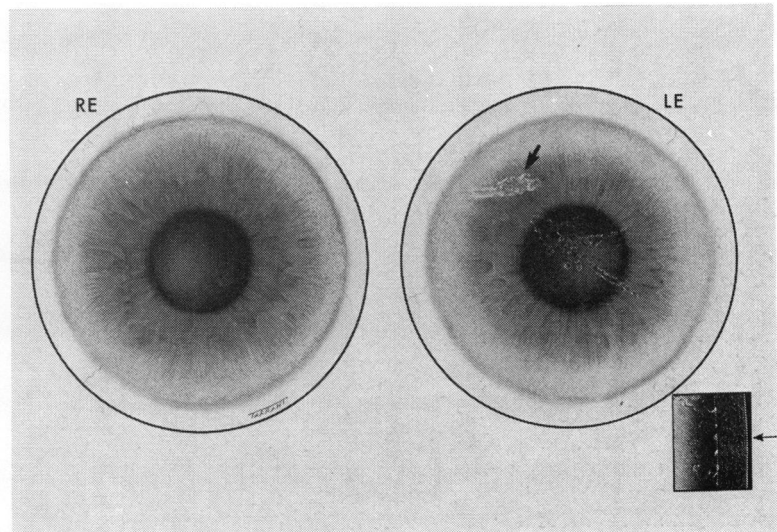


Fig. 5 Family tree of case 2

Fig. 6 Cornea of case 3. Note (a) Normal right cornea, (b) herpetic scar superonasal quadrant in left cornea (c) central posterior polymorphous changes in left cornea



No family history was present. Again the posterior polymorphous changes observed in the right cornea were thought to be a sequel to other ocular disease (intraocular inflammation in this case).

CASE 5

A woman aged 76 had been attending her local eye hospital for a few years with the diagnosis of lenticular opacities and corneal endothelial dystrophy before she was referred to our unit. Examination revealed the presence of bilateral posterior polymorphous corneal changes, particularly involving the axial area (Fig. 8). Both angles were normal but lens opacities were present. Visual acuity was 6/60 and 6/36. A right combined full-thickness graft and cataract extraction restored the vision to 6/6, and the graft remains clear 4 years later. Deteriora-

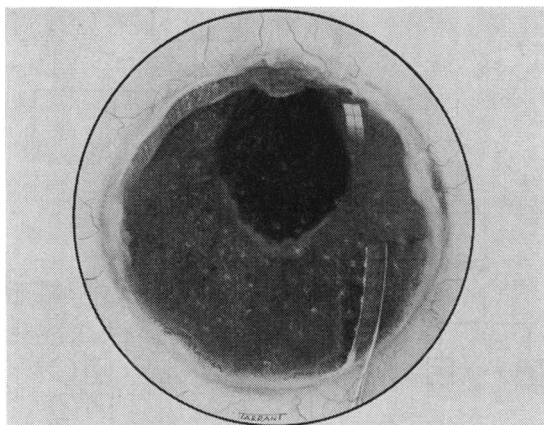


Fig. 7 Right cornea of case 4

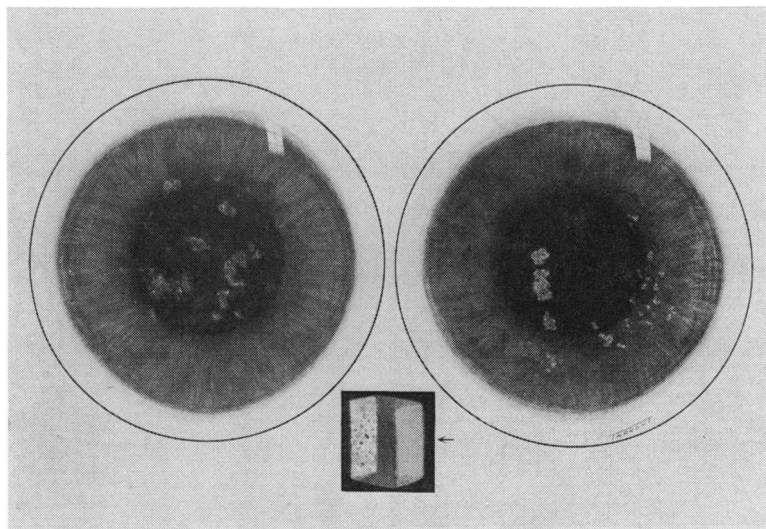


Fig. 8 Cornea of case 5

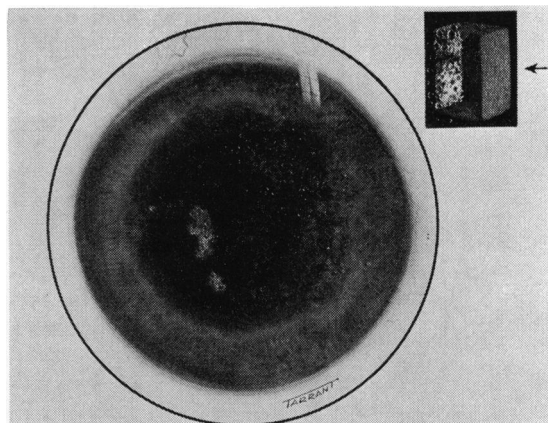


Fig. 9 Left cornea of case 5 4 years later
Note progression of condition with epithelial oedema

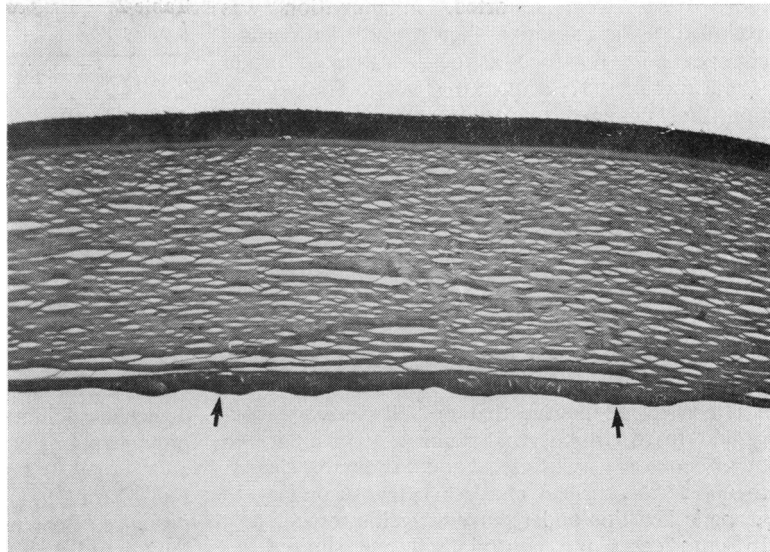
tion of the left cornea has been noted since (Fig. 9), demonstrating the progressive nature of the condition.

Histology confirmed the clinical findings (Fig. 10). No similar changes were found in examining the relatives, so that this case is one of sporadic character.

CASE 6

A woman aged 43 gave a history of good vision until the age of 25, when she contracted measles. Indeed when she was examined in 1973 there was evidence of old keratitis involving the anterior layers of the right cornea but not the left one. In addition polymorphous changes were present in the posterior layers of both corneas. An area of peri-

Fig. 10 Light microscopy of case 5. Note thickening and nodularity of Descemet's membrane (arrows). (H and E stain $\times 50$)



pheral synechiae was seen by gonioscopy in the right eye, but the left anterior chamber was normal. Visual acuity was 6/60 and 6/24. A right full-thickness graft carried out in 1974 restored vision to 6/6 and still remains clear.

All members of the family examined were normal without any evidence of the corneal condition.

CASE 7

A man aged 49 underwent a routine ophthalmological check because of family history of glaucoma. On examination both corneae showed posterior polymorphous changes. Gonioscopy revealed no abnormality in either eye, but intraocular tensions were 24 and 25 mmHg. Visual acuity was 6/6 and 6/6.

The condition has remained stationary for the

last 3 years. No other members of the family were affected.

Discussion

In describing this rare corneal condition, the present cases of which are summarised in Table 1, several different terms have been used. The first was 'keratitis bullosa interna', used by Koeppel (1916) when describing the condition for the first time. He evidently regarded the condition as inflammatory in origin, hence the term 'keratitis', but this contrasts with his next article on the condition (Koeppel, 1920), when, reporting 18 additional cases, he stated that owing to absence of other ocular changes he regarded the condition as congenital in origin. Subsequently, as more observations were made and

Table 1 Summary of reported cases

Case	Sex	Age	Type of PPK	Associated findings	VA	Opposite cornea	Course	Treatment
1	M	40	Familial	PAS	6/36	PPK	Progressive	FTG
2	M	54	Familial	PAS	HM	PPK	Progressive	FTG
3	F	55	Acquired	Herpetic keratitis	6/6	NAD	Static	—
4	F	42	Acquired	Aphakic old uveitis	6/36	Old graft (host cornea NAD)	Static	—
5	F	74	Sporadic	Cataract	6/36	PPK	Progressive	FTG
6	F	41	Sporadic	PAS	6/60	PPK	Progressive	FTG
7	M	51	Sporadic	CSG	6/6	PPK	Static	—

CSG = Chronic simple glaucoma. FTG = Full thickness graft. NAD = Nothing abnormal detected. PAS = Peripheral anterior synechiae. PPK = Posterior polymorphous keratopathy. VA = Visual acuity.

more cases were reported, inflammation was excluded as a causative factor and the corneal changes were regarded as degenerative in origin (Freudenthal, 1932; Schlichting, 1941). The description thus changed to 'degeneration of the inner cornea'.

The term 'polymorphous' was introduced by Forni (1951), who recognised the diverse configuration of the corneal changes. Since then several familial cases were reported by various authors, and the condition has been accepted as hereditary, with autosomal dominant transmission, hence the term 'posterior polymorphous dystrophy' (Franceschetti *et al.*, 1950; McGee and Falls, 1953; Bergman, 1964; Hanselmayer, 1972a, b).

However, we believe that not all cases are congenital in origin but that some are secondary to other ocular disease. Cases 3 and 4 show this clearly, the posterior corneal changes being secondary to herpetic keratitis and recurrent uveitis respectively. In both cases the contralateral eye showed no evidence of similar changes, and examination of the immediate relatives revealed no similar disease.

In case 3 the pattern of the posterior changes was typical, constituting ridges, vesicles, and lines (Fig. 6). In case 4 the picture was more atypical, the changes being smaller, heavily pigmented, and confined to endothelium and Descemet's membrane (Fig. 7). The fact that previous surgery had been performed complicates the picture, and it is difficult to decide whether the surgery or the inflammatory episodes initiated the corneal changes. It would be interesting to examine the histology of these two corneas, but neither of the 2 eyes has reached the stage that justifies keratoplasty.

The familial character of the condition is represented by cases 1 and 2. In both cases various members of the family were affected. The extent of the corneal changes and the effect on the visual acuity were variable from person to person, this variation confirming the differing penetration.

Cases 5, 6, and 7 show the sporadic type of the condition. Case 6 is interesting because of the association with measles keratitis. This must be regarded as a coincidence unaffected the course of the dystrophic changes. The opposite eye showed no evidence of keratitis.

In accordance with the above findings we propose a new descriptive term that covers all the cases with posterior polymorphous changes, and that is 'posterior polymorphous keratopathy'. By using the word keratopathy instead of dystrophy we include not only the congenital types of the condition but also the acquired ones. Further differentiation can be made by adding 'congenital' or 'acquired' to 'posterior polymorphous keratopathy' (Table 2).

Table 2 *Classification of posterior polymorphous keratopathy*

Posterior polymorphous keratopathy		
Congenital		Acquired
Familial	Sporadic	

PATHOGENESIS

Equally confusing is the pathogenesis proposed by various authors in describing cases with this condition. Thus Morgan and Patterson (1967) proposed that the excrescences from the Descemet's membrane are formed by the endothelium as a variant of Hessel-Henle bodies. Hogan and Bietti (1969) detected calcium crystals on a corneal button with polymorphous changes, and regarded the condition as a sequel to a metabolic disorder. Boruchoff and Kuwabara (1971) presenting their case, reported the presence of extensive peripheral synechiae obliterating the trabeculum, and suggested that the condition is a type of mesodermal dysplasia. An additional finding was the presence of epithelial cells on the endothelial surface, and the question of endothelial transformation was raised. Tripathi *et al* (1974) similarly accepted the theory of mesodermal dysplasia.

The diversity of the pathological findings by various authors simply points towards a different origin. Nevertheless, one associated finding appears to be quite common in the literature of the condition, and this is the presence of peripheral anterior synechiae. Theodore (1939), Pietruschka (1960), Rubenstein and Silverman (1968) reported glaucoma and Hugonier *et al.* (1963) and Malbran and Troncoso (1973) reported congenital glaucoma in association with polymorphous corneal changes. In our series 3 cases had peripheral anterior synechiae and 1 case chronic simple glaucoma in spite of normal angle. We are convinced that the congenital type of posterior polymorphous keratopathy is a mild variant of mesodermal dysplasia syndrome.

Trauma or inflammation can produce proliferation of Descemet's membrane. We think that inflammation is the cause of the acquired type of posterior polymorphous keratopathy, but a metabolic disorder as suggested by Hogan and Bietti (1969) cannot be excluded.

The condition is regarded by many as non-progressive. In contrast to this view 4 of our 7 cases followed a progressive course, developing bullous keratopathy and necessitating penetrating keratoplasty.

We should like to thank Mr P. D. Trevor-Roper for advice and Mrs Ayles for secretarial assistance.

References

- Bergman, G. D. (1964). Posterior polymorphous degeneration of the cornea. *American Journal of Ophthalmology*, **58**, 125-127.
- Borouchoff, S. A., and Kuwabara, T. (1971). Electron microscopy of posterior polymorphous degeneration. *American Journal of Ophthalmology*, **72**, 879-887.
- Forni, S. (1951). Degenerescence polymorphe familiale de la membrane limitante posterieure de la cornee. *Archives d'Ophthalmologie* (Paris), NS, II, 162-166.
- Franceschetti, A., Klein, D., Forni, S., and Babel, J. (1950). Transactions of XVI International Ophthalmological Congress. *Brittania Acta*, **1**, 157.
- Freudenthal, E. (1932). Über zwei fälle von familiärer endotheldystrophie der hornhaut bei vorhandensein allgemein degenerativer veränderungen. *Zeitschrift für Augenheilkunde*, **78**, 224-229.
- Hanselmayer, H. (1972a). Histopathology of posterior polymorphous corneal dystrophy of Schlichting. *Albrecht von Graefe's Archive for Clinical and Experimental Ophthalmology*, **184**, 345-357.
- Hanselmayer, H. (1972b). Histopathology of posterior polymorphous corneal dystrophy of Schlichting. *Albrecht von Graefe's Archive for Clinical and Experimental Ophthalmology*, **185**, 53-65.
- Hogan, M. J., and Bietti, G. (1969). Hereditary deep dystrophy of the cornea (polymorphous). *American Journal of Ophthalmology*, **68**, 777-788.
- Hugonnier, R., Etienne, R., Bonnet-Genin, M. et al. (1963). A propos de deux observations de degenerescence familiale polymorphe de la membrane limitante posterieure de la cornee. *Bulletin des Societes Ophtalmologie de France*, **63**, 270-274.
- Koeppe, L. (1916). Klinische beobachtungen mit der nerstspaltlampe und dem hornhautmikroskop. *Albrecht von Graefe's Archive for Clinical and Experimental Ophthalmology*, **91**, 375-379.
- Koeppe, L. (1920). Die Mikroskopie des lebenden Auges, Vol. 1, p. 130. Springer: Berlin.
- Malbran, E., and Troncoso, V. V. (1973). Degeneracion polimorfa posterior de koeppe. *Annales del Instituto Barraquer*, **11**, 275-283.
- McGee, H. B., and Falls, H. F. (1953). Hereditary polymorphous deep degeneration of the cornea. *Archives of Ophthalmology*, **50**, 462-467.
- Morgan, G., and Patterson, A. (1967). Pathology of posterior polymorphous degeneration of the cornea. *British Journal of Ophthalmology*, **51**, 433-436.
- Pietruschka, G. (1960). Über eine familiäre endothel-dystrophie der hornhaut. *Klinische Monatsblätter für Augenheilkunde*, **136**, 794-806.
- Rubenstein, R. A., and Silverman, J. J. (1968). Hereditary deep dystrophy of the cornea associated with glaucoma and ruptures in Descemet's membrane. *Archives of Ophthalmology*, **79**, 123-126.
- Schlichting, H. (1941). Blasen und dellenformige endotheldystrophie der hornhaut. *Klinische Monatsblätter für Augenheilkunde*, **107**, 425-435.
- Theodore, F. H. (1939). Congenital type of endothelial dystrophy. *Archives of Ophthalmology*, **21**, 626-638.
- Tripathi, R. C., Casey, T. A., and Wise, G. (1974). Hereditary posterior polymorphous dystrophy. An ultrastructural and clinical report. *Transactions of the Ophthalmological Societies of the United Kingdom*, **94**, 211-225.