

Retinitis pigmentosa and retinal oedema

D. J. SPALTON, A. C. BIRD, AND P. E. CLEARLY

From Moorfields Eye Hospital and the Institute of Ophthalmology, London

SUMMARY Twenty-five patients with retinitis pigmentosa and retinal leakage were investigated. Oedema was present in dominant and X-linked inherited disease and is likely to be present in recessive disease as well. We suggest that this might be a general response seen in many types of tapeto-retinal degeneration to actively degenerating photoreceptors or pigment epithelium.

Oedema and cystic changes at the macula have been recognised in some patients with retinitis pigmentosa (RP) Gass, 1970; Merin, 1970; Hyvarinen *et al.* 1971; ffytche, 1972; François *et al.*, 1972; Fishman *et al.*, 1977. The association of retinitis pigmentosa with Coats's disease (Zamorani, 1956; Morgan and Crawford, 1968; Schmidt and Faulborn, 1970; Schmidt and Faulborn, 1972; Ayesh *et al.*, 1976; Lanier *et al.*, 1976) and with peripheral vascular leakage has been identified (Deutman, 1976). Cystoid macular oedema has also been reported in patients who subsequently developed outer retinal dystrophy (Deutman *et al.*, 1976).

It has been postulated that RP is the end stage of a number of different conditions which can be subdivided, at least in part, by the inheritance. We undertook this study to identify if there was a relationship between retinal vascular leakage and the pattern of inheritance of the condition. A relationship of this type would lend support to the hypothesis that RP is a syndrome produced by different diseases and that vascular leakage may provide a means of further subdividing the disorder.

Methods

From the records of the Genetic Clinic and Retinal Diagnostic Department at Moorfields Eye Hospital all fluorescein angiograms of patients with RP were reviewed. Those patients who showed undoubted evidence of fluorescein leakage were recalled for further examination where possible. Apart from the patients seen while the study was in progress these angiograms had been taken sporadically over a period of 9 years for a variety of reasons and

involved only a small percentage of the patients seen at the hospital with RP during this time.

The diagnosis of RP was established by typical fundus change and visual field loss. Electrodiagnostic tests were performed on those patients in whom affected relatives had not been examined or where there was no family history of disease.

The patients who were available for recall were given a general ophthalmic examination, especially noting their visual acuity, fields, lens, vitreous, and fundus changes. Peripheral retinal exudation was looked for in all patients, and blood tests taken for immunological survey. Fluorescein angiography was performed by our standard technique (Bird, 1975).

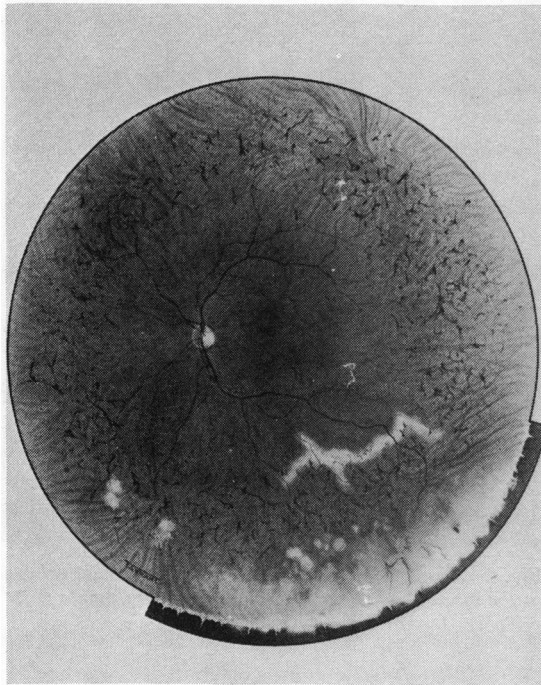
Results

Twenty-five patients with retinitis pigmentosa and retinal vascular leakage were seen. Twenty of these had had previous angiograms and 15 were able to attend for further examination. During the course of the study 6 new patients were seen. Six patients had proved autosomal dominant inheritance, and there were 4 males with X-linked disease and 1 female heterozygote for the X-linked gene who had retinal degeneration. Two other patients had a family history of retinitis pigmentosa, but there was not enough evidence from the family history to classify these. Of the remaining patients who had no family history of RP there were 3 children with severe disease.

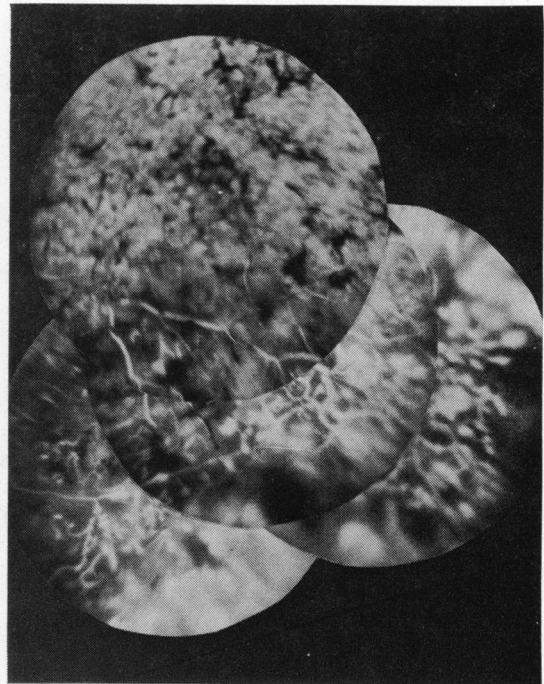At some stage of their disease 18 had evidence of accumulation of dye at the macula (Figs. 1 to 4), 8 had disc vessel leakage (Figs. 2 to 6), 22 had leakage in the arcuate fibre bundle area (Figs. 1 to 6), and 11 had peripheral leakage (Figs. 1, 2, 6, 7). Twenty-one patients had leakage from 2 or more of

these areas at some time. In 2 patients telangiectatic vessels were seen in the peripheral retina; in 1 this was associated with intraretinal exudates similar to Coats's disease, and in the other the abnormal vessels were at the site of previous confluent

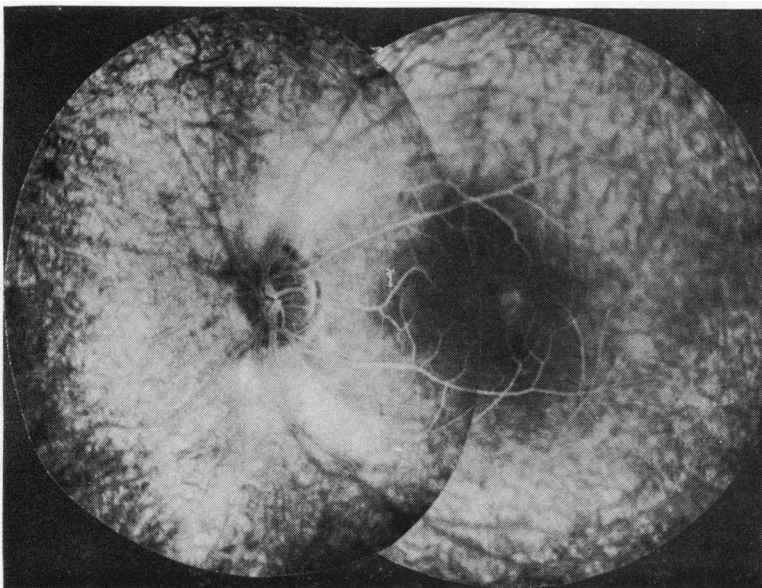
exudation (Fig. 1). In 2 patients with fluorescein accumulation at the macula stereoangiography showed that this originated deep to the retinal circulation (Fig. 4); in all others the leakage was from the retinal vessels. Even in the 2 patients with



1a



1c



1b

Fig. 1 *Case 4. (a) Retinitis pigmentosa associated with retinal exudates below the macula and in the periphery. Fluorescein angiography demonstrated leakage at the arcuate area, macula (b), and peripheral retinal telangiectasis (c)*

leakage from the choroid the overlying retinal capillaries were dilated. Of the 15 patients followed up the leakage was less in 6, increased in 4, and unchanged in another 4 (Table 1).

All patients had excessive numbers of cells in their vitreous and 6 patients presented with exudates in the pre-equatorial fundus indistinguishable from pars planitis (Fig. 1).

We have also included in this paper an interesting child with Batten's disease (Case 26). She presented at 5 years of age with poor central vision and macular lesions, later developing seizures and cerebral signs. Diagnosis was made on the appearances of her blood film and rectal biopsy. During 2 years of follow-up she has developed increasing peripheral retinal vascular leakage (Fig. 8), with rapid deterioration of her vision and slow progression of her cerebral signs.

Discussion

Retinal vascular leakage was recorded in patients with undoubted dominant and X-linked RP. In the absence of consanguinity it is difficult to prove autosomal recessive inheritance, but it is likely that many of the patients classified as sporadic had recessively inherited disease. This would be especially true of female children presenting with severe disease (Jay and Bird, 1973). Therefore it seems probable that retinal vascular leakage occurs in all genetic

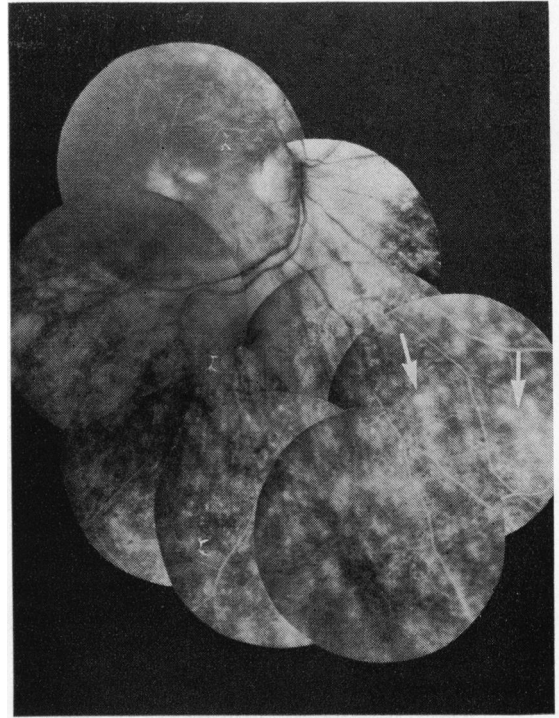
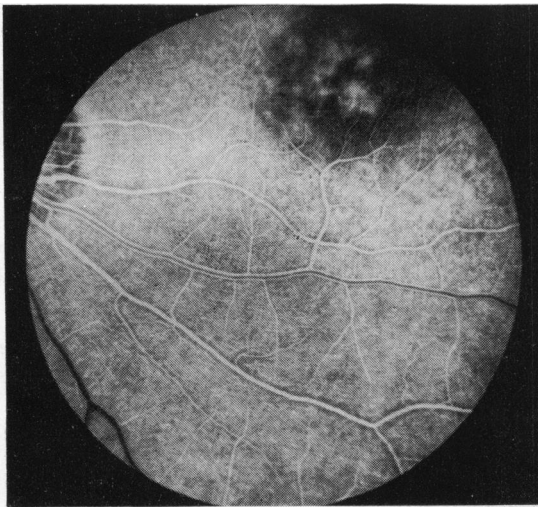
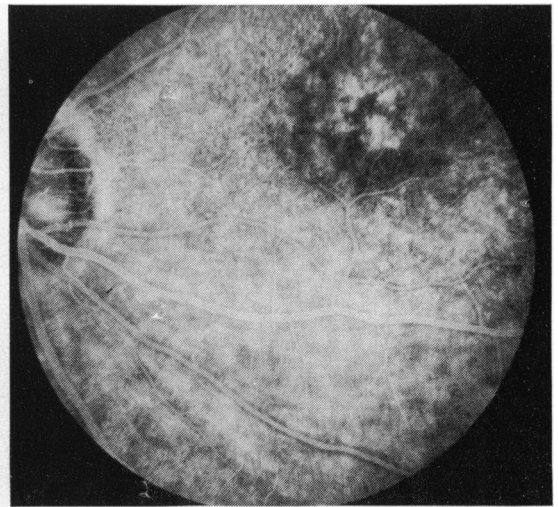


Fig. 2 Case 5. Fluorescein angiography showing leakage at the macula, optic disc, arcuate area, and in the periphery (arrows)



3a



3b

Fig. 3 Case 12. Fluorescein angiogram showing macular oedema and dilatation of the peripapillary plexus (a), from which there was progressive leakage of dye (b)

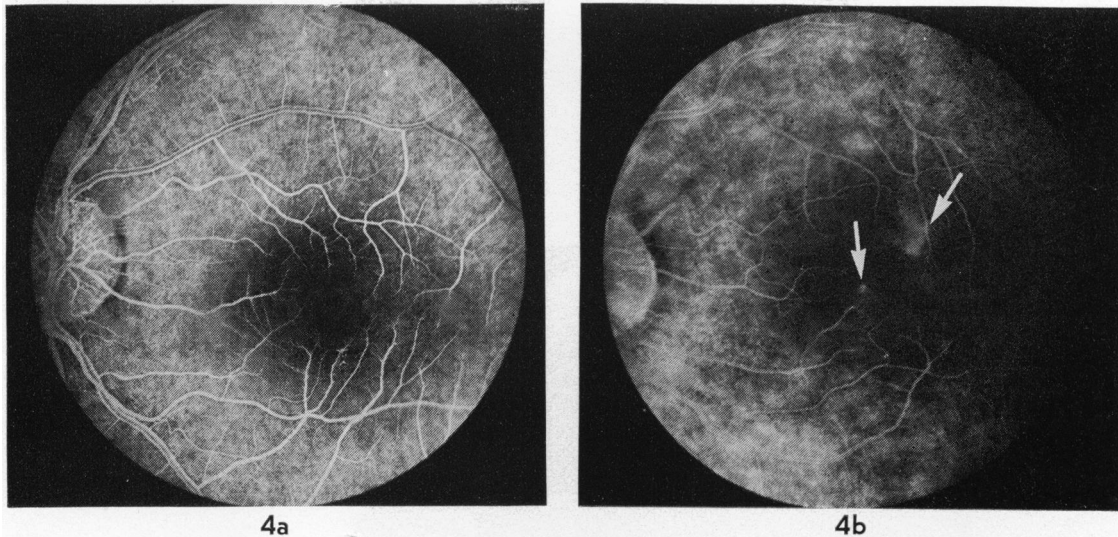


Fig. 4 Case 11. Fluorescein angiogram demonstrating dilatation of retinal capillaries (a), and leakage from these vessels into the optic disc and arcuate area. This patient also showed progressive leakage of dye from the choroid into the retina (b) (arrows)

forms of RP. The distribution of the patterns of inheritance in the patients reported here corresponds to that already reported in London (Jay and Bird, 1973; Bird, 1975). Oedema does not appear to be more common in any of the genetic groups when compared with any other.

Previous accounts have largely been concerned with leakage at the macula and posterior retina. This was the commonest pattern of leakage recorded in our patients. Every one of them had some part of the posterior pole affected during the course of the study. Three patients had swollen optic discs, and indeed 1 patient was initially referred for investigation of papilloedema. However, 11 of our patients, spread throughout all genetic groups, showed evidence of peripheral dye leakage, and in all but 2 this was associated with profound posterior pole leakage. These patients were young (apart from Case 25), with a relatively short history of visual impairment, and were possibly at a stage of disease when the retinal degeneration was rapidly progressive. Apart from having extensive peripheral leakage 1 of these patients had an area of pronounced retinal telangiectasis simulating Coats's disease (known to be associated with RP), and another had some neovascularisation in an area of previous peripheral retinal exudates.

The topographical correlation of vascular leakage with the fundus appearance was poor. Leakage was not specifically associated with areas of pigmentation or retinal pigment epithelial atrophy. Nevertheless,

leakage was not seen in areas of longstanding atrophy, and the arcuate area, which often corresponded to the margin of relatively normal and diseased retina, was commonly affected. However, the highly vascular nature of the arcuate area may account for the commonly observed leakage at this site. In some patients dilatation of the retinal capillaries was observed without dye leakage; this abnormality has been observed in other receptor dystrophies (Notting and Deutman, 1976).

Those patients in whom we recorded increasing leakage during the period of observation had relatively early disease (as illustrated by Case 26), whereas those in whom the leakage became less had relatively advanced disease.

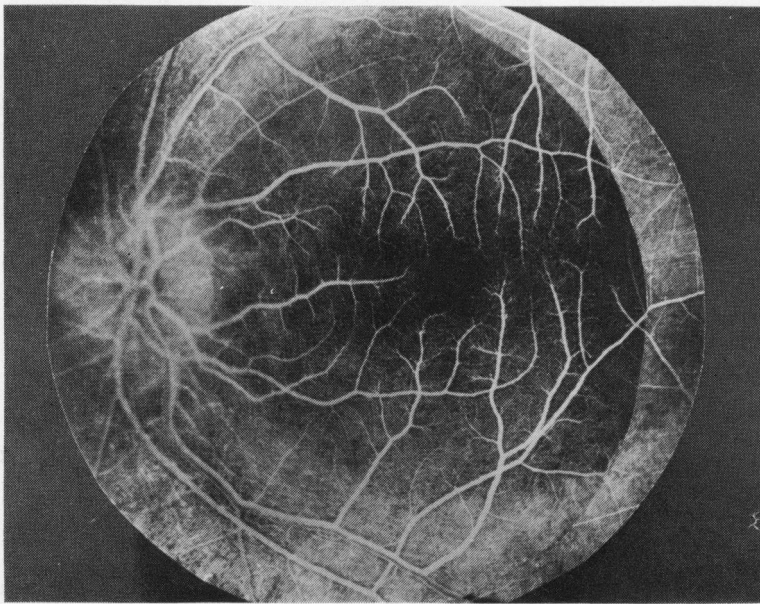
Leakage of dye from the choroid into the retina was identified with certainty in only 2 cases, and in these patients there was overlying retinal vasodilatation. This phenomenon was not easy to identify because of difficulty in achieving good stereo-angiography throughout the study and because it was hard to differentiate deep leakage from transmission defects. It is likely that leakage from the choroid was commoner than observed. Leakage from the choroid has been the subject of speculation (Archer, 1975) but has not been identified previously.

Many of the vascular changes in retinitis pigmentosa are found in other conditions of which inflammation is thought to be the cause. Six of our patients presented with peripheral retinal exudates, and these have been reported earlier (Chester *et al.*,

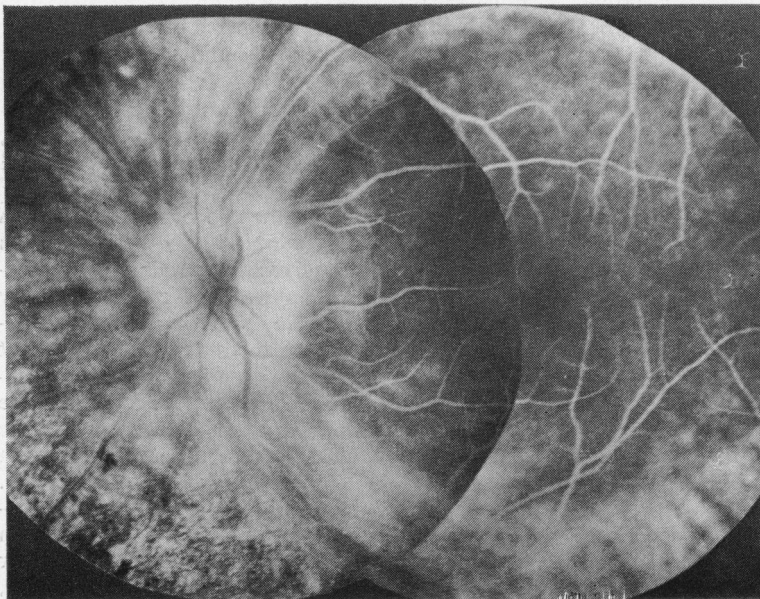
1976). In all these patients the exudates had disappeared by the time of review and in 1 patient had resolved during a 4-month period. All our patients had excessive numbers of cells in the vitreous, and 5 had posterior subcapsular lens opacities. The pattern of leakage of dye in the posterior pole is similar to that seen in aphakic macular oedema and

posterior uveitis, in which the inflammation is thought to be the cause of vascular changes (Norton *et al.*, 1975; Maumenee, 1970; Welch *et al.*, 1960).

Retinal vascular leakage has also been noticed in the Favre-Goldmann syndrome (Fishman *et al.*, 1976), ring choroidal atrophy (Chopdar, 1976), and dominant macular oedema (Deutman *et al.*, 1976),



5a



5b

Fig. 5 Case 2. Showing dilatation of the retinal vessels (a) and marked leakage into the optic disc and arcuate area but only mild macular oedema (b)

as well as 1 child with Batten's disease. It would seem likely that retinal oedema is common to a number of genetically-determined conditions in which there is degeneration of the photoreceptors and pigment epithelium, and, therefore, it might be a non-specific response to inflammation consequent upon the degeneration of photoreceptors or pigment epithelium.

Only 2 of our patients under 40 had enough lens opacities to contribute to their visual loss. Whether or not the presence of retinal oedema has a deleterious effect on the visual prognosis is uncertain. However,

in this context it is significant that 6 patients with dominantly inherited RP were young and might have been expected to retain good central vision until middle age (Jay and Bird, 1973). Two of our patients were incapacitated by their poor central vision, and it would be reasonable to suppose that their macular oedema had contributed to the visual downfall.

We thank Mr T. Bandle and Mr K. S. Sehmi for their photographic expertise and Miss Jayne Fisher for secretarial assistance. Fig. 1(a) is printed by the

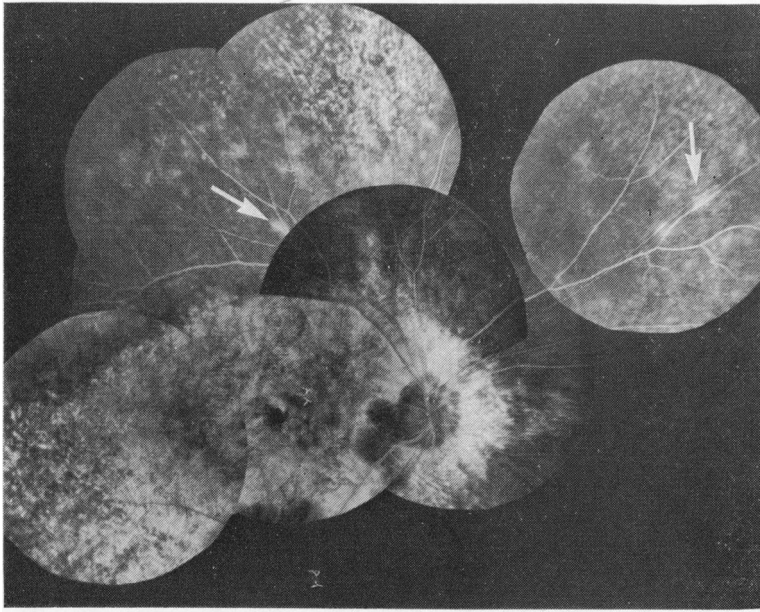


Fig. 6 Case 24. Combined dystrophy of macula and peripheral retina. Fluorescein angiography demonstrated leakage into the arcuate area and from the peripheral retinal vessels (arrows)

Fig. 7 Case 17. Fluorescein angiogram showing leakage from peripheral retinal vessels only

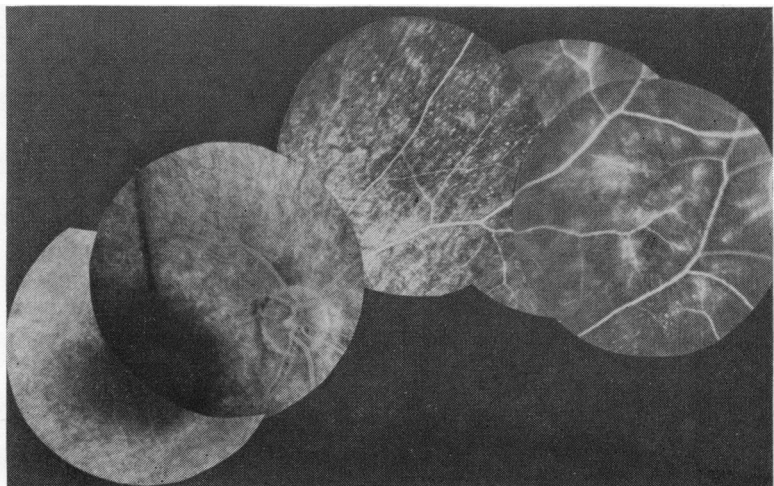
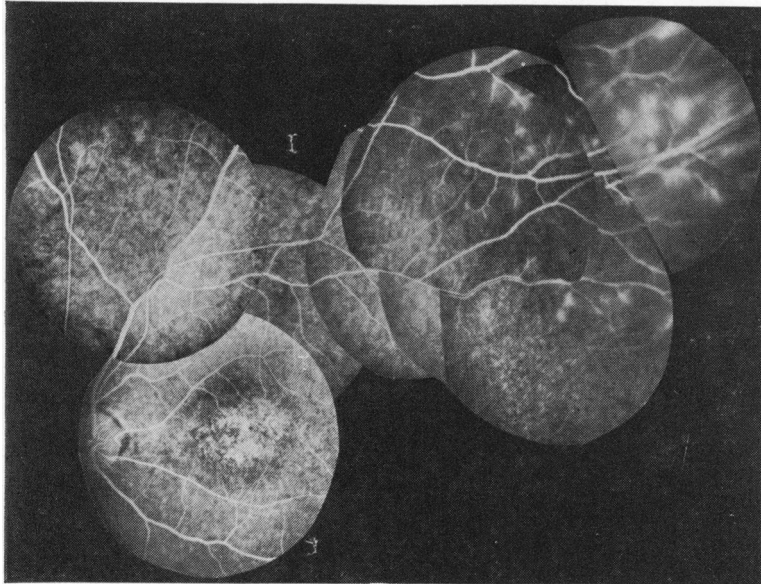


Table 1 Clinical details of patients with retinitis pigmentosa and retinal oedema

Name	Date seen	Age	Sex	Visual acuity	Lens appearance	Fundus appearance			Fluorescein findings				Comment	
						Cystic macular oedema	Vitreous cells	Pars plana exudate	Disc leakage	Macular leakage	Arcuate fibre leakage	Peripheral leakage		Inheritance
1	31.1.73 16.8.76	23	F	6/24 6/36 6/24 6/18		+		present clear	+	+		AD		
2	18.7.72	32	M	6/12 6/12		+	+	+	+	+	+	AD	Presented as papillo-oedema	
3	19.11.76 8.3.77	26	F	6/24 6/24 CF 6/60	early post. subcap.	+	+	+	+	+	+	AD	Less leakage	
4	20.1.76 8.3.77	21	F	6/5 6/5 6/9 6/9	clear	+	++	+	present new vessels	-	+	+	AD	Probably increased
5	16.6.75 8.3.77	43	M	6/9 6/9 6/12 6/12	clear	+	+	+	clear	+	+	+	AD	Little change over 2 years
6	17.3.77	49	M	6/12 6/9	clear	+	+	+	clear	-	+	-	AD	Brother of above Minimal changes in RE only
7	13.5.72	25	F	6/6 6/6		+				-	-	+	XL	Female carrier
8*	15.9.76	10	M	6/9 6/6	clear	-	++	++	-	+	+	+	XL	
9	26.1.70 8.3.77	22	M	CF HM CF HM	clear	-	++	+	-	+	-	-	XL	Little change Asteroid hyalitis
10	18.10.74 8.3.77	24	M	CF CF HM CF	clear	+	+	+	-	+	+	+	XL	Brother of above Much increased leakage Deep leakage
11	29.3.77	23	M	6/18 6/18	clear	+	++	++	-	+	+	+	XL	Mother and sister carriers but no leakage Deep leakage
12	24.3.76 15.3.77	10	F	6/60 6/60 6/36 6/36	clear	+	+	+	-	+	+	+	AR	Increased leakage
13	25.2.76 15.3.77	6	M	4/60 4/60 6/60 6/60	clear	+			-	+	+	+	AR	Gross leakage, little change. Swollen discs
14	5.2.74 10.3.76	10	M	6/9 6/18		+		+		+	+	+	AR	Swollen discs, less leakage (brother with RP)
15	28.7.75 11.3.77	25	F	6/36 6/36 6/36 6/36	clear	+	+	±	-	-	+	-	S	Less leakage
16	3.3.75 11.3.77	27	M	6/9 6/60 6/18 6/18	clear	+	+	+	clear	-	-	±	S	Less leakage
17	3.12.75 11.3.77	29	F	6/60 6/60 6/60 6/36	clear	+	present	+	-	+	+	+	S	Less leakage
18	13.10.69 11.3.77	58	M	CF 6/18 NPL 6/24	early post subcap.	atrophic	+	+	-	-	+	-	S	Less leakage
19	29.3.76 14.3.77	20	F	6/6 6/6 6/9 6/9	clear	+	+	+	-	+	+	+	S	More leakage
20	21.7.75 23.3.77	21	F	6/9 6/12 6/9 6/9	clear	-	+	+	clear	+	-	+	S	No change
21	14.7.72 14.9.77	21	M	6/7.5 6/5 6/24 6/5	Post subcap. op. in RE	CM atrophic	(Right macula)	++	-	-	+	-	S	Unilateral RP
22	26.11.75	53	F	6/60 6/60		+				+	+	+		History of taking Chloroquin for 25 years
23	23.3.77	44	F	6/60 CF	Moderate post. subcap. op BE	+	++	++	-	+	+	+	AD or XL	Paternal aunt with RP
24	2.3.77	55	M	6/60 6/24	clear	-	++	++	-	+	-	+	AD or XL	One brother with RP Cone/rod dystrophy
25	17.6.77	31	M	6/18 6/60	clear	+	+	+	-	+	+	+		Coats's disease of LE
26	24.7.77 14.7.77	7	F	5/60 4/60 HM CF	clear	'Bull's eye' macula				-	-	-	+	Batten's disease Increasing leakage

*Case 8 is quoted by the kind permission of Dr Dwain Fuller, Miami.

AD = Autosomal dominant. XL = X-linked. AR = Presumed autosomal recessive. S = Sporadic. Blank spaces indicate no observation recorded



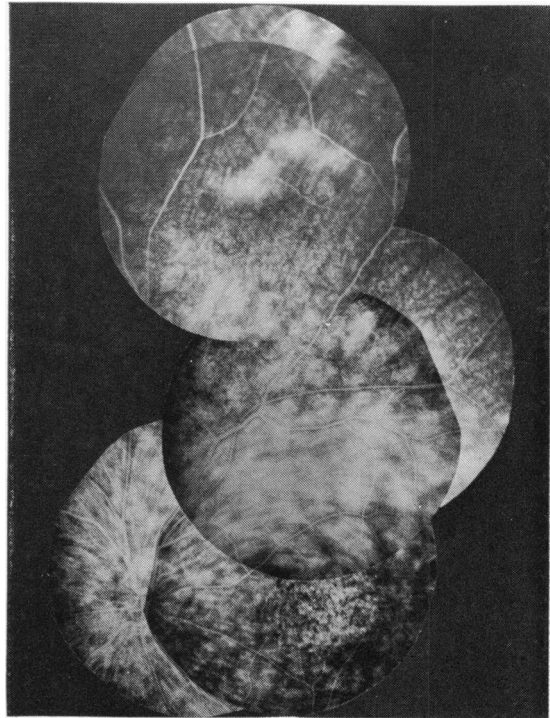
8a

Fig. 8 Case 26. With Batten's disease. Angiography at age 5 showed leakage from peripheral retinal vessels only (a). One year later there was extensive leakage of dye throughout the fundus but not at the macula

kind permission of the editor of the transactions of the Ophthalmological Society of the United Kingdom.

References

- Archer, D. B. (1975). Some observations on blood retinal barriers in health and disease. *New Developments in Ophthalmology*. Edited by A. F. Deutman. *Documenta Ophthalmologica Proceedings Series*, 7, 155-167.
- Ayesh, I., Sanders, M. D., and Friedmann, A. I. (1976). Retinitis pigmentosa and Coats's disease. *British Journal of Ophthalmology*, 60, 775-777.
- Bird, A. C. (1975). X-linked retinitis pigmentosa. *British Journal of Ophthalmology*, 59, 177-199.
- Chester, G. H., Blach, R. K., and Cleary, P. E. (1976). Inflammation in the region of the vitreous base. *Transactions of the Ophthalmological Societies of the United Kingdom*, 96, 151-157.
- Chopdar, A. (1976). Annular choroidal sclerosis. *British Journal of Ophthalmology*, 60, 512-516.
- Deutman, A. F. (1976). Personal communication.
- Deutman, A. F., Pinckers, A. J. L. G., and Aan de Kerk, A. (1976). Cystoid macular oedema. *American Journal of Ophthalmology*, 82, 540-548.
- ffytche, T. J. (1972). Cystoid maculopathy in retinitis pigmentosa. *Transactions of the Ophthalmological Societies of the United Kingdom*, 92, 265-283.
- Fishman, G. A., Jampol, L. M., and Goldberg, M. F. (1976). Diagnostic features of the Favre-Goldmann syndrome. *British Journal of Ophthalmology*, 60, 345-353.
- Fishman, G. A., Fishman, M., and Maggiano, J. (1977). Macular lesions associated with retinitis pigmentosa. *Archives of Ophthalmology*, 95, 798-803.
- François, J., de Laey, J. J., and Verbraeken, H. (1972). L'oedeme kystoïde de la macula. *Bulletin de la Société Belge d'Ophthalmologie*, 161, 708-721.
- Gass, J. D. M. (1970). In *Stereoscopic Atlas of Macular Disease*, p. 154. C. V. Mosby: St. Louis.
- Hyvarinen, L., Maumenee, A. E., Kelly, J., and Cantollino, S. (1971). Fluorescein angiographic findings in retinitis pigmentosa. *American Journal of Ophthalmology*, 71, 17-26.
- Jay, B. S., and Bird, A. C. (1973). Genetic aspects of retinitis pigmentosa in London. *Transactions of the American*



8b

- Academy of Ophthalmology and Otolaryngology*, **77**, 641–651.
- Lanier, J. D., McCrary, J. A., and Justice, J. (1976). Autosomal recessive retinitis pigmentosa and Coats's disease. *Archives of Ophthalmology*, **94**, 1737–1742.
- Maumenee, A. E. (1970). Clinical entities in uveitis. An approach to the study of intraocular inflammation. Jackson Lecture. *Transactions of the American Academy of Ophthalmology and Otolaryngology*, **74**, 473–504.
- Merin, S. (1970). Macular cysts as an early sign of tapeto-retinal degeneration. *Journal of Paediatric Ophthalmology*, **7**, 225–228.
- Morgan, W. E., and Crawford, J. B. (1968). Retinitis pigmentosa and Coats's disease. *Archives of Ophthalmology*, **79**, 146–149.
- Norton, A. L., Brown, W. J., Carlson, M., and Pilger, I. S. (1975). The pathogenesis of aphakic macular oedema. *American Journal of Ophthalmology*, **80**, 96–101.
- Notting, J. G. A., and Deutman, A. F. (1976). Leakage from retinal capillaries in hereditary dystrophies. International Symposium on Fluoroangiography. Edited by J. J. de Laey. *Documenta Ophthalmologica Proceedings Series*, **9**, 439–447.
- Schmidt, D., and Faulborn, J. (1970). Retinopathia pigmentosa mit Coats-syndrom (Retinitis pigmentosa with Coats's syndrome). *Klinische Monatsblätter für Augenheilkunde*, **157**, 643–652.
- Schmidt, D., and Faulborn, J. (1972). Familiäres Vorkommen von Coats-syndrom kombiniert mit Retinopathia pigmentosa. *Klinische Monatsblätter für Augenheilkunde*, **160**, 158–163.
- Welch, R. B., Maumenee, A. E., and Whalen, H. E. (1960). Peripheral posterior segment inflammation. Vitreous opacities and oedema of the posterior pole. *Archives of Ophthalmology*, **64**, 540–549.
- Zamorani, G. (1956). Un' rara associazione di retinite di Coats con retinite pigmentosa. *Giornale italiano di oftalmologia*, **2**, 429–443.