

Measles retinopathy during immunosuppression

M. HALTIA, A. TARKKANEN, A. VAHERI, A. PAETAU, K. KAAKINEN, AND H. ERKKILÄ

From the Departments of Pathology, Ophthalmology, and Virology, University of Helsinki, Finland

SUMMARY A 14-year-old boy had an acute attack of measles while on cytotoxic chemotherapy for a testicular neoplasm. Two months later a fatal measles encephalopathy developed, verified by histological, ultrastructural, and immunofluorescent studies. Ophthalmoscopy showed progression of flat depigmented areas of the retina as well as prominent lesions mimicking central serous retinopathy or retinitis. Histopathological studies showed focal retinal necroses with invasion of pigment-laden macrophages into the retina. There were no inflammatory cell infiltrations in the choroid. The presence of structures with the morphological and antigenic properties of measles virus in the affected areas of the retina was shown by electron microscopy and indirect immunofluorescence. With the increase of immunosuppressive therapy for various purposes the incidence of opportunistic measles virus infections is likely to rise. In the clinical management of such complications ophthalmological examination may prove very helpful.

During recent years several reports have appeared on an unusual and fatal encephalopathy apparently caused by measles virus invasion of the central nervous system in children treated for leukaemia (Breitfeld *et al.*, 1973; Sluga *et al.*, 1975; Drysdale *et al.*, 1976; Mellor, 1976; Pullan *et al.*, 1976; Smyth *et al.*, 1976; *British Medical Journal*, 1976). We have reported on the occurrence of a similar encephalopathy in a 14-year-old boy on cytotoxic chemotherapy for a testicular rhabdomyosarcoma (Haltia *et al.*, 1977). On the basis of our case and other recent reports (Lyon, 1972; Murphy and Yunis, 1976; Nihei *et al.*, 1977; Wolinsky *et al.*, 1977) it seems clear that this serious complication must be borne in mind during any form of cytotoxic treatment, immunosuppression, or immunodeficiency state lowering the resistance of the host to measles virus (Haltia *et al.*, 1978). In our case we noted characteristic, rapidly progressive retinal changes, not reported by previous workers.

In this report we will describe the ophthalmological findings in detail. It will be shown by electron microscopic and immunofluorescent studies that the retinal lesions are indeed caused by measles virus, and that the fundoscopic alterations may be helpful in the diagnosis of this condition during life.

Case report

A 13-year-old boy was operated on for a testicular

rhabdomyosarcoma of embryonal type in April 1975. After the operation the patient was well, without signs of metastasis, and he was kept on vincristine-actinomycin-cyclophosphamide cytotoxic chemotherapy. After 2 months vincristine had to be discontinued, but the treatment with the 2 other drugs was continued.

In April 1976 the patient had an acute attack of measles, followed by continued fever for 1 month. He also lost weight, and his sedimentation rate rose to 90 mm in the first hour. In June 1976 he had 2 convulsive attacks and he was admitted to hospital. There were no signs of extracranial metastasis, and the cerebrospinal fluid, brain scan, and left carotid angiogram were normal. The electroencephalogram showed a prominent slow-wave disturbance in the left hemisphere. Fundoscopic examination revealed depigmented lesions in both eyes (Fig. 1), and inferotemporally to the macula a greyish raised lesion was seen resembling central serous retinopathy. There was no exudation into the vitreous.

The general condition of the patient deteriorated rapidly. He developed a right hemiplegia with aphasia. At this stage, 1 week after the first ophthalmological examination, ophthalmoscopy was repeated, and a considerable progression of the retinal changes was recorded (Fig. 2). The patient died 3 months after the measles infection and 4 weeks after the onset of neurological symptoms.

Necropsy was carried out 19 hours after death. No signs of recurrence of the primary tumour or metastasis were found. At histological examination of the brain numerous intranuclear inclusion bodies

Address for reprints: Dr M. Haltia, Department of Pathology, University of Helsinki, Haartmaninkatu 3, SF-00290 Helsinki 29, Finland

were found both in oligodendroglial cells and in neurons, particularly in the left lenticular region and internal capsule. These inclusion bodies consisted of masses of tubular structures with the ultrastructural and immunofluorescent properties of measles virus nucleocapsids. In the same region there was severe oedema, but inflammatory cell infiltration was absent except for some macrophage reaction (for detailed neuropathological description, see Haltia *et al.*, 1977).

Materials and methods

The eyes were removed 19 hours after death, fixed in 4% phosphate-buffered formaldehyde, and embedded in paraffin. Small pieces of formalin-fixed material were post-fixed in glutaraldehyde and osmium tetroxide and processed for electron microscopy.

Routine paraffin sections of the eye (the paraffin melting point was 56°C; the paraffin blocks were

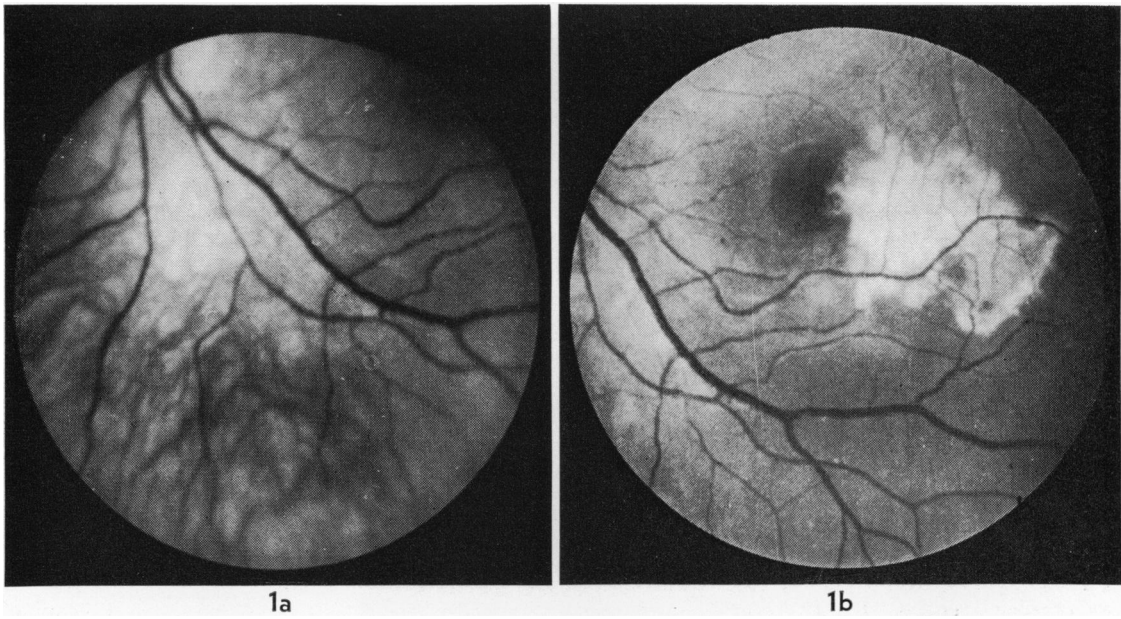


Fig. 1 (a) Funduscopy of the left eye shows irregular, flat, depigmented areas below the optic disc. (b) One week later, funduscopy shows a greyish elevated retinal lesion measuring at least 2 × 2 disc diameters inferotemporal to the macula

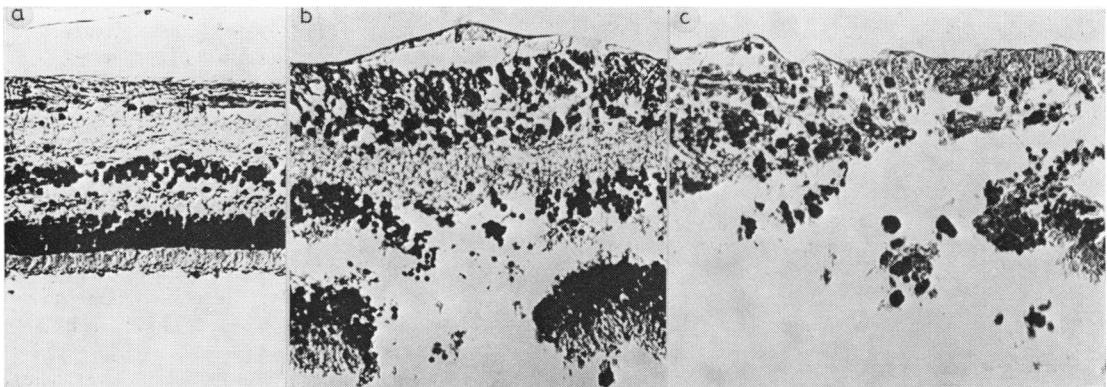


Fig. 2 (a) The retina in the non-affected area is not remarkable. (b) Beginning retinal necrosis with destruction of the photoreceptors and of the bipolar cells. (c) Extensive retinal necrosis with scattered pigment-laden macrophages. Only remains of occasional retinal cells and of the internal limiting membrane can be seen × 200

stored at room temperature) were deparaffinised and stained by indirect immunofluorescence using hyperimmune antimeasles virus rabbit serum, human SSPE (subacute sclerosing panencephalitis)-serum, kindly provided by Dr A. Salmi of the University of Turku, a negative rabbit control serum, a low-titre human control serum (measles haemagglutination inhibition titre 1:20), and commercially obtained fluoresceinated antirabbit or antihuman gammaglobulin.

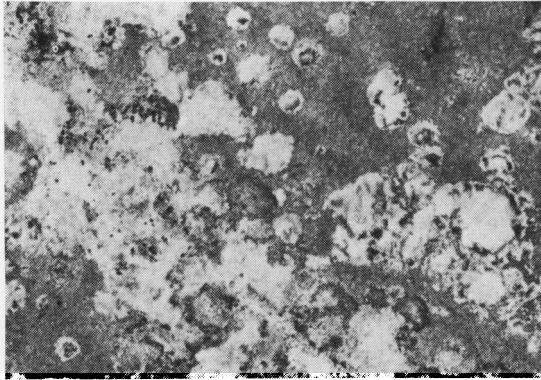


Fig. 3 Flat mount of the retinal pigment epithelium shows patchy loss of pigment with scattered macrophages, visible as black dots $\times 30$

Results

The anterior structures of the eye were not remarkable. Large areas of the retina appeared entirely normal (Fig. 2a) except for slight oedema in the outer plexiform layer. The most prominent pathological feature was, however, the presence of patchy focal retinal necrosis. In the necrotic areas the retinal structures had disappeared without signs of reparative gliosis. Only occasional traces of the inner nuclear layer and the internal limiting membrane were left (Fig. 2b, c). There was a total absence of inflammatory cells except for invasion of large numbers of pigment-laden macrophages in the retina. The pigment epithelium showed a patchy loss of pigment (Fig. 3). The choroid appeared normal without any signs of inflammation. No definite inclusion bodies were found by light microscopy.

Electron microscopy of the affected regions of the retina showed some remaining nuclei, particularly those of the inner nuclear layer, were studied with cross-hatched tubular structures, approximately 15 to 17 nm in diameter. Occasionally these structures, resembling the nucleocapsids of paramyxoviruses, entirely filled the nucleus and were pushed through the disrupted nuclear membrane towards the cytoplasm (Fig. 4). In the limited number of specimens

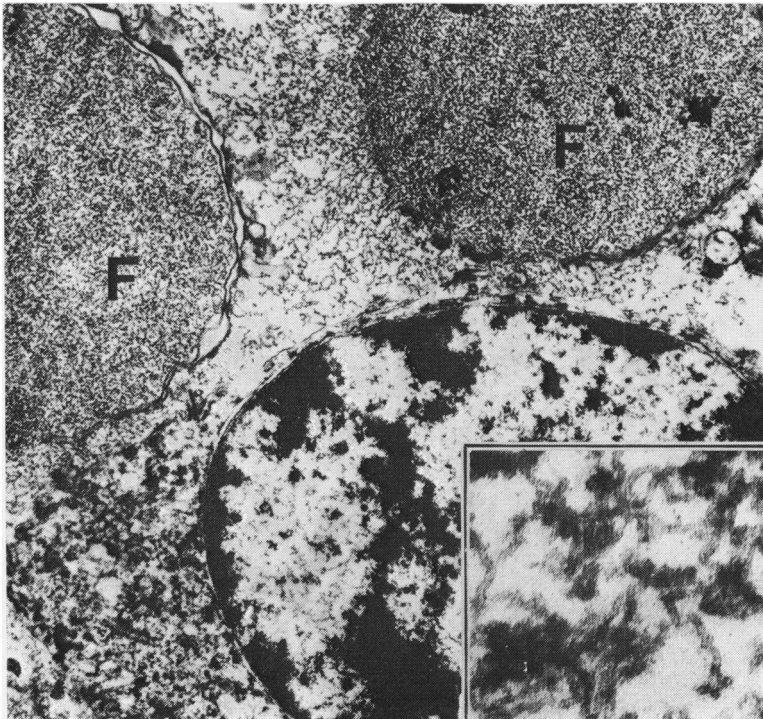


Fig. 4 Nuclei of 2 retinal cells are filled with filamentous material (F) pushing out through the disrupted nuclear membrane ($\times 10\ 900$). Inset: Longitudinal and cross-sectional profiles of the paramyxovirus nucleocapsid-like tubular structures $\times 60\ 000$

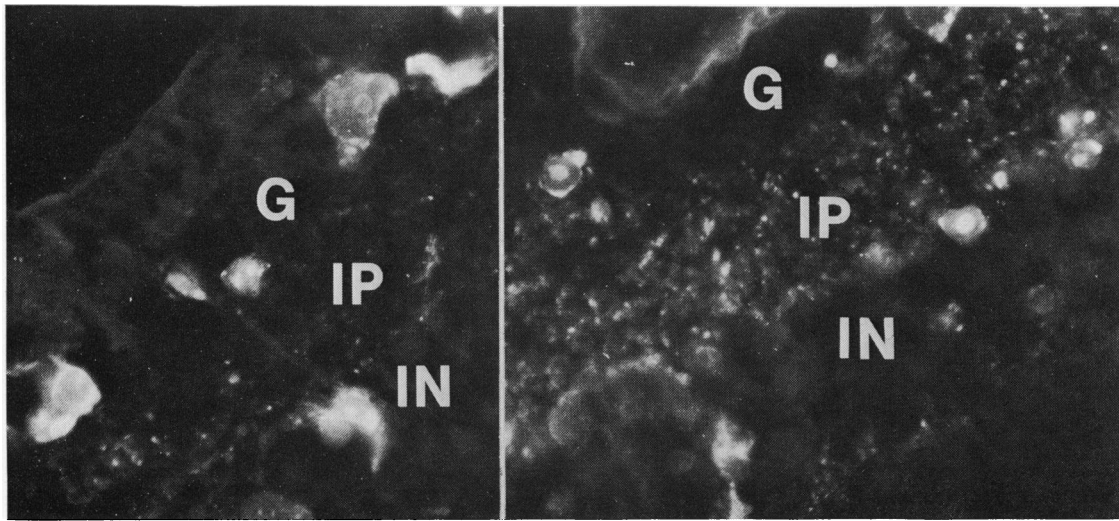


Fig. 5 Bright specific fluorescence in the nuclei and cytoplasm of scattered retinal cells of the ganglion cell (G) and inner nuclear (IN) layers as well as small fluorescent spots in the inner plexiform layer (IP). Indirect staining with hyperimmune antimeasles virus rabbit serum $\times 700$

available for electron microscopy it was not possible to identify these particles in the pigment epithelium.

In the histologically affected areas many nuclei of the inner nuclear layer and occasional ganglion cells showed a bright fluorescence on indirect immunofluorescence with hyperimmune antimeasles virus rabbit serum and human SSPE-serum (Fig. 5). Scattered small fluorescent spots were also seen in the inner and outer plexiform layers. Negative results were obtained with the control sera (Table 1).

Discussion

The incidence of complicating opportunistic viral infections is likely to rise with increase in the use of immunosuppressive therapy for a variety of neoplastic and autoimmune disorders and in association with transplantation surgery. Owing to the altered host response the clinical and histopathological manifestations of these infections may be highly atypical. Ocular involvement, including typical inclusion bodies and focal necrosis of the retina in congenital cytomegalic inclusion disease in an immunologically defective child, was described by Tarkkanen *et al.* (1972). Similar retinal changes have also been reported in association with rubella (Krill, 1972) and herpes simplex infection in immunologically defective persons (Minckler *et al.*, 1976; Johnson and Wisotzkey, 1977). Though measles virus seems to be able to produce an unusual type of encephalopathy during immunosuppression (see introduction), we are not aware of

Table 1 Measles retinopathy during immunosuppression: demonstration of measles virus antigen by indirect immunofluorescence

Antiserum	Conjugate	Retinal nuclei	Plexiform layers
Rabbit hyperimmune antimeasles virus serum	Fluoresceinated antirabbit IgG	+++	+
Rabbit negative control serum	„	—	—
Human SSPE serum	Fluoresceinated antihuman IgG	+++	+
Human control serum (measles HI titre 1:20)	„	(+)	—

previous reports on retinal lesions in this condition.

However, it is by now well known (Karel *et al.*, 1971) that quiet pigmentary changes due to scar formation are a frequent ophthalmoscopic finding in subacute sclerosing panencephalitis, a condition apparently caused by a modified measles virus (Katz, 1977). The acute stages of the ocular lesions in SSPE probably often precede the clinical manifestation of the central nervous system disease and remain unrecognised (Karel *et al.*, 1971). If they are identified at an early stage they mimic central serous retinopathy (Otradovec, 1969) and ophthalmoscopically closely resemble the retinal lesions seen in the present case. The histological lesions in SSPE consist of a retinitis of the neural and pigment epithelium, choroidal involvement being limited to the choriocapillaris (Nelson *et al.*,

1970). In one case of SSPE measles virus has been shown in the retinal neuroepithelium by electron microscopy (Landers and Klintworth, 1971) and in another by combined electron microscopy and immunofluorescence (Font *et al.*, 1973). In our case the presence of measles virus was established by electron microscopy and by immunofluorescence, but the retinal lesions were characterised by patchy focal necrosis without inflammatory cell infiltration, apart from macrophage reaction.

Measles, a frequently fatal disease among the malnourished populations of developing countries, is generally considered to be the most important cause of blindness in children in East Africa (Rodger, 1959). The cases of Donders (1976) from Kenya showed major changes in the anterior ocular structures: anterior staphyloma, aphakia, and chronic glaucoma. The retina showed degeneration of the ganglion cell layer and of the retinal pigment epithelium with scattering of pigment throughout the retina and around the retinal vessels. There were no inflammatory changes. These findings may be interpreted as secondary to the anterior ocular changes and ensuing secondary glaucoma. In sharp contrast to these findings in Kenyan children the anterior ocular structures in our case were not remarkable, and the retinal changes consisted of focal abrupt retinal destruction. Our findings thus lend support to the theory of Franken (1974) that something else, most probably xerophthalmia, rather than measles is the real cause of blindness in East Africa.

Fundus lesions in a patient with a history of previous malignant tumour elsewhere in the body will arouse suspicion of ocular metastasis. Choroidal metastases, however, most often assume a flat configuration in the posterior uvea, while the measles-induced changes in the present case showed flat depigmented areas and focal retinal necrosis. In these terms ophthalmoscopy may prove helpful in the clinical differential diagnosis.

References

- Breitfeld, V., Hashida, Y., Sherman, F. E., Odagiri, K., and Yunis, E. J. (1973). Fatal measles infection in children with leukemia. *Laboratory Investigation*, **28**, 279–291.
- 'British Medical Journal' (1976). Measles encephalitis during immunosuppressive treatment. *British Medical Journal*, **1**, 1552.
- Donders, P. C. (1976). Xerophthalmia. Presented at the Joint Meeting of the Verhoeff Society and European Ophthalmic Pathology Society, Washington, DC, 26–29 May.
- Drysdale, H. C., Jones, L. F., Oppenheimer, D. R., and Tomlinson, A. H. (1976). Measles inclusion-body encephalitis in a child with treated acute lymphoblastic leukaemia. *Journal of Clinical Pathology*, **29**, 865–872.
- Font, R. L., Jenis, E. H., and Tuck, K. D. (1973). Measles maculopathy associated with subacute sclerosing panencephalitis. *Archives of Pathology*, **96**, 168–174.
- Franken, S. (1974). Measles and xerophthalmia in East Africa. *Tropical and Geographical Medicine*, **26**, 39–44.
- Haltia, M., Paetau, A., Vaheri, A., Erkkilä, H., Donner, M., Kaakinen, K., and Holmström, T. (1977). Fatal measles encephalopathy with retinopathy during cytotoxic chemotherapy. *Journal of the Neurological Sciences*, **32**, 323–330.
- Haltia, M., Paetau, A., Vaheri, A., and Salmi, A. (1978). Measles encephalopathy during immunosuppression. *Scandinavian Journal of Infectious Diseases*. (In press.)
- Johnson, B. L., and Wisotzkey, H. M. (1977). Neuroretinitis associated with herpes simplex encephalitis in an adult. *American Journal of Ophthalmology*, **83**, 481–489.
- Karel, I., Otradovec, J., Peleška, M., and Nevsimal, O. (1971). Fluoroangiographic picture of the macular lesion in subacute sclerosing leucoencephalitis van Bogaert. *Ophthalmologica* (Basel), **162**, 348–354.
- Katz, M. (1977). Subacute sclerosing panencephalitis. In *Slow Virus Infections of the CNS*, pp. 106–115. Edited by V. Meulen and M. Katz. Springer Verlag: Berlin.
- Krill, A. E. (1972). Retinopathy secondary to rubella. *International Ophthalmology Clinics*, **12**, 89–103.
- Landers, M. B., III, and Klintworth, G. K. (1971). Subacute sclerosing panencephalitis (SSPE). *Archives of Ophthalmology*, **86**, 156–163.
- Lyon, G. (1972). Examen ultra-structural du cerveau dans trois encéphalopathies aiguës et chroniques. *Archives Françaises de Pédiatrie*, **29**, 641–654.
- Mellor, D. (1976). Encephalitis and encephalopathy in childhood leukaemia. *Developmental Medicine and Child Neurology*, **18**, 90–98.
- Minckler, D. S., McLean, E. B., Shaw, C. M., and Hendrickson, A. (1976). Herpesvirus hominis encephalitis and retinitis. *Archives of Ophthalmology*, **94**, 89–95.
- Murphy, J. V., and Yunis, E. J. (1976). Encephalopathy following measles infection in children with chronic illness. *Journal of Pediatrics*, **88**, 937–942.
- Nelson, D. A., Weiner, A., Yanoff, M., and De Peralta, J. (1970). Retinal lesions in subacute sclerosing panencephalitis. *Archives of Ophthalmology*, **84**, 613–621.
- Nihei, K., Kamoshita, S., Mizutani, H., Kitayama, T., and Nishimura, H. (1977). Atypical subacute sclerosing panencephalitis. *Acta Neuropathologica* (Berlin), **38**, 163–166.
- Otradovec, J. (1969). Das klinische Bild der zentralen chorioretinalen Veränderungen bei subakuter sklerosierender Leukoencephalitis (van Bogaert). *Ophthalmologica*, **157**, 427–441.
- Pullan, C. R., Noble, T. C., Scott, D. J., Wisniewski, K., and Gardner, P. S. (1976). Atypical measles infections in leukaemic children on immunosuppressive treatment. *British Medical Journal*, **1**, 1562–1565.
- Rodger, F. C. (1959). Blindness in West Africa. Cited by Duke-Elder, S. (1965). *System of Ophthalmology*, Vol. 3, Pt. 1, p. 335. Kimpton: London.
- Sluga, E., Budka, H., Jellinger, K., and Pichler, E. (1975). SSPE-like inclusion body disorder in treated childhood leukemia. *Acta Neuropathologica*, Suppl. 6, 267–272.
- Smyth, D., Tripp, J. H., Brett, E. M., Marshall, W. C., Almeida, J., Dayan, A. D., Coleman, J. C., and Dayton, R. (1976). Atypical measles encephalitis in leukaemic children in remission. *Lancet*, **2**, 574.
- Tarkkanen, A., Merenmies, L., and Holmström, T. (1972). Ocular involvement in congenital cytomegalic inclusion disease. *Journal of Pediatric Ophthalmology*, **9**, 82–86.
- Wolinsky, J. S., Swoveland, P., Johnson, K. P., and Baringer, J. R. (1977). Subacute measles encephalitis complicating Hodgkin's disease in an adult. *Annals of Neurology*, **1**, 452–457.