

Visual field defects in onchocerciasis

BJØRN THYLEFORS AND ASBJØRN M. TØNJUM

From the University Eye Department, Rikshospitalet, Oslo

SUMMARY Lesions in the posterior segment of the eye in onchocerciasis may give visual field defects, but so far no detailed investigation has been done to determine the functional visual loss. Examination of the visual fields in 18 selected cases of onchocerciasis by means of a tangent screen test revealed important visual field defects associated with lesions in the posterior segment of the eye. Involvement of the optic nerve seemed to be important, giving rise to severely constricted visual fields. Cases of postneuritic optic atrophy showed a very uniform pattern of almost completely constricted visual fields, with only 5 to 10° central rest spared. Papillitis gave a similar severe constriction of the visual fields.

The pattern of visual fields associated with optic neuropathy in onchocerciasis indicates that a progressive lesion of the optic nerve from the periphery may be responsible for the loss of vision. The visual field defects in onchocerciasis constitute a serious handicap, which must be taken into consideration when estimating the socioeconomic importance of the disease.

Lesions in the posterior segment of the eye associated with onchocerciasis are well known, but the relationship between these lesions and the loss of visual function is less clear. Recent studies by Bird *et al.* (1976) indicate that the lesions of the retina and the choroid and of the optic nerve may be responsible for major losses of vision. In previous works the association between onchocerciasis and 'papillitis' and postneuritic atrophy of the optic nerve has been documented (Vedy *et al.*, 1971, 1975; Anderson *et al.*, 1974). Optic nerve disease in onchocerciasis is considered to be of inflammatory origin, and microfilariae have been found in the optic nerve tissue (Rodger, 1960; Paul and Zimmerman, 1970).

The influence of optic nerve disease and/or fundus lesions due to onchocerciasis on the visual fields needs further investigation. Vedy *et al.* (1975) observed 1 case with papillitis in which a constriction of the visual fields was confirmed by a tangent screen test. Bird *et al.* (1976) used a simple confrontation test (Donders's test) and found severely constricted visual fields in patients with optic nerve disease. However, in general ophthalmology it is unusual for papillitis or inflammation of the optic nerve to result in constriction of the visual fields without central or para-central scotoma. It therefore seemed to be of importance to study in more detail the pattern of visual field defects in onchocerciasis.

The purpose of this paper is to present the results of an investigation of the visual fields in selected cases of ocular onchocerciasis with lesions in the posterior segment of the eye.

Material and methods

A total of 18 selected cases of ocular onchocerciasis with lesions of the posterior segment of the eye were examined during field surveys for the WHO Onchocerciasis Control Programme in the Volta River basin area.

An ophthalmological examination of each patient was carried out in a dark-room. The anterior segment was studied with a Haag-Streit 900 slit lamp. The microfilariae were counted and registered, after which the intraocular pressure was measured with applanation tonometry, and the pupils were dilated with tropicamide 1%. The fundus was examined with direct and indirect ophthalmoscopy, and photographs of fundus lesions were taken with a Kowa RC-2 camera.

Visual acuity was determined with the Sjögren hand test at 5 different levels from 1.0, corresponding to 6/6, to 0.05 (3/60). Each eye was tested separately without glass correction.

The central visual fields were examined using a 2×2 m black tangent screen (Bjerrum screen) and a white object 5 mm in diameter. The distance between the patient's eye and the screen was 1.1 m. The right eye was examined first. The procedure and the meaning of the test were carefully explained

Table 1 Observations in 18 cases of ocular onchocerciasis with visual field defects. VA = visual acuity, OA = optic atrophy

Case no.	Age	Visual acuity R/L	Optic discs	Fundus	Visual fields
1	37	1·0/1·0	Normal	Bilat. temporal mottl. of retina	Large nasal defects bilaterally. Normal blind spots
2	16	0·3/0·1	Normal	Mottled retina post. poles, fovea spared	Nasal and temporal defects bilaterally
3	29	1·0/1·0	Normal	Mottled retina post. poles, fovea spared	Constricted visual fields, most pronounced nasally (see Fig. 5)
4	36	1·0/1·0	Normal	Mottled retina post. poles, foveae spared	Severely constricted fields, to less than 10° central rest (see Fig. 5)
5	41	1·0/1·0	Normal	Temporal retinal mottling + atrophy	Large nasal defects bilat. Normal blind spots
6	40	0·1/0·3	Normal	Nasal and temporal atrophy of retina	Constricted fields, to less than 20° bilaterally
7	25	0·1/0·1	R: post-n. OA L: normal	Temporal retinal mottling + atrophy	R: Severely constricted field, to less than 5° central rest L: large nasal defect, slight temporally
8	25	0·3/0·3	Post-n. OA	Temporal retinal mottling bilat.	Severely constricted fields, to less than 10° central rest bilaterally
9	16	1·0/0·3	Post-n. OA	Temporal retinal mottling bilat.	Constricted fields, most pronounced left, to less than 20° central rest (Fig. 5)
10	40	1·0/0·7	Post-n. OA	Mottled retina post. poles, foveae spared	Severely constricted fields, to less than 10° central rest bilaterally
11	40	0·3/0·3	Post-n. OA	Mottled retina post. poles, foveae spared	Severely constricted fields, to less than 10° central rest bilaterally
12	60	0·7/0·7	Post-n. OA	Mottled retina post. poles, foveae spared	Severely constricted fields, to less than 10° central rest bilaterally
13	26	0·7/0·3	Post-n. OA	Mottled retina post. poles, foveae spared	Severely constricted fields, to less than 5° central rest bilaterally
14	12	0·1/0·1	R: post-n. OA L: pale disc	Normal	R: constricted to less than 5° central rest L: constricted to less than 10° central rest (Fig. 6)
15	35	0·05/0·1	Post-n. OA bilat.	Normal	Severely constricted fields, to less than 5° bilaterally (Fig. 6)
16	23	1·0/0·7	Post-n. OA	Retinal mottling + atrophy temporally	Severely constricted fields, to less than 5° central rest bilaterally
17	63	0·3/0·7	R: post-n. OA	Retinal mottling + atrophy temp. bilat.	Severely constricted fields, to less than 5° (R) and 12° (L) central rest
18	38	0·05/0·05	Papillitis bilat.	Mottled retina post. poles, foveae spared	Severely constricted fields, to less than 5° central rest bilaterally (Fig. 6)

to each person. In all individuals, whenever possible, care was taken to determine the blind spot. The result of the examination was recorded on visual field charts. Every patient was also carefully examined with a confrontation test for the peripheral visual field limits, with the use of hand and finger movements or smaller objects when possible. The visual fields were studied in daylight.

Results

All the 18 patients were men, with an average age of 33·4 years, ranging from 12 to 63 years (Table 1). They all had microfilariae in the anterior segment of the eyes and in skin snips from both iliac crests. In 4 eyes there were microfilariae on the posterior

lens surface or in the vitreous. Early sclerosing keratitis, not influencing the central optical zone of the cornea, was present in 8 cases (Nos. 1, 2, 3, 5, 7, 8, 10, and 14), who also had iritis. In Case 2 there were posterior synechiae. In 9 of the cases (Nos. 3, 4, 6, 7, 8, 9, 11, 13, and 14) the pupils were dilated and poorly reacting to light. The intraocular pressure was normal in all cases, ranging from 7 to 18 mmHg, but reliable readings could not be obtained in 2 cases. However, none showed signs of glaucoma. The visual acuity was 1·0 in 11 eyes, 0·7 in 6 eyes, 0·3 in 9 eyes, 0·1 in 7 eyes, and 0·05 in 3 eyes.

The *optic discs* were assessed to be normal in 6 cases but were pale in 11 cases; the pallor was considered to be due to 'postneuritic' atrophy of the optic nerve. One patient had oedema and

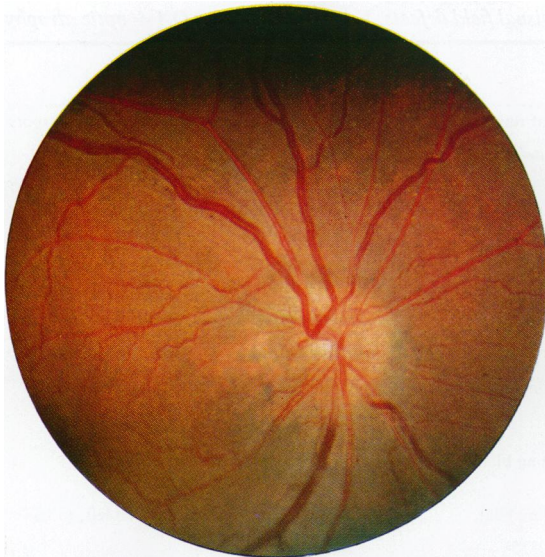


Fig. 1 *Oedema and congestion of the optic disc in Case 18*

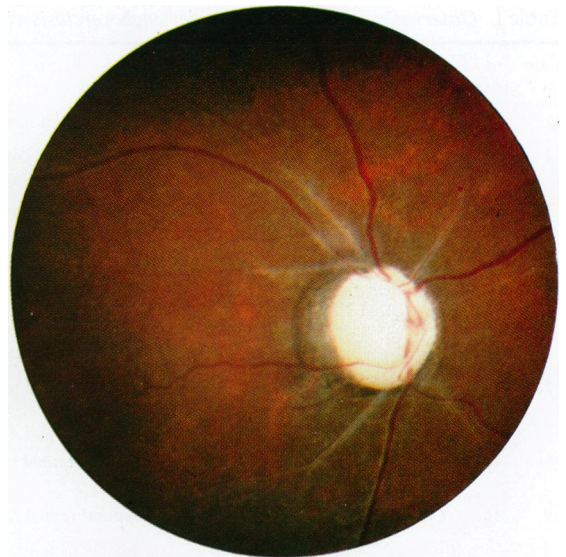


Fig. 2 *Postneuritic optic atrophy with extensive sheathing of the central retinal vessels (Case 15)*

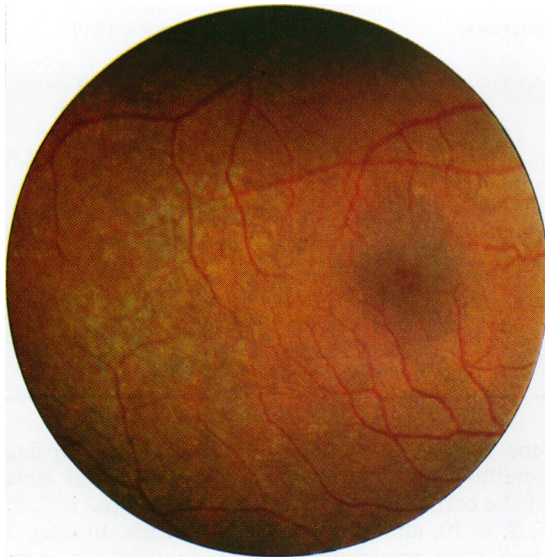


Fig. 3 *Mottling of the retinal pigment epithelium temporal to the fovea (Case 1)*

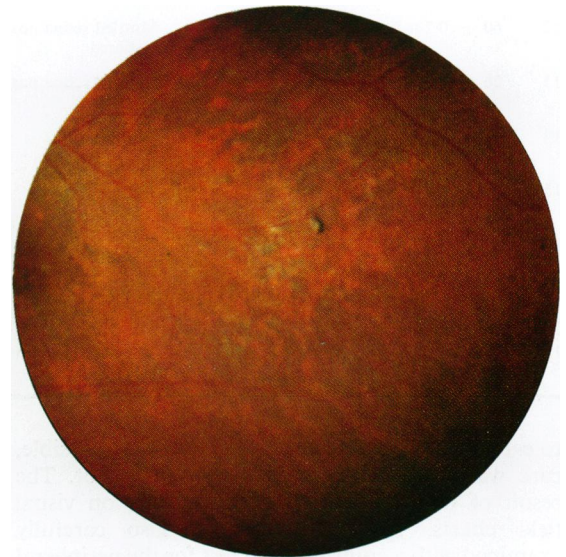


Fig. 4 *Mottling and atrophy of the retinal pigment epithelium with slight involvement of the choriocapillary vessels (Case 5)*

congestion of the optic disc in both eyes (Fig. 1). All those with markedly pale discs had peripapillary pigmentation, and in addition 4 had extensive sheathing of the central arteries and veins (Fig. 2).

The retina was normal in 2 cases, Nos. 14 and 15. An uneven mottling of the pigment epithelium (Fig. 3), attributed to onchocerciasis, was the most

prevalent lesion. It was the only retinal change in 11 cases. In 5 cases (Nos. 5, 6, 7, 16, and 17) there was more extensive atrophy of the pigment epithelium along with disease of the choriocapillary vessels (Fig. 4). The retinal lesions were most frequently found temporal to the fovea. In some cases the whole posterior pole was involved, but with a characteristic

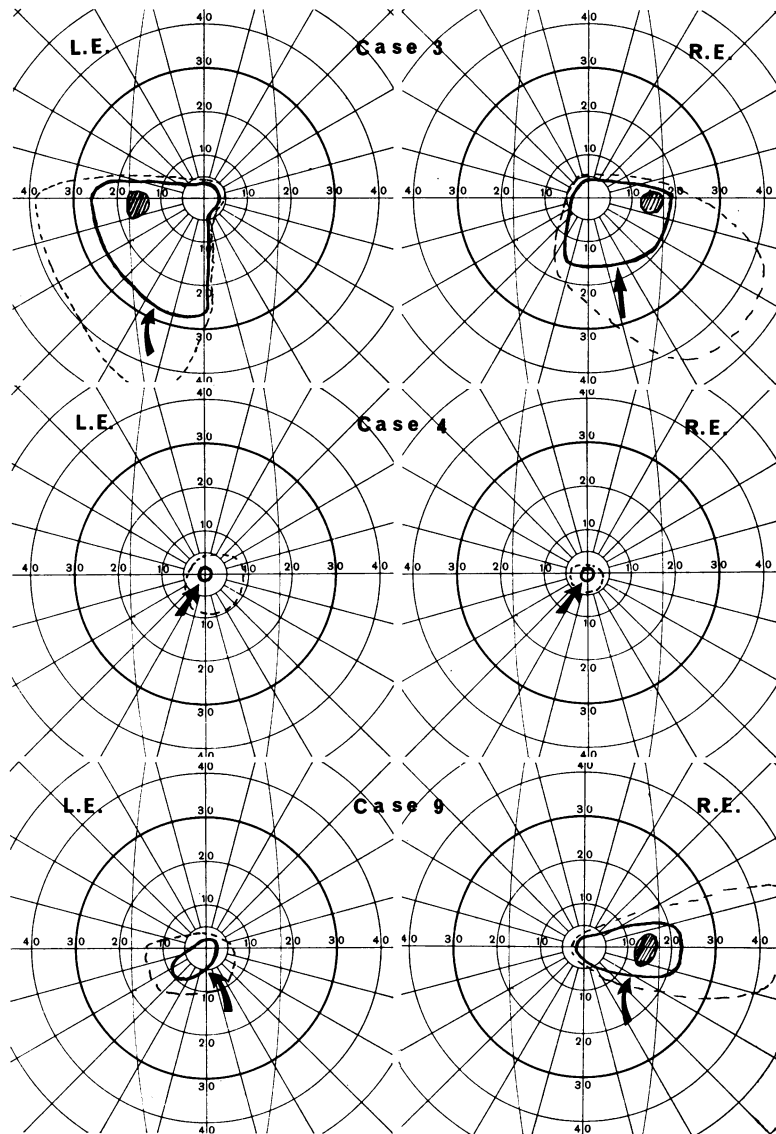


Fig. 5 Visual fields in onchocerciasis. Fully drawn line: outer limits with tangent screen test. Dotted line: estimated outer limits with confrontation test. Case 3: Gross peripheral mainly nasal defects. Case 4: Severely constricted visual fields bilaterally in a case with mottling of the retina. Case 9: Visual fields associated with postneuritic optic atrophy and discrete mottling of the retina temporal to the fovea

sparing of the fovea. In no case were isolated lesions above or below the optic discs observed.

The visual fields of Cases 1, 2, 3, and 5 were similar to each other (Case 3, Fig. 5). They all had irregular peripheral gross defects, mainly on the nasal side. These cases had apparently normal discs but mottling of the retina, especially temporal to the fovea.

Case 4 had severely constricted visual fields (Fig. 5). This patient had seemingly normal discs but mottling of the retina like the previous cases. Nevertheless, only small central islands were left of the visual fields. The visual acuity was 1.0 in both

eyes. In Case 6 similar observations were done.

Case 7 had a postneuritic optic atrophy of the right eye but a normal disc on the left side. Both fundi had mottling and atrophy of the retina temporal to the fovea. The visual field of the right eye was constricted with a central rest of less than 5°. The left eye had a gross nasal defect and a slight temporal constriction of the visual field.

The Cases 8 to 17 were similar to each other in their visual fields. They all had a postneuritic optic atrophy. The majority also had mottling or atrophy of the retina (Table 1). In Figs 5 and 6 the visual fields of Cases 9, 14, and 15 are shown, all severely

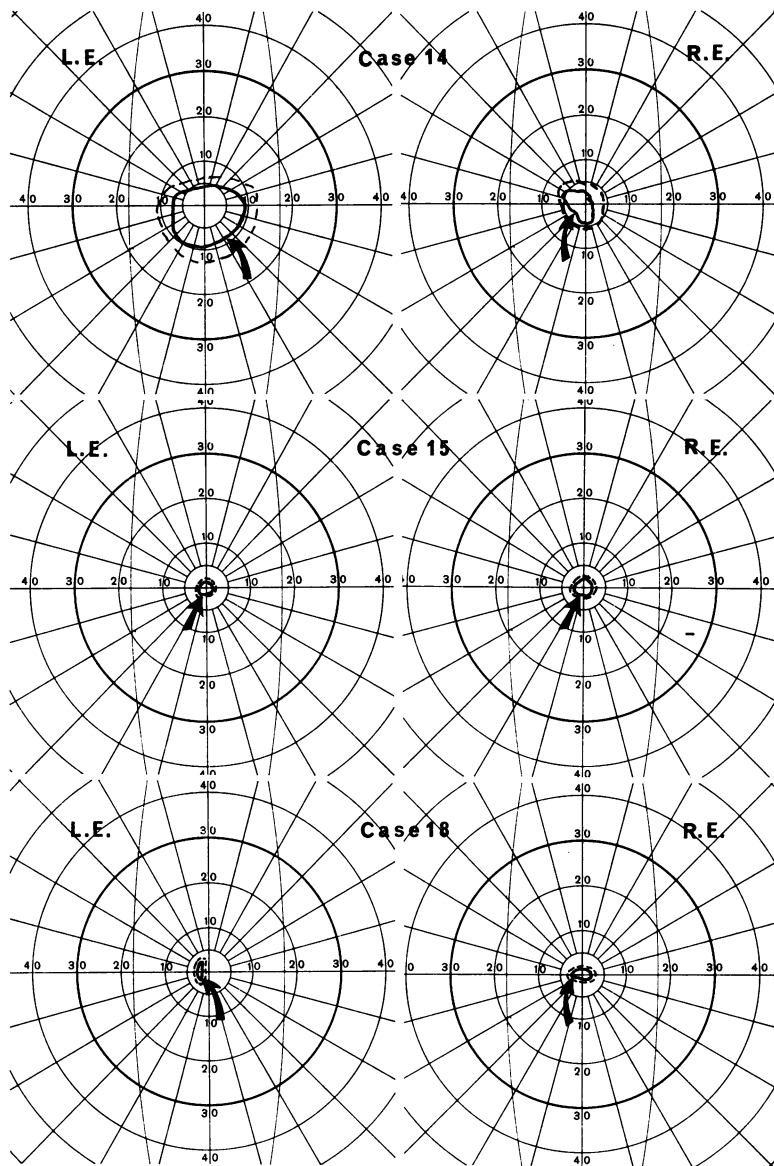


Fig. 6 Cases 14 and 15: Severely constricted visual fields in cases of postneuritic optic atrophy without retinal lesions. Case 18: The visual fields in a case of bilateral papillary oedema

constricted. The other cases also had visual field constriction, leaving a central rest of less than 10° . No clear correlation between the degree of the optic atrophy and the visual field defects could be established.

Case 18 had bilateral oedema and congestion of the optic discs. There was also retinal mottling. The visual fields were severely constricted to a central rest of less than 5° (Fig. 6).

Discussion

Testing of the visual fields is a complex matter, and

good co-operation by the patient is a necessity. In the present study only selected cases were included in order to obtain as reliable results as possible. The correlation between the tangent screen and the confrontation test was good, which indicates a high level of reliability.

The visual field defects found were mainly characterised by a general constriction of the fields. In no case were central, centrocaecal, or other scotomas inside the outer limits of the visual fields detected. Thus they differed from those visual field defects commonly found in optic nerve disease. There was a relatively poor correlation between the degree of

the fundus lesions and the visual field defects. However, in those cases where pale optic discs were found severe visual field defects were also present, even though the retinal lesions varied from discrete mottling to severe atrophy of large areas. On the other hand severe visual field defects were present in cases in which the optic discs were assessed to be normal. One case of bilateral oedema and congestion of the optic discs had a similar severe constriction of the visual fields.

Severely constricted visual fields can be seen in diseases other than onchocerciasis, such as retinitis pigmentosa, anterior ischaemic optic neuropathy, glaucoma, and intoxication with quinine, but no signs of these conditions could be detected. Hypovitaminosis A may lead to constriction of the visual fields, but all the patients in this study lived in southern Togo and Ivory Coast, where lack of vitamin A is not known to be a problem, and no ophthalmological signs of hypovitaminosis A were seen in any of the villages examined. Constrictive arachnoiditis following meningitis or a traumatic lesion of the optic nerve, as well as syphilis, may lead to constriction of the visual fields, but it was impossible in the circumstances of our work to undertake investigations to rule out these conditions. However, Bird *et al.* (1976) found no association between syphilis and optic nerve disease in the Cameroons.

Peripheral defects of the visual fields, often with severe constriction to about 5°, along with a fairly good visual acuity have been typical findings in our sample. A progressive lesion of the optic nerve from the periphery, with the centrally situated macular fibres being the last to be affected, seems to be a reasonable explanation of this functional impairment. This process is probably due to invasion of microfilariae into the optic nerve. To know the route of entry of the microfilariae and the movement of them in the ocular tissues is therefore of the utmost importance. Blood-borne invasion has been suggested by Fuglsang and Anderson (1974), movement along the sheaths of the ciliary nerves and vessels by Neumann and Gunders (1973). The presence of microfilariae in the optic nerve sheaths and in the cerebrospinal fluid and their possible influence on the optic nerve has been pointed out by Paul and Zimmerman (1970) and Duke *et al.* (1976).

The distribution pattern of the corneal changes (Tønjum and Thylefors, 1978) indicates that the microfilariae, which may have an affinity for fibrous tissues such as the corium of the skin, invade the eye from the skin along the fibrous ligaments of the nasal and the temporal sides. Just as the micro-

filariae invade the cornea, so may they move in the sclera, eventually reaching the posterior pole and the optic nerve. Paul and Zimmerman (1970) found microfilariae in the sclera, the optic nerve sheaths, and the optic nerve itself. The inflammatory involvement of the optic nerve may thus progress from the periphery. An inflammatory process in the periphery of the nerve may for long leave the centrally-located maculopapillary nerve fibres undamaged. The optic nerve lesions in onchocerciasis may therefore start as a 'peripapillitis' or 'perineuritis' rather than as a 'papillitis'.

The majority of the cases in the present study had a normal or a moderately reduced visual acuity. Most of them would not have been classified as 'blind' in a routine survey using visual acuity as the only test for visual function. A few of the patients with severely constricted visual fields complained spontaneously about poor vision in darkness, while others seemed to be unaware of any vision problem. However, blindness due to constricted visual fields in onchocerciasis may be of great importance. The rate of blindness or serious visual handicap is therefore grossly underestimated if only the visual acuity is taken into consideration.

References

- Anderson, J., Fuglsang, H., Hamilton, P. J. S., and Marshall, T. F. de C. (1974). Studies on onchocerciasis in the United Cameroon Republic. I. Comparison of populations with and without *Onchocerca volvulus*. *Transactions of the Royal Society of Tropical Medicine and Hygiene*, **68**, 190-208.
- Bird, A. C., Anderson, J., and Fuglsang, H. (1976). Morphology of posterior segment lesions of the eye in patients with onchocerciasis. *British Journal of Ophthalmology*, **60**, 2-20.
- Duke, B. O. L., Vinceletti, J., and Moore, P. J. (1976). Microfilariae in the cerebrospinal fluid, and neurological complications during treatment of onchocerciasis with diethylcarbamazine. *Tropenmedizin und Parasitologie*, **27**, 123-132.
- Fuglsang, H., and Anderson, J. (1974). Microfilariae of *Onchocerca volvulus* in blood and urine before, during and after treatment with diethylcarbamazine. *Journal of Helminthology*, **48**, 93-97.
- Neumann, E., and Gunders, A. E. (1973). Pathogenesis of the posterior segment lesions of ocular onchocerciasis. *American Journal of Ophthalmology*, **75**, 82-89.
- Paul, E. V., and Zimmerman, L. E. (1970). Some observations on ocular pathology of onchocerciasis. *Human Pathology*, **1**, 581-594.
- Rodger, F. C. (1960). The pathogenesis and pathology of ocular onchocerciasis. IV. The pathology. *American Journal of Ophthalmology*, **49**, 560-594.
- Tønjum, A. M., and Thylefors, B. (1977). Aspects of corneal changes in onchocerciasis. *British Journal of Ophthalmology*, **62**, 458-461.
- Védy, J., and Sirol, J. (1971). A propos d'une papillite onchocercienne. *Médecine tropicale*, **31**, 559-564.
- Védy, J., Sirol, J., Barabé, P., Derrien, J. P., and Delpy, P. (1975). A propos de sept observations de papillite onchocercienne. *Médecine et armées*, **3**, 851-858.