

Senile macular degeneration and geographic atrophy of the retinal pigment epithelium

DARRELL WILLERSON JR. AND THOMAS M. AABERG

From the Department of Ophthalmology, The Medical College of Wisconsin

SUMMARY The case is reported of a man who had oval areas of atrophy of the retinal pigment epithelium in paracentral areas which previously had heavy concentrations of drusen OU. This supports the suggestion by others that atrophy of the RPE in senile macular disease may in some cases occur in the absence of previous serous detachment of the RPE.

A previous report documented the occurrence of geographic atrophy of the retinal pigment epithelium (RPE) associated with age-related choroidal/pigment epithelial degeneration (senile macular degeneration) after serous detachment of the pigment epithelium (Blair, 1975). This report describes a patient who after 7 years of observation developed bilateral areas of atrophy of the RPE and choriocapillaris in the perimacular areas which previously had heavy concentrations of drusen. This supports the concept, therefore, that some patients with age-related choroidal/pigment epithelial degeneration may develop atrophy of the RPE and choriocapillaris without preceding serous detachment of the RPE.

Case report

The patient was a 52-year-old Caucasian male who had no ocular complaints other than decreased night vision during the 7 years of ocular examination at the Medical College of Wisconsin. There was no family history of eye disease. His past history included mild systemic hypertension well controlled on methyl dopa HCl 250 mg orally four times a day and hydrochlorothiazide 50 mg orally daily.

His visual acuity in 1970 and now is 20/25 in the right eye (OD) and 20/20 in the left eye (OS), and remains stable. Ocular examination was normal in 1970 except for drusen in the fundi of both eyes (OU), especially concentrated temporal to the fovea (OU). Fluorescein angiography in June 1970 showed many areas of transmission hyperfluorescence without leakage OU corresponding to the drusen (Figs. 1, 2, 3). Repeat fluorescein angiography during July 1971

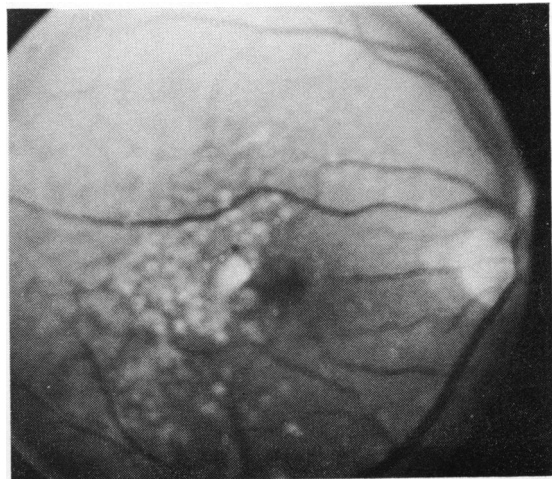


Fig. 1 *Fundus photograph OD taken with red-free light (June 1970), showing perimacular drusen*

demonstrated similar areas of hyperfluorescence without leakage, now associated with areas of atrophy of the retinal pigment epithelium. One fluorescein study of March 1977 showed paracentral atrophy of the RPE and choriocapillaris, which has occurred in the area where drusen were concentrated temporal to the maculas (Figs. 4, 5, 6, 7). An electroretinogram (ERG) during 1971 had scotopic b-waves which were 200 microvolts, reduced for our laboratory. Flicker testing was normal. A repeat ERG during 1974 was again normal except for reduced dark-adapted b-wave values of 175 microvolts OD and 200 microvolts OS (normal values: 350 to 600 microvolts). A third ERG in 1977 had not significantly changed and remained normal except for reduced dark-adapted b-waves of 240

Address for reprints: Dr Thomas M. Aaberg, Department of Ophthalmology, The Medical College of Wisconsin, 8700 West Wisconsin Avenue, Milwaukee, Wisconsin 53226, USA

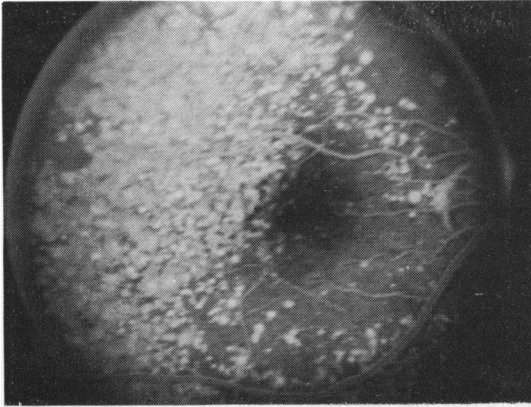

Fig. 2 Venous phase of fluorescein angiogram OD (June 1970) with discrete areas of transmission hyperfluorescence corresponding to drusen. Many more drusen are apparent than in Fig. 1

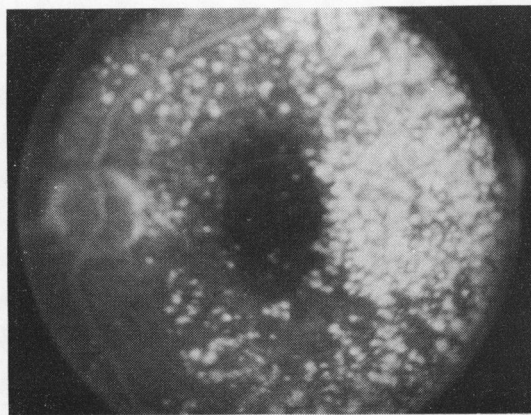


Fig. 3 Late phase of fluorescein angiogram OS (June 1970) with areas of hyperfluorescence corresponding to drusen

microvolts OD and 200 microvolts OS. EOG in 1977 had a reduced light peak to dark trough amplitude ratio OU (1.54 OD and 1.52 OS). Dark adaptation studies revealed reduced cone and total rod amplitudes OU, 0.7 log units and 1.3 log units respectively. Visual fields in 1977 showed paracentral scotomas which corresponded to the oval areas of atrophy of the RPE and choriocapillaris.

Discussion

Age-related choroidal/pigment epithelial degeneration becomes manifest as a spectrum ranging from drusen to disciform macular lesions, or as geographic atrophy of the retinal pigment epithelium. Blair

(1975) reported 11 patients with geographic atrophy of the RPE secondary to senile macular degeneration and differentiated them from central areolar choroidal sclerosis. He suggested that geographic atrophy in this entity follows serous or haemorrhagic detachment of the RPE. Thus, after the serous or haemorrhagic fluid is reabsorbed a well demarcated area of atrophy of the pigment epithelium would result through which the underlying choroidal vessels

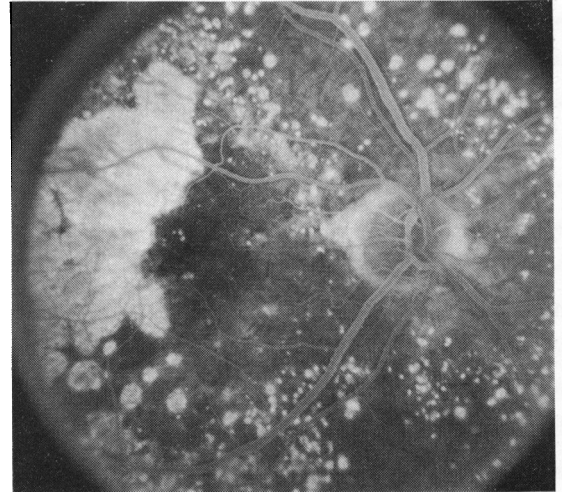


Fig. 4 Late phase of fluorescein angiogram OD (March 1977) showing hyperfluorescence temporal to the fovea in the area of atrophy of the RPE and choriocapillaris where drusen were previously concentrated (Figs. 1 and 2)

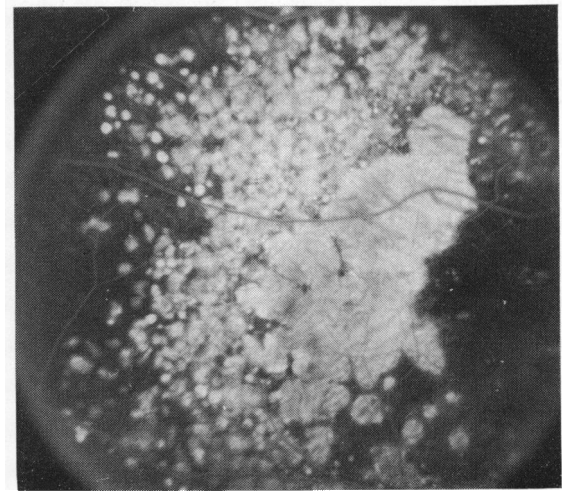

Fig. 5 Late phase of fluorescein angiogram showing the fundus temporal to Fig. 4

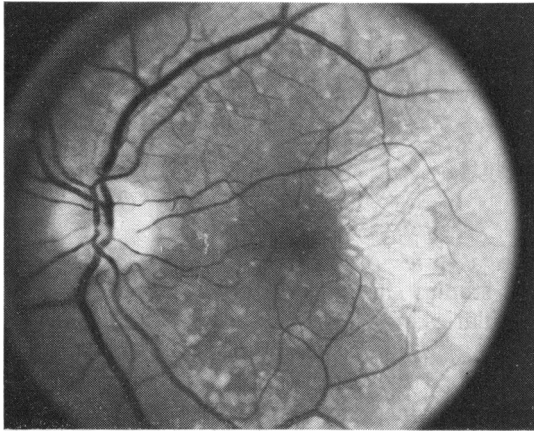


Fig. 6 Photograph taken with red-free light OS (March 1977) showing atrophy of RPE and choriocapillaris temporal to the fovea where drusen were previously concentrated (Fig. 3)

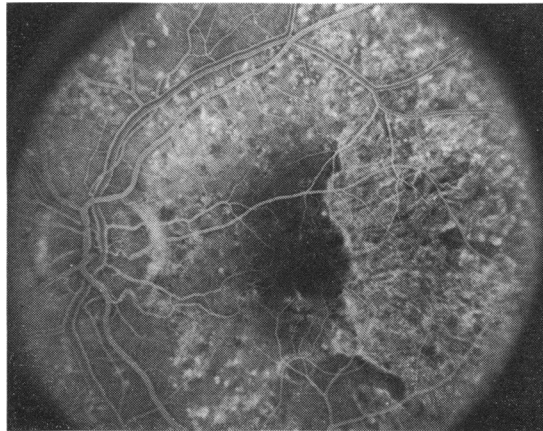


Fig. 7 Venous phase of fluorescein angiogram OS (March 1977) showing transmission hyperfluorescence temporal to the fovea in area of atrophy of RPE and choriocapillaris

could be seen. Other authors have suggested that in some patients atrophy of the RPE may occur in the absence of disciform macular lesions (Gass, 1977). The present patient had a dense concentration of drusen in the paramacular region of both eyes (Figs. 1, 2, 3). After close follow-up for 7 years symmetrical oval areas of atrophy of the RPE and choriocapillaris developed in both eyes in the areas where drusen had previously been concentrated (Figs. 4, 5, 6, 7). During the period of observation the patient never had serous or haemorrhagic pigment epithelial detachment. This case therefore supports the concept that geographic atrophy of the RPE in age-related choroidal degeneration may occur in some patients in the absence of preceding disciform macular lesions.

In a recent clinicopathological study by Sarks (1976) age-related changes were classified into 6 groups depending on the presence and extent of a finely granular deposit beneath the RPE cells (basal

linear deposit) as well as hyalinisation and thickening of Bruch's membrane. Clinical evidence of senile macular degeneration evidenced by reduced visual acuity and moderate disturbance in the RPE did not occur until the basal linear deposit became continuous beneath the macula. Thickening of the basal linear deposit was associated with progressive degeneration of the pigment epithelium. Some cases in Sarks's series showed progressive atrophic changes in the RPE culminating in geographic atrophy. Other eyes underwent subretinal neovascularisation, haemorrhage, and exudation.

References

- Blair, C. J. (1975). Geographic atrophy of the retinal pigment epithelium. *Archives of Ophthalmology*, **93**, 19-25.
- Gass, J. D. M. (1977). *Stereoscopic Atlas of Macular Diseases*, pp. 70-74. C. V. Mosby: St. Louis.
- Sarks, S. H. (1976). Ageing and degeneration in the macular region: a clinico-pathologic study. *British Journal of Ophthalmology*, **60**, 324-341.