

# Bilateral acute retinal necrosis

N. J. A. YOUNG AND A. C. BIRD

*From Moorfields Eye Hospital and the Institute of Ophthalmology, London*

**SUMMARY** In this paper 4 patients are described who had bilateral symmetrical confluent retinal swelling followed by apparent necrosis and sloughing of the retina into the vitreous. The disease was accompanied by signs of uveitis and the clinical appearance suggested inflammation rather than infarction as the pathogenic mechanism. No systemic abnormalities were found by which the aetiology could be identified.

This paper describes 4 previously healthy patients with apparently similar disease characterised by bilateral acute retinal necrosis (BARN) for which no cause was found. The pattern and evolution of disease was not previously familiar to us.

## Case reports

### CASE 1

A 63-year-old male lorry driver presented on 16 September 1971 with a 4-day history of blurred right eye vision associated with frontal headache. Visual acuity was hand movements with the right eye and 6/9 with the left. The anterior segments were normal and the vitreous was clear in each eye. There were retinal swelling and haemorrhages in the right macular and left paramacular regions, and in the mid-periphery of the right fundus 2 other circumscribed patches of yellow swollen retina were seen.

During the following 6 days vision fell to finger counting in the left eye, and cells were identified in the anterior chamber and vitreous bilaterally. The macular lesions were larger (Figs. 1*a, b*), and the peripheral retina in each eye became involved by disease (Figs. 1*f, g, h, i*). The swollen retina was intensely opaque and yellowish and showed scattered haemorrhages. Fluorescein angiography showed no dye entry into the affected retina and leakage from the vessel walls at the margin of non-perfused retina (Figs. 1*c, d, e*). In the upper nasal mid periphery of the left eye was an isolated patch of swelling with dye leakage from the arterial wall as it crossed this area. Choroidal and retinal per-

fusion appeared normal in the unaffected fundus.

### Investigations

The patient was extensively investigated for a systemic abnormality but none was found. Hb, PCV, WBC, plasma proteins, urea and electrolytes, and the ESR were normal. Serological tests for syphilis and toxoplasmosis were negative and blood cultures were sterile. Antinuclear factor and rheumatoid arthritis latex test were negative and the cytomegalovirus titre was  $< 1/8$ . A chest x-ray showed emphysematous changes only. The lipoprotein electrophoresis was normal but the cholesterol was slightly elevated.

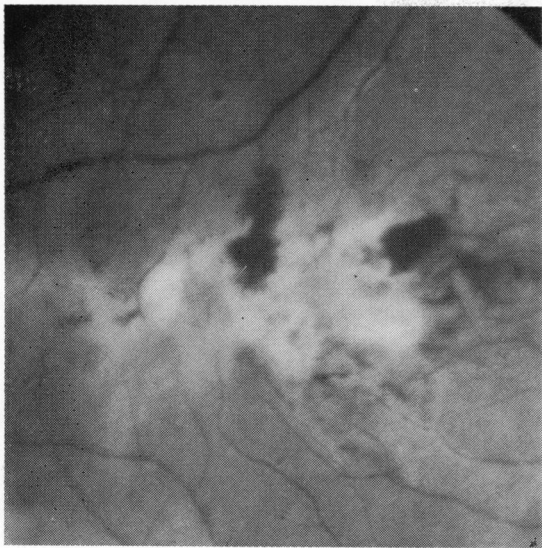A diagnosis of retinitis of possible infective origin was made and the patient was treated with systemic antibiotics and corticosteroids.

### Progress

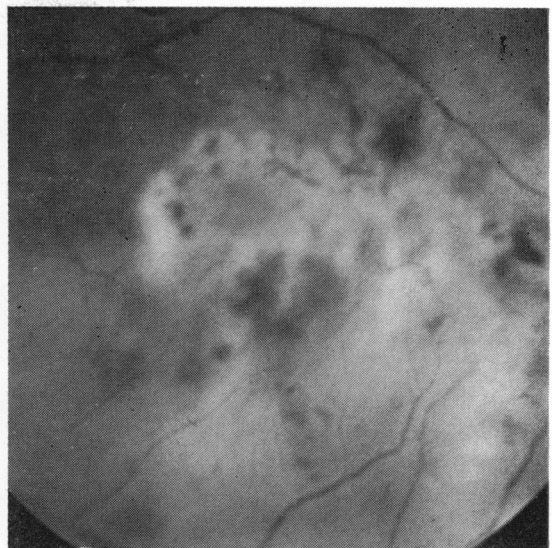Over the next 4 weeks gaps developed in the areas of retinal inflammation and this change was accompanied by an increase in vitreous turbidity. Eight weeks after initial presentation he developed a superior retinal detachment in the left eye, which failed to reattach after 2 operations and remains detached with a vision of light perception.

In March 1972 his right vision was 6/60 with minimal inflammatory signs. There was still considerable vitreous debris; in areas of previous disease there were mild, well demarcated changes in the retinal pigment epithelium.

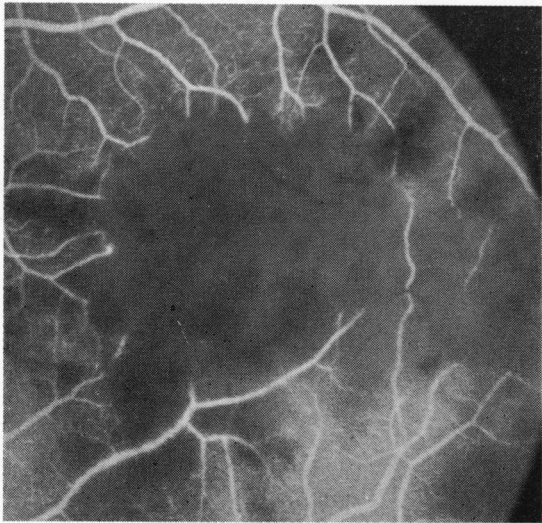
Over the next 17 months the right eye showed no signs of recurrent inflammation but developed a cataract, which was extracted uneventfully on 23 August 1973. When last reviewed on 6 October 1977 his best vision was 6/60+1 in the right eye, and atrophy of the choriocapillaris had developed at the sites of previous disease (Fig. 1*j*).



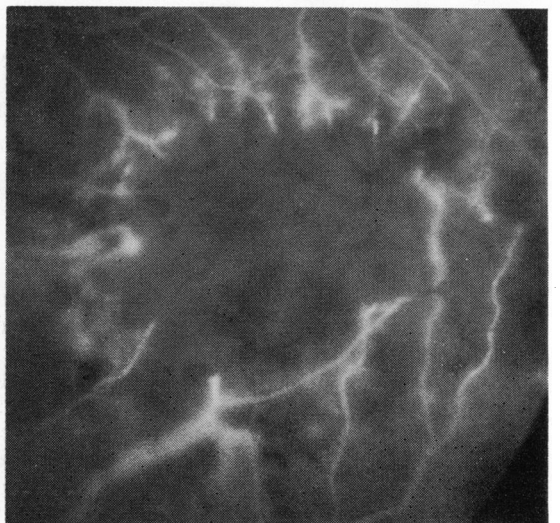
1a



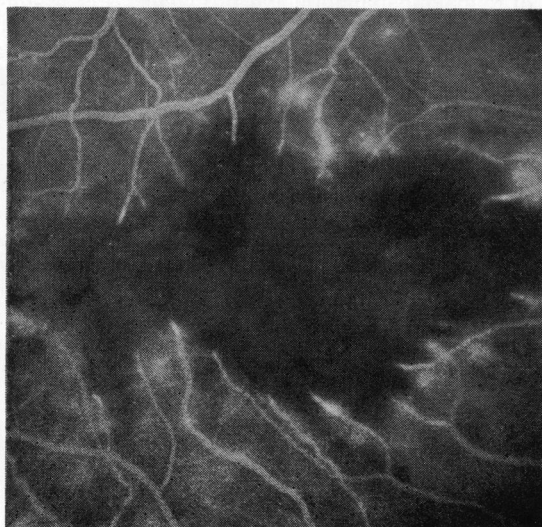
1b



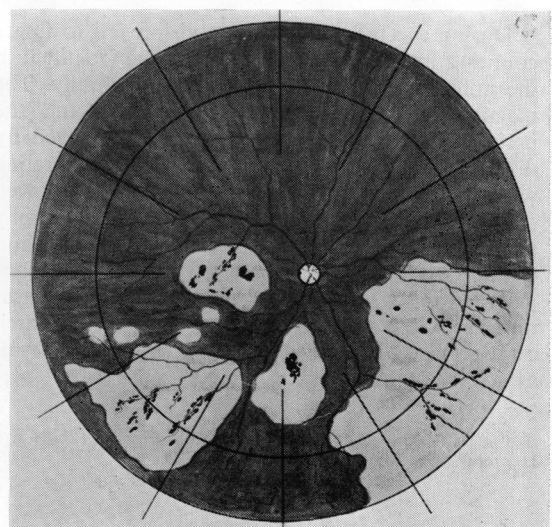
1c



1d



1e



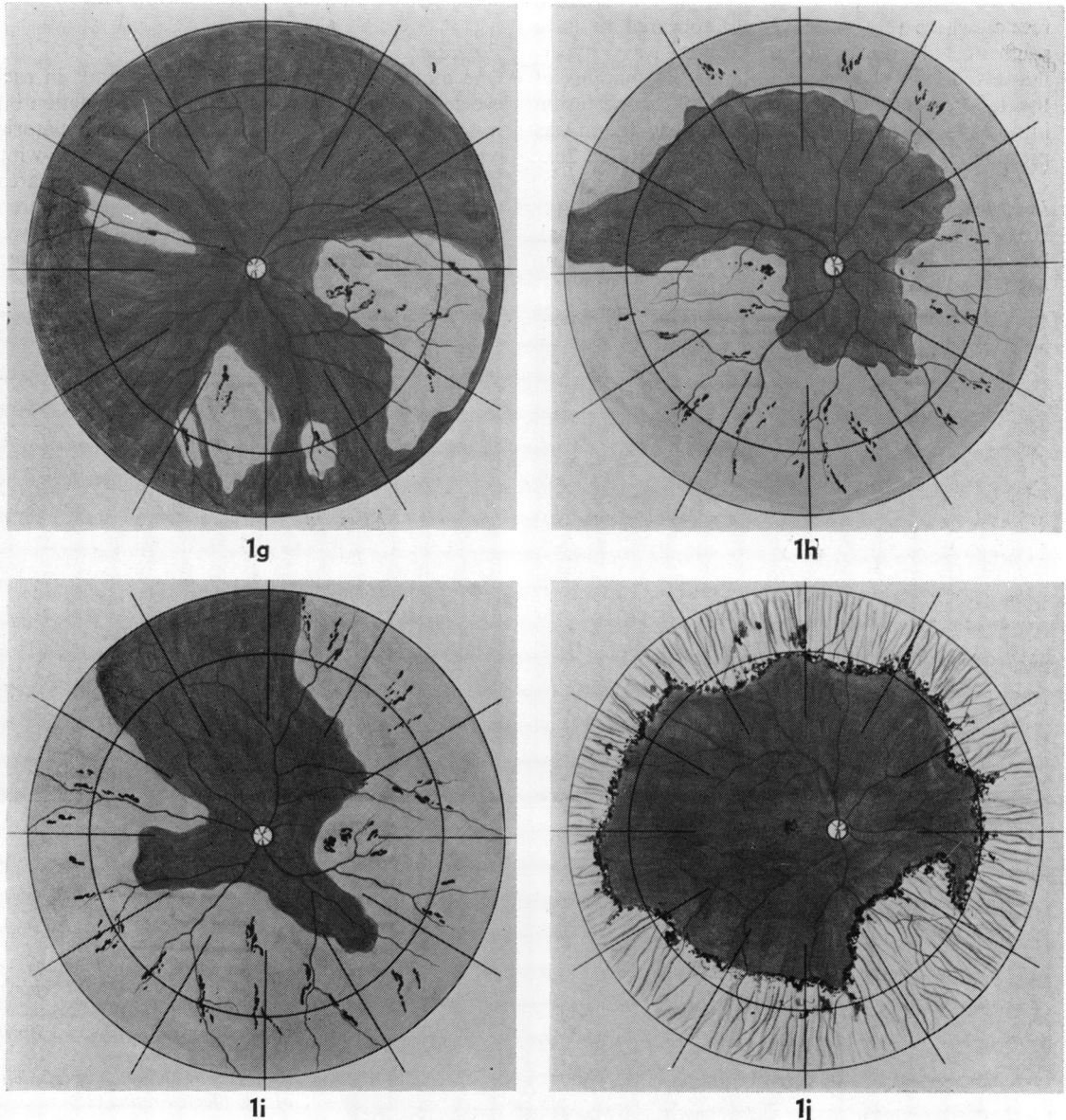
1f

**CASE 2**

A 57-year-old female was first seen on 9 March 1974 with a 2-day history of watering and aching of the right eye. Visual acuity was 6/6 part with each eye. In the right eye there was anterior uveitis with large keratic precipitates and raised intraocular pressure. There was a cellular reaction in the vitreous with

confluent yellowish-white swelling of the peripheral retina, especially below. The left eye was normal at this time. She was treated with local cycloplegics and corticosteroids, but 1 week later systemic antibiotics and corticosteroids were introduced as the changes became more marked.

Two weeks after initial presentation she developed



**Fig. 1** Case 1—Retinal swelling and haemorrhages of both maculae, 22 September 1971 (1a, b). Fluorescein angiograms show no perfusion of the retina with leakage of the vessels at the margins of retinal non-perfusion (left eye 1c, d; right eye 1e). Retinal diagrams showing distribution of disease 27 September 1971 (1f, g), 4 October 1971 (1h, i), and 5 March 1972 (1j)

anterior uveitis, with raised intraocular pressure in the left eye, with vitreous cells and confluent peripheral yellow retinal swelling with perivascular haemorrhages (Figs. 2*a, b*). The vision at that time was hand movements with the right eye and 6/18 with the left.

Fluorescein angiography of the left temporal retina showed perfusion to be normal in the unaffected retina but no perfusion in the diseased retina, where the blood vessels appeared to have stagnant blood columns. There was hyperfluorescence of the vessel walls at the margins of the lesions. In the areas of retinal non-perfusion intraretinal dye was seen early in the study and was presumed to be derived from the choroid (Fig. 2*c*).

#### Investigations

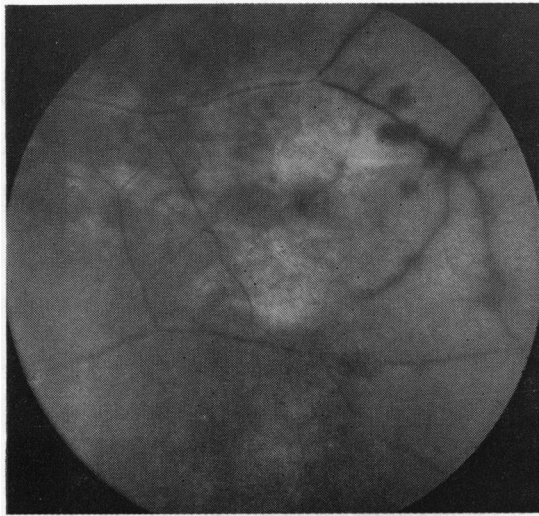
Hb, PCV, WBC, urea, and electrolytes were normal. Immunoglobulins were reported initially as being

generally decreased but subsequently as normal. Blood cultures were sterile, and there was no serological evidence of syphilis, toxoplasmosis, or rheumatoid arthritis. Chest and skull x-rays were normal.

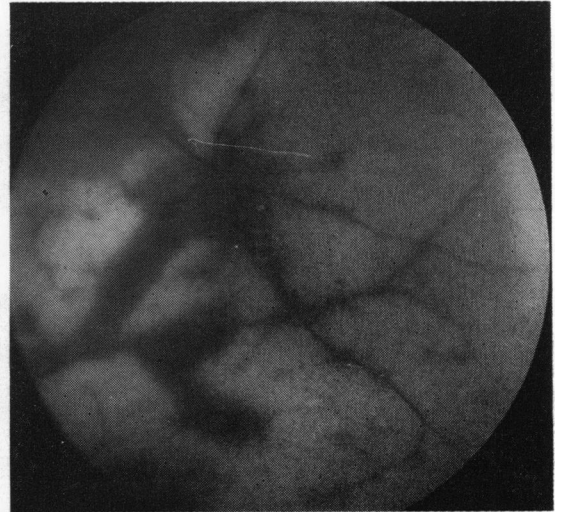
The ESR was repeatedly raised, and this prompted a full investigation for a systemic disorder, but none was detected.

#### Progress

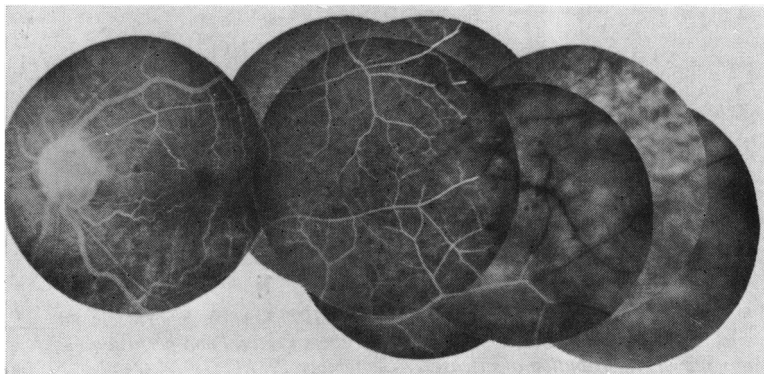
One month after presentation the vitreous in each eye continued to show a heavy cellular reaction but was sufficiently clear to see the entire pre-equatorial region of each fundus replaced by a yellowish-white infiltration with a sharp posterior line of demarcation. Within areas of disease patches of apparent resolution could be seen which were also well defined. There were a few scattered haemorrhages



2a



2b



2c

Fig. 2 Case 2—Swelling and haemorrhages in the left temporal retina on 1 April 1974 (2a), which increased considerably by 3 April 1974 (2b). Fluorescein angiography showed no perfusion of the affected retina (2c)



within the lesion. Systemic corticosteroid therapy was continued and the dose increased.

Three weeks later the vision in the right eye had improved to 6/18. Minimal inflammation was present in both anterior segments, with a few cells and considerable debris in the vitreous of each. No retinal swelling could be seen, but in its place was well demarcated retinal pigment epithelial change. The retinal vessels were extensively sheathed and were narrow on fluorescein angiography.

Four days after this assessment she developed a detachment of the left retina, apparently due to the retina tearing along the posterior demarcation of the previously infiltrated retina. This was considered inoperable as the dehiscence extended through 360°.

Three months after initial presentation she developed a detachment of the temporal half of the right retina due to a tear in the upper temporal quadrant and a dehiscence of the retina below, again along the posterior demarcation of the chorioretinal scarring. This was treated by encirclement, drainage of subretinal fluid, cryotherapy, and intravitreal air

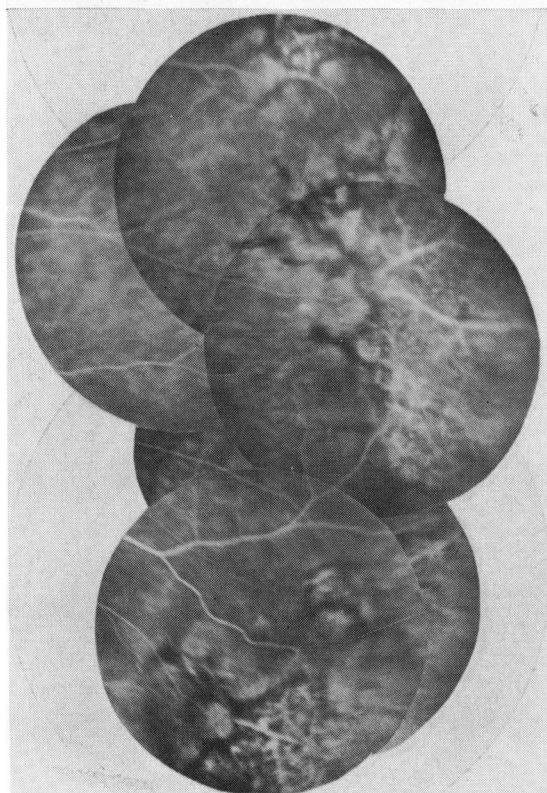
injection, but she developed signs of anterior segment ischaemia, which failed to resolve, and both eyes are now blind and becoming phthisical.

#### CASE 3

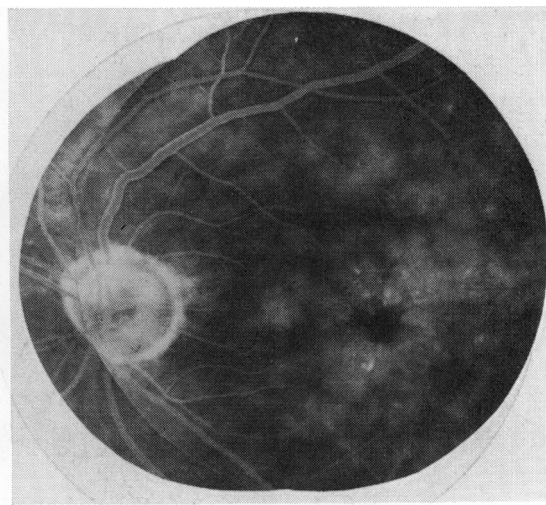
A 58-year-old male electrical inspector presented on 4 June 1975 with a 1-week history of redness, pain, and blurring of vision in the right eye starting immediately prior to the onset of acute urinary retention. Right eye vision was 6/60 with a moderate anterior uveitis and normal intraocular pressure. There was massive vitreous exudation with debris and cells. In the fundus were widespread scattered areas of grey to white swollen retina in the mid periphery, which became confluent more anteriorly and were associated with multiple small haemorrhages. The left eye was normal with a vision of 6/6.

Over the next 2 weeks the right eye subjectively improved on local corticosteroids, but the left developed a mild anterior uveitis with raised intraocular pressure. After a further 10 days left eye vision fell to 6/12 with many cells appearing in the vitreous, and the retina developed similar changes to those seen in the right eye, with narrowing and sheathing of the peripheral arterioles, which were partly obscured by the opaque retina. This eye was also treated with local and orbital floor corticosteroids.

Fluorescein angiography was of poor quality on account of the large amount of vitreous activity, and no conclusions could be drawn concerning the



3a



3b

Fig. 3 Case 3—Fluorescein angiography on 11 September 1975 after resolution of the disease showing peripheral transmission defects (3a) and cystoid macular oedema (3b)

retinal circulation. Five minutes after dye entry there was considerable dye accumulation in the peripheral retina of the right eye.

#### Investigations

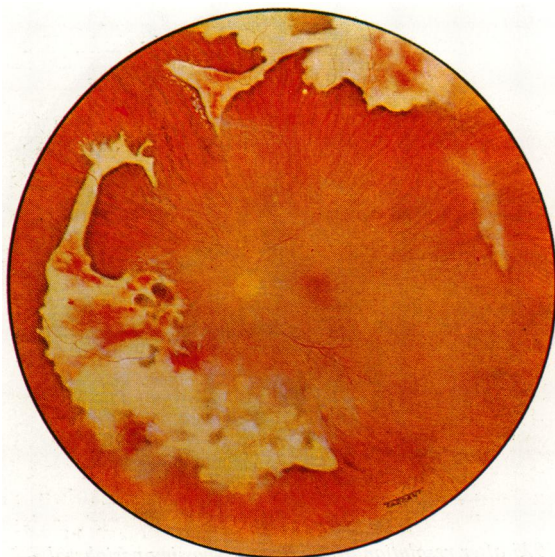
The following were normal: Hb, PCV, WBC, serum calcium, lipoproteins, total plasma proteins, and serology for syphilis. The gammaglobulin fraction was raised, with a slight increase in IgM and IgA.

Anti-smooth muscle antibody was detected in a 1:10 dilution. Blood cultures were sterile. The toxoplasma dye test was positive at 1/64 dilution, but no rising titre and 2 blood samples for cytomegalovirus complement fixation test showed a titre of <1/8. The ESR was raised at 46 mm/h. A chest x-ray showed minor emphysematous changes, but the lumbar spine and sacroiliac joints showed the changes of advanced ankylosing spondylitis.

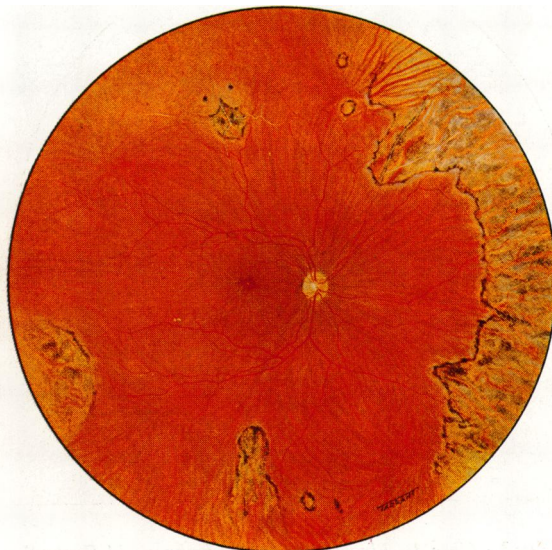Fig. 4 Case 4—Dense yellow swelling of the peripheral retina on 28 January 1977. In the right eye (4a) this co-existed with areas of pigment epithelial change where swelling had resolved. In the left eye (4b) the acute lesions were associated with haemorrhages and there was vitreous debris. After resolution areas of swelling were replaced by well-defined retinal pigment epithelial atrophy in the right eye (9 June 1977) (4c, d). Fluorescein angiography on 1 June 1977 showed dilated perifoveal capillaries (4e) and cystoid macular oedema (4f)



4a



4b



4c

No evidence of vasculitis was seen in a conjunctival biopsy on electron microscopy.

#### Progress

Over the next month areas of retinal swelling disappeared in a patchy manner and the vitreous opacity increased. Ten weeks after initial presentation the patient developed a subtotal detachment of the right retina. There was marked reduction in vitreous mobility in this eye, with increase in debris and cells; the retina developed massive periretinal

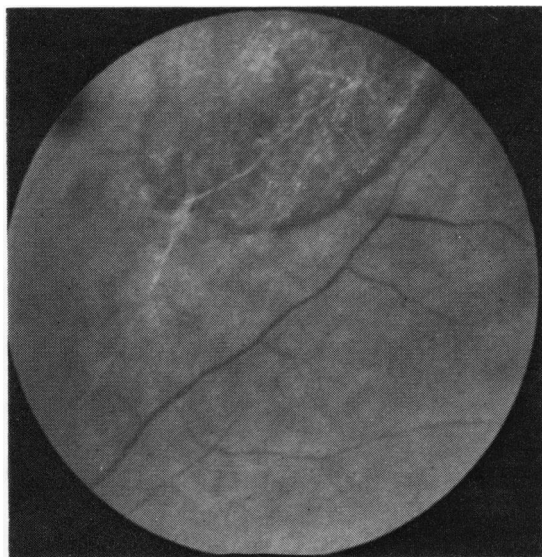
fibrosis and failed to re-attach after surgery. At this time vision with the left eye was 6/9, with minimal signs of anterior uveitis. There was vitreous debris and in the retinal periphery a geographic pattern of fine pigmentary change at the sites of previous inflammation. There was widespread peripheral vessel closure.

Fluorescein angiography confirmed the sharp transition from normal to abnormal retina, but there was no dye leakage (Fig. 3a) apart from macular oedema (Fig. 3b).

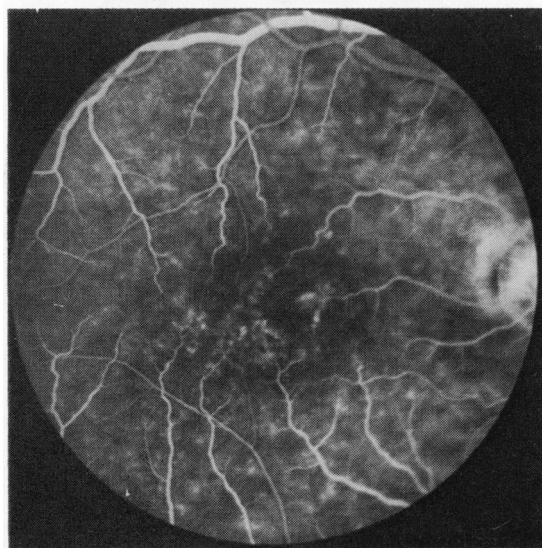
When last assessed on 12 February 1977 the left eye had an acuity of 6/12, reading N5, and showed no signs of active disease, with no change in the retinal pigmentary pattern.

#### CASE 4

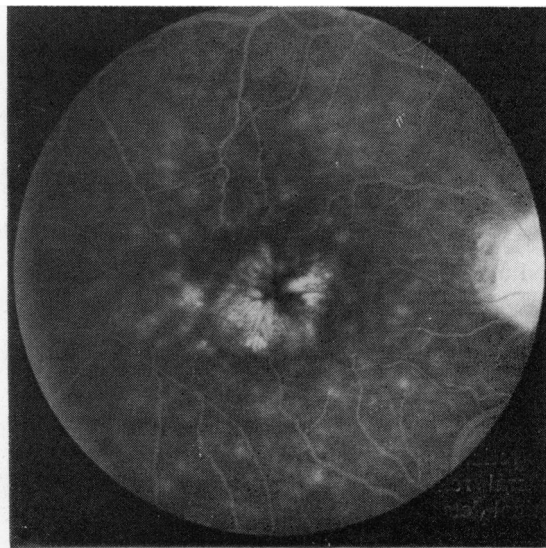
A 58-year-old retired medical practitioner was first seen by Mr S. P. Redmond in Lincoln on 13 December 1976 with a 10-day history of sudden redness of the left eye followed by deterioration of vision. This had been preceded by a feverish illness the day before. A diagnosis of iritis with raised intraocular pressure was made, and later he developed signs of posterior uveitis. He was treated with local and systemic corticosteroids, but 6 weeks later developed similar symptoms in the right eye. When referred to Moorfields Eye Hospital on 20 January 1977, 2 days after the right eye had become affected, the right vision was 6/12 and the left 6/18. Both anterior chambers showed a moderate uveitis with normal intraocular pressures. There was cellular reaction and debris in each vitreous, which



4d



4e



4f



was more marked in the left. In both fundi there was confluent yellowish-white retinal swelling in the periphery with haemorrhages (Fig. 4a, b). In the right eye gaps existed within the areas of swelling, in which there were mild retinal pigment epithelial changes.

#### Investigations

Clinical examination showed no signs of systemic disease. Blood cultures were sterile and serological tests for syphilis and toxoplasmosis were negative. The blood chemistry was normal, as was the ESR. The only abnormality in the protein fractions was a slightly raised gammaglobulin, but the immunoglobulins were normal. The Hb was 17.4 g/dl, PCV 53%, WBC  $13.0 \times 10^9/l$ , the differential count showing a lymphocytosis. Antinuclear factor was detected, 1:40, and the cytomegalovirus complement fixation titre was 1:64, but not rising. His chest and skull were normal on x-ray.

#### Progress

The patient was treated with local and systemic corticosteroids, and during the next 4-week period gaps progressively appeared in the areas of disease, which were replaced by retinal pigment epithelial changes only. Within these areas the retinal blood vessels were sheathed and were not perfused.

On 23 February 1977 he was reviewed as the left eye vision had deteriorated for the previous 2 days. At this time the right vision was 6/9 with a quiet anterior chamber and fine pigment stippling in the peripheral retina in the areas of previous inflammation. Left vision, however, had dropped to hand movements, and there was a marked increase in the vitreous debris obscuring the disc and macula; the peripheral retina showed a white plaque in the inferonasal quadrant. His corticosteroid dose was increased but despite this the eye worsened and he developed a traction detachment of the posterior retina. When last reviewed on 1 June 1977 the right eye, in which the vision has improved to 6/5, now had a vision of 6/12. The anterior chamber of this eye was clear and there were vitreous cells. There were well-demarcated areas of subtle retinal pigment epithelial change in the periphery and macular oedema (Fig. 4c, d). Fluorescein angiography of the right eye demonstrated dilatation of the perfoveal capillaries (Fig. 4e) with leakage of dye into the retina (Fig. 4f). In the left eye there were peripheral retinal pigment epithelial changes and a retinal detachment arising from a retinal dehiscence above, beyond which the retina appeared to be absent.

#### ADDENDUM

While this paper was in preparation a further patient was seen in whom the findings suggested similar disease to that described in the other 4 cases. At the time of examination he had a total detachment of the right retina (Fig. 5) and very subtle retinal pigment epithelial disturbances in the periphery of the left eye.

#### SUMMARY OF DISEASE PROCESS

All the eyes of these patients had bilateral peripheral retinal change and, in 1, bilateral macular disease. The swollen retina was intensely opaque and yellowish-white with a well demarcated border between normal and abnormal retina. Fluorescein angiography showed no capillary perfusion in the affected areas, with dye leakage from the few surviving major vessels crossing non-perfused retina and at the terminations of the occluded larger vessels as they entered the swollen tissue. Shortly afterwards areas of diseased retina cleared in a patchy manner, leaving mild retinal pigment epithelial changes only. The vessels within this area became sheathed, and in most perfusion was not re-established. Clearing of the diseased retina was accompanied by marked accumulation of vitreous debris. It was thought that clearing was due to retinal necrosis, with sloughing of the retina into the vitreous. In 5 of the 8 eyes the retina became detached with tears at the demarcation between normal and abnormal retina:

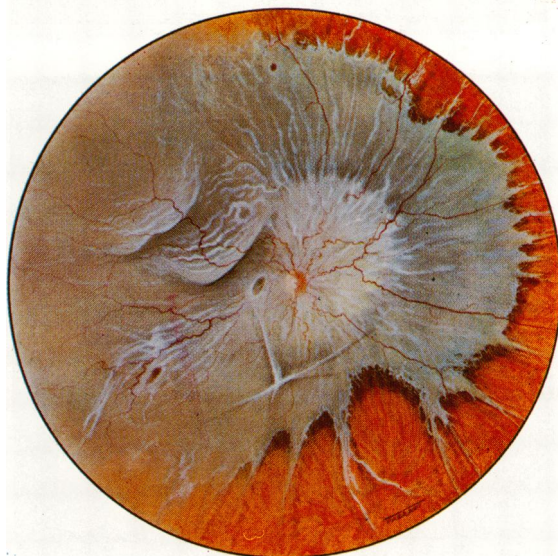


Fig. 5 Retinal detachment with periretinal fibrosis and discontinuous retinal tears through  $210^\circ$  of the retinal periphery



this tended to support the concept that the retina was largely deficient beyond the demarcation line. In none of these eyes was retinal re-attachment achieved.

The choroid appeared normal during the acute phase of the disease and there was no evidence of choroidal vessel closure at the time of acute disease, but atrophy of the choriocapillaris has occurred in the previously diseased areas in the first case now followed for 6 years.

The disease was characteristically bilateral and symmetrical, although 1 eye was involved before the other in all cases. Apart possibly from Case 4 this disease occurred as a single acute attack without recurrence. No systemic abnormalities were identified in any patient to indicate the cause of the disease.

### Discussion

In the absence of any clinical or histopathological evidence to indicate the nature of the disease, its aetiology remains obscure. Retinal vascular non-perfusion in the affected areas suggests the possibility of infarction. However, retinal infarction due to retinal vascular disease alone is characterised by mild grey opacity of the retina as opposed to the dense opacity seen in these patients. The resolution of ischaemic swelling is fairly rapid and the retinal pigment epithelial changes are mild or absent. The intense opaque white lesions seen in infarcted retina due to accumulation of axoplasmic debris (McLeod, 1976) are characteristically linear and not seen in the peripheral retina. Choroidal infarction alone causes sector-shaped retinal swelling (Amalric, 1971; Foulds *et al.*, 1971); resolution of swelling is rapid and results in marked atrophy of the retinal pigment epithelium and choriocapillaris. Infarction due to coincident obstruction of both choroidal and retinal circulations gives rise to intensely opaque white swollen retina as seen in our patients. The period of resolution, however, is shorter and the choroidal changes much more marked, with atrophy of the pigment epithelium and choriocapillaris and migration of pigment-containing cells into the retina. It seems unlikely, therefore, that the disease which we have described is due to vascular occlusion alone.

In Behçet's syndrome the retinal disease is produced by a combination of vasculitis and infarction. The fluorescein findings are similar in many respects to those of our cases, with an accumulation of white exudative material in the deep retina and obscuration of the retinal vascular pattern in these areas (Shimizu, 1972). The posterior pole is the site most commonly affected in this disease, whereas the periphery was usually involved in ours.

Alternatively, this disease may be the result of retinitis due to an infective agent. The evolution of the disease suggests primary involvement of the neuroretina rather than spread from the neighbouring structures. The distribution of the lesions and the self-limited course are unlike bacterial infection, and no source of bacterial infection was detected in any patient. Virus infections produce a primary retinitis. The retinitis of cytomegalic inclusion disease (CID) at its height is clinically indistinguishable from BARN (de Venecia *et al.*, 1971). Scattered white dots or white granular patches are seen early on, and these become confluent with the development of haemorrhages. During the healing phase there is atrophy of the retina and pigmentary changes in the retinal pigment epithelium. Histologically there is massive coagulative necrosis of the retina, with little inflammation; the pigment epithelium and choroid are affected little by the disease or not at all (Smith, 1964; Wyhinny *et al.*, 1973; Chumbley *et al.*, 1975). The pattern of disease in CID retinitis is unlike BARN. The cases described in this paper had simultaneous affection of large areas of retina, and the extent of the disease was determined within a short time of onset. By contrast CID causes slowly spreading disease of the retina over a period of weeks, so that the swelling of acute disease is seen at the same time as pigment epithelial atrophy in old lesions; usually the whole retina is affected eventually. Moreover, of the many patients described with CID only one was not immunodeficient (Chawla *et al.*, 1976). Our patients showed no positive evidence of CID infection and none was immunodeficient.

Necrotising retinitis may also be produced by herpes simplex virus infection with relative sparing of the choroid (Cogan *et al.*, 1964; Cibis, 1975), but such cases rarely occur except during infancy (Pavan-Langston and Brockhurst, 1969). A case of retinitis following herpes zoster ophthalmicus has been described by Brown and Mendis (1973) in which extensive peripheral yellow retinal exudates were associated with attenuated retinal arterioles, but without haemorrhages. Measles retinitis is rarely seen in the absence of subacute sclerosing panencephalitis (Nelson *et al.*, 1970).

The descriptions of viral retinitis demonstrate close morphological similarities with BARN and suggest that the disease described in our patients may be due to primary retinitis, probably of an infective aetiology. However, no clinical evidence was identified which might indicate the infective agent.

Experimental autoimmune retinitis has been produced in animals (von Sallmann *et al.*, 1969), but such a disease process remains a theoretical possibility at present.

Two cases were reported by Willerson *et al.* (1977) in which the peripheral retinal changes were almost indistinguishable from the patients we have described, both in the fundus appearances and in the evolution of the disease; in all 4 of their eyes the retina became detached and failed to respond to surgery. In neither patient was an aetiology identified beyond question. Both had some stigmata of Behçet's disease and 1 developed herpes simplex dermatitis when on antimetabolite and corticosteroid therapy. There was insufficient evidence in either patient for Behçet's disease to be diagnosed with certainty, nor could herpes simplex retinitis be confirmed conclusively, since the cytopathic effects typical of the virus could not be produced on tissue culture with the subretinal fluid obtained from 1 patient.

Bilateral acute retinal necrosis appears to be a definite and recognisable clinical entity in which the course of the disease can be predicted. Treatment does not appear to alter its course.

We thank Mr Barrie Jay, Mr R. A. Hitchings, and Mr P. K. Leaver for allowing us to study and publish their cases. We are particularly grateful to Mr K. Sehmi for photographic assistance and to Miss J. Fisher for secretarial help.

#### References

- Amalric, P. (1971). Acute choroidal ischaemia. *Transactions of the Ophthalmological Societies of the United Kingdom*, **91**, 305–322.
- Brown, R. M., and Mendis, U. (1973). Retinal arteritis complicating herpes zoster ophthalmicus. *British Journal of Ophthalmology*, **57**, 344–346.
- Chawla, H. B., Ford, M. J., Munro, J. F., Scorgie, R. E., and Watson, A. R. (1976). Ocular involvement in cytomegalovirus infection in a previously healthy adult. *British Medical Journal*, **2**, 281–282.
- Chumbley, L. C., Robertson, D. M., Smith, T. F., Campbell, R. J. (1975). Adult cytomegalovirus inclusion retinopathy. *American Journal of Ophthalmology*, **80**, 807–816.
- Cibis, G. W. (1975). Neonatal herpes simplex retinitis. *Albrecht von Graefes Archiv für klinische und experimentelle Ophthalmologie*, **196**, 39–47.
- Cogan, D. G., Kuwabara, T., Young, G. F., and Knox, D. L. (1964). Herpes simplex retinopathy in an infant. *Archives of Ophthalmology*, **72**, 641–645.
- de Venecia, G., Zu Rhein, G. M., Pratt, M. V., and Kissen, W. (1971). Cytomegalic inclusion retinitis—A clinical, histopathologic and ultrastructural study. *Archives of Ophthalmology*, **86**, 44–57.
- Foulds, W. S., Lee, W. R., and Taylor, W. O. G. (1971). Clinical and pathological aspects of choroidal ischaemia. *Transactions of the Ophthalmological Societies of the United Kingdom*, **91**, 323–341.
- McLeod, D. (1976). Ophthalmoscopic signs of obstructed axoplasmic transport after ocular vascular occlusions. *British Journal of Ophthalmology*, **60**, 551–556.
- Nelson, D. A., Weiner, A., Yanoff, M., and de Peralta, J. (1970). Retinal lesions in subacute sclerosing panencephalitis. *Archives of Ophthalmology*, **84**, 613–621.
- Pavan-Langston, D., and Brockhurst, R. J. (1969). Herpes simplex panuveitis—A clinical report. *Archives of Ophthalmology*, **81**, 783–787.
- Shimizu, K. (1972). Fluorescein fundus angiography in Behçet's syndrome. *Modern Problems in Ophthalmology*, **10**, 224–228.
- Smith, M. E. (1964). Retinal involvement in adult cytomegalic inclusion disease. *Archives of Ophthalmology*, **72**, 44–49.
- Von Sallmann, L., Meyers, R. E., Stone, S. H., and Lerner, H. E. M. (1969). Retinal and uveal inflammation in monkeys following inoculation with homologous retinal antigen. *Archives of Ophthalmology*, **81**, 374–382.
- Wyhinny, G. J., Apple, D. J., Guastella, F. R., and Vygantas, C. M. (1973). Adult cytomegalic inclusion retinitis. *American Journal of Ophthalmology*, **76**, 773–781.
- Willerson, Jr., D., Aaberg, T. M., and Reeser, F. H. (1977). Necrotizing vaso-occlusive retinitis. *American Journal of Ophthalmology*, **84**, 209–219.