

Experimental posterior penetrating eye injury in the rabbit. I. Method of production and natural history

PHILIP E. CLEARY AND STEPHEN J. RYAN

From the Department of Ophthalmology, University of Southern California, and Estelle Doheny Eye Foundation, Los Angeles, California, USA

SUMMARY A technique has been developed which produces an experimental posterior penetrating eye injury that reproducibly results in traction retinal detachment in rabbit eyes. The standard injury is an incision through the pars plana with vitreous prolapse and incarceration; the wound is then carefully closed with microsurgical techniques. It appears that blood in the vitreous is an essential factor in the development of vitreous traction and of traction retinal detachment. The model, which has been successfully transferred to Rhesus monkey eyes, is considered useful for further histological, electromicroscopical, electrophysiological, and ultrasound studies of posterior penetrating injuries of the eye. Our immediate goal is to assess in a controlled experiment whether pars plana vitrectomy can interrupt the sequence of events leading to traction retinal detachment after a posterior penetrating injury.

Although the prognosis for penetrating eye injuries has greatly improved, this is largely reflected in injuries which involve only the anterior segment (Moncrieff and Scherible, 1945; Snell, 1945; Roper-Hall, 1959; Remky *et al.*, 1967; Watz and Reim, 1973; Eagling, 1975). Unfortunately there has been little change in the prognosis for injuries to the posterior segment in the past 15 years (Johnson, 1971; Eagling, 1975), and severe injuries involving both the anterior and the posterior segments still result in a blind or excised eye in most cases (Johnson, 1971; Cinotti and Maltzman, 1975; Eagling, 1975). Many of these eyes suffer an expulsive choroidal haemorrhage, with disruption of the intraocular contents and prolapse of the retina, so that there is no potential for visual recovery (Eagling, 1975). However, not all eyes losing useful vision are damaged beyond potential repair; for injuries confined to the posterior segment traction retinal detachment is the main reason for loss of vision (Johnson, 1971; Eagling, 1975; Faulborn *et al.*, 1977).

The development of vitreous traction and traction retinal detachment after a penetrating eye injury has been linked clinically with the presence of vitreous haemorrhage and vitreous incarceration in the wound (Roper-Hall, 1959; Percival, 1972; Johnson, 1971; Eagling, 1975; Faulborn *et al.*,

1977). Clinical and histopathological observations suggest that fibrovascular ingrowth from the scleral wound, vitreous haemorrhage, injury to the lens, and injury to the ciliary body may all contribute to a fibroblastic response within the vitreous, which often progresses to the formation of a cyclitic membrane, in which detached retina may be incorporated (Hogan and Zimmerman, 1964; Coles and Haik, 1972; Eagling, 1975).

It has been postulated that the importance of the vitreous is that it provides a framework or scaffold for fibrosis from other sources. Removal of this scaffold is a rationale for vitrectomy in the treatment of complicated penetrating injuries which involve the posterior segment (Coles and Haik, 1972). Furthermore, after a posterior penetrating injury the blood is typically loculated within the vitreous (Winthrop *et al.*, 1978), and removal of this blood by vitrectomy may reduce the stimulus to inflammation and organisation.

The introduction of pars plana vitrectomy has offered a new approach to the treatment of complicated posterior penetrating injuries (Machemer and Norton, 1972; Michels and Ryan, 1975; Peyman *et al.*, 1975; Benson and Machemer, 1976; Hutton *et al.*, 1976; Faulborn *et al.*, 1977; Conway and Michels, 1978). Yet despite the encouraging preliminary results the indications and optimum timing for vitrectomy remain a matter of controversy. Attempts to address the issues by establishing a

Table 1 Natural history of posterior perforating injury in the rabbit eye

Type of injury	Number of eyes	Length of follow-up	Histological appearance
Standard incision and blood injection	9	3 to 9 days	Retina attached in 9 eyes
	11	12 to 15 days	Retina attached in 3 eyes Retina detached in 8 eyes
	34	18 days to 3 months	Retina attached in 6 eyes Retina detached in 28 eyes
Standard incision and injection of balanced salt solution	15	3 months	Retina attached in 14 eyes Retina detached in 1 eye
Standard incision with injury to the retina	14	2 months	Retina detached with fixed retinal folds* Posterior retinal tears (7 eyes)

randomised controlled clinical trial have been unsuccessful so far (Hutton *et al.*, 1976; Faulborn *et al.*, 1977; Ryan and Allen, personal communication). And certainly the incongruity of penetrating eye injuries with many variables in each individual injury will demand a very large number of patients within a trial to provide a statistically significant result.

Since variables are subject to more precise control in a laboratory environment than in a random patient population, we undertook a study to develop in an experimental animal a model of a posterior penetrating eye injury. Our objective was an injury with the least number of variables, which reproducibly resulted in traction (specifically, non-rhegmatogenous) retinal detachment. The present report describes the method of production and natural history of an experimental posterior penetrating injury in the rabbit eye.

Materials and methods

Pigmented rabbits of either sex, weighing 4 to 5 lb (1.8 to 2.3 kg), were anaesthetised by intravenous injection of pentobarbitone; analgesia was obtained by a retrobulbar injection of 0.5 ml saline solution containing 5 mg of lignocaine. The pupils were dilated with 1 drop of cyclopentolate 1% and 1 drop of phenylephrine 10%. The eye was gently prolapsed and secured by a lid suture. Surgery was carried out under sterile conditions and with the magnification of a Zeiss OPMI 6 operating microscope.

The standard wound was a stab incision with a Graefe knife through the pars plana to the centre of the vitreous cavity. This incision was lengthened to 8 mm with scissors, with avoidance of the lens and the peripheral retina. Gel vitreous prolapsed spontaneously through the wound, with rupture of the vitreous face, in a manner similar to that encountered in the perforated human eye. The

prolapsed vitreous was abscised and the wound carefully closed with interrupted sutures of 8-0 silk, with particular attention to good wound apposition. After wound closure the fundus was inspected by indirect ophthalmoscopy and the area of the wound and peripheral retina examined by scleral indentation. Eyes were excluded when the peripheral retina in the area of the wound could not be clearly seen. In some eyes 0.4 ml of autologous blood, drawn immediately beforehand, was injected through a 25-gauge needle inserted through the wound into the midvitreous under ophthalmoscopic control. In others, 0.4 ml of balanced salt solution was injected. The blood or balanced salt solution was injected slowly under low pressure; 0.4 ml could be easily injected without reflux through the wound.

The animals were observed at weekly intervals after surgery. Fundus photographs, descriptions, and drawings of the fundi were made. For histological study eyes were enucleated at varying intervals (Table 1).

Results

During the first week the anterior chamber and vitreous were hazy, but during the second week the media slowly cleared in the eyes without the blood in the vitreous.

STANDARD INCISION AND BLOOD INJECTION
Fifty-four eyes had a standard incision through the pars plana and injection of 0.4 ml of autologous blood into the midvitreous under ophthalmoscopic control. Some eyes were enucleated for histology at 3-day intervals after injury, and others were examined clinically at weekly intervals for up to 3 months (Table 1). At up to 9 days after injury the retina was attached in all 9 eyes examined histologically; at 12 days the retina was detached in 2 out of 4 eyes, and at 15 days the retina was detached in 6 out of 7 eyes that were enucleated (Table 1).

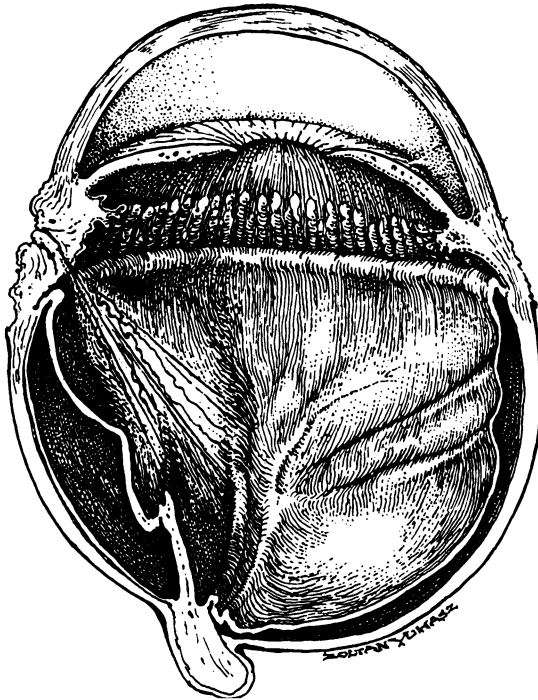


Fig. 1 Artist's interpretation of the appearance in the rabbit eye at 12 days after injury. There is a subtotal retinal detachment. A condensation of vitreous strands extends from the wound to the posterior retina suggesting anteroposterior vitreous traction. (In the rabbit eye the vitreous is adherent posteriorly in the area of myelinated nerve fibres.) Owing to vitreous traction the peripheral retina has been dragged anteriorly on to the pars plana

The remaining 34 eyes were enucleated at varying intervals between 18 days and 3 months after injury, and the retina was detached in all but 6 (Table 1).

The fundus appearance was obscured by blood in the vitreous for at least 6 weeks after injury. As the blood cleared, vitreous strands and membranes were observed extending across the anterior vitreous and antero-posteriorly to the retina (Fig. 1). From the wound, scar tissue extended into the vitreous—often on the surface of the adjacent detached retina (Figs. 3 and 4). The clinical findings were confirmed by gross examination of the enucleated eyes with the dissecting microscope. It was possible to identify changes in the vitreous with strands of vitreous extending from the wound to the posterior retina (Fig. 1), and strands extending from the wound to the peripheral retina in the area of the vitreous base (Fig. 2). The configuration of the retinal detachment suggested the presence of vitreoretinal traction; the earliest appearance was of traction from the wound to the posterior retina,

resulting in elevation of the area of the medullary rays (Fig. 1), and the late appearance was of total retinal detachment with the entire retina drawn up into the area of the wound (Fig. 4). The peripheral retina showed a characteristic appearance of being dragged forward towards the wound. This characteristic rolling forward of the peripheral retina on to the pars plana might involve its entire circumference (Fig. 2).

STANDARD INCISION AND INJECTION OF BALANCED SALT SOLUTION

Fifteen eyes had a standard incision through the pars plana and injection of 0.4 ml of balanced salt solution. These eyes were documented clinically for 3 months after injury (Table 1). Vitreous strands or membranes were not identified by ophthalmoscopy in these eyes, nor was fibrous proliferation from the area of the wound into the vitreous. One eye had a spontaneous vitreous haemorrhage at the time of the incision, and 4 weeks later, when the vitreous haemorrhage had cleared, a traction retinal detachment was observed. In the other 14 eyes the retinas remained attached.

STANDARD INCISION WITH INJURY TO THE RETINA

Fourteen eyes suffered unintentional retinal damage at the time of injury, either by disinsertion of the peripheral retina adjacent to the wound or by direct laceration of the retina. During the incision through the pars plana 10 of these eyes suffered a spontaneous choroidal and subretinal haemorrhage, and the blood ruptured through the peripheral retina so that torn retina was prolapsed into the wound. In the other 4 eyes the standard incision was too far posterior and involved the peripheral retina. Retinal

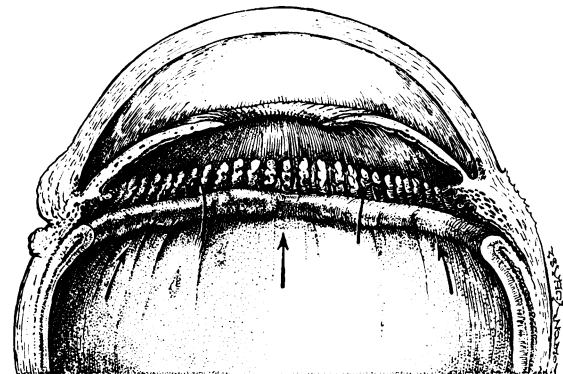


Fig. 2 Artist's interpretation of the characteristic rolling forward of the peripheral retina on to the pars plana owing to traction on the vitreous base

detachment was total in 10 eyes and incomplete in 4. Typically, at 3 to 4 weeks after injury these eyes showed the appearance of fixed retinal folds, starfolds, pigment granules on the surface of the retina, and funnel-type retinal detachments. In 4 eyes large posterior retinal tears occurred and in 3 eyes smaller oval tears. These retinal tears were not identified at the time of injury.

Discussion

For penetrating injuries which are confined to the posterior segment traction retinal detachment is the main reason for loss of vision (Eagling, 1975; Hutton *et al.*, 1976; Benson and Machemer, 1976; Faulborn *et al.*, 1977). The experimental injury in the rabbit eye incorporates few variables and results in traction retinal detachment which is highly reproducible. Progressive detachment of the retina has been produced previously in experimental animals but usually as a result of retinal hole formation (Foulds, 1963; Machemer and Norton, 1968). By contrast, our specific aim was to produce traction retinal detachment and to avoid direct

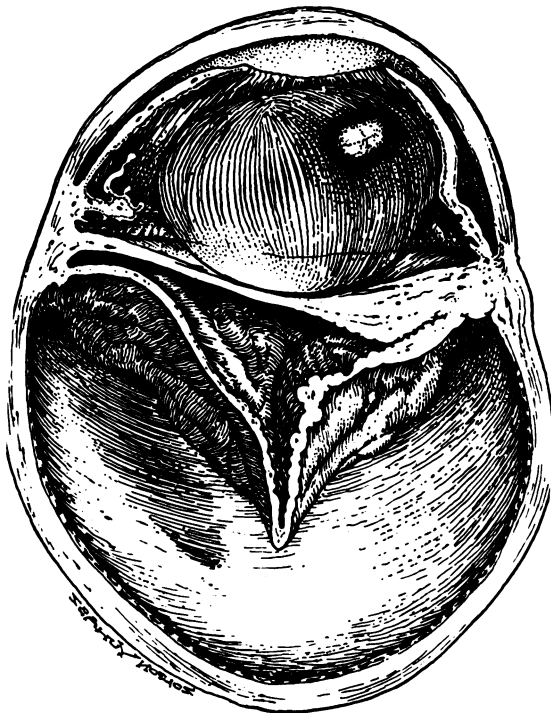


Fig. 3 Artist's interpretation of the appearance in the rabbit eye at 4 weeks after injury. The retina is totally detached, and a prominent fibrous ingrowth from the wound has formed a cyclitic membrane

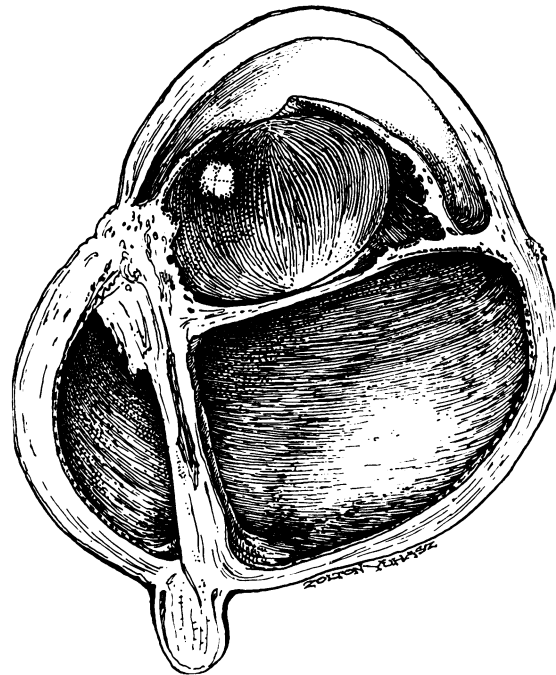


Fig. 4 Artist's interpretation of the appearance at 6 weeks after injury. There is a total retinal detachment, with the retina drawn up into the wound and incorporated into the fibrous ingrowth

damage to the retina, thus excluding rhegmatogenous retinal detachment as another variable.

Injection of blood into the rabbit vitreous by a needle puncture alone may result in retinal detachment due to a posterior retinal tear (Freilich *et al.*, 1966) or related to the growth of scar tissue into the vitreous along the needle track and subsequent traction on the retina (Constable, 1975; Swan, 1977). In preliminary experiments we investigated the effects of a single injection of autologous blood into the rabbit vitreous by a needle puncture, but we were unable to produce traction retinal detachment with the reproducibility that we desired (Cleary and Ryan, 1978). Furthermore, since some vitreous loss is a frequent accompaniment of penetrating trauma, it was felt desirable to include this as a component of the experimental model.

In the rabbit eye, after injury and intravitreal blood injection, retinal detachment occurred typically at between 12 and 15 days. During the development of retinal detachment the configuration of the peripheral and posterior retina, as well as the orientation of vitreous strands, suggested the presence of vitreous traction. The characteristic rolling forward of the peripheral retina, which might involve its entire circumference (Fig. 1),

might be related to vitreoretinal adhesion in the area of the vitreous base. Similarly, the early detachment of the posterior retina could be attributed to anterior-posterior vitreous traction related to the vitreoretinal adhesion in the area of the medullary rays in the posterior fundus of the rabbit.

We have observed a similar appearance of traction on the peripheral retina in the region of the vitreous base not only in rabbit eyes but also in monkey eyes and in human eyes enucleated after penetrating injuries (Cleary and Ryan, 1978; Winthrop *et al.*, 1978). Clinically we have also observed in patients after a posterior penetrating injury that this characteristic dragging forward of the peripheral retina on to the pars plana may precipitate and be the only cause of total retinal detachment. In the human eye, however, unlike the rabbit's, the cortical vitreous is not so adherent to the posterior retina (Foos, 1975), and typically, after a posterior penetrating injury, the vitreous becomes detached posteriorly without subsequent direct traction on the posterior retina. The exception is a double perforating injury with incarceration of vitreous in both the anterior and posterior wound, when antero-posterior vitreous traction may be observed.

In this study, although our aim was to avoid direct damage to the retina, in some eyes the peripheral retina was involved in the standard incision, while in others a profuse choroidal and subretinal haemorrhage occurred at the time of injury, and blood ruptured through the peripheral retina, disinserting it. This expulsive type of haemorrhage in the rabbit eye has its counterpart in the most severe penetrating injuries in human eyes (Eagling, 1975; Barry, 1975).

In eyes with clear media, and retinal tears and funnel-shaped retinal detachments, we observed the appearance of fixed retinal folds and starfolds with pigment on the surface of the retina. The clinical appearance resembled massive periretinal proliferation (Machemer and Laguna, 1975). The histopathological features will be reported in detail in a separate communication.

The experimental evidence in this study supports clinical observations on the importance of blood in the vitreous in the development of vitreous traction and, ultimately, traction retinal detachment after a posterior penetrating eye injury (Johnson, 1971; Percival, 1972; Eagling, 1975; Faulborn *et al.*, 1977). We have successfully transferred this method of experimental posterior penetrating injury to rhesus monkey eyes and have shown that traction retinal detachment is also highly reproducible in the primate eye. We believe that this experimental model can provide much information of clinical

relevance and the opportunity to examine mechanisms which underlie the development of traction retinal detachment. The many variables which complicate penetrating injuries may be isolated and investigated, such as the effects of vitreous loss, the role of blood and its different components in the vitreous, the effects of lens injury, and the admixture of lens material and vitreous. It will be of value to have precise histopathological correlation of ultrasound and bright-flash electroretinographic findings. Finally, we shall investigate in a controlled experiment the role and optimum timing for vitrectomy in the treatment of a posterior penetrating injury.

We thank Ms Kate Borkowski for technical assistance and Mr Zoltan Yuhasz for the illustrations.

References

- Barry, D. R. (1975). Pathological changes after trauma. *Transactions of the Ophthalmological Societies of the United Kingdom*, **95**, 340-345.
- Benson, W. E., and Machemer, R. (1976). Severe perforating injuries treated with pars plana vitrectomy. *American Journal of Ophthalmology*, **81**, 728-732.
- Cinotti, A. A., and Maltzman, B. A. (1975). Prognosis and treatment of perforating ocular injuries. *Ophthalmic Surgery*, **6**, 54-61.
- Cleary, P. E., and Ryan, S. J. (1978). Experimental posterior penetrating eye injury in the Rhesus monkey (in preparation).
- Coles, W. H., and Haik, G. M. (1972). Vitrectomy in intra-ocular trauma. *Archives of Ophthalmology*, **87**, 621-628.
- Constable, I. J. (1975). Pathology of vitreous membranes and the effect of haemorrhage and new vessels on the vitreous. *Transactions of the Ophthalmological Societies of the United Kingdom*, **95**, 382-386.
- Conway, B. P., and Michels, R. G. (1978). Vitrectomy techniques in the management of selected penetrating ocular injuries. *Transactions of the American Academy of Ophthalmology and Otolaryngology*, **85**, 560-583.
- Eagling, E. M. (1975). Perforating injuries involving the posterior segment. *Transactions of the Ophthalmological Societies of the United Kingdom*, **95**, 335-339.
- Faulborn, J., Atkinson, A., and Olivier, D. (1977). Primary vitrectomy as a preventive surgical procedure in the treatment of severely injured eyes. *British Journal of Ophthalmology*, **61**, 202-208.
- Foos, R. Y. (1975). Ultrastructural features of posterior vitreous detachment. *Albrecht v. Graefes Archiv für klinische und experimentelle Ophthalmologie*, **196**, 103-111.
- Foulds, W. S. (1963). Experimental retinal detachment. *Transactions of the Ophthalmological Societies of the United Kingdom*, **83**, 153-170.
- Freilich, D. B., Lee, P. F., and Freeman, H. McK. (1966). Experimental retinal detachment. *Archives of Ophthalmology*, **76**, 432-436.
- Hogan, M. J., and Zimmerman, L. E. (1964). *Ophthalmic Pathology: An Atlas and Textbook*. W. B. Saunders: Philadelphia.
- Hutton, W. L., Snyder, W. B., and Vaiser, A. (1976). Vitrectomy in the treatment of ocular perforating injuries. *American Journal of Ophthalmology*, **81**, 733-739.
- Johnson, S. (1971). Perforating injuries: A five-year study. *Transactions of the Ophthalmological Societies of the United Kingdom*, **91**, 895-921.

- Machemer, R., and Norton, E. W. D. (1968). Experimental retinal detachment in the owl monkey. *American Journal of Ophthalmology*, **66**, 388-395.
- Machemer, R., and Norton, E. W. D. (1972). A new concept for vitreous surgery. 3. Indications and results. *American Journal of Ophthalmology*, **74**, 1034-1056.
- Machemer, R., and Laqua, H. (1975). Pigment epithelium proliferation in retinal detachment (massive periretinal proliferation). *American Journal of Ophthalmology*, **80**, 1-23.
- Michels, R. G., and Ryan, S. J. (1975). Results and complications of 100 consecutive cases of pars plana vitrectomy. *American Journal of Ophthalmology*, **80**, 24-29.
- Moncreiff, W. F., and Scherible, K. J. (1945). Penetrating injuries of the eye. A statistical study. *American Journal of Ophthalmology*, **28**, 1212-1220.
- Percival, A. P. B. (1972). Late complications from posterior segment intraocular foreign bodies. *British Journal of Ophthalmology*, **56**, 462-468.
- Peyman, G. A., Huamonte, F. U., and Rose, M. (1975). Management of traumatic retinal detachment with pars plana vitrectomy, scleral buckling, and gas injection. *Acta Ophthalmologica*, **53**, 731-737.
- Remky, H., Kobor, J., and Pfeiffer, H. (1967). Traumatologie chirurgicale du segment antérieur. *Annales Instituto Barraquer*, **7**, 487-509.
- Roper-Hall, M. J. (1959). The treatment of ocular injuries. *Transactions of the Ophthalmological Societies of the United Kingdom*, **79**, 57-69.
- Snell, A. C. (1945). Perforating ocular injuries. *American Journal of Ophthalmology*, **28**, 263-281.
- Swan, D. A. (1977). *Vitreous Surgery and Advances in Fundus Diagnosis and Treatment*, p. 3. Appleton, Century Croft: New York.
- Watz, H., and Reim, N. (1973). Statistics of injuries referred to provincial eye clinic. *Klinische Monatsblätter für Augenheilkunde*, **162**, 648-655.
- Winthrop, S., Cleary, P. E., and Ryan, S. J. (1978). The histopathology of penetrating ocular trauma (in preparation).