

Stickler's syndrome and neovascular glaucoma

N. J. A. YOUNG, R. A. HITCHINGS, K. SEHMI, AND A. C. BIRD

From Moorfields Eye Hospital and the Institute of Ophthalmology, London

SUMMARY A case of Stickler's syndrome with neovascular glaucoma is described.

Wagner (1938) described a Swiss family with dominantly inherited vitreoretinal degeneration, and von Böhringer *et al.* (1960) re-examined the family, adding further members. The characteristic findings which Wagner described were an optically empty vitreous with peripheral avascular membranes, peripheral visual field constriction, narrowing and sheathing of the peripheral retinal arteries with pigment clumping adjacent to the abnormal vessels and elsewhere in the periphery, choroidal vascular sclerosis and atrophy, myopia, and disc pallor in advanced cases. Presenile posterior subcapsular cataracts were present in some patients while in others these had become mature. None of the patients described by Wagner (1938) and subsequently by von Böhringer and others (1960) were reported to have retinal detachment, and yet further families have been described in whom the risk of retinal detachment was high and the results of treatment poor. Many authors (Delaney *et al.*, 1963; Alexander and Shea, 1965; van Balen and Falger, 1970; Hirose *et al.*, 1973; Tolentino *et al.*, 1976) have advocated early prophylactic surgery prior to the onset of cataracts, which occur consistently by the fifth decade of life (Hirose *et al.*, 1973). The concept has now evolved that there are separate conditions in which the fundus changes are similar. In Wagner's syndrome myopia is of a low degree, cataracts occur in middle life, and the risk of retinal detachment is small. By contrast, families in which retinal detachments are common have high myopia and associated skeletal abnormalities. In some families the skeletal abnormalities are characterised by changes similar to Marfan's syndrome with arachnodactyly, lax joints, and micrognathia; severe arthropathy, cleft palate, and neurosensory deafness have also been described. This condition has been termed Stickler's syndrome (Stickler *et al.*, 1965; Stickler and Pugh, 1967; Opitz *et al.*, 1972; Popkin and Polomeno, 1974).

Open-angle glaucoma has been described (Jansen,

1962; Delaney *et al.*, 1963; Hirose *et al.*, 1973) in some cases, and Frandsen (1966) reported congenital angle anomalies in others.

It is the purpose of this paper to describe a patient with a family history of retinal detachment who presented with neovascular glaucoma in addition to other changes identical to those described by Wagner, and to discuss the aetiology of the glaucoma and the management of the disease in this case.

Case history

A 32-year-old woman of German descent was first seen in the casualty department on 4 May 1978. For the previous 2 months she had experienced transient obscurations of vision in the right eye, which became constantly blurred 10 days before presentation. A diagnosis of neovascular glaucoma had been made at another hospital and treatment started with acetazolamide. Despite this she had developed severe pain in the eye 5 days later, and 2 days before presentation a haemorrhage had been noted in the anterior chamber. Her general health was good, and her only recent medications had been the oral contraceptive pill, which was stopped in January 1978.

Vision with the right eye was 1/60, with a relative afferent pupil defect, and with the left 6/9 corrected by a -6.50 D sphere. The conjunctiva on the right was intensely injected with corneal epithelial oedema. There was a 2 mm hyphaema with rubeosis iridis and ectropion of the iris pigment epithelium; the intraocular pressure was 45 mmHg. No view of the fundus was possible, but ultrasonography showed that the retina was flat. The left anterior segment was normal, as was the drainage angle, the intraocular pressure being 10 mmHg. The left lens had scattered cortical and posterior subcapsular opacities, the latter associated with anterior vitreous attachments. The mid vitreous was optically empty, and there were peripheral vitreous veils. The optic disc and macula were normal, but the peripheral retinal vessels were narrowed and sheathed with

perivascular pigment clumping. Elsewhere in the peripheral retina there was extensive lattice degeneration and pigmentary change, but no holes were found (Fig. 1). Iris fluorescein angiography showed

no abnormality in the left eye (Fig. 2), but fundus angiography showed widespread vascular changes in the periphery, consisting of delayed perfusion of the retina, areas of non-perfusion, and telangiectasis, with considerable dye leakage (Fig. 3). The capillary pattern in the posterior pole was normal. General examination showed no abnormality except arachnodactyly; there was no carotid bruit.

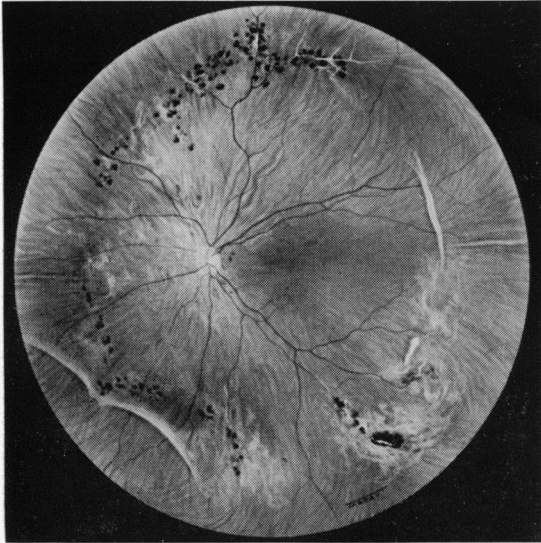


Fig. 1 *Left eye. Extensive peripheral perivascular pigment clumping and vitreous veils*

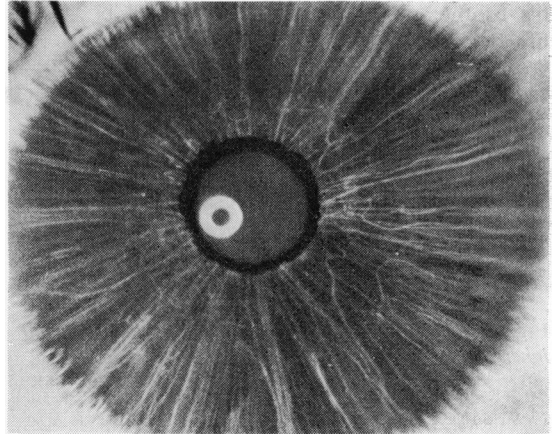


Fig. 2 *Left eye. Iris angiogram showing normal vascular pattern with no leakage of dye*

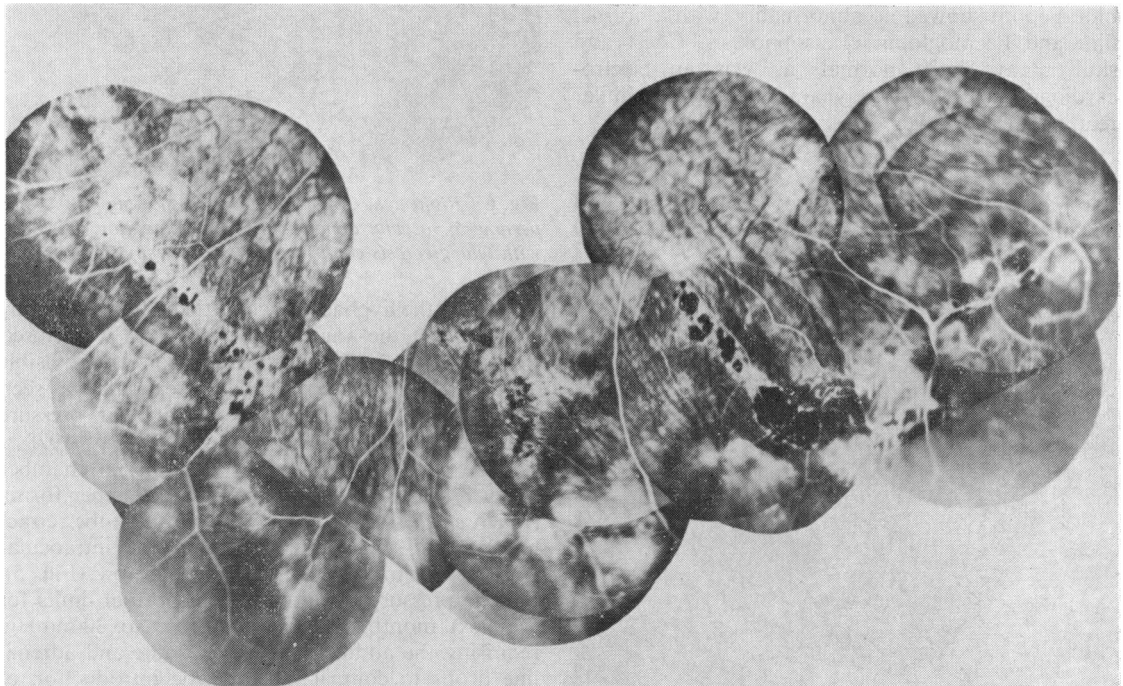


Fig. 3 *Left eye. Composite angiogram of the lower half of the fundus showing widespread peripheral vascular abnormalities with areas of non-perfusion, telangiectasis and dye leakage*

FAMILY HISTORY (Fig. 4)

The patient's mother (III/6) was blind after failed operations for retinal detachment when aged 38 and 45 years, and her sister (IV/6) had one phthisical eye after a similar failure, the other showing vitreous and retinal changes identical to those in our patient's left eye. The affected uncle (III/1) is blind in both eyes, but further details are not available as he lives abroad. The maternal grandfather (II/1) and 2 of his brothers (II/3 and II/6) were blind by middle life.

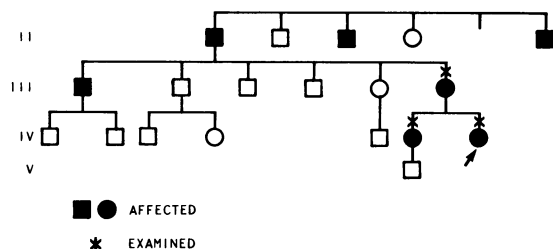


Fig. 4 Pedigree demonstrating the autosomal dominant inheritance

INVESTIGATIONS

Urea and electrolytes, glucose tolerance test, plasma proteins, and immunological screen were normal. Serological tests for syphilis were negative. A full blood count showed no abnormality, with a normal film and haemoglobin electrophoresis. Chest and skull x-rays were normal, as was an electrocardiogram. Ophthalmodynamometry gave similar readings in each eye.

PROGRESS

She was symptomatically improved on atropine and dexamethasone drops and acetazolamide. On 9

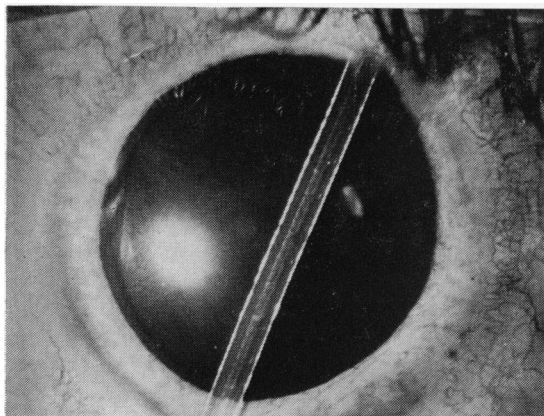


Fig. 5 Right eye. Tube traversing the anterior chamber becoming impacted in the angle below

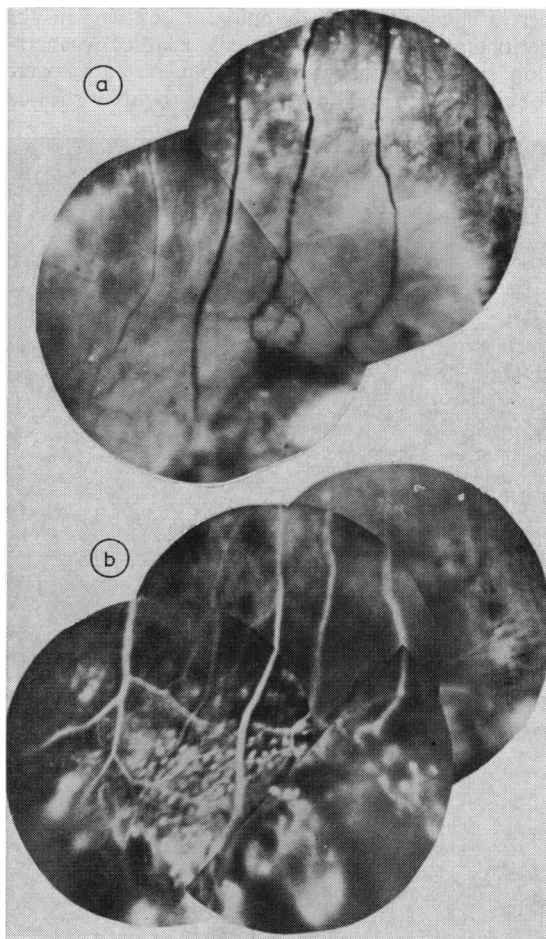


Fig. 6 Right eye. Colour photograph showing peripheral vascular abnormalities and exudation (6a) with telangiectasis confirmed on angiography (6b)

May 1978 the hyphaema had settled, and gonioscopy showed that the angle in the right eye was closed throughout 360°. The fundus was not clearly visible at this time, but an area of yellow exudate was seen in the periphery below. The intraocular pressure remained at 40 mmHg, and on 17 May 1978 a silicone tube was inserted into the anterior chamber under a scleral flap, draining into the upper fornix (Blach *et al.*, 1977). Postoperatively the tube retracted beneath the conjunctiva, and the intraocular end became impacted in the angle below (Fig. 5), but the pressure remained within normal limits for the next month. Thereafter it rose to 30 mmHg, requiring the addition of guanethidine and adrenaline drops to control it. After the introduction of the tube the iris new vessels regressed, and after an initial hyphaema there has been no further bleeding,

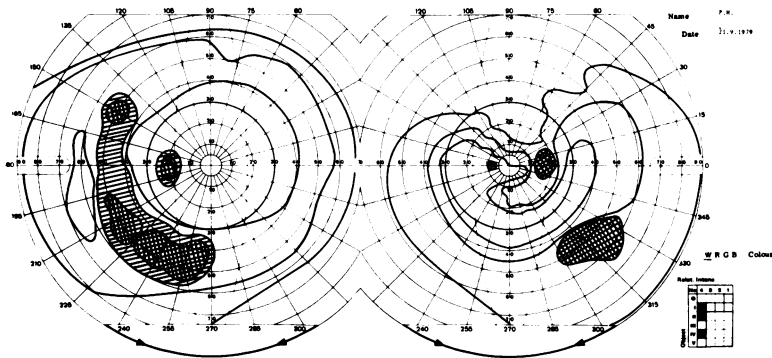


Fig. 7 Visual fields showing mid-peripheral scotomata in the temporal field of each and constriction of the upper half of the right

the eye remaining free of pain and without signs of inflammation. The right vision improved to 6/9 despite the development of posterior subcapsular lens opacities. The vitreous and peripheral retina showed changes similar to the left, but the area of telangiectasis was more extensive and associated with considerable exudate below (Fig. 6a). Fluorescein angiography confirmed the abnormal vasculature below, with much dye leakage in the late stages (Fig. 6b).

Visual fields on 21 September 1978 showed scotomata in the mid-temporal periphery of each eye with constriction of the upper field in the right eye (Fig. 7).

On 8 November 1978 an encircling procedure was performed on the left eye which resulted in considerable relaxation of the vitreous traction. The vision in this eye was 6/9 and the intraocular pressure 12 mmHg when last seen. A postoperative iris angiogram showed no change in the vascular pattern.

Discussion

Iris neovascularisation has not previously been reported in Stickler's syndrome. In general it is assumed to be a response to ischaemia (Knox, 1965; Hart and Haworth, 1971) and occurs in patients with widespread capillary non-perfusion in diabetes mellitus (Kohner *et al.*, 1976) and central retinal vein occlusion (Laatikainen and Kohner, 1976), where there is peripheral vessel closure as in Eales's disease (Smith, 1955) and retrolental fibroplasia (Reese and Blodi, 1951), and in cases of reduced perfusion of the eye due to carotid insufficiency (Smith, 1962; Hart and Haworth, 1971), pulseless disease (Knox, 1965), and giant cell arteritis (Wolter and Phillips, 1965). It is also seen in long-standing retinal detachment (Zollinger, 1952). In retinal telangiectasis iris new vessels are rarely seen, and in the original series

reported by Coats (1908) 3 of the 6 eyes had secondary glaucoma due to neovascularisation of the angle, but these were the eyes with the most severe retinal disease causing retinal detachment.

In our case the relevance of these factors is uncertain. Peripheral retinal non-perfusion, though present, was confined to the pre-equatorial fundus; the telangiectasis was limited in extent and not associated with retinal detachment. The only other possible contributing factor was myopia, in which the peripheral vessels appear attenuated, but how this affects retinal perfusion is at present poorly documented (Deutman, 1977), and it is not known if this attenuation results in ischaemia. No case has yet been reported of iris new vessels developing in the presence of uncomplicated myopia.

It is possible that the combination of peripheral vessel closure, retinal telangiectasis, and myopia had an additive effect. However, an additional factor in this patient which at present remains undetected may have precipitated neovascularisation in the anterior segment; alternatively there may be an inherent tendency for this complication in Stickler's syndrome. The lack of previous reports on this subject suggests that it is not a common complication, but 2 cases are described (Alexander and Shea, 1965) in which blind eyes were enucleated after raised intraocular pressure and which showed signs suggestive of iris neovascularisation on histological examination.

This case presented 2 management problems, the first being the control of her glaucoma and the second prophylaxis for retinal detachment.

Treatment of secondary glaucoma due to a neovascular process involving the drainage angle depends on the degree of angle closure. Laatikainen (1977) has shown in central retinal vein occlusion that, in the early stages with an open or partially open angle, panretinal photocoagulation is effective in reducing the pressure and the extent of the rubeosis. When the angle is closed, as in this case, surgical

procedures must be adopted to reduce the pressure and maintain vision. Of the noninvasive techniques available cyclocryotherapy is considered to be the most effective by some authors (Feibel and Bigger, 1972; Krupin *et al.*, 1978), but visual deterioration is an almost constant feature, hypotony occurs in one-third of cases, and there is a risk of anterior segment ischaemia (Krupin *et al.*, 1977) and phthisis bulbi (Feibel and Bigger, 1972). Furthermore the pressure control may be only temporary owing to regrowth of the ciliary epithelium (Smith *et al.*, 1977). In this patient the apparently normal posterior pole suggested a good visual prognosis, and because of the complications of cyclocryotherapy we were reluctant to undertake this procedure. Standard filtering procedures are seldom effective as fibrovascular tissue blocks the sclerostomy, but, if used, Scheie's operation may be successful (Watson, 1972), and good results have been reported with sclerotomy combined with β -irradiation (Cameron, 1973). Molteno *et al.* (1977) have reported good results using a seton to drain aqueous into the subconjunctival space. This concept was modified by Blach *et al.* (1977), and their technique was successfully performed in our case, achieving adequate pressure control and maintenance of central vision for 9 months. The lens in this eye is now showing early posterior subcapsular opacities which are distant from any possible site of impaction by the tube. There are certainly adequate causes for lens opacities in this patient apart from the tube. Cataracts are known to develop as part of the disease (Wagner, 1938), and in addition there has been a period of raised intraocular pressure and evidence of anterior segment ischaemia, both of which may have contributed to their development.

Prophylactic measures to reduce the risk of retinal detachment are universally advocated in the literature, and, as detachment operations had failed in all the eyes in members of the family examined by us, they were clearly desirable in our patient. Because of the extensive circumferential vitreous traction, encirclement was considered the ideal procedure. However, the presence of peripheral vascular abnormalities and indirect evidence of anterior segment ischaemia in the right eye indicated that such a procedure might carry a very high risk, since it is known that encirclement itself can cause ischaemia (Boniuk and Zimmerman, 1961; Hudson *et al.*, 1973). With these considerations in mind, and having ensured that there was no evidence of anterior segment ischaemia in the left eye, we undertook a gentle encirclement.

It appears that iris neovascularisation can occur in Stickler's vitreoretinopathy, although the causal relationship between the 2 is unclear. Our findings

suggest that before prophylactic measures are undertaken it may be important to investigate the vascular status of the anterior segment, though Hirose *et al.* (1973) reported no ischaemic complications following surgery. We are still considering the more complex problem of prophylaxis for the right eye.

References

- Alexander, R. L., Shea, M. (1965). Wagner's disease. *Archives of Ophthalmology*, **74**, 310-318.
- Blach, R. K., Hitchings, R. A., and Laatikainen, L. (1977). Thrombotic glaucoma—prophylaxis and management. *Transactions of the Ophthalmological Societies of the United Kingdom*, **97**, 275-279.
- Boniuk, M., and Zimmerman, L. E. (1961). Necrosis of the iris, ciliary body, lens and retina following scleral buckling operations with circling polyethylene tubes. *Transactions of the American Academy of Ophthalmology and Otolaryngology*, **65**, 671-691.
- Cameron, M. E. (1973). Thrombotic glaucoma successfully treated. *Transactions of the Ophthalmological Societies of the United Kingdom*, **93**, 537-547.
- Coats, G. (1908). Forms of retinal disease with massive exudation. *Royal London Ophthalmic Hospital Reports*, **17**, 440-525.
- Delaney, W. V., Podedworny, W., and Havener, W. H. (1963). Inherited retinal detachment. *Archives of Ophthalmology*, **69**, 44-50.
- Deutman, A. F. (1977). In Krill's *Hereditary Retinal and Choroidal Diseases*, vol. 2, p. 1093. Harper and Row: Hagerstown, Maryland, New York, San Francisco, London.
- Feibel, R. M., and Bigger, J. F. (1972). Rubeosis iridis and neovascular glaucoma. Evaluation of cyclocryotherapy. *American Journal of Ophthalmology*, **74**, 862-867.
- Frandsen, E. (1966). Hereditary hyaloideo-retinal degeneration (Wagner) in a Danish family. *Acta Ophthalmologica*, **44**, 223-232.
- Hart, C. T., and Haworth, S. (1971). Bilateral common carotid occlusion with hypoxic ocular sequelae. *British Journal of Ophthalmology*, **55**, 383-388.
- Hirose, T., Lee, K. Y., and Schepens, C. L. (1973). Wagner's hereditary vitreoretinal degeneration and retinal detachment. *Archives of Ophthalmology*, **89**, 176-185.
- Hudson, J. R., Kanski, J. J., and Elkington, A. R. (1973). Prophylactic encirclement. *British Journal of Ophthalmology*, **57**, 531-536.
- Jansen, L. M. A. A. (1962). Degeneratio hyaloideo-retinalis hereditaria. *Ophthalmologica*, **144**, 458-464.
- Kohner, E. M., Shilling, J. S., and Hamilton, A. M. (1976). The role of avascular retina in new vessel formation. *Metabolic Ophthalmology*, **1**, 15-23.
- Knox, D. L. (1965). Ischaemic ocular inflammation. *American Journal of Ophthalmology*, **60**, 995-1002.
- Krupin, T., Johnson, M. F. and Becker, B. (1977). Anterior segment ischaemia after cyclocryotherapy. *American Journal of Ophthalmology*, **84**, 426-428.
- Krupin, T., Mitchell, K. B., and Becker, B. (1978). Cyclocryotherapy in neovascular glaucoma. *American Journal of Ophthalmology*, **86**, 24-26.
- Laatikainen, L. (1977). Preliminary report on the effect of retinal panphotocoagulation on rubeosis iridis and neovascular glaucoma. *British Journal of Ophthalmology*, **61**, 278-284.
- Laatikainen, L., and Kohner, E. M. (1976). Fluorescein angiography and its prognostic significance in central

- retinal vein occlusion. *British Journal of Ophthalmology*, **60**, 411–418.
- Molteno, A. C. B., van Rooyen, M. M. B., and Bartholomew, R. S. (1977). Implants for draining neovascular glaucoma. *British Journal of Ophthalmology*, **61**, 120–125.
- Opitz, J. M., France, T., Hermann, J., and Spranger, J. W. (1972). The Stickler syndrome. *New England Journal of Medicine*, **286**, 546.
- Popkin, J. S., and Polomeno, R. C. (1974). Stickler's syndrome (hereditary progressive arthro-ophthalmopathy). *Canadian Medical Association Journal*, **111**, 1071–1076.
- Reese, A. B., and Blodi, F. C. (1951). Retrolental fibroplasia. *American Journal of Ophthalmology*, **34**, 1–24.
- Smith, J. L. (1962). Unilateral glaucoma in carotid occlusive disease. *Journal of the American Medical Association*, **182**, 683–684.
- Smith, R. (1955). Concerning glaucoma and central retinal venous occlusion. *Transactions of the Ophthalmological Societies of the United Kingdom*, **75**, 265–279.
- Smith, R. S., Boyle, E., and Rudt, L. A. (1977). Cyclocryotherapy—a light and electron microscopic study. *Archives of Ophthalmology*, **95**, 284–288.
- Stickler, G. B., Belau, P. G., Farrell, F. J., Jones, J. D., Pugh, D. G., Steinberg, A. G., and Ward, C. E. (1965). Hereditary progressive arthro-ophthalmopathy. *Mayo Clinic Proceedings*, **40**, 433.
- Stickler, G. B., and Pugh, D. G. (1967). Hereditary progressive arthro-ophthalmopathy. 2. Additional observations on vertebral abnormalities, a hearing defect and a report of a similar case. *Mayo Clinic Proceedings*, **42**, 495.
- Tolentino, F. I., Schepens, C. L., and Freeman, H. M. (1976). *Vitreoretinal Disorders: Diagnosis and Management*, pp. 242–259. W. B. Saunders: Philadelphia, London, Toronto.
- van Balen, A. Th. M., and Falger, E. L. F. (1970). Hereditary hyaloideoretinal degeneration and palatoschisis. *Archives of Ophthalmology*, **83**, 152–162.
- von Böhrringer, H. R., Dieterle, P., and Landolt, E. (1960). Zur Klinik und Pathologie der Degeneratio hyaloideoretinalis hereditaria (Wagner). *Ophthalmologica*, **139**, 330–338.
- Wagner, H. (1938). Ein bisher unbekanntes Erbleiden des Auges (Degeneratio hyaloideo-retinalis hereditaria), beobachtet im Kanton Zürich. *Klinische Monatsblätter für Augenheilkunde*, **100**, 840–857.
- Watson, P. (1972). Surgery of the glaucomas. *British Journal of Ophthalmology*, **56**, 299–306.
- Wolter, J. R., and Phillips, R. L. (1965). Secondary glaucoma in cranial arteritis. *American Journal of Ophthalmology*, **59**, 625–634.
- Zollinger, R. (1952). Klinische Untersuchungen über Gefassneubildungen auf der Iris. *Ophthalmologica*, **123**, 216–219.