

Benign familial fleck retina

SURA F. SABEL AISH AND BASEM DAJANI

From the Jordan University Hospital

SUMMARY A family with a benign form of fleck retina is described. Seven out of 10 siblings were affected. The consanguineous parents were both normal. The fundi were massively invaded by lesions which appeared as discrete, bright white or yellow flecks situated well behind the retinal blood vessels. The macula was always free. Fluorescein studies revealed a healthy macula and retinal and choroidal blood vessels. The relationship of this benign form to the other forms of fleck retina is discussed.

Massive mosaic hyaline excrescences along the cuticular layer of Bruch's membrane, leading to the appearance of multiple deep yellow to yellowish white lesions of variable size and shape in the fundi have been well known for more than a century.¹⁻³ Many forms of this condition have been described with different findings, prognosis, and inheritance.⁴⁻¹⁵

Krill^{16,17} regarded all these conditions as fleck retina diseases. He then classified them into 4 groups: fundus albipunctatus, fundus flavimaculatus, familial drusens, and fleck retina of Kandori. This classification with subgrouping according to the severity of the condition seemed to bring order into the confusion that had lasted for a century.

In this paper we present a family with flecked retina, with typical fundoscopy picture and normal visual findings. We suggest they belong to a fifth group—benign familial fleck retina.

Patients and methods

This was an Arab Palestinian family residing in Amman-Jordan. There were 10 children. The parents are first cousins. All 12 members of the family were studied. The parents had normal vision and fundi. Seven out of 10 children had flecked retina (Fig. 1). The affected children had undergone the following ophthalmic investigations: Refraction tests and assessment of visual acuities, dark adaptometry, central and peripheral visual fields, fundoscopy along with white light photography, and fluorescein angiography. Examination of the patients included a full blood picture; blood

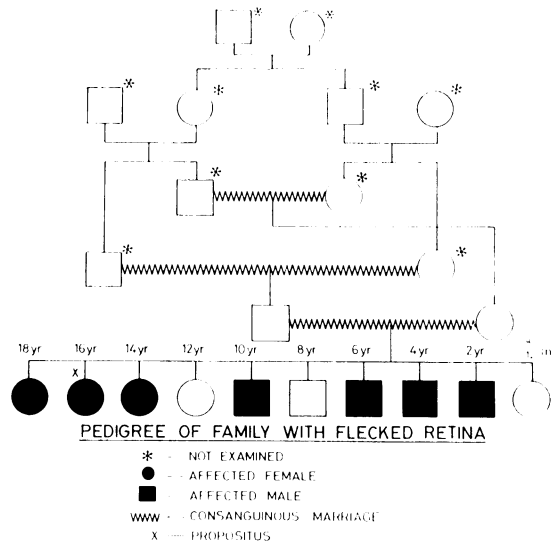


Fig. 1 The pedigree of the family.

sugar, cholesterol; protein electrophoresis; and skull x-rays.

CASE 1

The propositus was a 16-year-old girl who presented in 1977 with headaches. She gave no history of ophthalmic or systemic disease.

On examination her visual acuities were 6/18 corrected to 6/6 with -1.00 DS in either eye. The anterior segments of both eyes were normal, and the intraocular pressures were within normal limits. Central and peripheral visual fields did not show any abnormalities, and dark adaptometry was normal. Fundoscopy showed that in both eyes

Correspondence to Dr S. F. Sabel Aish, Jordan University Hospital, PO Box 13046, Amman-Jordan.

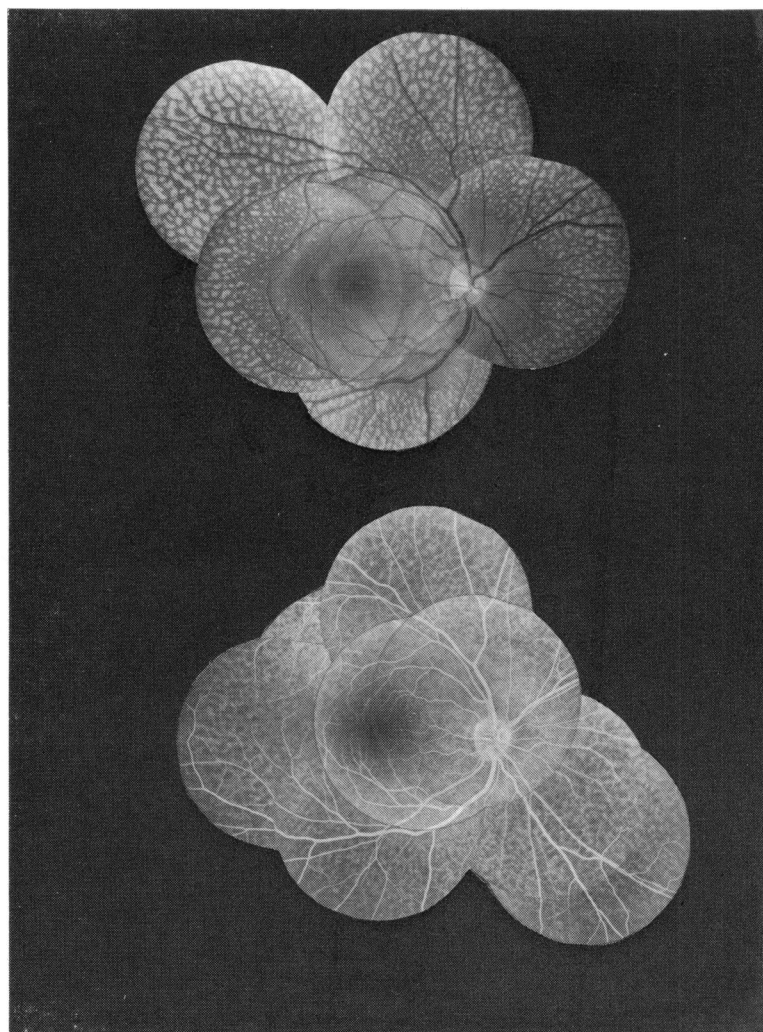


Fig. 2 Above: *White light photograph demonstrating fleck retinal dystrophy in case 1 (the propositus). Central areas are spared.* Below: *Fluorescein angiography of the same eye. Notice that the macula is the only nonhyperfluorescent area.*

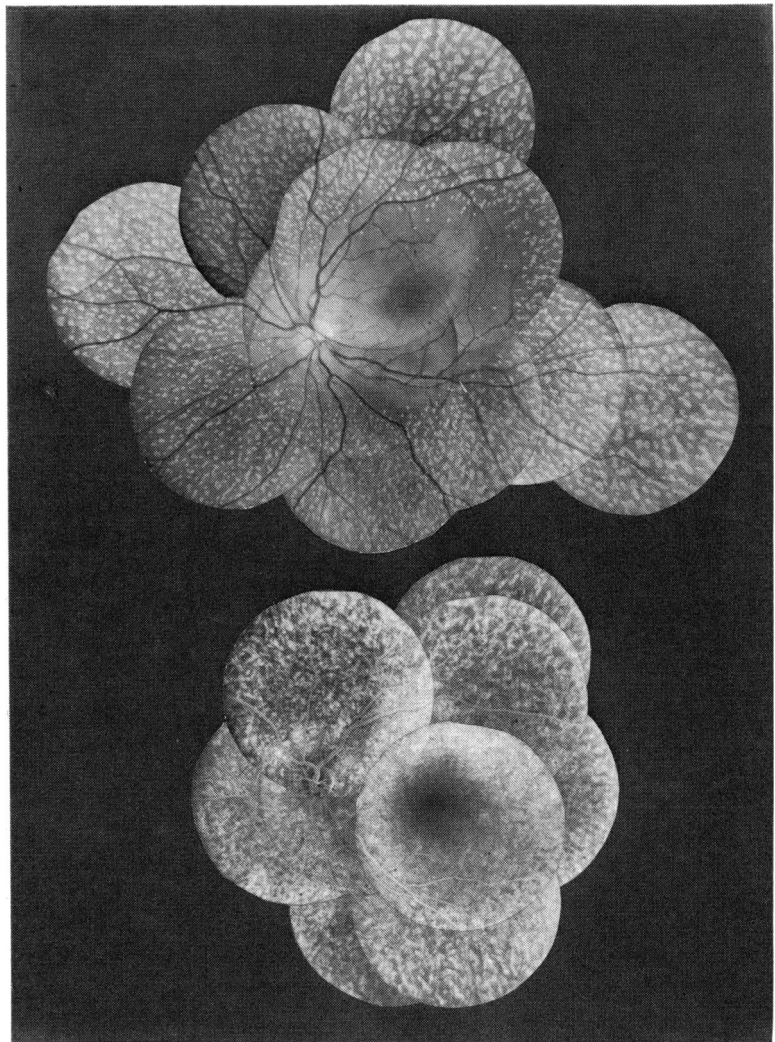
the fundi were invaded by an enormous number of bright white and sometimes yellowish white flecks of variable size and configuration, arranged in a concentric pattern around the posterior fundus and sparing the optic disc, macula, papillomacular area as well as 1-2 disc diameters circular region surrounding the disc and macula. They spread everywhere in the equator and mid and extreme periphery of fundus. The more centrally located flecks appeared sparse, small, round, and dot-like. Others of larger size in the equatorial and peripheral areas varied in shape, being, round, elongate, pisciform, star-shaped, and sometimes circular. The flecks were always discrete, well defined, with almost sinuous margins and a flat or prominent surface. They appeared to be solid and well behind the

retinal vascular tree. Throughout the fundus they showed the same mosaic appearance. They spared no area in the periphery. No pigmentary disturbances, calcification or conglomeration was observed, nor were choroidal vessels observed.

Follow-up 1 year later gave the same funduscopy findings, with 6/6 corrected visual acuity in either eye. Headaches had disappeared, visual fields were again normal, and there was no delay in dark adaptation.

Fluorescein angiography carried out at this time showed that apart from the macula the whole fundus was hyperfluorescent, including the central areas which appeared free of flecks on funduscopy and white light photography. This indicated there was no close correlation between the site of the

Fig. 3 Above: *Plain fundus composite photograph illustrating the distribution of flecks in case 2. The flecks involve more central areas than those in case 1. Below: Fluorescein angiography to the same eye.*



flecks and the hyperfluorescent areas, particularly in the central part of the fundus (Fig. 2).

CASE 2

The eldest sister of the propositus was 18 years old. She gave no history of systemic or ophthalmic trouble.

Visual acuity in both eyes was 6/6. Her visual fields and dark adaptometry were normal. The fundi were extensively invaded by flecks like those seen in case 1. The disc, macula, and paramacular area bordered by the upper and lower temporal retinal vascular branches were the only areas that were spared (Fig. 3). Small, round, dot-like flecks were distributed nasally above and below the disc, while the equatorial and midperipheral areas of the

fundi were invaded by much larger fleck lesions with irregular configurations, mainly longitudinal in shape. The most peripheral parts of the fundus were invaded mainly by linear flecks. The results of fluorescein angiography were comparable to those seen in the propositus. The only nonfluorescent area was the macula (Fig. 3).

CASE 3

A 14-year-old boy, brother of the propositus. His corrected visual acuities were 6/6. His visual fields were normal, and he did not show any defect in dark adaptation. The fundi were very extensively invaded by fleck lesions, comparable in shape and size to those in the propositus. But in this case, apart from the disc and macula, no other areas were

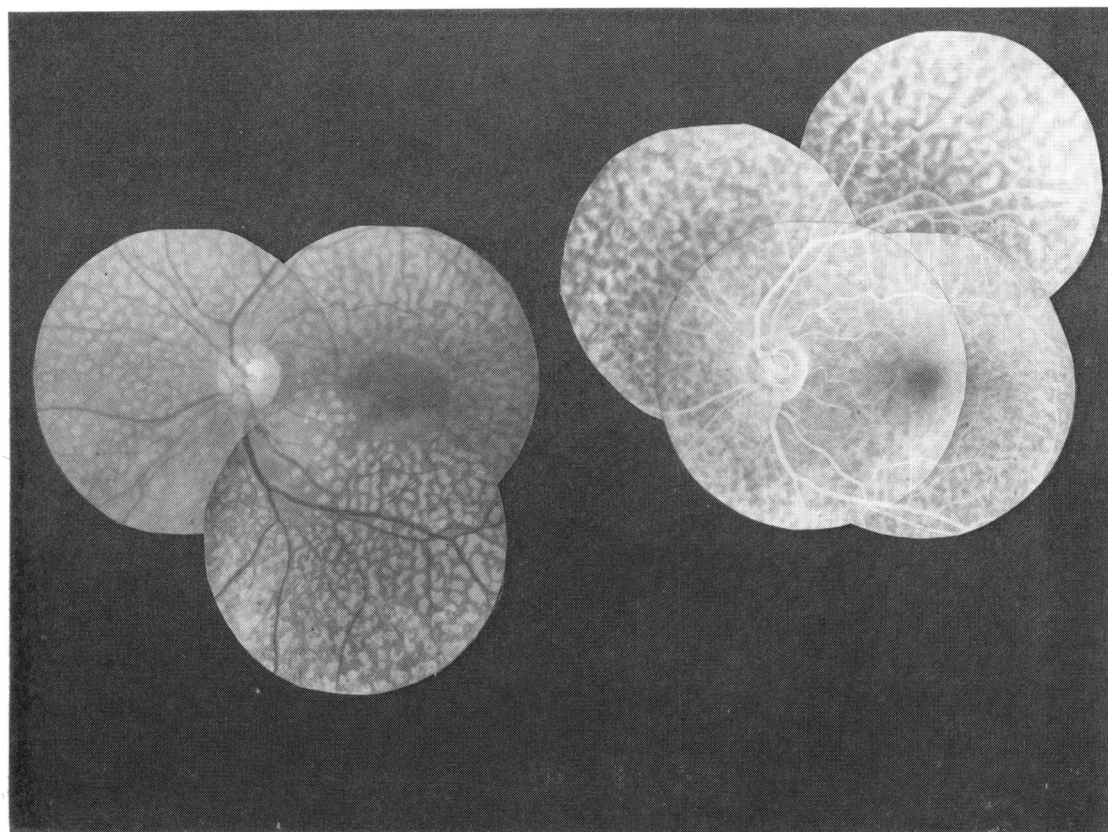


Fig. 4 Left: *White light fundus composite photograph of the left eye of case 3.* Right: *Fluorescein angiography of the same eye.*

spared (Fig. 4). As in the previous cases, fluorescein angiography showed hyperfluorescence of the whole fundi apart from the macula itself, with a normal vascular tree (Fig. 4).

CASE 4

A 12-year-old boy, brother of the propositus. This child was also healthy, with 6/6 visual acuities and normal visual fields and dark adaptometry. Both his eye grounds were affected with fleck lesions comparable in shape, size, and distribution to those in the propositus, as seen by funduscopy, fundus photography, and fluorescein angiography (Fig. 5).

CASE 5

A 6-year-old brother of the propositus. He had 6/6 uncorrected visual acuities with normal visual fields and dark adaptometry. Only the mid and extreme periphery of the eye grounds were invaded by small, dot-like, round fleck lesions. Some appeared to be of the same shape as those found in the pre-

vious cases but never of the same size. The disc, macula, and retinal as well as choroidal blood vessels were normal. Fluorescein angiography revealed a rather uniform hyperfluorescent fundus apart from the fleck-free macular area (Fig. 6).

CASE 6

A 4-year-old boy, brother of the propositus. As in the previous cases he had 6/6 vision in both eyes, and examination of the anterior segments of both eyes showed nothing abnormal. Fundoscopy of both eyes revealed symmetrical involvement, with fine fleck lesions scattered everywhere beyond the central fundus. The flecks appeared immature in comparison with those seen in the older sisters and brothers. Discrete and sparse along the central border of the involved areas, they were mainly round in shape. Fluorescein angiography revealed hyperfluorescent fundi except for the macula itself. The retinal and choroidal blood vessels were normal (Fig. 7).

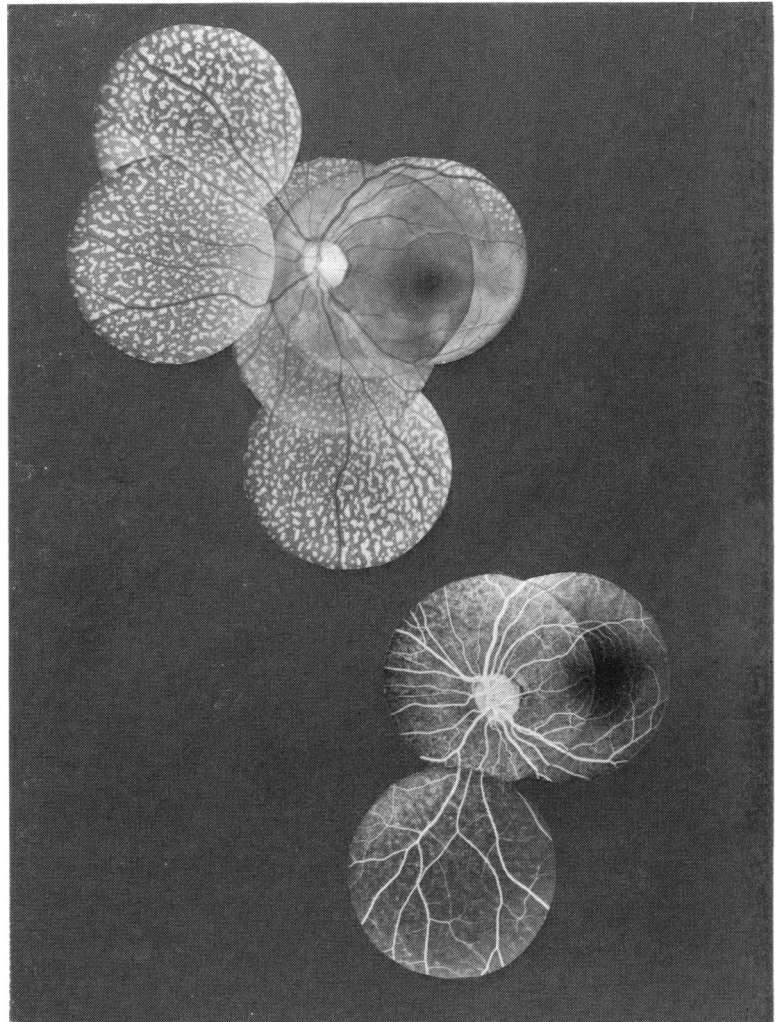


Fig. 5 Above: *White light fundus photography*. Below: *Fluorescein angiography to left eye of case 4*. Here the pattern and distribution of flecks are rather similar to those of the *propositus*.

CASE 7

A 2-year-old boy, brother of the *propositus*. Fundoscopy showed the same appearance as in case 6, except that the fleck lesions appeared smaller, fainter, and sparser; they were situated mainly in the peripheral fundus (Fig. 8). Fluorescein angiography could not be undertaken. The child appeared emmetropic, with normal day and night vision.

Discussion

The 7 cases presented here are characterised by multiple whitish or yellowish white fleck-like deposits deeply situated in the retina well behind the retinal vascular tree. They varied in size and configuration, being round, pisciform, star-shaped,

and linear. No vascular changes in either retina or choroid and no abnormalities in the central fundus were observed. Nor could pigmentary disturbances or secondary calcifications be seen among the fleck-like lesions. Apart from some differences in size and shape of the flecks and slight variations in the pattern of their distribution in the juxtapapillary area, these 7 cases seem to constitute a uniform fleck retina dystrophy.

Clinically there was no night blindness or any delay in dark adaptation. The fundal lesions in the younger patients were clearly immature when judged by their size, density, concentration, and shape in comparison with those of the older patients. However, the findings at fluorescein angiography did not differ with age of patient. These observa-

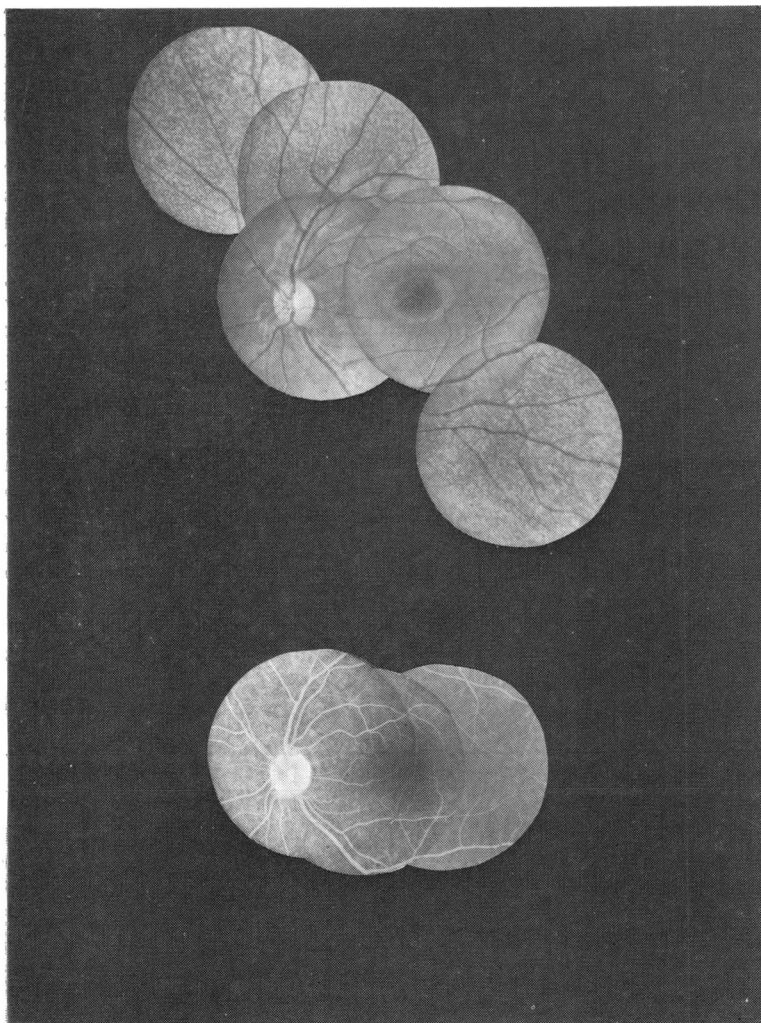


Fig. 6 Above: *White light photography.* Below: *Fluorescein angiography.* *Left eye, case 5.* Notice the fine immature flecks which are studded in the paracentral and peripheral area.

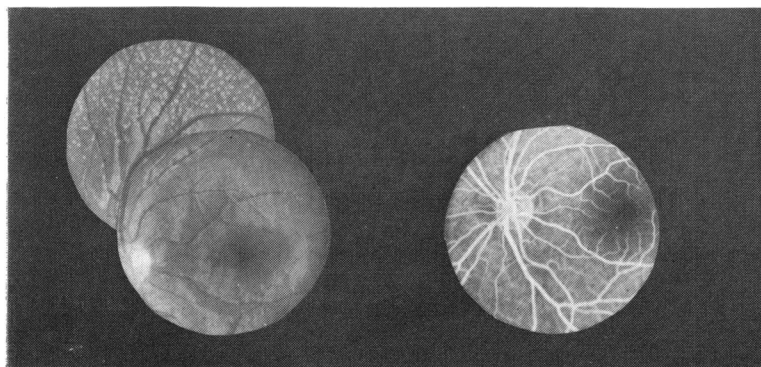


Fig. 7 Left: *White light fundus photograph of left eye in case 6,* showing the small fine flecks dystrophy extending beyond the central areas. Right: *Fluorescein angiography of same eye.*

tions, together with the fact that there was hyper-fluorescence of the fleck-free area as seen with fundoscopy and white light photography, suggest that involvement of Bruch's membrane antedates the appearance of the flecks.

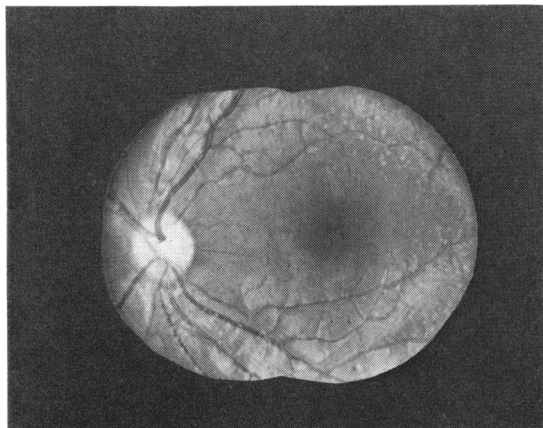


Fig. 8 Fundus white light photograph showing some discrete, fine, dot-like flecks scattered in the peripheral fundus of left eye in case 7.

The main features of the different types of flecked retina disorders reported in the literature are summarised in Table 1. We consider the family reported here to be a separate entity, benign familial fleck retina. In contrast to all previously reported cases of fleck retina disorders our cases showed no disturbance of visual functions attributable to the disorder during a 3-years follow-up. It is obvious that our family cannot be considered as familial drusen or fundus flavimaculatus. The macular involvement, calcifications, choroidal involvement, and visual function disturbances reported in these conditions are different from what was seen in our family.

The distribution of the flecks in our cases may be similar to that of fundus albipunctatus, but their shape is different. In addition, the fact that none of our cases had any disturbance of visual function puts them in a separate entity. When compared to cases of the fleck retina of Kandori our cases show more extensive involvement of the fundus, with flecks of different shape and size that show no conglomeration.

We suggest that benign familial fleck retina is inherited as an autosomal recessive condition. This is

Table 1 Classification of fleck retina disorders

Fleck retina disease	Changes in fundi	Functional disturbances	Mode of inheritance
Fundus albipunctatus ^{4 6 18 20}	Discrete uniform white dots. Distribution: over the whole fundus greatest density at midperiphery. No macular involvement. No pigmentary disturbances or secondary calcification	Night blindness. Dark adaptation: normal, slow or monofunctional (only cone threshold)	Autosomal recessive Autosomal dominant ²³
Fundus flavimaculatus ^{9 11 18}	Round, linear, or pisciform lesions. Distribution: limited to the posterior pole, or extends to the equator. Macula is involved. Network atrophy of retinal pigment epithelium. Choroidal vascular atrophy	Central visual loss, colour vision loss, photophobia, paracentral scotoma, slow dark adaptation	Autosomal recessive ^{12 14 24 25}
Familial drusen ^{21 22}	Round or oval lesions in almost grape-like clusters. Distribution: concentrated in the posterior polar region. Pigmentary disturbances and secondary calcifications. Macula is almost always involved, may appear oedematous or haemorrhagic	Loss of vision during progressive stages, central scotoma slow dark adaptation	Autosomal dominant ^{16 22 26-28}
Fleck retina of Kandori ^{7 30}	Irregular flecks with great variability in size. Distribution: in the equatorial or between the equatorial and macular region with tendency for confluence. No macular lesions. Disturbance of pigment epithelium	Some night blindness. Initially delayed dark adaptation, recovers to normal value after 30-40 minutes in the dark	Autosomal recessive
Benign familial fleck retina	Round, linear, or pisciform. Distribution: in the whole fundus except the disc and macula. No macular lesions. No tendency for confluence. No pigmentary disturbances	No disturbance of visual function (no symptoms)	Autosomal recessive

supported by the fact that both sexes were involved and that both parents were free of the disease.

References

- ¹Wedl C. *Grundzuge der pathologischen Histologie*, Wien: Gerold, 1854: 825.
- ²Donders FC. Beiträge zur pathologischen Anatomie des Auges. *Albrecht von Graefes Arch Klin Ophthalmol* 1855; **1**: 106.
- ³Muller H. Untersuchungen über die glashaute des Auges, insbesondere die glaslammelle der Choroidea und ihre senilen Veränderungen. *Albrecht von Graefes Arch Klin Ophthalmol* 1856; **2**: 1–63.
- ⁴Mooren A. *Fünf Lustren ophthalmologischer Wirksamkeit*. Wiesbaden: Bergmann, 1882: 311.
- ⁵Doyne RW. Peculiar condition of choroiditis occurring in several members of the same family. *Trans Ophthalmol Soc UK* 1899; **19**: 71.
- ⁶Lauber H. Die signierte Retinitis punctata albescens *Klin Monatsbl Augenheilkd* 1910; **48**: 133–48.
- ⁷Kandori F. Very rare cases of congenital non-progressive night blindness with fleck retina. *Jpn J Ophthalmol* 1959; **13**: 384–6.
- ⁸Brini A. Fundus flavimaculatus. *Bull Soc Ophthalmol Fr* 1966; **66**: 222–39.
- ⁹Franceschetti A, Francois J. Fundus flavimaculatus. *Arch Ophthalmol (Paris)* 1965; **25**: 505–30.
- ¹⁰Carr RE. Fundus flavimaculatus. *Arch Ophthalmol* 1965; **74**: 163–8.
- ¹¹Ernest JT, Krill AE. Fluorescein studies in fundus flavimaculatus and drusen. *Am J Ophthalmol* 1966; **62**: 1–6.
- ¹²Kempt H, Amalric P, Remky H. Fundus flavimaculatus. *Klin Monatsbl Augenheilkd* 1967; **150**: 625–36.
- ¹³Deutman AF. *The Hereditary Dystrophies of the Posterior Pole*. Assen: Van Gorcum, 1971: 484.
- ¹⁴Babel J. Le fundus flavimaculatus. *Arch Ophthalmol (Paris)* 1972; **32**: 109–21.
- ¹⁵Newell FW, Krill AE, Farkas TC. Drusen and fundus flavimaculatus: clinical, functional and histological characteristics. *Trans Am Acad Ophthalmol Otolaryngol* 1972; **76**: 88–100.
- ¹⁶Krill AE, Klien BA. Flecked retina syndrome. *Arch Ophthalmol* 1965; **74**: 496–508.
- ¹⁷Krill AE. *Hereditary Retinal and Choroidal Diseases: Flecked Retina Diseases*. Hagerstown: Harper and Row, 1877: **2**: 739–819.
- ¹⁸Duke-Elder S. Diseases of the retina. *System of Ophthalmology*. St Louis: Mosby, 1967: **10**.
- ¹⁹Francois J. Fundus flavimaculatus. *Ophthalmologica (Basel)* 1970; **160**: 105–9.
- ²⁰Franceschetti A, Francois J, Babel J. Les heredo-degenerescences Chorioretinennes (degenerescences tapeto-retinennes) Paris: Masson, 1963: **1**.
- ²¹Pataias J. Honigwabenähnliche der Netzhaut als nosologische Einheit. *Ophthalmologica (Basel)* 1957; **134**: 101–4.
- ²²Pearce WC. Doyne's honeycomb retinal degeneration. *Br J Ophthalmol* 1968; **52**: 73–8.
- ²³Krill AE, Folk MR. Retinitis punctata albescens. A functional evaluation of unusual case. *Am J Ophthalmol* 1962; **53**: 450–4.
- ²⁴Brown N, Hill DW. Fundus flavimaculatus. Two familial cases with macular degeneration. *Br J Ophthalmol* 1968; **52**: 849–52.
- ²⁵Klien BA, Krill AE. Fundus flavimaculatus: clinical, functional, and histopathological observations. *Am J Ophthalmol* 1967; **64**: 3–23.
- ²⁶Doyne RW. A note on family choroiditis. *Trans Ophthalmol Soc UK* 1910; **30**: 93–274.
- ²⁷Evans PJ. Five cases of familial retinal dystrophy. *Trans Ophthalmol Soc UK* 1950; **70**: 13–58.
- ²⁸Fuchs A. Drusen of the lamina vitrea. *Am J Ophthalmol* 1956; **41**: 840–6.
- ²⁹Deutman AE, Jansen LM. Dominantly inherited drusen of Bruch's membrane. *Br J Ophthalmol* 1970; **54**: 373–82.
- ³⁰Kandori F, Tamai A, Kurimoto S, Fukunaga K. Fleck retina. *Am J Ophthalmol* 1972; **73**: 673–85.