

Penetrating eye injuries: a histopathological review

STUART R. WINTHROP, PHILIP E. CLEARY,
DONALD S. MINCKLER, AND STEPHEN J. RYAN

*From the Department of Ophthalmology, University of Southern California,
Estelle Doheny Eye Foundation, Los Angeles, California, USA*

SUMMARY This study reports the histological findings in human eyes after severe penetrating trauma. The findings confirm the high incidence of retinal detachment in eyes with severe penetrating injuries. The retina was detached in 32 out of the 34 eyes examined, with 27 having evidence of traction on the retina. These eyes were characterised histologically by intraocular cellular proliferation producing cyclitic, epiretinal, and retroretinal membranes. Intraocular cellular proliferation was discernible or established within 1 week of injury and typically resulted in a cyclitic membrane at about 6 weeks. Epiretinal and retroretinal membranes were found between 1 and 2 weeks after injury in eyes with a detached retina. The results indicate that a damaged lens, the admixture of lens material and vitreous, and the presence of vitreous haemorrhage were all factors promoting intravitreal fibroblastic proliferation. Vitreous surgery may be a rational method of treatment for these severely injured eyes by removing the stimulus and vitreous scaffold for intravitreal fibroblastic proliferation. From this series it would appear that vitrectomy should not be delayed beyond the second week of injury, by which time massive cellular ingrowth may already be under way.

Ocular trauma is an important cause of blindness,¹ and in some centres it accounts for half or more of all eyes enucleated.² Among eye disorders ocular trauma is responsible for a disproportionate economic problem, as it occurs most commonly in young, otherwise healthy, productive individuals.³ Penetrating injuries of or involving the posterior segment of the eye have a particularly poor visual prognosis because of the high incidence of retinal detachment,^{4–7} whereas in penetrating injuries confined to the anterior segment of the eye a relatively better visual outcome can be expected.⁸ Improved results for anterior segment injuries can be attributed to the introduction of microsurgical techniques, antibiotics, and steroids.⁹ Recent experience with new surgical techniques such as vitrectomy suggests that it is now also possible to salvage some eyes with severe posterior segment injuries.^{10–13}

This study reports the histological findings in human eyes enucleated after severe penetrating trauma and correlates the occurrence and chronology of various tissue reactions with time after injury. It was of special interest to characterise early changes occurring after injury and to deter-

mine how they might trigger the mechanisms responsible for eventual retinal detachment. Knowledge of the chronology of histopathological events after severe penetrating trauma may help determine a rationale for surgical management of these cases and specifically identify the optimal timing for surgical intervention by pars plana vitrectomy.

Material and methods

We reviewed case reports from 1970 to 1977 in the pathology files of the Estelle Doheny Eye Foundation and retrieved slides on 72 cases with a diagnosis of ruptured globe or penetrating eye injury. Among these were 34 eyes enucleated between 1 day and 3 years after the original injury which could be analysed histologically with reference to: (1) the status of the wound; (2) the presence of damage to the uvea, the lens, the vitreous, or the retina; (3) intraocular cellular proliferation; (4) intraocular inflammation.

Multiple sections were examined from each case stained with haematoxylin-eosin, periodic acid Schiff (PAS), Masson-trichrome, alcian blue with and without digestion by hyaluronidase, and the Prussian blue reaction for iron.

The remaining 38 eyes were either enucleated

Correspondence to Philip E. Cleary, FRCS, USC School of Medicine, Estelle Doheny Eye Foundation, 1355 San Pablo Street, Los Angeles, California 90033, USA.

soon after injury or were too disorganised to permit accurate evaluation of individual histological features. They were excluded from the study.

Results (Table 1)

THE WOUND

The site of penetration was limited to the cornea in 16 eyes, included the peripheral cornea and adjacent sclera in 13 eyes, and involved the sclera alone in 5. The full extent of the penetrating wound was determined by compiling information from clinical and operative reports, gross histological descriptions, and light microscopy.

Corneal wounds were closed externally by sliding and hyperplasia of epithelial cells within 1 week of injury. A fibrous stromal scar was present by 3 to 4 weeks in those wounds with good closure where no uveal or vitreous incarceration had occurred. Delayed healing of corneal wounds was common and could be related to defective wound closure, especially with incarceration of intraocular tissues in the wound. We judged wound apposition as particularly poor in 12 eyes, 9 of which had to be enucleated within 2 weeks of injury. Poor wound closure varied from a wide gap to moderate malapposition of the wound edges. Many corneal wounds showed posterior wound gape, probably related to superficial placement of sutures.

Healing of limbal and scleral wounds was more rapid than in corneal wounds. As early as 4 days after injury fibroblastic proliferation had occurred from the episclera, and by 1 week it occurred from the stroma of the ciliary body and choroid. At 2 weeks a mass of vascularised fibrous tissue joined the wound edges, and by 4 to 6 weeks a dense

fibrous scar had formed. Pigment, both free and within macrophages, was scattered throughout the scar tissues.

Of the 34 eyes 28 showed prolapsed or incarcerated tissues in the wound, including lens material, lens capsule and retina, and most commonly uvea or vitreous. Incarceration of tissues in a corneal wound was consistently associated with a delay in wound healing in eyes enucleated within the first 2 weeks of injury, and with the development of fibrous ingrowth from the wound in eyes enucleated from 3 weeks onward. Incarceration of tissues in limbal or scleral wounds was associated with the formation of granulation tissue in the wound, often extending intraocularly into the adjacent incarcerated tissue.

A single eye with poor closure of a corneal wound showed an epithelial ingrowth. Fibrous ingrowth from the wound occurred in 19 of the 34 eyes. It did not occur from corneal wounds without incarceration of tissues in the wound, or at least apposition of tissues to the wound, such as a damaged lens or iris. In limbal or scleral wounds fibrous ingrowth occurred despite good wound closure. These eyes, however, often had obvious vitreous incarceration in the wound, and they usually showed damage to the lens and/or vitreous haemorrhage.

THE VITREOUS

Early changes in the structure of the vitreous gel after injury included separation of the vitreous from the posterior retina and condensation of vitreous fibrils over the vitreous base. The vitreous had separated from the posterior retina in six of the 13 eyes examined between 1 and 2 weeks after injury. Of a total of 22 eyes with a posterior vitreous detachment 18 had blood loculated in the vitreous gel. In the early weeks after injury, the surface of the posterior hyaloid consisted of a discrete layer of condensed vitreous lined by red blood cells and macrophages, and in 1 eye at 2 months after injury it also contained fibroblast-like cells.

The vitreous did not become detached anteriorly. Typically, condensed vitreous fibrils remained attached to the peripheral retina and nonpigmented ciliary epithelium over the vitreous base. Vitreous fibrils often radiated from a limbal or scleral wound in which they were incarcerated, and fibroblasts were typically aligned along these fibrils. In some eyes the vitreous fibrils appeared taut and seemed to account for traction detachment of the peripheral retina 180° from a penetrating limbal or pars plana wound (Fig. 1).

Condensed vitreous fibrils were also prominent in eyes with double perforating injuries due to a foreign body. These fibrils were incarcerated in the entry and exit wound, bridging the vitreous cavity.

Table 1 *Time at which eyes were examined after injury*

<i>Time after injury</i>	<i>Eyes examined</i>
1 day	2
7 days	5
12 "	3
14 "	5
3 weeks	1
4 "	1
6 "	3
2 months	5
4 "	2
5 "	1
6 "	3
18 "	1
2 years	1
3 "	1

INTRAOCULAR INFLAMMATION

Intraocular inflammatory infiltrate was quite variable, but was often prominent in the anterior chamber or vitreous, especially in the presence of blood. Inflammatory cells, usually mainly monocytes, often surrounded the site of rupture of the lens capsule or were present in the penetrating wound or in the incarcerated tissues. The inflammatory response was most marked in eyes with lens, vitreous, and blood admixture. Macrophages were present in these eyes, surrounding lens fragments or at the margins of blood clot within the vitreous. Almost all eyes contained some macrophages either lining the posterior vitreous separation or accumulated in areas of subretinal haemorrhage.

INTRAOCULAR CELLULAR PROLIFERATION

Fibroblastic proliferation within the vitreous was

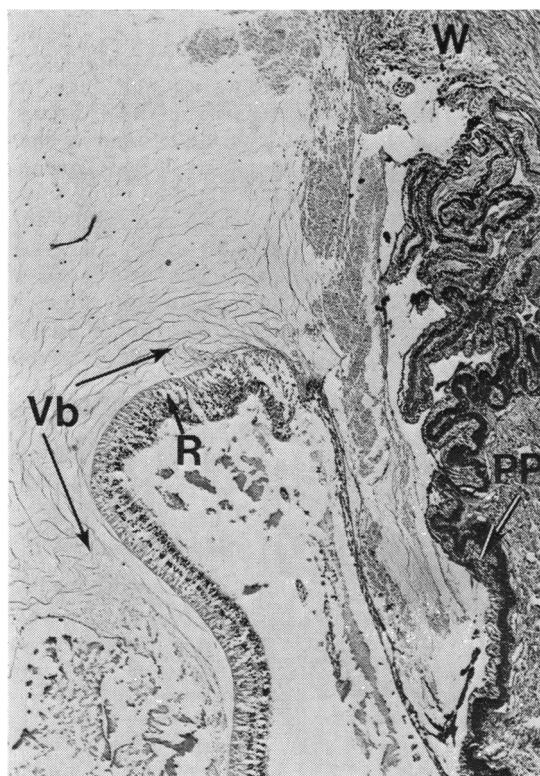


Fig. 1 Photomicrograph showing the appearance of the peripheral retina in the vitreous base at 2 months after a penetrating injury. The peripheral retina (R) is detached and appears to be pulled forward over the pars plana (PP). The vitreous is condensed and vitreous fibrils are incarcerated in a peripheral corneal wound (W). The vitreous was detached from the posterior retina, but remains attached to the peripheral retina over the vitreous base (VB). (Haematoxylin and eosin, $\times 37$).

present as early as 1 week after injury and most often emanated from the stroma of the ciliary body or choroid at a limbal or scleral wound. The invading fibroblasts appeared to extend along the scaffold provided by vitreous fibrils or into the blood clot and the vitreous gel behind the lens (Fig. 2). Fibroblastic proliferation also extended posteriorly over the pars plana and on to the surface of the peripheral retina. Fibrous proliferation within the vitreous resulted in a cyclitic membrane in which lens material, lens capsule, and detached retina were often incorporated. We found cyclitic membranes in 17 eyes as early as 2 weeks after injury in 2 eyes that had a limbal wound and vitreous haemorrhage and prolapse of the lens. The cyclitic membrane was well established in most eyes by 6 to 8 weeks after injury.

Cellular proliferation within the vitreous also appeared to originate from the nonpigmented ciliary epithelium. Characteristically these cells became elongated and at 1 week after injury appeared to be proliferating into the vitreous cavity along the vitreous fibrils attached over the vitreous base (Fig. 2).

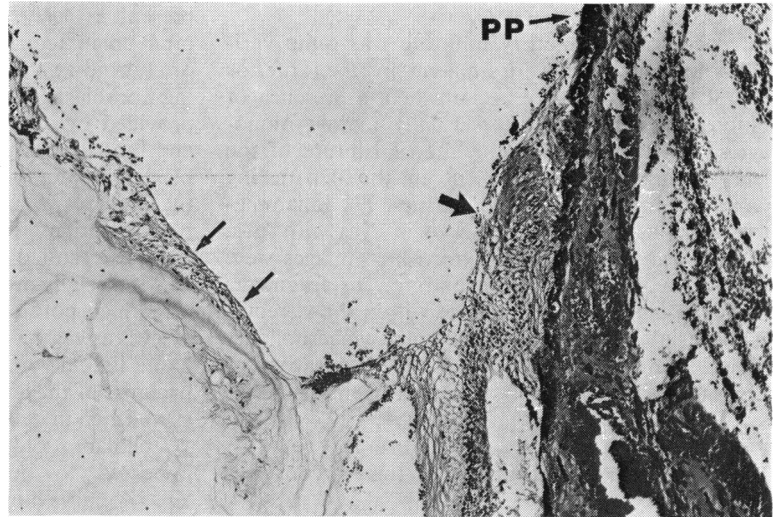
Intravitreal fibroblastic proliferation also appeared to occur from the exit wound in eyes with double perforating injuries.

THE RETINA

Retinal detachment was present in 32 out of 34 eyes. The 2 eyes without a retinal detachment had been enucleated as blind and painful because of uncontrolled glaucoma. We found retinal tears in only 2 eyes, but it was impossible to exclude a rhegmatogenous component in the others as we did not serially section all eyes. Retinal haemorrhages were present in all 20 eyes enucleated within the first 2 months of injury. Choroidal haemorrhages were also common within the first 2 to 3 weeks after injury, and ciliary body effusions were frequent in eyes with cyclitic membranes.

Epiretinal membranes were present in 14 eyes. They seemed to originate from the fibrous ingrowth from the wound, or from the surface of the optic nerve head, or from the surface of the retina. Epiretinal membranes were present over the peripheral retina in 2 eyes examined at 2 weeks after injury and consisted of spindle cells which seemed to have their origin in the fibrous ingrowth from an adjacent penetrating wound through the limbus or pars plana (Fig. 3). Similarly, by 12 days after injury spindle cells had formed an epiretinal membrane over the posterior retina adjacent to an exit wound in an eye with a double perforating injury (Fig. 4). By 4 to 6 weeks after injury multilayered epiretinal membranes could be found over both peripheral (Fig. 5) and posterior retina (Fig. 6).

Fig. 2 *Photomicrograph demonstrating the peripheral retina and pars plana (PP) 180° from a penetrating wound through the pars plana in an eye enucleated 1 week after injury. There is an apparent proliferation of the nonpigmented ciliary epithelium (large arrow). Cellular proliferation has also occurred along the anterior hyaloid (small arrows). Possibly these cells are derived from the nonpigmented ciliary epithelium. (Haematoxylin and eosin, $\times 64$).*

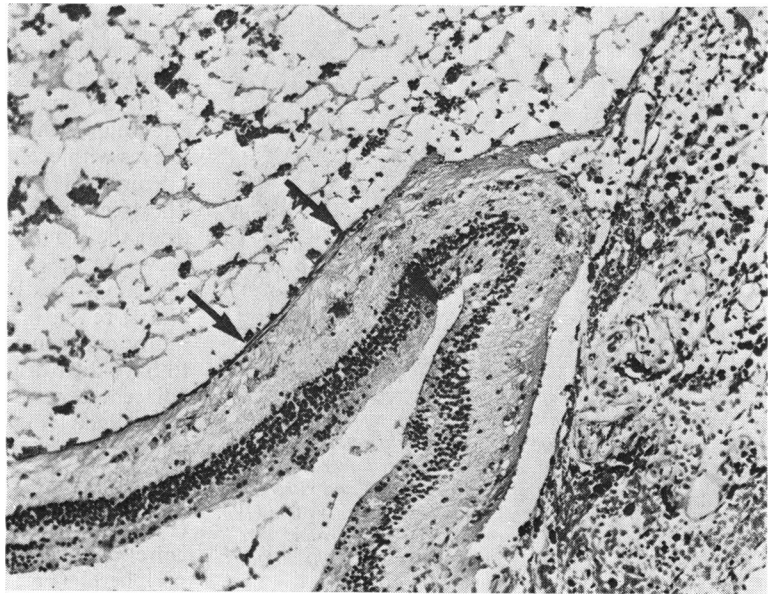


These membranes also contained pigmented cells and macrophages and some had connections to the surface of the retina. In 10 of 16 eyes the epiretinal membranes were also connected to the surface of the optic nerve head. Thick multilayered epiretinal membranes were often associated with full-thickness retinal folds.

We found retroretinal membranes in 15 eyes. They were present in 6 of 13 eyes examined between 1 and 2 weeks after injury. In the early cases the membranes were delicate, branching, and dendritic in appearance. In late cases they were thickened

and attached to folds in the retina. The pathogenesis of the retroretinal membranes was not clear, but they were often found in areas of subretinal haemorrhage (Fig. 7). In 1 eye at 1 week after injury a small retroretinal membrane composed of nonpigmented cells was connected to and extended along the outer retina (Fig. 8). In eyes examined at 2 weeks after injury prominent retroretinal membranes were present and appeared continuous with areas of proliferation of the retinal pigment epithelium. At 2 weeks also, in eyes with choroidal and subretinal haemorrhage, cellular invasion of the subretinal

Fig. 3 *Photomicrograph showing the appearance of the peripheral retina posterior to a penetrating wound through the pars plana in an eye enucleated 2 weeks after injury. The peripheral retina appears to be pulled forward over the pars plana. Spindle cells are present on the surface of the peripheral retina (arrows) and have probably originated from the wound or from proliferation of the ciliary epithelium posterior to the wound. (Haematoxylin and eosin, $\times 86$).*






Fig. 4 Photomicrograph showing the appearance of a posterior penetrating wound at 12 days after injury in an eye with a double perforating injury due to an intraocular foreign body. Spindle cells (arrows) are emanating from the surface of the peripheral retina (R), and appear to be infiltrating the vitreous and blood clot. These spindle cells may originate from the choroid, or possibly have their origin in metaplastic retinal pigment epithelial cells or in the episclera. (Haematoxylin and eosin, $\times 43$).

blood clot occurred, apparently from the choroid through breaks in Bruch's membrane (Fig. 9).

Discussion

We analysed the histological findings in 34 eyes enucleated after penetrating trauma. These eyes were characterised histologically by intraocular cellular proliferation leading to the formation of cyclitic, epiretinal, and retroretinal membranes and by the presence of traction retinal detachment. These findings support clinical studies in which traction retinal detachment has been identified as a main cause of loss of vision after a posterior penetrating injury.⁴⁻⁷

Immediately after injury an expulsive type of haemorrhage may occur with bleeding into the choroid, under the retina, and into the vitreous. If the expulsive haemorrhage results in prolapse of the intraocular contents, there is little potential for visual recovery.⁷ In the injured eye an inflammatory response occurs, the extent of which is influenced by various factors, such as vitreous haemorrhage, vitreous-lens admixture, or the presence of a reactive intraocular foreign body or of infection. As the inflammation subsides, cellular invasion and proliferation within the vitreous occur. Physical alterations in the structure of the vitreous may provide a more effective scaffold for intravitreal cellular proliferation.¹⁴ The proliferating cells give rise to

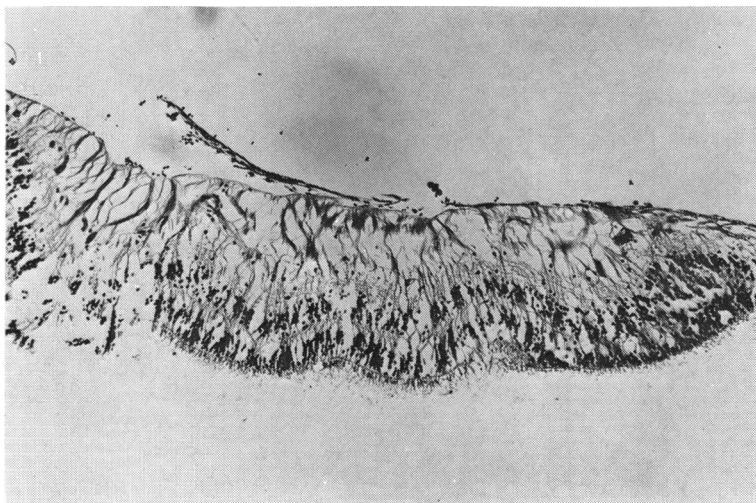
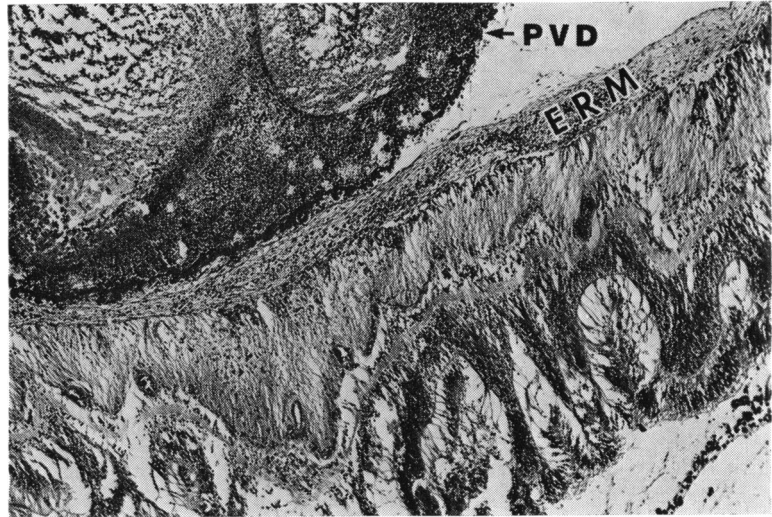


Fig. 5 Photomicrograph of peripheral retina from an eye with a total retinal detachment enucleated 6 weeks after a penetrating injury shows an epiretinal membrane 3 layers thick present on the surface of the retina. The epiretinal membrane is artefactually detached, revealing an apparently intact inner limiting membrane. (Haematoxylin and eosin, $\times 68$).

Fig. 6 Photomicrograph showing a multilayered epiretinal membrane (ERM) on the surface of the posterior retina in an eye enucleated 2 months after a penetrating injury. A posterior vitreous detachment (PVD) is present and blood clot is loculated within the vitreous gel. The posterior hyaloid (PVD) is lined with red cell debris. The epiretinal membrane lies between the posterior hyaloid and the inner limiting membrane of the retina. In adjacent sections full-thickness retina folds were present. (Haematoxylin and eosin, $\times 37$).



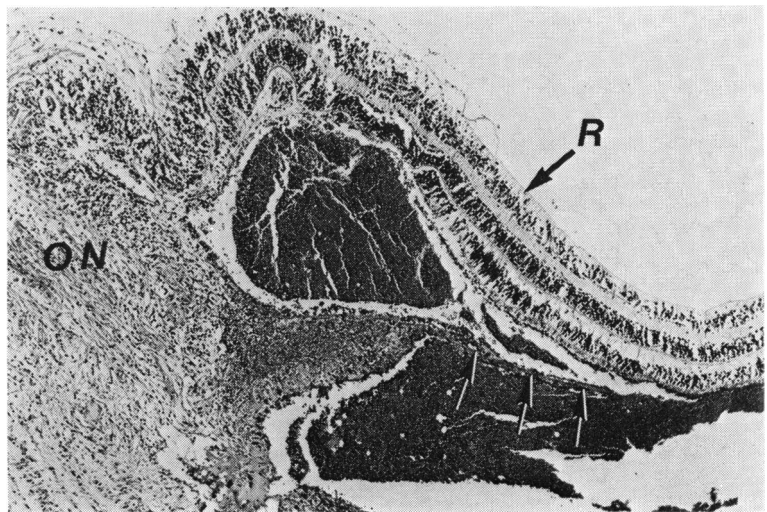
cyclitic or transvitreal membranes and to epiretinal and retroretinal membranes. Ultimately cells within these membranes contract, producing traction on the retina and resulting in traction retinal detachment.¹⁴

In this study intraocular cellular proliferation was discernible or established within 1 week of injury and typically resulted in a cyclitic membrane at about 6 weeks. A cyclitic membrane was present as early as 2 weeks after injury in eyes with limbal or scleral wounds associated with incarceration of lens material, vitreous, and blood. The factors associated with a vigorous fibrous ingrowth and intra-vitreal fibroblastic proliferation were the site of the penetrating wound; the adequacy of wound closure; the incarceration of tissues in the wound;

the extent of involvement of intraocular tissues including the iris, lens, and vitreous; and the presence of massive vitreous haemorrhage.

Cellular proliferation within the vitreous appeared to be derived from multiple sources, usually from the episclera and from the uvea in the area of a perforating scleral or limbal wound. Proliferation of the nonpigmented ciliary epithelium was also a common finding. These cells became elongated and extended along the vitreous fibrils into the vitreous cavity, apparently contributing to the formation of cyclitic membranes. Hyperplasia of the nonpigmented ciliary epithelium has been observed by others in a variety of conditions, including trauma and inflammation.^{2,15} It is also possible that the

Fig. 7 Photomicrograph showing the appearance of the posterior retina (R) and optic nerve head (ON) in an eye enucleated 12 days after a penetrating injury. A subretinal haemorrhage is present, and spindle cells have formed a retroretinal membrane (arrows) in the blood clot. Possible origins of this membrane would include adjacent pigment epithelial cells, or glial cells from the retina, or from the glial lining of the optic nerve. (Haematoxylin and eosin, $\times 43$).



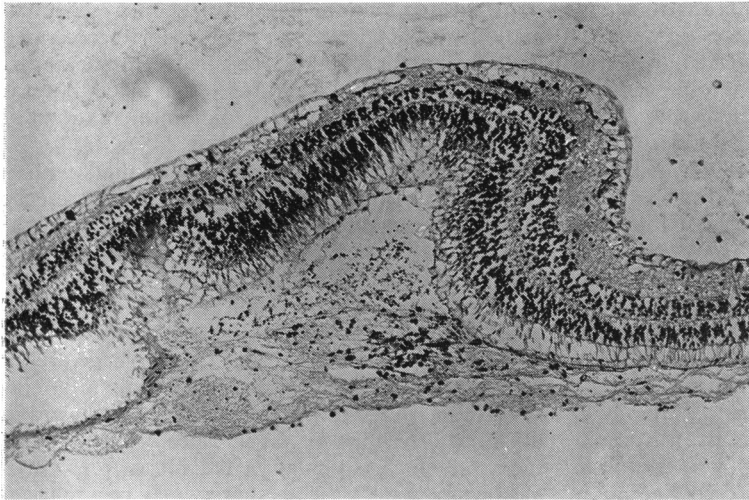


Fig. 8 Appearance of a retroretinal membrane under the equatorial retina 1 week after a penetrating injury. (Haematoxylin and eosin, $\times 77$).

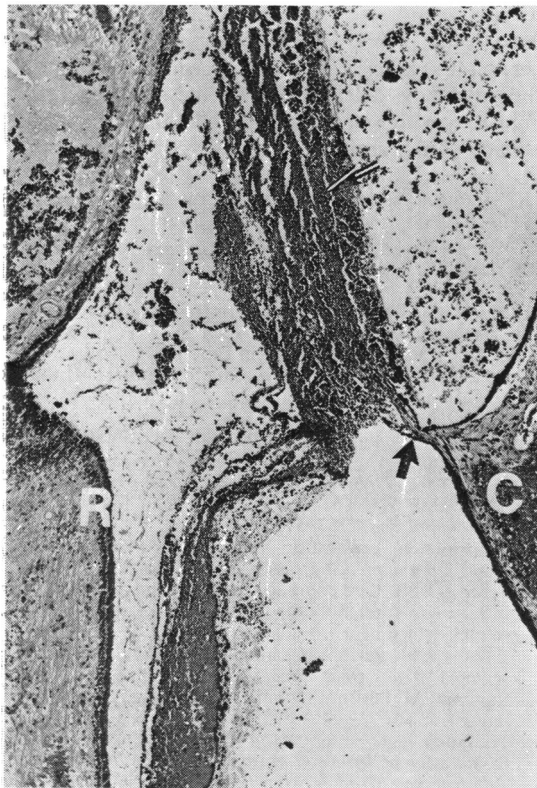


Fig. 9 Photomicrograph showing the subretinal space in an eye enucleated at 2 weeks after penetrating injury. A subretinal blood clot (BC) is present, and fibroblasts are invading the blood clot and subretinal space through a break in Bruch's membrane (arrow). The retina (R) is detached and partially necrotic. Bleeding has also occurred in the choroid (C). (Haematoxylin and eosin, $\times 42$).

intraocular fibroblastic response may have been derived in part from macrophages or monocytes originating in the systemic circulation, though most of the experimental evidence now supports the view that fibroblasts involved in wound healing are derived locally.^{16 17}

Intraocular cellular proliferation also included the formation of epiretinal and retroretinal membranes which were prominent between 1 and 2 weeks after injury. The epiretinal membranes over the peripheral retina and over the posterior retina adjacent to exit wounds in eyes with double perforations appeared to be derived from fibroblastic ingrowth from the area of the penetrating wound. A similar appearance has been observed in experimental animal models of a posterior penetrating eye injury.¹⁸⁻²⁰ On the other hand some epiretinal membranes were connected to the surface of the retina by bridges of tissue suggesting a glial component, a feature which has also been described in experimental animal models.^{14 20} The retroretinal membrane probably originated from glial cells in the retina or from proliferation of retinal pigment epithelial cells. Additionally, in some eyes with choroidal and subretinal haemorrhage, fibroblasts proliferated from the choroid through breaks in Bruch's membrane into the subretinal space.

The concept that damaged vitreous forms a scaffold or matrix for cellular proliferation was supported by this study. We observed a condensation of the anterior vitreous fibrils in virtually all cases. When vitreous was incarcerated in a penetrating wound, vitreous strands formed between the wound and the peripheral retina over the vitreous base, and in those eyes with a double perforating injury the vitreous fibrils were aligned between

entry and exit wounds. Ingrowing fibroblasts along these vitreous condensations suggest that the vitreous acts as a scaffold for the directed proliferation of cells. In a similar fashion fibroblasts from the penetrating wound proliferated along the surface of the retina. These findings are in accord with information derived from growth of fibroblasts in tissue culture, where it has been observed that cells use linear structures and scaffolds for directed proliferation.¹⁷

We found evidence of traction on the retina in 27 eyes, either by epiretinal or retroretinal membranes or signs suggesting vitreoretinal traction. Retinal tears were observed histologically in only 2 eyes, but it was impossible to exclude a rhegmatogenous component in the others, and certainly a severe penetrating injury may result in retinal dialysis or a retinal tear as part of the contusive effect. Nevertheless the characteristic configuration of the detached peripheral retina pulled anteriorly over the pars plana and the presence of retinal folds related to epiretinal and retroretinal membranes suggested that traction mechanisms were important in the evolution of eventual total retinal detachment. We observed a similar appearance in an experimental animal model of a posterior penetrating eye injury and proposed that the mechanisms for traction retinal detachment after a penetrating injury are due to the effects of vitreous traction on the peripheral retina over the vitreous base and contraction of epiretinal and retroretinal membranes on the peripheral and equatorial retina.^{14 20 21} We have also noted in this study and in experimental models that with a double perforating injury anteroposterior vitreous traction may be observed.^{18 22} But, typically, in single perforating wounds through the limbus or pars plana the vitreous detaches from the posterior retina without any subsequent anteroposterior traction.

In this study fibrous ingrowth occurred from corneal wounds only with poor wound closure and with incarceration of tissues in the wound. Conversely, with limbal or scleral wounds a fibrous ingrowth was common despite good wound closure, but usually associated with damage to the lens and/or vitreous haemorrhage. Development of fibrous ingrowth from scleral wounds despite good wound closure is in accordance with findings from experimental animal models of posterior penetrating eye injuries which emphasised the prognostic significance of blood in the vitreous and damage to intraocular structures in severe penetrating trauma.^{18 20}

The clinical implications of this study are numerous. It is clear that the primary surgical repair of penetrating wounds must include thorough explora-

tion and debridement with microscopic reapproximation of wound edges. Prolapsed or incarcerated tissue must be excised or repositioned. Vitreous incarceration in a corneal wound can be avoided, but it is probably impossible to avoid incarceration of vitreous in scleral wounds.

The results of this study indicate that, with a posterior penetrating eye injury and in the presence of retinal detachment, significant cellular proliferation is present within the vitreous and along the surfaces of the retina as early as 2 weeks after injury. The results also indicate that a damaged lens, the admixture of lens material and vitreous, and the presence of a vitreous haemorrhage are all factors promoting intravitreal fibroblastic proliferation. It has not been possible in this study or in others to determine the significance of each one of these factors in stimulating the intravitreal fibroblastic response.⁹ Vitreous surgery may be a rational method of treatment for these eyes by removing the stimulus and vitreous scaffold for intravitreal fibroblastic proliferation. From this series of post-trauma human eyes it would appear that vitrectomy should not be delayed beyond the second week of injury, by which time massive cellular ingrowth may already be under way.

This study was supported in part by the National Institutes of Health grant award EY 02061 (Dr Ryan).

References

- 1 *Blindness, Facts on the Major Killing and Crippling Diseases in the United States Today*. New York: National Health Education Committee, Inc., 1971: 4-5.
- 2 Coles WH, Haik GM. Vitrectomy in intraocular trauma: its rationale and its indications and limitations. *Arch Ophthalmol* 1972; **87**: 621-8.
- 3 Cox MS, Freeman HM. Retinal detachment due to penetration. I. Clinical characteristics and surgical results. *Arch Ophthalmol* 1978; **95**: 1354-61.
- 4 Roper-Hall MJ. The treatment of ocular injuries. *Trans Ophthalmol Soc UK* 1959; **79**: 57-69.
- 5 Johnson S. Perforating injuries: a five-year study. *Trans Ophthalmol Soc UK* 1971; **91**: 895-921.
- 6 Percival SPB. Late complications from posterior segment intraocular foreign bodies with particular reference to retinal detachment. *Br J Ophthalmol* 1972; **56**: 462-8.
- 7 Eagling EM. Perforating injuries involving the posterior segment. *Trans Ophthalmol Soc UK* 1975; **95**: 335-9.
- 8 Eagling EM. Perforating injuries of the eye. *Br J Ophthalmol* 1976; **60**: 732-6.
- 9 Faulborn J, Topping TM. Proliferation in the vitreous cavity after perforating injuries: a histopathologic study. *Albrecht von Graefes Klin Exp Ophthalmol* 1978; **205**: 157-66.
- 10 Benson WE, Machemer R. Severe perforating injuries treated with pars plana vitrectomy. *Am J Ophthalmol* 1976; **81**: 728-32.
- 11 Hutton WL, Synder WB, Vaiser A. Vitrectomy in the treatment of ocular perforating injuries. *Am J Ophthalmol* 1976; **81**: 733-9.
- 12 Conway BP, Michels RG. Vitrectomy techniques in the

- management of selected penetrating ocular injuries. *Trans Am Acad Ophthalmol Otolaryngol* 1978; **85**: 560-83.
- 13 Ryan SJ, Allen AW. Pars plana vitrectomy in ocular trauma. *Am J Ophthalmol* 1979; **88**: 483-91.
 - 14 Cleary PE, Minckler DS, Ryan SJ. Ultrastructure of traction retinal detachment in rhesus monkey eyes after a posterior penetrating eye injury. *Am J Ophthalmol* in press.
 - 15 Hogan MJ, Zimmerman LE. *Ophthalmic Pathology: An Atlas and Textbook*. Philadelphia: Saunders, 1964.
 - 16 Grillo HC. Derivation of fibroblasts in the healing wound. *Arch Surg* 1964; **88**: 82-8.
 - 17 Peacock EE, VanWinkle W. *Surgery and Biology of Wound Repair*. Philadelphia: Saunders, 1970.
 - 18 Cleary PE, Ryan SJ. Experimental posterior penetrating eye injury in the rabbit. II. Histology of wound, vitreous and retina. *Br J Ophthalmol* 1979; **63**: 312-21.
 - 19 Topping TN, Abrams GW, Machemer R. Experimental double-perforating injury of the posterior segment in rabbit eyes. The natural history of intraocular proliferation. *Arch Ophthalmol* 1979; **97**: 735-42.
 - 20 Cleary PE, Ryan SJ. Method of production and natural history of experimental posterior penetrating eye injury in the rhesus monkey. *Am J Ophthalmol* 1979; **88**: 221-31.
 - 21 Cleary PE, Ryan SJ. Histology of wound, vitreous, and retina in experimental posterior penetrating eye injury in the rhesus monkey. *Am J Ophthalmol* 1979; **88**: 212-20.
 - 22 Cleary PE, Ryan SJ. Experimental posterior penetrating eye injury in the rabbit. I. Method of production and natural history. *Br J Ophthalmol* 1979; **63**: 306-11.