



OPEN ACCESS

Original research

Pseudocoloboma-like maculopathy with biallelic *RDH12* missense mutations

Che-Yuan Kuo,^{1,2} Ming-Yi Chung ,^{3,4} Shih-Jen Chen^{1,2}

► Additional supplemental material is published online only. To view, please visit the journal online (<http://dx.doi.org/10.1136/jmg-2022-108918>).

¹Department of Ophthalmology, Taipei Veterans General Hospital, Taipei, Taiwan

²Department of Ophthalmology, National Yang Ming Chiao Tung University, Taipei, Taiwan

³Department of Life Sciences & Institute of Genome Sciences, National Yang Ming Chiao Tung University, Taipei, Taiwan

⁴Department of Medical Research, Taipei Veterans General Hospital, Taipei, Taiwan

Correspondence to

Dr Shih-Jen Chen, Department of Ophthalmology, Taipei Veterans General Hospital, Taipei, Taiwan; sjchen@vghtpe.gov.tw; mychung@nycu.edu.tw

M-YC and S-JC contributed equally.

Received 4 September 2022
Accepted 2 January 2023
Published Online First 23 January 2023

ABSTRACT

Background Hereditary maculopathy is a group of clinically and genetically heterogeneous disorders. With distinctive clinical features, subtypes of macular atrophy may correlate with their genetic defects.

Methods Seven patients from six families with adolescent/adult-onset maculopathy were examined in this clinical case series. A detailed medical history and eye examination were performed. Genomic DNA sequencing was performed using whole exome sequencing or direct sequencing of retinol dehydrogenase 12 (*RDH12*) coding exons.

Results Seven patients, including one male and six female patients, with pseudocoloboma-like maculopathy had biallelic missense *RDH12* mutations. The most common mutant allele found in six of the seven patients was p.Ala269Gly. The average disease onset was at age 19.3 years, and visual acuity ranged from count fingers to 1.0. Most of the patients had mild myopic refraction. Common findings on fundus examination and spectral-domain optical coherence tomography include discrete margins of pseudocoloboma-like macular lesions with variable degrees of chorioretinal atrophy, excavation of retinal tissue and pigmentary changes mainly in the macular area. The electroretinograms were relatively normal to subnormal in all participants.

Conclusions Progressive macular degeneration with a relatively normal peripheral retina and subsequent development of a pseudocoloboma-like appearance were the main clinical features in patients with compound heterozygous *RDH12* missense mutations. Genetic testing may be crucial for early diagnosis and may play a key role in the development of future treatment strategies.

INTRODUCTION

Inherited retinal diseases (IRDs) are a group of retinal disorders caused by gene mutations and may lead to vision loss or even blindness.¹ Before the advancement of gene identification, the classification of IRDs was primarily based on inheritance pattern, disease onset and clinical features. Through the increasing popularity of genetic diagnosis, it is clear that phenotypical variation exists among defects in a diseased gene. Among the IRD genes, mutations in the biallelic retinol dehydrogenase 12 (*RDH12*) gene cause a wide range of clinical presentations from the early onset of Leber congenital amaurosis (LCA) with nystagmus to minimally impaired central macula accompanied by preserved electroretinogram (ERG).

WHAT IS ALREADY KNOWN ON THIS TOPIC

⇒ Mutations in retinol dehydrogenase 12 (*RDH12*) were identified for causing autosomal recessive Leber congenital amaurosis type 13 and retinitis pigmentosa type 53 as listed on OMIM.

WHAT THIS STUDY ADDS

⇒ In this case series, we present a novel type of adolescent/adult-onset macular atrophy with pseudocoloboma-like feature resulting from compound heterozygous mutations in *RDH12*.

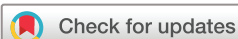HOW THIS STUDY MIGHT AFFECT RESEARCH, PRACTICE OR POLICY

⇒ *RDH12*, a protein of 316 a.a., is suitable for the development of gene-augmented therapy. Early diagnosis of *RDH12*-related retinopathy may benefit the patients.

RDH12, a short-chain NADPH (nicotinamide adenine dinucleotide phosphate) -dependent retinal reductase expressed abundantly in the inner segments of the photoreceptors, is responsible for the reduction of all-trans-retinal to all-trans-retinol in the visual cycle to maintain the normal vision of human beings by preventing the accumulation of aldehyde.^{2,3} *RDH12* is located on chromosome 14q24 with seven coding exons.⁴ Genetic defects that affect the enzymatic activity of *RDH12* may result in the build-up of cytotoxic aldehydes, leading to death of photoreceptors and subsequent vision impairment.^{2,3}

It was postulated that different *RDH12* missense mutations, in addition to numerous environmental factors, could explain these variable phenotypes. Among the different clinical presentations, the macular pseudocoloboma type with minimal intraretinal pigment or peripheral pigmentary change was the most interesting and differed from the other presentations of IRD. Unlike other phenotypes of *RDH12* such as night blindness, impairment of cone and rod responses, and severely impaired peripheral visual field (VF), pseudocoloboma-like lesions may present with asymmetrically decreased central visual acuity and paracentral scotoma in early adulthood.⁵ The differential diagnosis of such a clinical manifestation as macular coloboma includes congenital macular coloboma, congenital toxoplasmosis, central areolar choroidal atrophy or North Carolina macular dystrophy (NCMD).

In this article, we present a novel type of adolescent/adult-onset pseudocoloboma-like maculopathy



© Author(s) (or their employer(s)) 2023. Re-use permitted under CC BY-NC. No commercial re-use. See rights and permissions. Published by BMJ.

To cite: Kuo C-Y, Chung M-Y, Chen S-J. *J Med Genet* 2023;**60**:859–865.

with minimal intraretinal or peripheral pigmentary change, relatively normal to subnormal ERG, and moderately impaired vision. Equally important is that its genetic defects are biallelic missense mutations in *RDH12*, which are apparently different from typical *RDH12* phenotypes, that is, LCA13 and retinitis pigmentosa type (RP53).

METHODS

Clinical evaluation

Seven individuals diagnosed with pseudocoloboma-like maculopathy at Taipei Veterans General Hospital were enrolled in this study and underwent a complete ophthalmic examination, including best-corrected visual acuity (BCVA), intraocular pressure and measurements of refractive error using an automated refractor. Fundus colour photography, spectral-domain optical coherence tomography (SD-OCT) (Avanti RTVue XR, OptoVue, Fremont, California, USA), full-field ERG (UTAS Visual Diagnostic System with BigShot, LKC Technologies, USA), and a standard 24–4 program VF test (Model 750, Humphrey field analyser, Carl Zeiss Meditec, Dublin, California, USA) were performed on all participants. Full-field ERG was performed and recorded in accordance with the standards of the International Society for Clinical Electrophysiology of Vision. Informed consent was obtained from all the participants.

Sequence analysis

Genomic DNA was extracted from peripheral blood leucocytes, according to our laboratory protocols. Whole exome sequencing (WES) was performed in the first three cases. Briefly, fragmented DNA was captured using the SureSelect Clinical Research Exome V2 kit (Agilent, Santa Clara, California, USA), followed by sequencing using Illumina HiSeq2500 (Illumina, San Diego, California, USA). Image analyses and base calling were performed using the Illumina pipeline with the default parameters. Reads were mapped to the human reference sequence (GRCh38) using the Burrows-Wheeler Aligner with maximal exact matches algorithm⁶ with duplicate reads removed using Picard tools. Variants were called using the Genome Analysis ToolKit pipeline (Broad Institute). The vcf files were imported into VarSeq (Golden Helix, Bozeman, Montana, USA) for further filtering and prioritisation. In addition to the artificial intelligence-assisted pipeline, determination of the possible pathogenicity of the variants was facilitated by the expression profile and segregation pattern in the family. CNVs were analysed using CNVkit⁷ with a reference depth prepared using 30 WES samples captured by the same kit. An integrated genome viewer was used to visualise the read alignment and variants. Direct DNA sequencing was performed using the dideoxynucleotide chain termination method with the Sequenase V.2.0 DNA Sequencing Kit (ThermoFisher Scientific) to validate variants identified by WES and to screen for mutations in cases 4–7. PCR primers were designed to amplify exons 3–9 of *RDH12*, with at least 50 bp flanking the exon-intron junction. The PCR products were purified by exonuclease and shrimp alkaline phosphatase treatment and sequenced using one of the primers. Variants were called using the Phred-Phrap-Consed-polyPhred package and NCBI (National Center for Biotechnology Information) Reference Sequence NG_008321.1.^{8,9} Compound heterozygotes were validated using parental DNA samples or restriction fragment length polymorphism. Minor allele frequencies in East Asians were queried using gnomAD v.3.1 (<https://gnomad.broadinstitute.org/>).

RESULTS

A total of seven patients (six female and one male) with macular atrophy were examined. The mean age of onset was 19.3 years, ranging from 5 years to 47 years (table 1). The presenting symptoms included decreased BCVA, photophobia, nyctalopia and different degrees of VF scotomata. All patients had discrete boundaries of pseudocoloboma-like macular lesions in both eyes and additional features including chorioretinal atrophic change, macular scar and hyperpigmentation in the affected area (online supplemental figure 1). Visual acuity varied among the participants, ranging from count fingers to 1.0. Most of the patients had mild myopic refraction. Central, cecocentral and paracentral VF defects were observed depending on the severity and location of the involvement. The ERG was mostly normal in all participants.

Representative case descriptions

Case 1: A woman in her 30s presented with photophobia and nyctalopia that had persisted for 2 years. The patient's family history was unremarkable. BCVA was 0.2 and 0.5 in the right and left eyes, respectively. Fundus examination revealed a well-demarcated large geographical macular atrophic change with variably scattered hyperpigmentation in both eyes. Fundus autofluorescence showed rims of hyperfluorescence along the temporal side of the central atrophic area whereas no hyperfluorescent rim was found at the nasal side. The visual acuity of this patient remained 0.2 and 0.5 after 7 years of follow-up (figure 1A and B). SD-OCT revealed coloboma-like choroid atrophy with an epiretinal membrane and thinning and disruption of the retinal structure (figure 1C and D). ERG levels were nearly normal (figure 1E). Nasal bilateral paracentral scotoma was detected using VF testing (figure 1F).

Case 7: A teenage girl presented to our clinic with decreased BCVA since the age of 11. On examination, BCVA was 0.1 in both eyes, and remained relatively stable after 4.5 years of follow-up. Fundus colour photography revealed variable degrees of pigmentation within the well-defined macular atrophy. SD-OCT showed atrophy of the outer nuclear layer and retinal pigment epithelium (RPE) at the baseline (figure 2A). Two years after the initial presentation, SD-OCT of the left eye demonstrated epiretinal membrane formation, progressive thinning of choroidal tissue, disruption of Bruch's membrane and herniation of the overlying retinal tissue, mimicking a pseudocolobomatous lesion (figure 2C). VF testing showed a central scotoma in both eyes, and ERG showed bilateral subnormal cone signals.

RDH12 mutation

In this case series, the ophthalmoscopic findings in seven patients resembled those in NCMD; however, their age at onset ranged from adolescence to adulthood. In addition, with the exception of cases 3 and 4 who are siblings, all the others are the only affected members of their families, suggesting that these cases are not typical NCMD, and that the disease may be inherited in an autosomal recessive manner rather than an autosomal dominant manner. There are two loci for NCMD, *MCDR1* and *MCDR3*, at 6q16.2 and 5p13.1-p15.33, respectively.^{10,11} *MCDR1* is caused by a tandem duplication of *PRDM13*¹² and the gene for *MCDR3* has yet to be identified. WES was performed to detect single nucleotide variants (SNVs) and CNVs. CNV and SNV analyses using WES data did not detect any significant change in genome-wide copy number (online supplemental figure 2), nor small nucleotide variations in *PRDM13* and genes at 5p13.1-p15.33. Unexpectedly, biallelic missense variants in *RDH12*

Table 1 Summary of clinical characteristics in examined participants with biallelic *RDH12* mutations

Subject	Age at exam (decades)	Sex	Presenting symptoms	Age at onset (years)	Initial BCVA R/L	Follow-up period; latest BCVA R/L	Autorefracton	Fundus findings	VF	ERG	Additional findings
Case 1	Fourth	F	Photophobia, nyctalopia	31	0.2/0.5	7.33 years; 0.2/0.5	▲ -0.25-2.25×174° ▲ -1.0-1.0×174°	Geographical macular atrophic scar with hyperpigmentation OU	Binasal scotoma OU	Normal	Family history unremarkable
Case 2	Third	F	Decreased BCVA	NA	0.8/0.8	9.5 years; 0.6/0.1	▲ -5.0-1.0×161° ▲ -5.0	Macular atrophy with small central island OU; peripheral RPE changes OU	Central scotoma OU	Normal	Family history unremarkable
Case 3	Fourth	F	Decreased BCVA	6	0.5/0.03	5 months; 0.4/0.08	▲ -1.5-2.0×162° ▲ -3.75-0.5×178°	Hyperpigmented chorioretinal atrophy with central island OU	Central scotoma with parapapillary island OU	Normal	Elder sister of case 4
Case 4	Fourth	M	Decreased BCVA	16	0.8/0.1	5 months; 0.8/0.1	▲ -3.0-0.5×165° ▲ -2.75-0.25×56°	Macular atrophy OU	Paracentral scotoma OU	Normal rod response; subnormal cone response	Younger brother of case 3
Case 5	Second	F	Decreased BCVA	5	0.2/0.3	1.25 years; 0.1/0.1	▲ -9.5-0.5×9° ▲ -8.5-0.25×179°	Central geographical macular atrophy with hyperpigmentation OU	Paracentral scotoma OD	Mild decreased rod and cone response	Family history unremarkable
Case 6	Sixth	F	Decreased BCVA	47	0.9/0.1	1 month; 0.9/0.1	▲ -4.75-0.25×2° ▲ -4.5-0.25×35°	Pigmented pseudocoloboma-like macular atrophy OU	Central scotoma OU	Subnormal rod and cone response	Family history unremarkable
Case 7	Second	F	Decreased BCVA, photophobia	11	0.1/0.1	4.5 years; 0.08/0.1	▲ -6.75-3.25×3° ▲ -6.25-4.5×162°	Variable degrees of pigmentation within the well-demarcated macular atrophy OU	Central scotoma OU	Subnormal cone response	Family history unremarkable

BCVA, best-corrected visual acuity; ERG, electroretinogram; F, female; L, left; M, male; NA, not available; OD, oculus dexter; OU, oculus uterque; R, right; RPE, retinal pigment epithelium; VF, visual field.

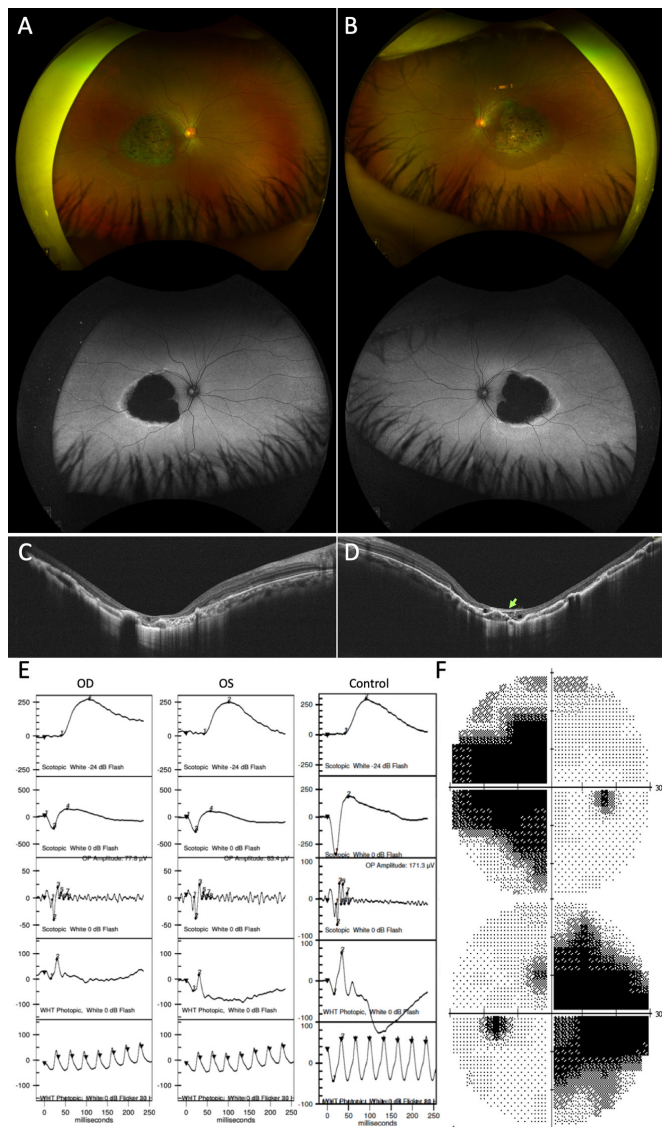


Figure 1 Colour fundus photography and fundus autofluorescence (A and B), optical coherence tomography of the right eye (C) and left eye (D). Full-field electroretinogram as compared with normal control (E) and visual field testing result (F) of case 2 demonstrates an example of pseudocoloboma-like maculopathy with biallelic *RDH12* missense mutation. Green arrow indicates the pseudocoloboma-like lesions and overlying epiretinal membrane.

were identified in the first three cases, and direct sequencing of the *RDH12* exons was performed in all later cases as shown in figure 3A and summarised in table 2. All amino acid alterations corresponding to these non-synonymous SNVs were evolutionarily conserved (figure 3B), suggesting that they may be pathogenic or likely pathogenic.

DISCUSSION

RDH12 is one of the critical enzymes in the visual cycle.¹³ Mutations in *RDH12* have been identified in LCA13,¹⁴ RP53^{15 16} and other retinal dystrophies.¹⁷ The clinical manifestations of patients diagnosed with *RDH12* retinopathy usually comprise of an early onset vision impairment after birth, or in early childhood, with progressive pigmentary retinopathy or maculopathy sparing the peripapillary area, atrophy of the RPE, yellowish deposits at the macula, and macular atrophy.^{5 18–20} Ultimately,

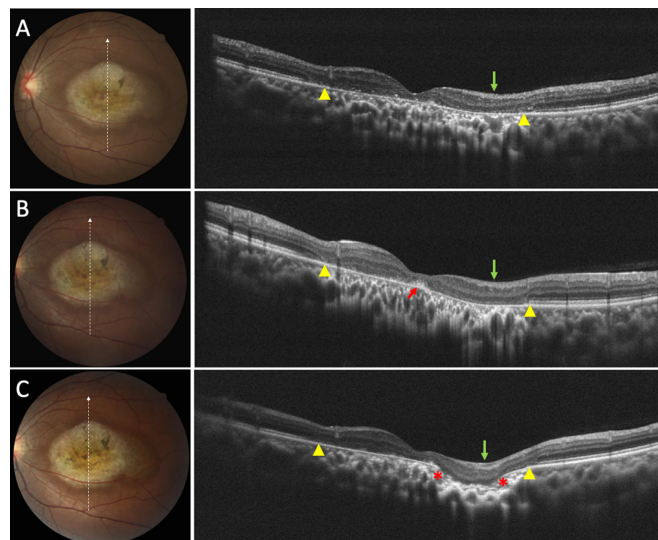


Figure 2 Serial vertical optical coherence tomography (OCT) scans reveal the development of a pseudocoloboma-like lesion in the left eye of case 7. (A) OCT scan in August 2017 showed thinning of the outer retina, atrophy of the retinal pigment epithelium (RPE) (between yellow arrowheads with increased OCT signal transmission of choroid) and intact Bruch’s membrane. Green arrows indicate area of retina with gradual posteriorly bowing. (B) In January 2019, slight bowing posteriorly in the superior juxtafoveal region was noticed (green arrow). Note a small clump of RPE hyperplasia underneath the centre of the fovea (red arrow). The atrophic RPE area slightly expanded compared with (A) (between yellow arrowheads) (C). In December 2019, there was a more depressive lesion (green arrow) extending into the atrophic choroidal tissue through the defective Bruch’s membrane (between red asterisks), resembling a pseudocolobomatous lesion. Note the formation of epiretinal membrane on the inner retina of the depressed area.

the patient may have severely impaired vision or even blindness in adulthood.

Recently, Zou *et al* reported that in a cohort of 92 patients with cone-rod dystrophy, 2.2% (2/92) of the patients were associated with *RDH12* mutations.⁵ However, the fundus manifestation of these two patients was different from that of other retinopathy associated with *RDH12* mutations in terms of a confined lesion to the macula and relatively preserved peripheral retina. Accordingly, the ERG revealed mild to severely impaired cone and rod responses.⁵ The most consistent clinical features of *RDH12* retinopathy include macular atrophy with or without retinal pigmentation. Based on the degree of retinal pigmentation, which ranges from mildly pigmented deposits to patchy pigment proliferation, the phenotypes of *RDH12* retinopathy are further classified into four types: type 1, macular coloboma with mid-peripheral pigmentation; type 2, macular retinal pigmentary atrophy with widespread peripheral pigmentation; type 3, heavy pigmentation extending from the posterior pole to the mid-periphery; and type 4, macular atrophy and relatively normal peripheral retina.⁵ Aside from the pseudocoloboma-like pattern in the posterior pole, our cases mostly resemble category type 4, with the presentation of macular atrophy sparing most of the peripheral retina.^{21 22}

Although the various clinical phenotypes of *RDH12* retinopathy have been described in the literature, few reports have focused on the manifestation of pseudocoloboma-like maculopathy.^{5 18 23} In contrast to our study participants, most of the previous cases with pseudocolobomatous lesions exhibited concomitant dense

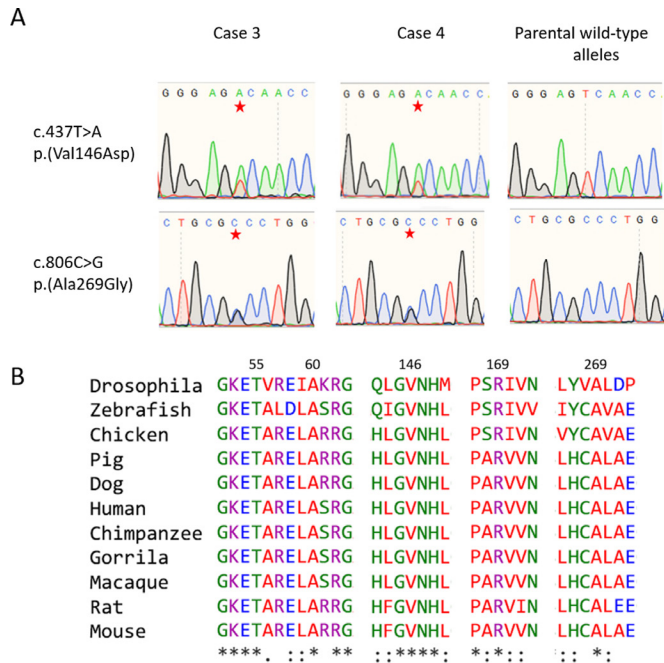


Figure 3 Sequence analysis and evolution conservation of variants found in *RDH12*. (A) Direct sequencing of exons 6 and 8 for c.437T>A (p.(Val146Asp)) and c.806C>G (p.(Ala269Gly)), respectively, in cases 3, 4. Stars indicate position of variants. Wild-type alleles from parents are shown as controls. (B) All five missense mutations in *RDH12* detected in pseudocoloboma-like macular atrophy are 100% conserved residues marked with asterisks (*) among 11 animal species from Drosophila to humans.

mid-peripheral retinal pigmentation, namely type 1 *RDH12* retinopathy based on Zou’s classification.⁵ As a result, more cases may be required to determine whether pseudocoloboma-like maculopathy sparing the peripheral retina is a developmental status within the spectrum between *RDH12* retinopathy types 1 and 4 or a new distinctive category. Moreover, the mechanism underlying the sole manifestation of macular involvement in *RDH12*-mutated subjects remains unclear.

The macula is a small yellowish area at the centre of the retina and is essential for detail and focused colour vision. Higher metabolic demand at the macula may explain why retinal pigment

epithelial cells are vulnerable to suboptimal *RDH12* activity in photoreceptors.²⁴ As *RDH12* mutations primarily affect photoreceptor function and retinal pigmentation probably originates from proliferating retinal pigment epithelial cells, an interesting point regarding the formation of colobomatous lesions remains unclear. According to a longitudinal follow-up of three Japanese patients with *RDH12*-related LCA, all developed posterior staphylomata and atrophic macula over the years.²⁵ Therefore, age may be a factor associated with the development of colobomatous lesions, as these lesions often present later in the disease course. This age-related hypothesis might be supported by our case 7, which demonstrated the development of a pseudocolobomatous lesion extending into the choroid in the left eye 2 years after the initial presentation. This pseudocoloboma-like lesion progressed from prior outer retinal atrophy (figure 2).

Online supplemental figure 3 shows fundus pictures from a girl with LCA with biallelic *RDH12* loss-of-function mutations, premature termination at codon 62, and a frameshift mutation at the exon 6–intron 6 boundary. In addition to the peripheral retinitis pigmentosa-like appearance, the macula had progressed from round-shaped homogenous diffuse RPE atrophy to a scalloped area of choroidal disruption over the past 5 years. Although genetic defects involving the visual cycle, such as Star-gardt’s disease, may develop from macular atrophy to Bruch’s membrane rupture and retinal herniation, choroidal tissue loss is limited.²⁶ The development of pseudocoloboma-like lesions at the macula may not be fully explained by the progression of RPE atrophy. At the genotype level, both *RDH12* mutations were predicted to encode a peptide chain less than the first 150 amino acids, that is, less than half the length of *RDH12*, suggesting that nonsense-mediated decay may result in degradation of the mutant mRNA and thus a nearly complete loss of *RDH12* activity. On the other hand, all other cases presenting with macular atrophy had missense mutations and may have variable amounts of residual enzyme activity, indicating that there is a strong correlation between the *RDH12* genotype and retinal phenotype severity and disease onset. It is worth mentioning that patients 1, 6, and 7 carried the same *RDH12* variants and their ages at onset were 31, 47 and 11, respectively. Their presenting visual acuities (right eye/ left eye) were also different: 0.2/0.5, 0.9/0.1, 0.1/0.1. Regardless of their age of onset, the onsets were mostly within the last decade, correlating to the availability of smart phones. Difference in age of onset was also noted in

Table 2 Compound heterozygous mutations in *RDH12* identified in patients affected with pseudocoloboma-like maculopathy

Case #	Nucleotide variants*	Amino acid change†	MAF‡	Clinical classification§	Reference
Case 1	c.505C>G c.806C>G	p.(Arg169Gly) p.(Ala269Gly)	0.000217 0.003592	LP, VUS LP	36 37
Case 2	c.505C>G c.806C>G	p.(Arg169Gly) p.(Ala269Gly)	0.000217 0.003592	LP, VUS LP	36 37
Cases 3 and 4	c.437T>A c.806C>G	p.(Val146Asp) p.(Ala269Gly)	0 0.003592	P, LP, VUS LP	37 38
Case 5	c.164C>T c.178G>A	p.(Thr55Met) p.(Ala60Thr)	0.000109 0.000109	LP P	17 39
Case 6	c.505C>G c.806C>G	p.(Arg169Gly) p.(Ala269Gly)	0.000217 0.003592	LP, VUS LP	36 37
Case 7	c.505C>G c.806C>G	p.(Arg169Gly) p.(Ala269Gly)	0.000217 0.003592	LP, VUS LP	36 37

*“NC_000014.9(NM_152443.3):” omitted in all variant nomenclature.

†“NM_152443.3(NP_689656.2):” omitted in all variant nomenclature.

‡Minor allele frequency from East Asian, gnomAD v.3.0⁴⁰

§LOVD v.3.0.³⁹

LOVD, Leiden Open Variation Database; LP, likely pathogenic; MAF, minor allele frequency; P, pathogenic; VUS, variant of unknown significance.

siblings, patients 3 and 4, being female and male, respectively. Such difference may suggest that biallelic *RDH12* mutations presenting pseudocoloboma-like maculopathy had phenotypical variance that may be modified by additional environmental, physiological or other genetic factors. Analyses with larger patient cohorts may provide additional evidence.

Additionally, retinoic acid metabolism is essential for the normal morphogenesis of the eye, and disruption of this process may lead to various ocular defects including coloboma.²⁷ For instance, aldehyde dehydrogenase family members are among the factors essential for eye development. In rodent models, knockout of *Aldh1* family members causes congenital eye deformities such as uveal coloboma and optic fissure closure problems, while in humans, biallelic mutations in *ALDH1A3* cause microphthalmia and anophthalmia.^{28,29} An animal model of *aldh7a1*-knockdown zebrafish also showed that such genetic alteration can lead to the reduction of cell proliferation in the optic cup and disrupt the fusion process of the optic fissure.³⁰ Nevertheless, a single genetic mutation in *RDH12* may not sufficiently explain the formation of acquired pseudocoloboma-like lesions so far, and future studies are needed to elucidate the underlying mechanism.

In addition to *RDH12*, pseudocoloboma with early onset has been reported in patients with mutations in *IDH3A* (isocitrate dehydrogenase (NAD⁺) 3 catalytic subunit alpha, RP90),³¹ *PAX6*,³² or *NMNAT1* (nicotinamide nucleotide adenylyltransferase 1, LCA9).³³ *PAX6* is well known for its role in ocular development and defects are usually inherited in an autosomal dominant manner, while the other three are enzymes and mutations resulting in retinal diseases segregated in an autosomal recessive manner. Although located in different subcellular compartments, mitochondria for *IDH3A*, cytosol for *RDH12* and nucleus for *NMNAT1*, all of these enzymes are involved in oxidation-reduction reactions. *NMAT1* catalyses the formation of NAD⁺ (nicotinamide adenine dinucleotide) from adenosine triphosphate and nicotinamide mononucleotide,³⁴ *IDH3A* uses NAD⁺ as the electron acceptor for the oxidative decarboxylation of isocitrate to 2-oxoglutarate, and *RDH12* catalyses the reduction of all-trans-retinal to all-trans-retinol using NADP⁺, the oxidized form of NADPH, as the electron acceptor,^{13,35} suggesting that ineffective metabolism of highly reactive oxidative molecules may lead to the development of a pseudocoloboma-like phenotype.

In our study, we identified several frequently occurring mutations. The most frequent allele in the current report was p.Ala269Gly, followed by p.Arg169Gly, p.Val146Asp, p.Thr55Met and p.Ala60Thr. Notably, the p.Ala269Gly mutation has been rarely reported in the literature associated with retinopathy. The most common *RDH12* mutation in another Chinese population was reported to be p.Val146Asp.⁵ In an Indian population, the most commonly found mutation was p.Cys201Arg; whereas the most frequent mutation was p.Ala269AlafsX1 in a group of British Caucasian participants.²⁰

Only one dominant mutation of *RDH12* was identified in a large family affected with RP53.¹⁵ This mutation, NC_000014.9(NM_152443.3): c.776del, is a single-nucleotide deletion at codon 259 resulting in a frameshift and premature termination after an extra 17 amino acids. The dominant inheritance of RP53 suggests that there may be an important functional role in the last 57 amino acids of *RDH12*, and that the mutant *RDH12* may interfere with the function of normal *RDH12* in the cells of these patients, that is, in a dominant-negative manner, and resemble the loss of both alleles of *RDH12*.

In conclusion, we present seven cases from six families of *RDH12*-associated pseudocoloboma-like macular atrophy with variable disease onset, relatively normal ERG, and moderately impaired vision. All of these cases are compound heterozygotes for missense mutations in *RDH12*, in contrast to the nearly complete loss-of-function mutations in LCA and truncated *RDH12* in adRP.¹⁵

Acknowledgements The authors thank all the patients and their family members for participation. The authors also thank the Genomics Center for Clinical and Biotechnological Applications supported by the National Core Facility for Biopharmaceuticals, Taiwan (MOST 110-2740-B-A49A-501) for DNA sequencing.

Contributors Project design: S-JC, M-YC; Manuscript writing: S-JC, C-YK, M-YC; Patient recruitment and phenotyping: S-JC, C-YK; Genetic sequencing and interpretation: M-YC. Guarantor: S-JC.

Funding Grant supports from Ministry of Science and Technology (MOST) (MOST107-2314-B-010-042, MOST109-2314-B-010-013) and from Taipei Veterans General Hospital (V110C-020, V111C-127) to M-YC.

Competing interests None declared.

Patient consent for publication Not applicable.

Ethics approval This study involves human participants and was approved by the Institutional Review Board of Taipei Veterans General Hospital (#2014-11-006B, #2021-02-021B) and conducted in accordance with the Declaration of Helsinki. Participants gave informed consent to participate in the study before taking part.

Provenance and peer review Not commissioned; externally peer reviewed.

Data availability statement All data relevant to the study are included in the article or uploaded as supplementary information.

Supplemental material This content has been supplied by the author(s). It has not been vetted by BMJ Publishing Group Limited (BMJ) and may not have been peer-reviewed. Any opinions or recommendations discussed are solely those of the author(s) and are not endorsed by BMJ. BMJ disclaims all liability and responsibility arising from any reliance placed on the content. Where the content includes any translated material, BMJ does not warrant the accuracy and reliability of the translations (including but not limited to local regulations, clinical guidelines, terminology, drug names and drug dosages), and is not responsible for any error and/or omissions arising from translation and adaptation or otherwise.

Open access This is an open access article distributed in accordance with the Creative Commons Attribution Non Commercial (CC BY-NC 4.0) license, which permits others to distribute, remix, adapt, build upon this work non-commercially, and license their derivative works on different terms, provided the original work is properly cited, appropriate credit is given, any changes made indicated, and the use is non-commercial. See: <http://creativecommons.org/licenses/by-nc/4.0/>.

ORCID iD

Ming-Yi Chung <http://orcid.org/0000-0003-2198-6860>

REFERENCES

- Sahel J-A, Marazova K, Audo I. Clinical characteristics and current therapies for inherited retinal degenerations. *Cold Spring Harb Perspect Med* 2015;5:a017111.
- Parker RO, Crouch RK. Retinol dehydrogenases (RDHs) in the visual cycle. *Exp Eye Res* 2010;91:788–92.
- Maeda A, Maeda T, Imanishi Y, Sun W, Jastrzebska B, Hatala DA, Winkens HJ, Hofmann KP, Janssen JJ, Baehr W, Driessen CA, Palczewski K. Retinol dehydrogenase (RDH12) protects photoreceptors from light-induced degeneration in mice. *J Biol Chem* 2006;281:37697–704.
- Stockton DW, Lewis RA, Abboud EB, Al-Rajhi A, Jabak M, Anderson KL, Lupski JR. A novel locus for Leber congenital amaurosis on chromosome 14q24. *Hum Genet* 1998;103:328–33.
- Zou X, Fu Q, Fang S, Li H, Ge Z, Yang L, Xu M, Sun Z, Li H, Li Y, Dong F, Chen R, Sui R. Phenotypic variability of recessive RDH12-ASSOCIATED retinal dystrophy. *Retina* 2019;39:2040–52.
- Li H. Aligning sequence reads, clone sequences and assembly contigs with BWA-MEM. *arXivorg* 2013.
- Talevich E, Shain AH, Botton T, Bastian BC. CNVkit: genome-wide copy number detection and visualization from targeted DNA sequencing. *PLoS Comput Biol* 2016;12:e1004873.
- Gordon D. Viewing and editing assembled sequences using Consed. *Curr Protoc Bioinformatics* 2003;Chapter 11:Unit 11.2.
- Montgomery KT, Iartchouck O, Li L, Loomis S, Obourn V, Kucherlapati R. PolyPhred analysis software for mutation detection from fluorescence-based sequence data. *Curr Protoc Hum Genet* 2008;Chapter 7:Unit 7.16.

- 10 Michaelides M, Johnson S, Tekriwal AK, Holder GE, Bellmann C, Kinning E, Woodruff G, Trembath RC, Hunt DM, Moore AT. An early-onset autosomal dominant macular dystrophy (MCDR3) resembling North Carolina macular dystrophy maps to chromosome 5. *Invest Ophthalmol Vis Sci* 2003;44:2178–83.
- 11 Sauer CG, Schworm HD, Ulbig M, Blankenagel A, Rohrschneider K, Pauleikhoff D, Grimm T, Weber BH. An ancestral core haplotype defines the critical region harbouring the North Carolina macular dystrophy gene (MCDR1). *J Med Genet* 1997;34:961–6.
- 12 Bowne SJ, Sullivan LS, Wheaton DK, Locke KG, Jones KD, Koboldt DC, Fulton RS, Wilson RK, Blanton SH, Birch DG, Daiger SP. North Carolina macular dystrophy (MCDR1) caused by a novel tandem duplication of the *PRDM13* gene. *Mol Vis* 2016;22:1239–47.
- 13 Haeseleer F, Jang G-F, Imanishi Y, Driessen CAGG, Matsumura M, Nelson PS, Palczewski K. Dual-Substrate specificity short chain retinol dehydrogenases from the vertebrate retina. *J Biol Chem* 2002;277:45537–46.
- 14 Janecke AR, Thompson DA, Utermann G, Becker C, Hübner CA, Schmid E, McHenry CL, Nair AR, Rüschemeyer F, Heckenlively J, Wissinger B, Nürnberg P, Gal A. Mutations in *RDH12* encoding a photoreceptor cell retinol dehydrogenase cause childhood-onset severe retinal dystrophy. *Nat Genet* 2004;36:850–4.
- 15 Fingert JH, Oh K, Chung M, Scheetz TE, Andorf JL, Johnson RM, Sheffield VC, Stone EM. Association of a novel mutation in the retinol dehydrogenase 12 (*RDH12*) gene with autosomal dominant retinitis pigmentosa. *Arch Ophthalmol* 2008;126:1301–7.
- 16 Benayoun L, Spiegel R, Auslender N, Abbasi AH, Rizel L, Hujeirat Y, Salama I, Garzoni HJ, Allon-Shalev S, Ben-Yosef T. Genetic heterogeneity in two consanguineous families segregating early onset retinal degeneration: the pitfalls of homozygosity mapping. *Am J Med Genet A* 2009;149A:650–6.
- 17 Thompson DA, Janecke AR, Lange J, Feathers KL, Hübner CA, McHenry CL, Stockton DW, Rammesmayr G, Lupski JR, Antinolo G, Ayuso C, Baiget M, Gouras P, Heckenlively JR, den Hollander A, Jacobson SG, Lewis RA, Sieving PA, Wissinger B, Yzer S, Zrenner E, Utermann G, Gal A. Retinal degeneration associated with *RDH12* mutations results from decreased 11-*cis* retinal synthesis due to disruption of the visual cycle. *Hum Mol Genet* 2005;14:3865–75.
- 18 Aleman TS, Uyhazi KE, Serrano LW, Vasireddy V, Bowman SJ, Ammar MJ, Pearson DJ, Maguire AM, Bennett J. *RDH12* Mutations Cause a Severe Retinal Degeneration With Relatively Sparing Rod Function. *Invest Ophthalmol Vis Sci* 2018;59:5225–36.
- 19 Garg A, Lee W, Sengillo JD, Allikmets R, Garg K, Tsang SH. Peripapillary sparing in *RDH12*-associated Leber congenital amaurosis. *Ophthalmic Genet* 2017;38:575–9.
- 20 Mackay DS, Dev Borman A, Moradi P, Henderson RH, Li Z, Wright GA, Waseem N, Gandra M, Thompson DA, Bhattacharya SS, Holder GE, Webster AR, Moore AT. *Rdh12* retinopathy: novel mutations and phenotypic description. *Mol Vis* 2011;17:2706–16.
- 21 Wang J, Wang Y, Li S, Xiao X, Yi Z, Jiang Y, Li X, Jia X, Wang P, Jin C, Sun W, Zhang Q. Clinical and genetic analysis of *RDH12*-Associated retinopathy in 27 Chinese families: a hypomorphic allele leads to cone-rod dystrophy. *Invest Ophthalmol Vis Sci* 2022;63.
- 22 Zhu L, Ouyang W, Zhang M, Wang H, Li S, Meng X, Yin ZQ. Molecular genetics with clinical characteristics of Leber congenital amaurosis in the Han population of Western China. *Ophthalmic Genet* 2021;42:392–401.
- 23 Sun W, Gerth C, Maeda A, Lodowski DT, Van Der Kraak L, Saperstein DA, Héon E, Palczewski K. Novel *RDH12* mutations associated with Leber congenital amaurosis and cone-rod dystrophy: biochemical and clinical evaluations. *Vision Res* 2007;47:2055–66.
- 24 Sarkar H, Toms M, Moosajee M. Involvement of oxidative and endoplasmic reticulum stress in *RDH12*-Related retinopathies. *Int J Mol Sci* 2021;22:8863.
- 25 Kuniyoshi K, Sakuramoto H, Yoshitake K, Abe K, Ikeo K, Furuno M, Tsunoda K, Kusaka S, Shimomura Y, Iwata T. Longitudinal clinical course of three Japanese patients with Leber congenital amaurosis/early-onset retinal dystrophy with *RDH12* mutation. *Doc Ophthalmol* 2014;128:219–28.
- 26 Park SP, Chang S, Allikmets R, Smith RT, Burke TR, Gregory-Roberts E, Tsang SH. Disruption in Bruch membrane in patients with Stargardt disease. *Ophthalmic Genet* 2012;33:49–52.
- 27 Duester G. Keeping an eye on retinoic acid signaling during eye development. *Chem Biol Interact* 2009;178:178–81.
- 28 Matt N, Dupé V, Garnier J-M, Dennefeld C, Chambon P, Mark M, Ghyselinck NB. Retinoic acid-dependent eye morphogenesis is orchestrated by neural crest cells. *Development* 2005;132:4789–800.
- 29 Fares-Taie L, Gerber S, Chassaing N, Clayton-Smith J, Hanein S, Silva E, Serey M, Serre V, Gérard X, Baumann C, Plessis G, Demeer B, Brétillon L, Bole C, Nitschke P, Munnich A, Lyonnet S, Calvas P, Kaplan J, Ragge N, Rozet J-M. *ALDH1A3* mutations cause recessive anophthalmia and microphthalmia. *Am J Hum Genet* 2013;92:265–70.
- 30 Babcock HE, Dutta S, Alur RP, Brocker C, Vasilou V, Vitale S, Abu-Asab M, Brooks BP. *Aldh7A1* regulates eye and limb development in zebrafish. *PLoS One* 2014;9:e101782.
- 31 Pierrache LHM, Kimchi A, Ratnapriya R, Roberts L, Astuti GDN, Obolensky A, Beryozkin A, Tjon-Fo-Sang MJH, Schuil J, Klaver CCW, Bongers EMHF, Haer-Wigman L, Schlij N, Breuning MH, Fischer GM, Banin E, Ramaswarao RS, Swaroop A, van den Born LI, Sharon D, Cremers FPM. Whole-Exome sequencing identifies biallelic *IDH3A* variants as a cause of retinitis pigmentosa accompanied by Pseudocoloboma. *Ophthalmology* 2017;124:992–1003.
- 32 Morrison D, FitzPatrick D, Hanson I, Williamson K, van Heyningen V, Fleck B, Jones I, Chalmers J, Campbell H. National study of microphthalmia, anophthalmia, and coloboma (MAC) in Scotland: investigation of genetic aetiology. *J Med Genet* 2002;39:16–22.
- 33 Perrault I, Hanein S, Zanlonghi X, Serre V, Nicouleanu M, Defoort-Delhemmes S, Delphin N, Fares-Taie L, Gerber S, Xerri O, Edelson C, Goldenberg A, Duncombe A, Le Meur G, Hamel C, Silva E, Nitschke P, Calvas P, Munnich A, Roche O, Dollfus H, Kaplan J, Rozet J-M. Mutations in *NMNAT1* cause Leber congenital amaurosis with early-onset severe macular and optic atrophy. *Nat Genet* 2012;44:975–7.
- 34 Emanuelli M, Carnevali F, Saccucci F, Pierella F, Amici A, Raffaelli N, Magni G. Molecular cloning, chromosomal localization, tissue mRNA levels, bacterial expression, and enzymatic properties of human *NMN* adenylyltransferase. *J Biol Chem* 2001;276:406–12.
- 35 Belyaeva OV, Korkina OV, Stetsenko AV, Kim T, Nelson PS, Kedishvili NY. Biochemical properties of purified human retinol dehydrogenase 12 (*RDH12*): catalytic efficiency toward retinoids and C9 aldehydes and effects of cellular retinol-binding protein type I (*CRBPI*) and cellular retinaldehyde-binding protein (*CRALBP*) on the oxidation and reduction of retinoids. *Biochemistry* 2005;44:7035–47.
- 36 Wang H, Wang X, Zou X, Xu S, Li H, Soens ZT, Wang K, Li Y, Dong F, Chen R, Sui R. Comprehensive molecular diagnosis of a large Chinese Leber congenital amaurosis cohort. *Invest Ophthalmol Vis Sci* 2015;56:3642–55.
- 37 Huang L, Xiao X, Li S, Jia X, Wang P, Sun W, Xu Y, Xin W, Guo X, Zhang Q. Molecular genetics of cone-rod dystrophy in Chinese patients: new data from 61 probands and mutation overview of 163 probands. *Exp Eye Res* 2016;146:252–8.
- 38 Gong B, Wei B, Huang L, Hao J, Li X, Yang Y, Zhou Y, Hao F, Cui Z, Zhang D, Wang L, Zhang H. Exome Sequencing Identified a Recessive *RDH12* Mutation in a Family with Severe Early-Onset Retinitis Pigmentosa. *J Ophthalmol* 2015;2015:1–7.
- 39 Fokkema IFAC, Kroon M, López Hernández JA, Asscheman D, Lugtenburg I, Hoogenboom J, den Dunnen JT. The LOVD3 platform: efficient genome-wide sharing of genetic variants. *Eur J Hum Genet* 2021;29:1796–803.
- 40 Karczewski KJ, Francioli LC, Tiao G, Cummings BB, Alföldi J, Wang Q, Collins RL, Laricchia KM, Ganna A, Birnbaum DP, Gauthier LD, Brand H, Solomonson M, Watts NA, Rhodes D, Singer-Berk M, England EM, Seaby EG, Kosmicki JA, Walters RK, Tashman K, Farjoun Y, Banks E, Poterba T, Wang A, Seed C, Whiffin N, Chong JX, Samocha KE, Pierce-Hoffman E, Zappala Z, O'Donnell-Luria AH, Minikel EV, Weisburd B, Lek M, Ware JS, Vittal C, Armean IM, Bergelson L, Cibulskis K, Connolly KM, Covarrubias M, Donnelly S, Ferreira S, Gabriel S, Gentry J, Gupta N, Jeandet T, Kaplan D, Llanwarne C, Munshi R, Novod S, Petrillo N, Roazen D, Ruano-Rubio V, Saltzman A, Schleicher M, Soto J, Tibbetts K, Tolonen C, Wade G, Talkowski ME, Neale BM, Daly MJ, MacArthur DG. Genome Aggregation Database Consortium. The mutational constraint spectrum quantified from variation in 141,456 humans. *Nature* 2020;581:434–43.