

Chlamydia trachomatis infection of the Fallopian tubes

Histological findings in two patients

B. R. MØLLER, L. WESTRÖM, S. AHRONS, K. T. RIPA, L. SVENSSON,
C. VON MECKLENBURG, H. HENRIKSON, AND P.-A. MÅRDH

From the Institute of Medical Microbiology, University of Aarhus; the Surgical University Clinic, Aarhus Amtssygehus, Denmark; the Institute of Medical Microbiology, the Department of Zoology, University of Lund, the Department of Gynaecology and Obstetrics, and the Department of Pathology, University Hospital, Lund, Sweden

SUMMARY In two patients with acute salpingitis, *C. trachomatis* was isolated from the cervix. In one of the patients, the organism was also recovered from the Fallopian tubes, and in the other, chlamydial inclusions were found in Giemsa-stained tubal epithelial cells. A significant change in micro-immunofluorescence antibodies to *C. trachomatis* occurred in both patients during the course of the disease. The Fallopian tubes of both patients were removed and studied by conventional histological techniques and, in the case of one of them, by transmission electron microscopy.

Introduction

Chlamydia trachomatis is a common cause of sexually transmitted genital infections (Schachter, 1978). It can be recovered from the cervix of about one third of women with signs of cervicitis but from only a small percentage of healthy women (Hilton *et al.*, 1974; Oriol *et al.*, 1978; Ripa *et al.*, 1978).

In patients with laparoscopically verified acute salpingitis, *C. trachomatis* has been isolated from the cervix in 19 of 53 cases and from six of 20 tubal specimens from these patients (Mårdh *et al.*, 1977). Evidence of chlamydial infection in women with acute salpingitis has also been demonstrated by serological means (Treharne *et al.*, 1979).

In non-human primates experimental salpingitis with *C. trachomatis* has been reported (Ripa *et al.*, 1979).

In the present study two patients with acute salpingitis with evidence of tubal infection with *C. trachomatis* are reported. In both patients the tubes were removed and studied by histological techniques, and, in one of them, by transmission electron microscopy.

Patients and methods

SAMPLING TECHNIQUES

Specimens for the isolation of *C. trachomatis*, mycoplasmas, and ureaplasmas were obtained by rotating a sterile, cotton-tipped swab in the cervical canal and in the lumen of the uterine tubes. Specimens for isolation of gonococci were taken from the cervix, the urethra, and from the rectum with a cotton-tipped swab treated with charcoal.

TRANSPORT MEDIA

Specimens for the isolation of chlamydia were transported and stored at -20°C in a sucrose-phosphate buffer supplemented with $50\ \mu\text{g}$ gentamicin and $2.5\ \mu\text{g}$ amphotericin B per ml (Gordon *et al.*, 1969). The specimens for the isolation of mycoplasmas were transported in liquid B medium (Freundt *et al.*, 1979), and those for ureaplasmas in liquid S medium (Freundt *et al.*, 1979). The *Neisseria gonorrhoeae* specimens were delivered to the laboratory in a modified Stuart's medium (Gästrin *et al.*, 1968).

ISOLATION PROCEDURES

C. trachomatis was cultured using cycloheximide-treated McCoy cells (Ripa and Mårdh, 1977). The culture techniques for mycoplasmas, ureaplasmas (Freundt *et al.*, 1979) and *N. gonorrhoeae* (Mårdh

Address for reprints: Dr B. Møller, Institute of Medical Microbiology, Bartholin Building, University of Aarhus, DK-8000 Aarhus C, Denmark

Received for publication 27 April 1979

and Weström, 1970) have been described in detail elsewhere.

SEROLOGICAL STUDIES

Serum antibodies to *C. trachomatis* were studied using a micro-immunofluorescence test (Treharne *et al.*, 1977). Fluorescein isothiocyanate conjugated rabbit anti-human anti-IgG and anti-IgM globulins (Dakopatt A/S, Copenhagen, Denmark) were used. The sera were titrated in two-fold dilutions; the lowest dilution used was 1/8.

Determination of antibodies to mycoplasmas and ureaplasmas was performed using an indirect haemagglutination test according to the method of Krogsgaard-Jensen (1971). Gonococcal anti-pilar antibodies were determined by an indirect haemagglutination test (Reiman and Lind, 1977).

HISTOLOGICAL TECHNIQUES

The tissue specimens were fixed in 10% formalin and processed by routine histological methods, including staining with haematoxylin and eosin, and with Giemsa.

TRANSMISSION ELECTRON MICROSCOPY

The specimens were fixed in 2.5% glutaraldehyde in

0.2 mmol/l cacodylate buffer, pH 7.4, for two hours. After repeated rinsing in the buffer, the specimens were refixed in 2% osmium tetroxide using the same buffer, dehydrated in ethanol and embedded in Vestopal W. Sections, 1 µm thick, and were examined by phase contrast microscopy. Ultrathin sections were then cut on an LKA-Ultrathome, contrasted with lead citrate and uranyl acetate, and viewed in a Zeiss EM 10 electron microscope.

CASE REPORTS

Case 1

A 27-year-old white African woman (gravida 4, para 2, legal abortion 1) was referred for legal abortion in the tenth week of pregnancy. On bimanual palpation the uterus was enlarged, corresponding to the tenth week of pregnancy. No sign of genital infection was detected. Erythrocyte sedimentation rate (ESR) was 2 mm/h and white blood cell count (WBC) $11.0 \times 10^9/l$ with a normal differential count.

On 10 April 1978, legal abortion was performed by dilatation and suction curettage under general anaesthesia as an outpatient. No immediate complications were noted.

Two weeks later the patient was readmitted with low abdominal pain of three to four days' duration. General examination was normal. A moderate amount of brownish discharge was found in the vagina. The uterus was of

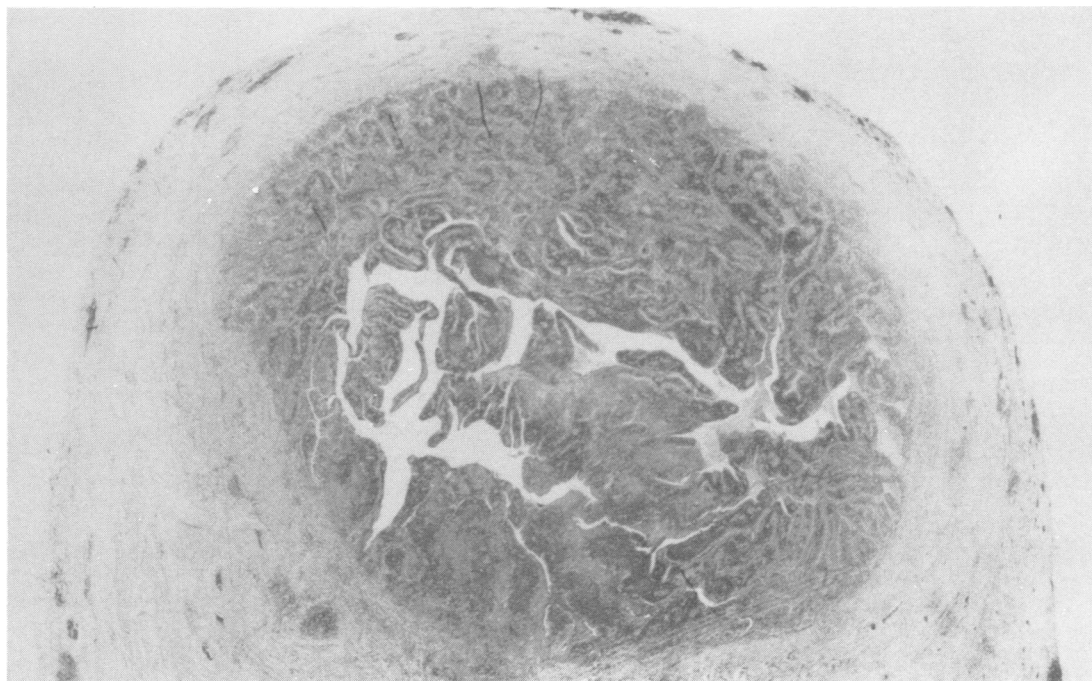


Fig. 1 Cross-section of Fallopian tube showing oedema and an intense infiltration of the epithelium, the subepithelial connective tissue, the muscular layer, and extending into the subserous layer (Case 1). Stained with hematoxylin and eosin, $\times 40$.

normal size and no adnexal masses were palpated. The pelvic examination caused moderate pain. Rectal temperature was 37.5°C, ESR 28 mm/h, and WBC $14.0 \times 10^9/l$. A clinical diagnosis of salpingitis was made, and the patient was treated in hospital with penicillin 10^6 IU and streptomycin 500 mg twice daily for six days.

During the following three weeks the rectal temperature fluctuated between 37.5°C and 38.5°C. ESR increased to 64 mm/h. On repeated pelvic examinations increasing tenderness was noted and, therefore, 26 days after admission a laparotomy was performed. At operation both Fallopian tubes were swollen, about 5 cm in diameter. A purulent exudate poured from the mouth of the oviduct. On the right side there was a tubo-ovarian abscess while the left ovary was normal. Bilateral salpingectomy was performed. Ampicillin 2 g and metronidazole 1.2 g a day were given daily for six days postoperatively. The postoperative course was uneventful and the patient was discharged eight days after the operation.

Histological examination of the tubal specimens showed a marked inflammatory infiltrate through all the layers of the uterine tubes (Fig. 1). The lumina were filled with an exudate containing lymphocytes and desquamated epithelial cells. The epithelium, which was injured in some areas, was oedematous and infiltrated with inflammatory cells (Fig. 2). The muscle layers were infiltrated with

numerous lymphocytes and some polymorphonuclear leucocytes. The cellular infiltration extended into the subserous layer.

Giemsa-stained specimens examined by darkfield illumination showed intracytoplasmic inclusions in surface epithelial cells. The appearance of these inclusions was consistent with those found in *C. trachomatis* infected cells.

Cultures for gonococci and mycoplasmas from the tubes and cervix gave negative results. *U. urealyticum* was isolated from the cervix but not from the uterine tubes. *C. trachomatis* was recovered from the cervix the day before legal abortion was performed. At laparotomy five weeks later we failed to isolate *C. trachomatis* from the tubes. No chlamydial IgM or IgG antibodies were detected in serum samples taken the day before the therapeutic abortion. On day 41 after the abortion, the IgM micro-immunofluorescence antibody titre was 1/128 and that of IgG 1/32. Two months later the IgG titre was 1/128 while no IgM antibodies could be determined.

No IHA antibodies to mycoplasmas and ureaplasmas and no anti-pilar antibodies to gonococci were found before the abortion nor during the follow-up period.

Case 2

A 31-year-old Caucasian woman of Polish origin (gravida

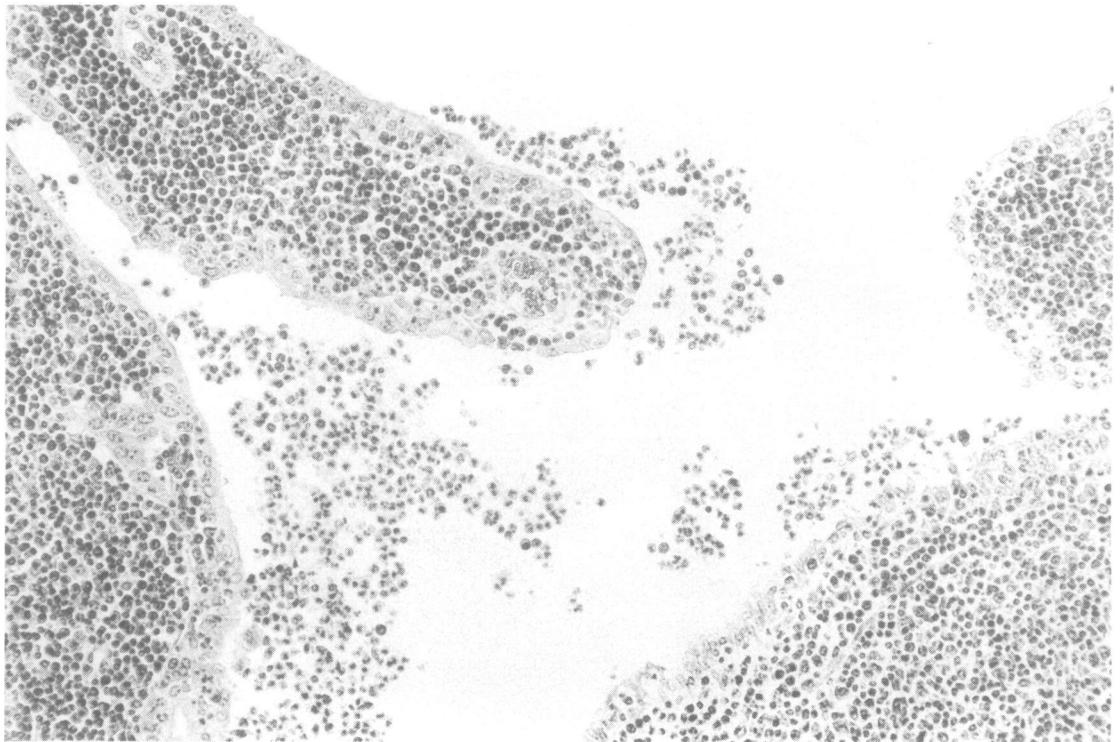


Fig. 2 Section of Fallopian tube showing the epithelium and the subepithelial tissue infiltrated with inflammatory cells. The epithelium is injured in some areas. The lumen contains inflammatory cells and desquamated epithelial cells (Case 1). Stained with hematoxylin and eosin, $\times 200$.

6, para 2, legal abortion 4) applied for legal sterilisation in January 1978 and was admitted on 20 April for the operation. After menstruating she had observed a yellowish discharge. Three days before admission she developed low abdominal pain. On admission her rectal temperature was 37.6°C, and ESR 40 mm/h. Vaginal examination showed a small amount of yellowish discharge with an equal number of vaginal epithelial cells and leucocytes in the wet smear. The uterus was of normal size but there were bilateral masses about 5 cm in diameter. The patient experienced moderate pain on pelvic examination.

A preoperative diagnosis of bilateral tubo-ovarian abscesses was made and, because the patient had applied for sterilisation, laparotomy was performed 26 hours after admission. No antibiotic treatment had been given before laparotomy.

At operation both Fallopian tubes were swollen, about 5 cm in diameter, with pus in the mouth of the oviduct. The tubal wall was about 5-10 mm thick. The ovaries were partly covered with a purulent discharge but no peritonitis was present. A bilateral salpingectomy was performed and doxycycline 200 mg was administered intravenously during the first 24 hours followed by 100 mg by mouth daily.

The postoperative course was uneventful and the patient left hospital on the sixth day after operation.

Histological examination of the tubes showed marked inflammatory changes through all layers of the tubes. The mucosal lining was very oedematous with inflammatory cells in the submucous and muscular layers to the serous lining. The lumen of the tube was full of leucocytes (Fig. 3).

By transmission electron microscopy a specimen from the epithelium of the Fallopian tubes was from one to several cells thick. There were ciliated and non-ciliated cells, both of which had surface microvilli and goblet cells at different stages of maturity lying interspersed among the ciliated cells and containing numerous vesicles filled with mucus. The cytoplasm of the goblet cells contained a granular endoplasmic reticulum. The nucleus of the ciliated and the non-ciliated cells varied in shape from round to oval or were greatly elongated. The nuclear membrane was often indented; the cytoplasm of these cells contained mainly agranular endoplasmic reticulum. The mitochondria, mainly oblong in form, were sometimes situated in the apical part of the cell. There were also lysosomes of different size both in the ciliated and non-ciliated cells. The apical part of these cells often protruded into the lumen (Fig. 4).

Cultures for gonococci gave a negative result. *C. trachomatis* was isolated from the cervix and the Fallopian tubes. Sera collected on day 21 postoperatively contained

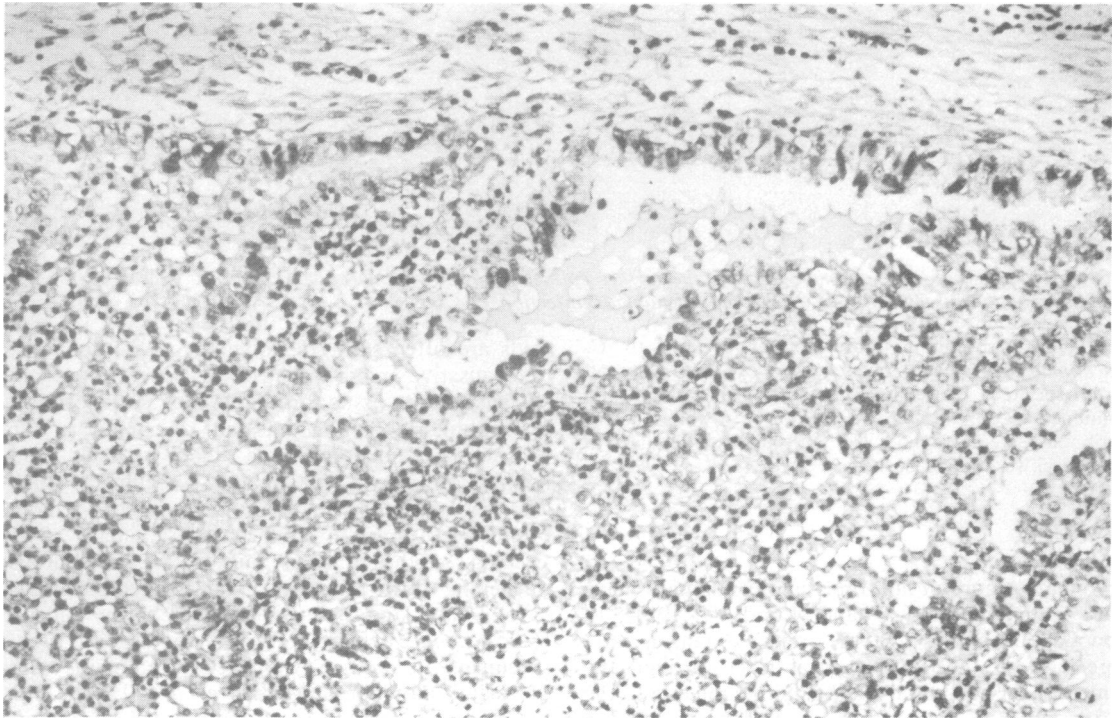


Fig. 3 Section of Fallopian tube. Marked inflammatory changes are evident throughout all the layers of the tube. The lumen contains leucocytes. The epithelium is oedematous and injured in some areas. Marked oedema with inflammatory cells in the submucous and muscular layers can be seen (Case 2). Stained with hematoxylin and eosin, $\times 200$.

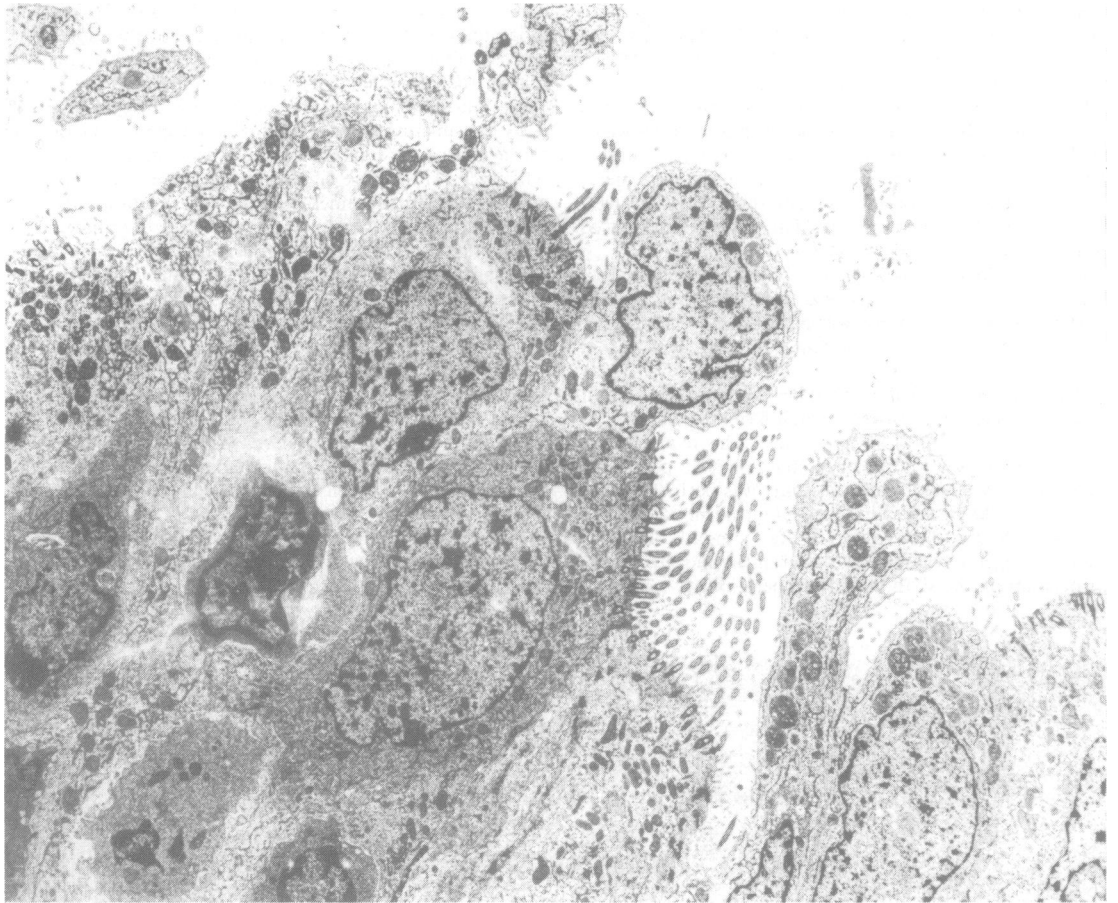


Fig. 4 Transmission electron micrograph of the surface epithelium of a Fallopian tube of a patient (Case 2) with acute salpingitis with evidence of *Chlamydia trachomatis* infection, $\times 4700$.

no IgM micro-immunofluorescence antibodies to *C. trachomatis* but IgG antibodies at a titre of 1/128. A second serum specimen was collected after a further month and contained IgG antibodies at a titre of 1/16 while no IgM antibodies were found. No anti-pilar antibodies to gonococci were found in the sera tested.

Discussion

Two main groups of non-tuberculous salpingitis have been recognised (Novak and Woodruff, 1974). In gonococcal salpingitis, the micro-organisms are spread from the lower genital tract through the lumen of cervical canal via the uterine mucosa to the tubes, which become red and swollen and contain a purulent exudate. Microscopically, the epithelium and the subepithelial tissue show an intense inflammation. In some areas the luminal surface epithelium is destroyed. Adhesion of the mucosal

folds are often seen. In nongonococcal salpingitis, the causative micro-organism is believed to gain entrance to the tissue through lesions in the cervical or endometrial epithelium and to spread to the parametria and tubes via blood vessels and lymphatics. The inflammatory swelling, which affects both the parametria and the tubes, is more pronounced than in gonococcal salpingitis. The swelling of the tubes is due to an oedematous thickening of the tubal wall. The tubal epithelium is usually intact and there is no exudate in the lumen.

Gonococci are seldom isolated from tubal specimens in women with acute salpingitis and cervical gonorrhoea (Mårdh *et al.*, 1978). The prognosis for fertility in antibiotic-treated cases of salpingitis with gonorrhoea is significantly better than in cases of salpingitis in which gonococci cannot be recovered (Weström and Mårdh, 1977). During the 1970s, the annual number of cases of

salpingitis with gonorrhoea in our hospital catchment region has been declining, even though the total number of such cases of acute salpingitis has increased during the same period (Weström and Mårdh, 1977). There is evidence that salpingitis caused by *C. trachomatis* is now more common in our area than that due to gonorrhoea (Mårdh *et al.*, 1977).

Experimental *C. trachomatis* salpingitis in grivet monkeys causes histological changes in the tubes which are similar to those of gonococcal salpingitis in man (Ripa *et al.*, 1979). *Mycoplasma hominis* produces changes which are similar to those in patients with nongonococcal salpingitis (Weström and Mårdh, 1977).

In Case 1, *C. trachomatis* was isolated from the cervix before abortion, at which time no antibodies to the micro-organism were detected. Two weeks after this operation, the patient was admitted to hospital with signs of acute salpingitis. She was treated with penicillin and streptomycin, which had no effect on the clinical course. Laparotomy was performed and both tubes were found to be swollen. Bilateral salpingectomy was performed. The histological changes in the tubes were the same as those described in textbooks for gonococcal salpingitis. Immunofluorescent studies showed intracytoplasmic chlamydial inclusions in some of the cells. IgM and IgG micro-immunofluorescence antibody titres to *C. trachomatis* were significantly raised.

Gonococci, mycoplasmas, and ureaplasmas could not be recovered from the tubes. The patient did not develop antibodies to any of these micro-organisms during the course of the disease. As in Case 1, therapeutic abortion may enable *C. trachomatis* to spread by way of the cervical canal to the tubes.

The other patient was admitted three days after the start of low abdominal pain. No diagnostic procedures had been performed before admission. When salpingitis was diagnosed, bilateral salpingectomy was performed as the patient had asked for legal sterilisation. Chlamydia were isolated from the Fallopian tubes and from the cervix whereas gonococci were not. During the postoperative period, a significant change in the titre of IgG antibodies to *C. trachomatis* but not to *N. gonorrhoeae*, *M. hominis*, or *U. urealyticum* was detected.

In those sections of the Fallopian tubes studied by transmission electron microscopy, no cellular inclusions consistent with those caused by chlamydia were noted. Ciliated cells could be seen but the cilia did not show any structural changes. The nucleus of the ciliated cells showed degenerative alterations with distorted morphology. The non-ciliated secretory

cells showed protrusions with plenty of microvilli indicating an increased luminal surface. In non-ciliated epithelial cells, an increased number of lysosomes suggesting an increased secretory activity was found.

The light microscopy findings of histological changes in the tubes from both patients were the same as those described in textbooks for gonococcal salpingitis (Novak and Woodruff, 1974). Furthermore, the inflammatory changes were similar to those in grivet monkeys experimentally infected in the tubes with *C. trachomatis* (Ripa *et al.*, 1979).

It seems that the old textbook differentiation of gonococcal and nongonococcal salpingitis ought to be re-evaluated.

This work was supported by Aarhus Universitets Forskningsfond 7131-01 and by the Swedish Medical Research Council grant 16X-4509.

References

- Freundt, E. A., Erno, H., and Lerncke, R. (in press). In *Methods in Microbiology*, volume 13. Edited by J. R. Norris and D. W. Ribbons. Academic Press: London and New York.
- Gordon, F. B., Harper, I. A., Quan, A. L., Trehanne, J. D., Dwyer, R. St. C., and Garland, J. A. (1969). Detection of *Chlamydia* (Bedsonia) in certain infections of man. I. Laboratory procedures: comparison of yolk sac and cell culture for detection and isolation. *Journal of Infectious Diseases*, **120**, 451-462.
- Gästrin, B., Kallings, L. O., and Marcetic, A. (1968). The survival time for different bacteria in various transport media. *Acta Pathologica et Microbiologica Scandinavica*, **74**, 371-380.
- Hilton, A. L., Richmond, S. J., Milne, J. D., Hindley, F., and Clarke, S. K. R. (1974). Chlamydia A in the female genital tract. *British Journal of Venereal Diseases*, **50**, 1-10.
- Krogsgaard-Jensen, A. (1971). Indirect hemagglutination with *Mycoplasma* antigens: effect of pH on antigen sensitization of tanned fresh and formalinized sheep erythrocytes. *Applied Microbiology*, **22**, 756-759.
- Møller, B. R., Freundt, E. A., Black, F. T., and Frederiksen, P. (1978). Experimental infection of the genital tract of female grivet monkeys by *Mycoplasma hominis*. *Infection and Immunity*, **20**, 248-257.
- Mårdh, P.-A., Buchanan, T., Christensen, P., Danielsson, D., Lind, I., and Reimann, K. (1978). Comparison of four serological tests for detection of gonococcal antibodies in patients with complicated gonococcal infection. In *Immunology of Neisseria gonorrhoeae*, pp. 377-381. Edited by G. F. Brooks, E. C. Gotschlich, K. K. Holmes, W. D. Somyer, and F. E. Young. American Society for Microbiology: Washington DC.
- Mårdh, P.-A., Ripa, T., Svensson, L., and Weström, L. (1977). *Chlamydia trachomatis* infection of the Fallopian tubes in patients with acute salpingitis. *New England Journal of Medicine*, **296**, 1377-1799.
- Mårdh, P.-A. and Weström, L. (1970). Tubal and cervical cultures in acute salpingitis with special reference to *Mycoplasma hominis* and T-strain mycoplasmas. *British Journal of Venereal Diseases*, **46**, 179-186.
- Novak, E. R. and Woodruff, J. D. (1974). In *Novak's Gynecologic and Obstetric Pathology with Clinical and Endocrine Relations*, seventh edition, pp. 299-321. W. B. Saunders Company: Philadelphia, London, and Toronto.
- Oriel, J. D., Johnson, A. L., Barlow, D., Thomas, R. J., Nayar, K., and Reeve, P. (1978). Infection of the uterine cervix with *Chlamydia trachomatis*. *Journal of Infectious Diseases*, **137**, 443-451.
- Reiman, K. and Lind, I. (1977). An indirect haemagglutination test for demonstration of gonococcal antibodies using gonococcal piliantigen. I. Methodology and preliminary results. *Acta Pathologica Scandinavica* Section C, **85**, 115-122.

- Ripa, K. T. and Mårdh, P-A. (1977). Cultivation of *Chlamydia trachomatis* in cycloheximide-treated McCoy cells. *Journal of Clinical Microbiology*, **6**, 328-331.
- Ripa, K. T., Møller, B. R., Mårdh, P-A., Freundt, E. A., and Melsen, F. (1979). Experimental acute salpingitis in grivet monkeys provoked by *Chlamydia trachomatis*. *Acta Pathologica et Microbiologica Scandinavica* Section B, **87**, 65-70.
- Ripa, K. T., Svensson, L., Mårdh, P-A., and Weström, L. (1978). *Chlamydia trachomatis* cervicitis in gynecologic outpatients. *Obstetrics Gynecology*, **52**, 698-702.
- Schachter, J. (1978). Chlamydial infections. *New England Journal of Medicine*, **298**, 428-435.
- Treharne, J. D., Darougar, S., and Jones, B. R. (1977). Modification of the microimmunofluorescence test to provide a routine serodiagnostic test for chlamydial infection. *Journal of Clinical Pathology*, **30**, 510-517.
- Treharne, J. D., Ripa, K. T., Mårdh, P-A., Svensson, L., Weström, L., and Darougar, S. (1979). Antibodies to *Chlamydia trachomatis* in acute salpingitis. *British Journal of Venereal Diseases*, **55**, 26-29.
- Weström, L. and Mårdh, P-A. (1977). Epidemiology, etiology and prognosis of acute salpingitis. A study of 1457 laparoscopically verified cases. In *Nongonococcal Urethritis and Related Infections*, pp. 84-90. Edited by D. Hobson and K. K. Holmes, American Society for Microbiology: Washington DC.