

The histopathological diagnosis of donovanosis

V N SEHGAL,* A L SHYAMPRASAD,* AND P C BEOHAR†

From the *Department of Dermatology and Venereology and the †Department of Pathology, Maulana Azad Medical College and Associated LNJP and GB Pant Hospitals, New Delhi, India

SUMMARY The role of histopathology in the diagnosis of donovanosis was assessed in 42 patients. There was heavy infiltration of the dermis with plasma and mononuclear cells but with few lymphocytes and neutrophils. The epidermis contained focal collections of polymorphonuclear leucocytes. Endothelial proliferation and dilatation of dermal blood vessels was striking. Intracellular and extracellular Donovan bodies were shown in Giemsa stained sections from 40 patients. Pseudoepitheliomatous hyperplasia was found in biopsy specimens from a few patients.

Introduction

Donovanosis, a sexually transmitted disease caused by *Calymmatobacterium granulomatis*, is predominantly a disease of the tropics. It was first described by McLeod in 1882 in Madras. The diagnosis of donovanosis is largely made on the clinical features of the condition, which have been well documented.¹⁻³ Diagnosis is helped by finding Donovan bodies in tissue smears, although the usefulness of this test is limited by lack of sensitivity on microscopy of stained smears. We therefore decided to assess the role of histopathology in the diagnosis of donovanosis.

Patients and methods

All patients with genital ulcers who attended the sexually transmitted diseases (STD) clinic of our hospital were studied. A detailed history was taken from each patient and, after clinical examination, material from each ulcer was taken for microbiological investigations. These included dark ground microscopy for *Treponema pallidum*, examination of a Gram stained smear for *Haemophilus ducreyi*, and of a tissue smear for Donovan bodies (fig 1). The latter test was performed by removing a piece of tissue from a granulating area or the edge of the ulcer with a pair of forceps. This was pressed between two glass slides, so as to get tissue impressions on both the slides. After air drying the smears were fixed with methanol, stained with Giemsa stain, and examined microscopically. Serological tests for syphilis,

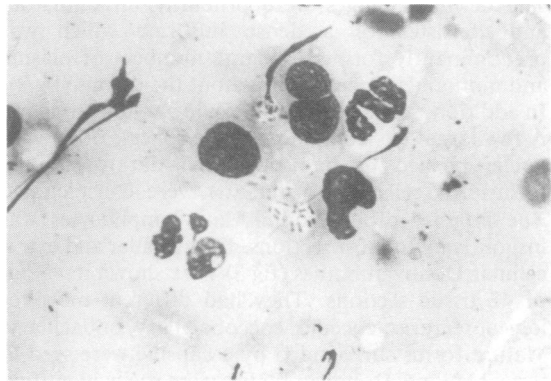


FIG 1 Tissue smear showing intracellular Donovan bodies (Giemsa \times 1000).

Venereal Diseases Research Laboratory (VDRL) and *Treponema pallidum* haemagglutination (TPHA) tests, were performed at the time of the first examination. The VDRL test was repeated every month for three months in each case. All patients showing positive tissue smears for Donovan bodies, as well as those clinically suggestive of donovanosis but with negative tissue smears, underwent biopsy of the lesions. The biopsy specimen was taken from the margin of the ulcer or from an area exhibiting luxuriant granulation tissue. A wedge of tissue was removed by a Bard-Parker knife, after local infiltration with 1% lignocaine at the base of the ulcer. Bleeding was arrested by pressure with a piece of gauze.

After being processed in the usual manner, tissue sections were stained with haematoxylin and eosin and Giemsa stains. A final diagnosis of donovanosis was based on clinical examination and the presence

Address for reprints: Dr V N Sehgal, A/6 Panchwati, Delhi-110033, India

Accepted for publication 18 July 1983

of Donovan bodies in tissue smears, histopathological sections or both.

Results

Of the 42 cases of donovanosis diagnosed, 34 were ulcerative or ulcerogranulomatous, seven hypertrophic, and one necrotic. Donovan bodies were shown in histopathological sections. In two other cases Donovan bodies were seen in tissue smears but these micro-organisms were not detected in histopathological sections.

HISTOPATHOLOGY

The histopathological changes were rather striking and affected the dermis as well as the epidermis.

Dermal changes

The dermal changes were primarily inflammatory and consisted of a dense infiltrate which was predominantly formed of large numbers of plasma and mononuclear cells throughout the dermis (fig 2). In addition, histiocytes were seen in varying numbers. A few large cells containing cystic spaces, often with nuclei pushed to one side, and darkly staining inclusions (cells of Greenblatt) were conspicuous. The number of neutrophils and lymphocytes was insignificant in most sections. Intracellular and extracellular Donovan bodies (fig 3) were shown in 40 out of 42 tissue sections. They had different morphological features: coccoid, coccobacillary, or bacillary. Mature forms surrounded by a capsule were seen in some sections. Donovan bodies were easily identified in Giemsa stained tissue sections but difficult to identify in haematoxylin and eosin stained sections. Vascular changes (dilatation, proliferation, or both)

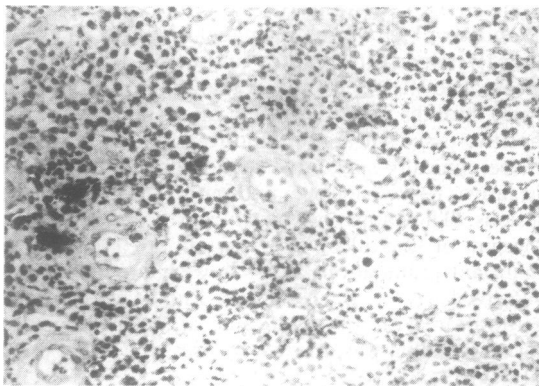


FIG 2 Tissue section showing massive inflammatory infiltrate comprising plasma and mononuclear cells. Vascular dilatation showing endothelial proliferation (H & E \times 400).

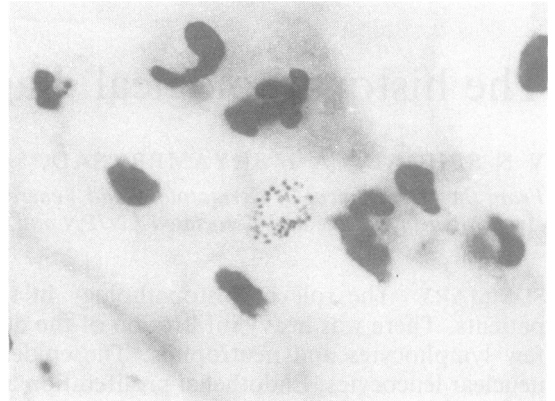


FIG 3 Tissue section showing collection of Donovan bodies (Giemsa \times 1000).

were predominant in 62% of cases. Endothelial proliferation was a common feature, and proliferation of the tunica media was seen in some cases.

Epidermal changes

Of the tissue sections 34 showed discontinuity in the epidermis, with ulcerations varying from mild to severe. Proliferation of the stratum spinosum (acanthosis), in the form of elongation of rete ridges (fig 4), was a constant feature of the hypertrophic variety, but was observed only in 19 cases of the ulcerative type of donovanosis. Pseudo-epitheliomatous hyperplasia was seen in only four tissue sections of the hyperplastic variety. There was no clear cut evidence of malignancy in the form of horn pearls, atypia of individual cells, or numerous mitotic figures, however, in these sections. Neutrophilic sprinkling of both the upper dermis, and the epidermis was seen in 18 sections. In only three cases was there a collection of neutrophils forming micro-abscesses in the epidermis (fig 5). The adnexae, fat, and muscle were conspicuously spared. In four sections, fibrosis of the lower dermis was also recorded.

Discussion

The diagnosis of donovanosis in our series was based on the clinical features and tissue smear microscopy. The limitations of the tissue smear are obvious in some varieties of donovanosis; in our study it was difficult to demonstrate Donovan bodies in early donovanosis, in two chronic cases, or with the necrotic variety of ulcer. Rajam and Rangiah have expressed similar views.¹ In addition, cases which clinically suggest malignancy necessitate a biopsy.⁴ Histopathological sections are of great value in the diagnosis of each of the clinical varieties of dono-

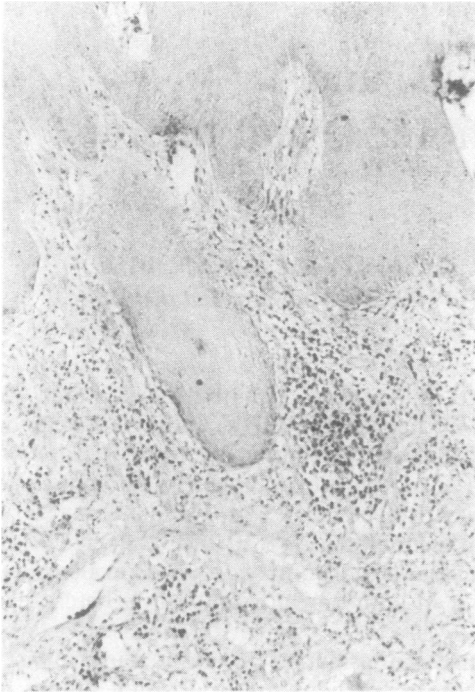


FIG 4 Epidermal changes in the form of elongation of the rete ridges, with intense inflammatory infiltrate primarily of mononuclear cells (H & E \times 160).

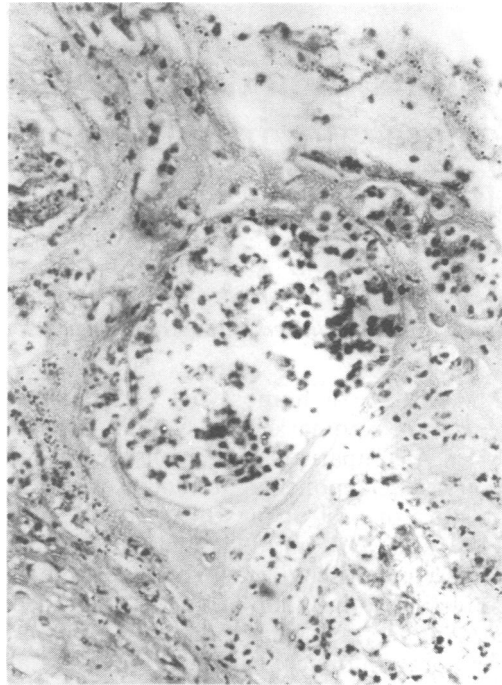


FIG 5 Ulcer with micro-abscess formation (H & E \times 400).

vanosis. In three of our cases which were clinically diagnosed as donovanosis, Donovan bodies were not found in repeated tissue smear examinations but were clearly shown in histopathological sections. Pund and Greenblatt described five essential histopathological features for the diagnosis of donovanosis.⁵ Their main emphasis was on the massive cellular infiltrate formed predominantly by plasma cells, a paucity of lymphocytes, diffuse sprinkling of polymorphonuclear leucocytes with focal collections, pronounced epithelial proliferation at the margins, and the presence of large, mononuclear cells in the infiltrate which were considered to be pathognomic. All these features were observed in our study. Intracellular and extracellular Donovan bodies of varying morphology and vascular proliferation and dilatation were also prominent in the lower dermis. The vascular proliferation was especially marked in the ulcerogranulomatous variety of donovanosis. Donovan bodies were easily identifiable in Giemsa stained tissue sections, and were easier to locate than in tissue smears. The characteristic cellular infiltrate of plasma and mononuclear cells and the extensive ulceration with acanthosis and rete ridge elongation at the margins were other characteristics which featured in our cases. Pseudo-epitheliomatous hyper-

plasia was observed in only four tissue sections, none of which showed features of malignancy. Beerman and Sonck emphasised the prominence of this feature.⁶ According to them, mitotic figures were not so numerous and 'pearl' formation not so prominent in epitheliomas compared with pseudo-epitheliomatous hyperplasia. Neutrophilic micro-abscesses in the epidermis and localised collections of neutrophils in the upper dermis were features seen in our study. Such findings were reported earlier by Rajam and Rangiah¹ and Nayar *et al.*⁴

References

1. Rajam RV, Rangiah PN. Donovanosis (granuloma inguinale, granuloma venereum) *WHO Series Monograph* No 24. Geneva: World Health Organisation, 1954.
2. US Public Health Service. *Management of chancroid, granuloma inguinale, lymphogranuloma venereum in general practice*. Atlanta, Georgia: US Department of Health, Education and Welfare, Communicable Disease Centre, Venereal Diseases Branch, 1964.
3. Sehgal VN. *A textbook of venereal diseases*. 1st ed. New Delhi: Vikas Publishing House, 1978.
4. Nayar M, Chandra M, Saxena HMK, Bhargava NC, Sehgal VN. Donovanosis—a histopathological study. *Indian J Pathol Microbiol* 1981;24:71-6.
5. Pund ER, Greenblatt RB. Specific histology of granuloma inguinale. *Arch Pathol Lab Med* 1937;23:224-30.
6. Beerman H, Sonck CE. The epithelial changes in granuloma inguinale. *American Journal of Syphilis, Gonorrhoea, and Venereal Disease* 1952;36:501-10.