

# Long-term outcomes of pouch surveillance and risk of neoplasia in familial adenomatous polyposis



## Authors

Roshani V. Patel<sup>1,2,‡</sup>, Kit Curtius<sup>3,4,‡</sup>, Ripple Man<sup>1</sup>, Jordan Fletcher<sup>1,2</sup>, Victoria Cuthill<sup>1</sup>, Susan K. Clark<sup>1,2</sup>, Alexander C. von Roon<sup>5</sup>, Andrew Latchford<sup>1,2</sup>

## Institutions

- 1 Polyposis Registry, St Mark's Hospital, Harrow, UK
- 2 Department of Surgery and Cancer, Imperial College London, London, UK
- 3 Barts Cancer Institute, Queen Mary University of London, London, UK
- 4 Division of Biomedical Informatics, Department of Medicine, University of California San Diego, La Jolla, California, USA
- 5 Department of Colorectal Surgery, University College Hospital, London, UK

submitted 14.2.2022

accepted after revision 15.2.2023

accepted manuscript online 17.2.2023

published online 22.5.2023

## Bibliography

Endoscopy 2023; 55: 836–846

DOI 10.1055/a-2038-0541

ISSN 0013-726X

© 2023. The Author(s).

This is an open access article published by Thieme under the terms of the Creative Commons Attribution-NonDerivative-NonCommercial License, permitting copying and reproduction so long as the original work is given appropriate credit. Contents may not be used for commercial purposes, or adapted, remixed, transformed or built upon. (<https://creativecommons.org/licenses/by-nc-nd/4.0/>)

Georg Thieme Verlag KG, Rüdigerstraße 14,  
70469 Stuttgart, Germany

Tables 1 s–6 s, Fig. 1 s

Supplementary material is available under  
<https://doi.org/10.1055/a-2038-0541>

## Corresponding author

Roshani Patel, MBBS MRCS MEd, The Polyposis Registry, St Mark's Hospital, Watford Road, Harrow, HA1 3UJ, UK  
roshani.patel@nhs.net

## ABSTRACT

**Background** Long-term pouch surveillance outcomes for familial adenomatous polyposis (FAP) are unknown. We aimed to quantify surveillance outcomes and to determine which of selected possible predictive factors are associated with pouch dysplasia.

**Methods** Retrospective analysis of collected data on 249 patients was performed, analyzing potential risk factors for the development of adenomas or advanced lesions ( $\geq 10$  mm/high grade dysplasia (HGD)/cancer) in the pouch body and cuff using Cox proportional hazards models. Kaplan–Meier analyses included landmark time-point analyses at 10 years after surgery to predict the future risk of advanced lesions.

**Results** Of 249 patients, 76% developed at least one pouch body adenoma, with 16% developing an advanced pouch body lesion; 18% developed an advanced cuff lesion. Kaplan–Meier analysis showed a 10-year lag before most advanced lesions developed; cumulative incidence of 2.8% and 6.4% at 10 years in the pouch body and cuff, respectively. Landmark analysis suggested the presence of adenomas prior to the 10-year point was associated with subsequent development of advanced lesions in the pouch body (hazard ratio [HR] 4.8, 95%CI 1.6–14.1;  $P=0.004$ ) and cuff (HR 6.8, 95%CI 2.5–18.3;  $P<0.001$ ). There were two HGD and four cancer cases in the cuff and one pouch body cancer; all cases of cancer/HGD that had prior surveillance were preceded by  $\geq 10$ -mm adenomas.

**Conclusions** Pouch adenoma progression is slow and most advanced lesions occur after 10 years. HGD and cancer were rare events. Pouch phenotype in the first decade is associated with the future risk of developing advanced lesions and may guide personalized surveillance beyond 10 years.

## Introduction

Familial adenomatous polyposis (FAP) is caused by a constitutional pathogenic variant in the APC gene [1]. Prophylactic co-

lectomy and ileorectal anastomosis (IRA) or restorative proctocolectomy (RPC) is advised to prevent the otherwise inevitable development of colorectal cancer [1].

Pathogenic variants in the mutation cluster region (MCR) predict severe colorectal disease, while variants at the ends of

‡ Contributed equally to this article

the gene are associated with a milder phenotype. Primary RPC is recommended for patients with features predicting a high risk of rectal adenoma/cancer, including: MCR pathogenic variant; over 500 colonic or over 20 rectal adenomas [1]. Following IRA, some patients require completion restorative proctectomy (secondary RPC) owing to the development of severe rectal polyposis [2].

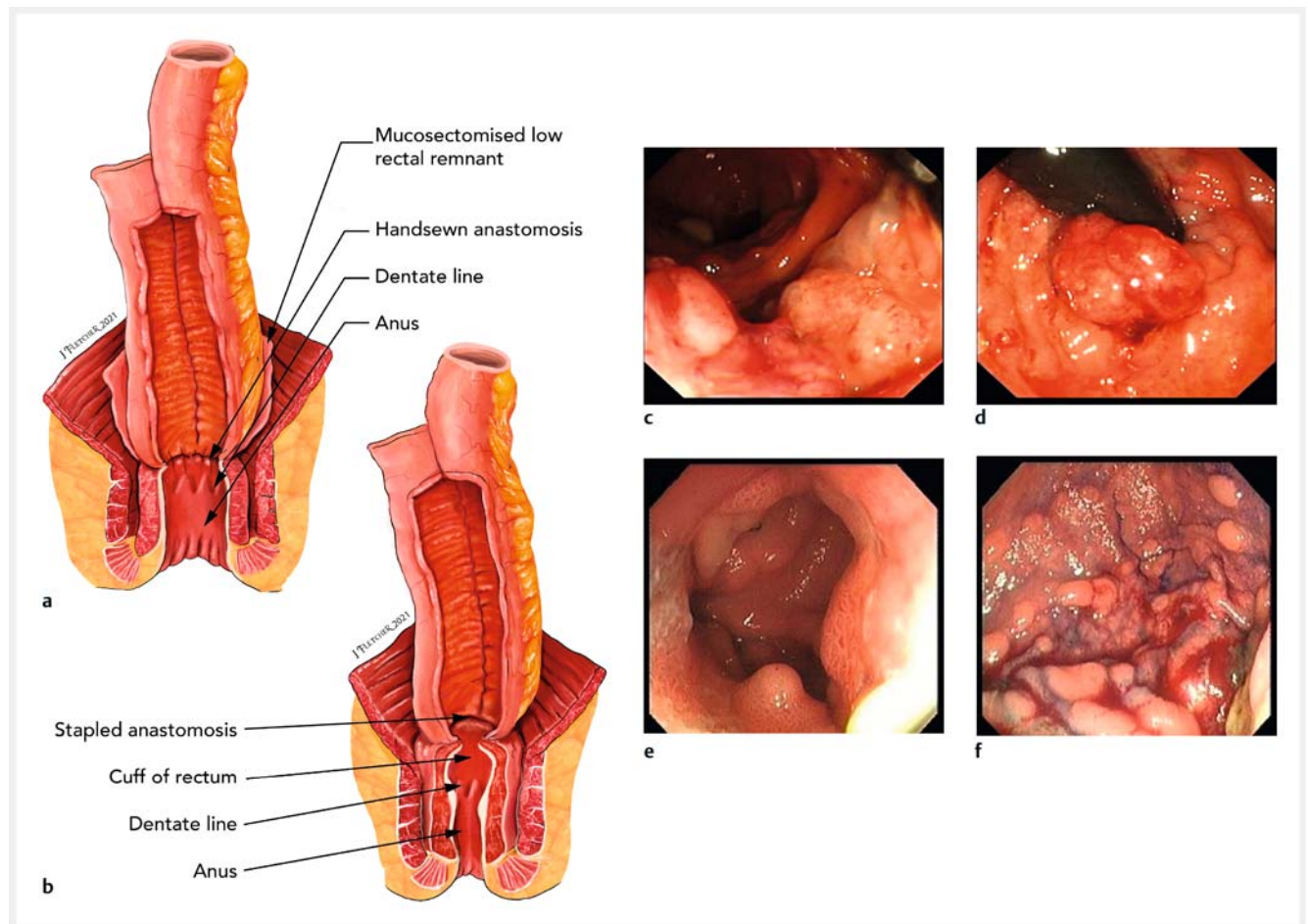
RPC initially included distal rectal mucosectomy with the ileal pouch pulled through the rectal muscle tube and hand-sewn above the dentate line [3], potentially leaving mucosal islands between the rectal muscle and the ileal pouch (► Fig. 1a). A stapled anastomotic technique [4] was later adopted, preserving a rectal mucosal “cuff,” which can develop adenomas and cancer, but is accessible for surveillance (► Fig. 1b).

Adenomas may develop in the pouch body or rectal cuff (► Fig. 1c–f). The risk of cuff adenomas increases over time and is higher after a stapled anastomosis [5–7]. Cuff cancer develops in 0.5%–3.6% of patients [5,6]. Pouch body cancer is

rare [8,9], but adenomas are present in 7%–15% of patients at 5 years and 72%–78% at 20 years [10–12]. Other factors associated with pouch body adenoma development, such as genotype, sex, and intestinal phenotype, have been inconsistently reported [10,13–15].

Most studies use time to development of an adenoma as the primary end point; however, it is the presence of uncontrolled pouch polyposis (hundreds of adenomas, large lesions, or high grade dysplasia [HGD]) that raises concern for cancer risk and is more clinically important. There is a need to better identify those at risk of this.

Current UK guidelines recommend annual pouchoscopy [16], but there is a lack of data to guide surveillance intervals. Our aims were to quantify the surveillance outcomes of pouches in FAP, to better understand adenoma development, and to determine which of selected possible predictive factors are associated with pouch dysplasia.



► **Fig. 1** Types of anastomoses used and the adenomas that develop in pouches in familial adenomatous polyposis. **a, b** Illustrations of the anastomoses showing: **a** a handsewn anastomosis, in which there remains a hidden risk of adenoma development from residual rectal cuff mucosal islands – the ileal pouch has been advanced into a 2-cm rectal cuff following mucosectomy, and is handsewn at the dentate line, meaning islands of mucosal cells can remain behind that may develop into adenomas that cannot be visualized on direct endoscopy, and therefore require expert digital examination; **b** a stapled anastomosis, in which ~1–2 cm of rectal cuff remains in-situ and is proximally stapled to the ileoanal pouch with a circular stapling device, with this technique enabling direct visualization of any adenomas at pouchoscopy. **c–f** Endoscopic images of example pouch adenomas showing: **c** cancer in a cuff; **d** high grade dysplasia in a cuff lesion visualized on retroflexion; **e** adenomas in the pouch body; **f** diffuse polyposis within the pouch body.

## Methods

### Patient cohort

We performed a retrospective review of all patients with FAP and an ileoanal pouch on the St Mark's Hospital Polyposis Registry database up to 2018. Inclusion criteria were a minimum of one surveillance pouchoscopy and a documented constitutional APC pathogenic variant. Genotype was categorized as: within the MCR (codon 1250–1450), 5' of the MCR, 3' of the MCR [2], or a gross deletion.

Annual pouch surveillance started in 1997, performed as previously described [17]. Enhanced imaging was used at the endoscopist's discretion. Data recorded included: patient demographics, prophylactic surgery type, endoscopic findings, intervention, and contemporaneous Spigelman stage for duodenal disease.

### Follow-up outcomes

Given the rarity of cancer, presence of an "advanced lesion," defined as an adenoma  $\geq 10$  mm, HGD, or cancer, was the primary outcome. Rectal cuff and pouch body findings were analyzed separately. We described risk factors for adenoma development, but focused on advanced lesions as our main clinical end point.

### Statistical analysis

When analyzing neoplastic progression, data were considered right-censored if the patient had not progressed to the outcome of interest by the time of the last surveillance. Follow-up was defined as the time between pouch formation and progression or censoring. The following continuous variables were compared using Mann–Whitney *U* tests between those patients who did and did not progress to an advanced lesion: number of surveillance pouchoscopies; mean surveillance interval; pouch and patient age at first and last surveillance.

Statistical associations for adenoma and advanced lesion development in the pouch body and cuff were examined using univariate and multivariate Cox proportional hazards models; Kaplan–Meier curve estimations with log-rank tests were performed for potential differences in progression. Survival analyses were performed using R Studio (version 4.0.3). Pouch age was the continuous time variable. Time-independent factors included in all of the univariate Cox proportional hazards models were: sex, patient age at surgery, primary or secondary RPC, and APC pathogenic variant.

Pouch body analysis included univariate models considering Spigelman stage at time of RPC as another potential time-independent risk factor. To account for changing Spigelman stage with pouch age, univariate models were also considered for Spigelman stage as a time-varying covariate using the contemporaneous highest Spigelman stage recorded as the time-varying covariate variable (to account for therapeutic downstaging of disease).

Only 80/249 patients had a Spigelman stage recorded at pouch surgery, so we excluded this variable in the first multivariate Cox proportional hazards model for advanced lesion development. We did however investigate a second multivariate Cox

proportional hazards model with the four time-independent factors and Spigelman stage included as a time-varying covariate.

Cuff analysis included univariate models with type of anastomosis as an additional time-independent risk factor. All time-independent factors were included in a multivariate model for advanced lesion development in the cuff.

Surveillance data were included until the outcome of interest or censoring at last follow-up date or pouch excision. Correction for multiple hypothesis testing was performed using the Bonferroni correction.

We hypothesized that it takes time to develop advanced lesions and that differences in the risk of developing later advanced lesions may be discernible by 10 years after pouch construction. We performed a landmark time-point analysis to determine differences in the rates of progression to advanced lesions in the pouch body and cuff, using clinical features detectable up to 10 years post-surgery [18, 19]. The aim was to potentially distinguish differences in the risk factors in those who were destined to remain advanced lesion-free from those who were on a "fast-track" to developing advanced lesions in the pouch body; these risk factors were used as constant "baseline 10-year" predictors in the univariate Cox proportional hazards models. This enabled us to add adenoma presence and size at the most recent surveillance pouchoscopy prior to the 10-year mark as two additional variables in univariate Cox proportional hazards models. Spigelman stage was considered a binary variable (grouped as stages 0–2 or 3–4) owing to the small sample size. Kaplan–Meier curves were used to assess differences in the future risk of advanced lesion progression for covariates found to be statistically significant in univariate Cox proportional hazards models starting at the 10-year mark.

### Secondary outcomes

We examined the maximum therapy employed for management of adenomas. We collected data on whether patients had snare polypectomy, endoscopic submucosal dissection (ESD), or surgical treatment such as examination under anesthesia (EUA) with surgical polypectomy or pouch excision.

## Results

Surveillance data were available for 249 patients (131 men [53%]) (► **Table 1**). Pouch formation was carried out at our center in 159 patients (64%). The median age of patients at pouch construction was 29 years (range 5–66 years). The median (interquartile range [IQR]) total follow-up was 15 (8–22) years. A total of 2225 surveillance pouchoscopies were performed (median [IQR] per patient 8 [4–14]) over 3811 patient-years. There were 164 patients who underwent primary RPC and 85 who underwent secondary RPC; among these, significant differences were found between the mean number of surveillance examinations, mean surveillance interval, and patient age at first and last examinations (**Table 1 s**, see online-only Supplementary material).

### Time to develop first adenoma

There were 188 patients (76%) who developed at least one pouch body adenoma; the cumulative incidence at 5, 10, 15,

► **Table 1** Details of the 249 patients with familial adenomatous polyposis who underwent restorative proctocolectomy (RPC), their surgery, and surveillance examinations.

Demographic data	
Sex, male, n (%)	131 (53)
Patient age at time of pouch surgery, median (range) [IQR], years	29 (5–66) [22–38]
Number of surveillance examinations, median (range) [IQR]	8 (1–26) [4–14]
Interval between examinations, median (range) [IQR], years	1.50 (0.14–15.93) [1.16–2.23]
First surveillance endoscopy post-surgery	
Age of pouch, median (range) [IQR], years	3.49 (0.14–30.85) [1.39–9.91]
Patient age, median (range) [IQR], years	36 (6–77) [29–46]
Last surveillance endoscopy	
Age of pouch, median (range) [IQR], years	15.44 (0.14–37.31) [8.45–21.52]
Patient age, median (range) [IQR], years	46 (10–83) [35–56]
Details of surgery	
Type of surgery, n (%)	
▪ Primary RPC	164 (66)
▪ Secondary RPC	85 (34)
Configuration of pouch, n (%)	
▪ J	137 (55)
▪ W	27 (10)
▪ S	1 (<1)
▪ Kock	2 (<1)
▪ Unknown	82 (33)
Anastomotic technique, n (%)	
▪ Handsewn	72 (48)
▪ Stapled	79 (52)
▪ Unknown	98 (–)
Site of APC pathogenic variant (codon), n (%)	
▪ 5' to codon 1249	152 (61)
▪ 1250 to 1450	69 (28)
▪ 3' to 1450	20 (8)
▪ Gross deletion	8 (3)
IQR, interquartile range.	

20, 25, and 30 years was 19.3%, 41.0%, 56.6%, 65.9%, 73.5%, and 74.7%, respectively (**Fig. 1 s**, part A). We did not identify significant risk factors associated with the development of a pouch body adenoma (**Table 2 s**).

A cuff adenoma developed in 179 patients (72%); the cumulative incidence at 5, 10, 15, 20, 25, and 30 years was 26.1%, 40.2%, 53.0%, 62.7%, 67.1%, and 70.7%, respectively (**Fig. 1 s**, part B). A stapled anastomosis was a significant risk factor on univariate analysis (hazard ratio [HR] 3.5, 95%CI 2.3–5.2) (**Table 3 s**). No other risk factors were found to be significant after Bonferroni correction.

Of 213 patients who developed at least one adenoma (cuff or pouch body), 154 (72%) developed adenomas at both sites; 34 (16%) and 25 (12%) developed adenomas uniquely in the pouch body and cuff, respectively (**Fig. 1 s**, part C). Of 72 patients who developed advanced lesions, 12 (17%) did so in both the cuff and pouch body; 27 (38%) and 33 (46%) developed advanced lesions uniquely in the pouch body and cuff, respectively (**Fig. 1 s**, part D).

### Pouch body lesions

The largest adenoma detected in the pouch body was 1–4 mm in 105 patients (42%), 5–9 mm in 44 patients (18%), and ≥ 10 mm in 39 patients (16%). HGD was not identified, but there was one case of pouch body cancer (**Table 4 s**).

### Advanced lesions

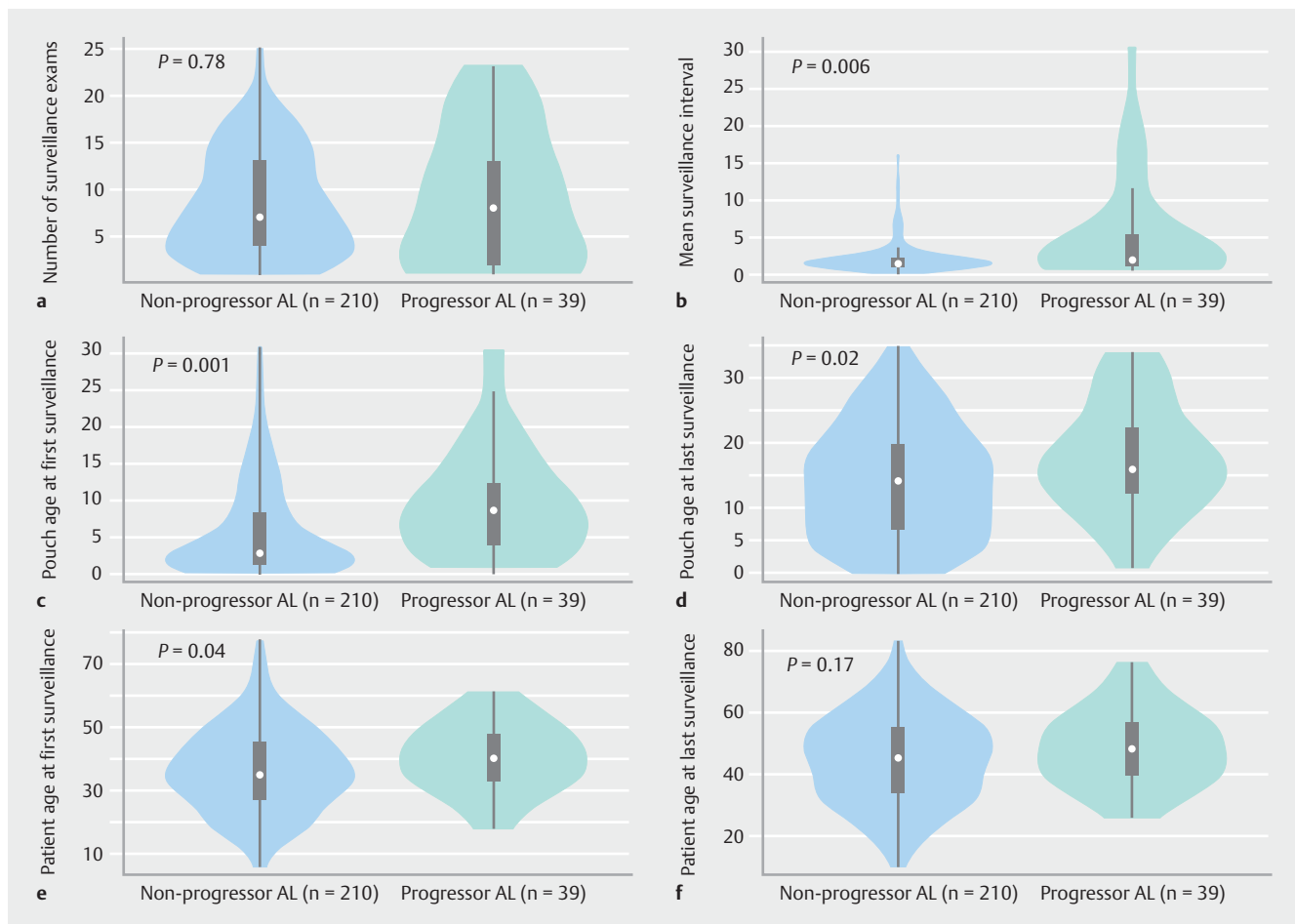
An advanced lesion developed in the pouch body in 39/249 patients (16%). There was no statistically significant difference in the number of surveillance examinations between patients that did and did not progress to an advanced lesion in the pouch body (► **Fig. 2 a**; **Table 5 s**). However, patients who developed an advanced lesion had a longer median (range) surveillance interval (1.96 years [0.66–30.44] vs. 1.46 years [0.14–16];  $P=0.006$ ; ► **Fig. 2 b**), started surveillance later (8.54 years [0.92–30.44] vs. 2.73 years [0.14–30.85];  $P<0.001$ ), and had an older (median [IQR]) pouch at diagnosis of the advanced lesion (15.9 [12.33–22.16] vs. 14.15 [6.88–19.66] years;  $P=0.03$ ) (► **Fig. 2 d**; **Table 5 s**). Patients were older at first surveillance in the progressors group, but the difference for patient age at last surveillance was not statistically significant (► **Fig. 2 e, f**).

Adenoma counts within the pouch body increased over time (► **Fig. 3 a**). Advanced lesions developed in the context of both high and low adenoma counts within the pouch body as recorded at time of advanced lesion diagnosis (► **Fig. 3 b**).

The cumulative incidence of advanced lesions at 5, 10, 15, 20, 25, and 30 years was 0.8%, 2.8%, 6.0%, 10.8%, 12.4%, and 14.1%, respectively (► **Fig. 3 c**). No baseline factors were identified as conferring increased risk of advanced lesions on univariate and multivariate Cox proportional hazard analysis.

Seven patients (2.8%) developed advanced pouch body lesions before 10 years (median [range] pouch age at diagnosis 7 [0.9–9.7] years). Of these seven patients, two commenced annual surveillance from RPC; the remaining five started at pouch ages of 4 ( $n=2$ ), 6, 7, and 10 years ( $n=1$  each).

One patient, with ulcerative colitis and FAP, developed pouch body cancer 34 years after surgery. Surveillance began at our center 30 years after pouch formation, when he had approximately 300 pouch body adenomas that were up to 30 mm in size. Biopsies had shown low grade dysplasia (LGD) at the



► **Fig. 2** Violin plots comparing the surveillance data of patients who progressed to advanced lesions versus those who did not progress ( $P$  values for Mann–Whitney  $U$  test), with results provided for: **a** number of surveillance examinations; **b** mean surveillance interval between examinations for each patients; **c** pouch age at first surveillance; **d** pouch age at last surveillance; **e** patient age at first surveillance; **f** patient age at last surveillance.

preceding surveillance pouchoscopies, before an ulcerated malignant lesion of 40–50 mm was identified.

### Landmark time-point analysis for advanced lesions in the pouch body

A landmark time-point analysis was performed using 165 patients who remained at risk for the development of future advanced lesions starting at 10 years after surgery. There were 84 patients who were excluded as they had either progressed to an advanced lesion ( $n=7$ ) or been censored ( $n=77$ ) before completing 10 years of follow-up. The majority (86% [32/37]) who progressed to an advanced lesion did so more than 10 years after RPC, indicating that the advanced lesion risk should be re-assessed for patients on surveillance at 10 years. Constant covariates (sex, age at surgery, pathogenic variant, first operation type) were considered fixed at year 10.

Considering those patients who had undergone at least one surveillance examination before 10 years and had follow-up continuing beyond 10 years ( $n=104$ ) in a univariate Cox proportional hazards models (► **Table 2**), we found that the presence of at least one pouch body adenoma (HR 4.8, 95%CI 1.6–

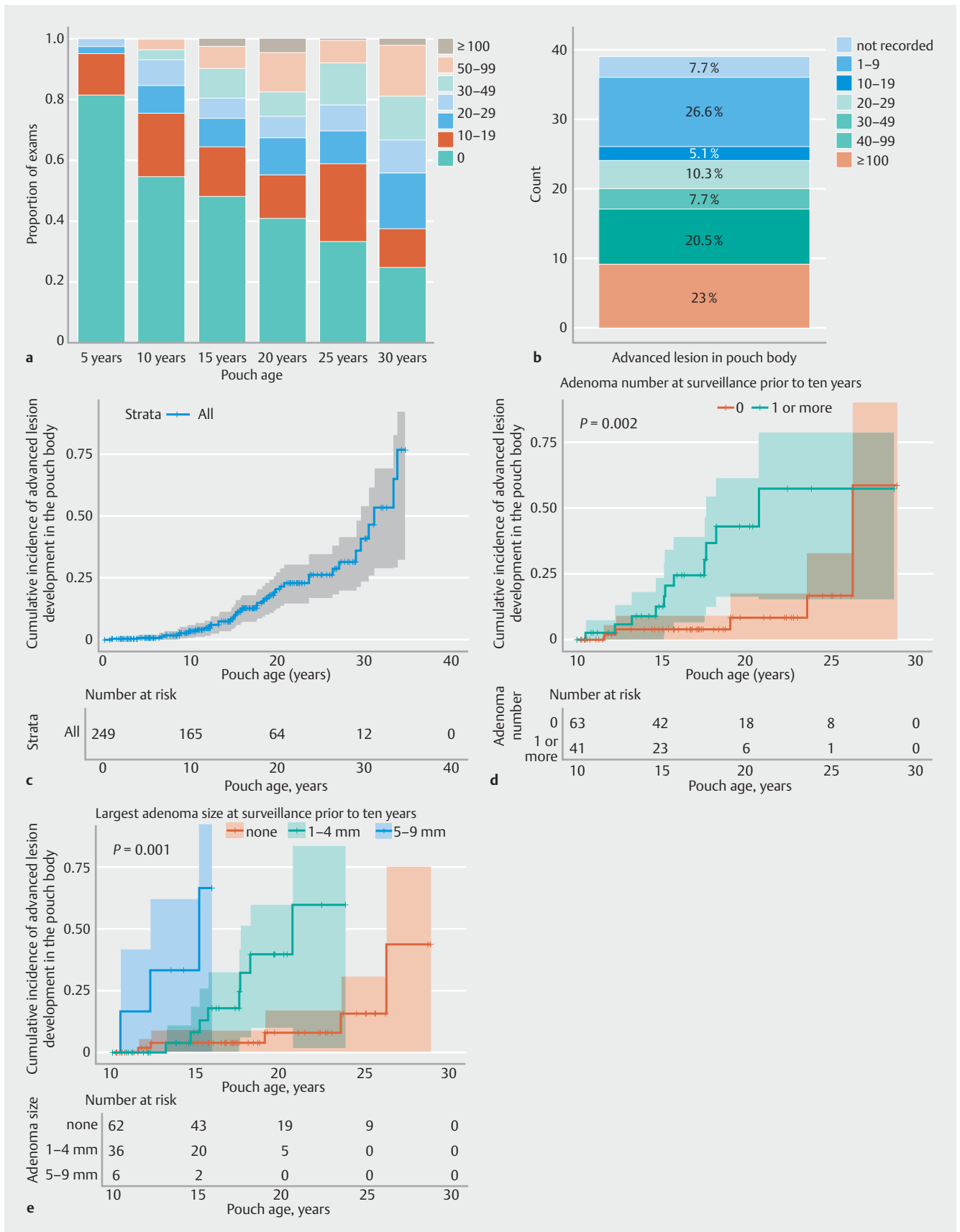
14.1;  $P=0.004$ ) or a larger pouch body adenoma (HR 32.4, 95%CI 5.8–177.1;  $P<0.001$ ) (► **Fig. 3 d,e**) prior to 10 years were significantly associated with an increased risk of developing advanced lesions in the subsequent years of follow-up.

### Cuff lesions

A total of 45 patients developed an advanced lesion in the cuff: 44 (18%) had an adenoma  $\geq 10$  mm, four (2%) had cuff cancer, and one (0.6%) had HGD.

### Advanced lesions

There were 16 patients who developed an advanced lesion in the cuff before 10 years; the cumulative incidence of advanced lesions at 5, 10, 15, 20, 25, and 30 years was 2.4%, 6.4%, 10.8%, 14.0%, 16.5%, and 17.3%, respectively (► **Fig. 4a**). Univariate Cox regression analyses (**Table 3s**) found that patients were more likely to develop advanced lesions following a stapled anastomosis (HR 4.5, 95%CI 2.7–11.9;  $P=0.002$ ) (► **Fig. 4b**), or if they carried a 3' APC pathogenic variant (compared to MCR), (HR 5.2, 95%CI 1.9–14.2;  $P=0.001$ ). Only stapled anastomosis remained significant on multivariate analysis.



► **Fig. 3** Graphs of surveillance outcomes, including advanced lesion development in the pouch body showing: **a** maximum adenoma count on record by 5, 10, 15, 20, 25, and 30 years; **b** contemporaneous adenoma count in the pouch body at the time an advanced lesion was diag-

nosed in the pouch body for the 39 patients with advanced lesions; **c–e** Kaplan–Meier curves for time to development of an advanced lesion in the pouch body: **c** for all patients; **d** (landmark at end of year 10 since surgery) stratified by presence or absence of an adenoma at the most recent surveillance prior to 10 years (of 104 patients still on study at year 10, 16 subsequently progressed to an advanced lesion; log-rank for differences in survival,  $P=0.002$ ); **e** (landmark at end of year 10 since surgery) stratified by largest adenoma size observed prior to 10 years (of 104 patients still on study at year 10, 16 subsequently progressed to an advanced lesion; log-rank for differences in survival,  $P<0.001$ ).

**► Table 2** Univariate Cox proportional hazards models for progression to an advanced lesion in the pouch body and cuff, with risk factors at year 10 (landmark time-point analysis).

Variable	Pouch body			Cuff		
	Number (n = 165)	Adjusted hazard ratio (95%CI)	P value <sup>1</sup>	Number (n = 158)	Adjusted hazard ratio (95%CI)	P value <sup>2</sup>
Female sex	76	0.7 (0.4–1.4)	0.34	71	0.7 (0.4–1.6)	0.42
Age at pouch surgery, years		1.01 (0.98–1.05)	0.53		1.0 (0.97–1.04)	0.72
APC pathogenic variant type						
▪ 1250–1450 (MCR)	48	1	ref	46	1	ref
▪ 1–1249	99	1.2 (0.5–2.7)	0.64	95	1.4 (0.5–3.5)	0.50
▪ > 1450	12	3.2 (0.8–12.4)	0.09	11	4.6 (1.3–16.7)	0.02
▪ Gross deletion	6	–	>0.99	6	2.1 (0.4–10.5)	0.37
Type of initial pouch surgery						
▪ IRA (secondary RPC)	59	1	ref	58	1	ref
▪ Primary RPC	106	1.09 (0.5–2.3)	0.81	100	1.5 (0.7–3.4)	0.33
Type of anastomosis <sup>3</sup>						
▪ Handsewn				60	1	ref
▪ Stapled				30	3.8 (1.2–11.9)	0.02
Adenoma number (at most recent examination where number was recorded before year 10) <sup>4</sup>						
▪ None	63	1	ref	73	1	ref
▪ 1 or more	41	4.8 (1.6–14.1)	<b>0.004</b>	24	6.8 (2.5–18.3)	<b>&lt;0.001</b>
Adenoma size (at most recent examination where size was recorded before year 10), mm <sup>5</sup>						
▪ None	62	1	ref	30	1	ref
▪ 1–4	36	5.8 (1.7–20.4)	<b>0.005</b>	12	3.1 (0.97–9.85)	0.06
▪ 5–9	6	32.4 (5.8–177.1)	<b>&lt;0.001</b>	1	–	–

MCR, mutation cluster region; IRA, ileorectal anastomosis; RPC, restorative proctocolectomy.

<sup>1</sup> Progression to an advanced lesion in the pouch body (32/165). Statistical significance in univariate analyses indicated when  $P<0.01$ . This pragmatic approach led to the same variables being considered statistically significant as in the stricter approach requiring  $P<0.008$  with Bonferroni multiple testing correction for six potential variables (shown in bold).

<sup>2</sup> Progression to an advanced lesion in the cuff (29/158). Statistical significance in univariate analyses indicated when  $P<0.01$ . This pragmatic approach led to the same variables being considered statistically significant as in the stricter approach requiring  $P<0.007$  with Bonferroni multiple testing correction for seven potential variables (shown in bold).

<sup>3</sup> Cuff group, n = 90.

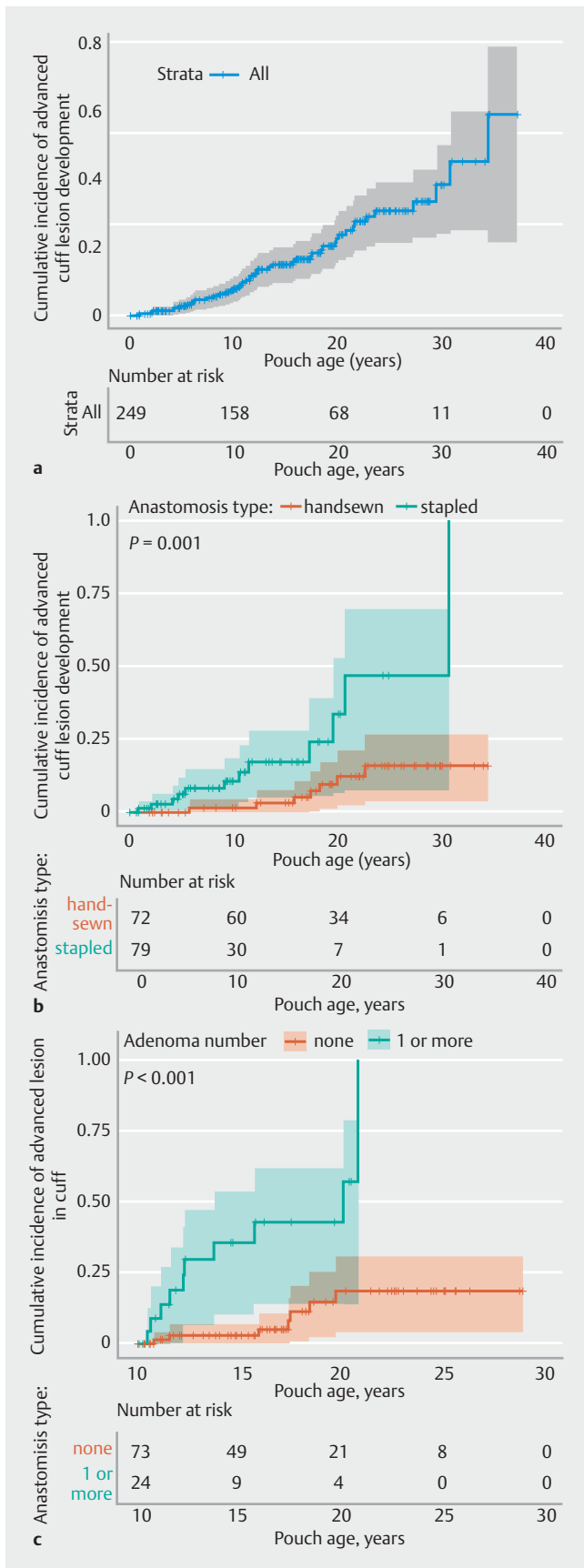
<sup>4</sup> Pouch body, n = 104 with 16 advanced lesions; cuff, n = 97, with 17 advanced lesions.

<sup>5</sup> Pouch body, n = 104, with 16 advanced lesions; cuff, n = 43, with 13 advanced lesions.

Of the 16 patients with an advanced lesion before 10 years, nine had an adenoma sized  $\geq 10$  mm. One patient had an adenoma sized  $\geq 10$  mm with subsequent HGD, a 10-mm adenoma having been observed on commencement of surveillance 6 years after pouch formation. At 8 years, the recurrence containing HGD was treated by transanal surgical excision; after four further transanal resections the pouch was excised (at

pouch age 20 years) and a cuff cancer was identified on post-operative histopathology. The patient remains disease free. No patient developed cuff cancer within 10 years of the RPC.

Overall there were 44 patients with a  $\geq 10$ -mm adenoma; three went on to develop cuff cancer (including the patient described above). The only patient who developed cuff cancer without a prior  $\geq 10$ -mm lesion was diagnosed at first surveil-



► **Fig. 4** Kaplan–Meier curves for progression to an advanced lesion in the cuff: **a** for all patients; **b** stratified by anastomosis type;

**c** (landmark at end of year 10 since surgery) stratified by presence or absence of an adenoma at the most recent surveillance prior to 10 years (of 97 patients still on study at year 10, 17 progressed to an advanced lesion on subsequent follow-up; log-rank for differences in survival,  $P < 0.001$ ).

lance pouchoscopy after referral to our center, at pouch age 20 years.

#### Landmark time-point analysis for advanced lesions in the cuff

In the landmark time-point analysis at 10 years, univariate Cox regression analysis showed that the phenotype of the cuff at a surveillance examination prior to the 10-year point could predict subsequent development of an advanced lesion in the cuff. The presence of an adenoma was significantly associated with the development of an advanced lesion in the cuff (HR 6.8, 95%CI 2.5–18.3;  $P < 0.001$ ) (► **Table 2**) in the subsequent years of follow-up (Kaplan–Meier log-rank,  $P < 0.001$ ) (► **Fig. 4c**). Overall, however, patients who progressed to an advanced lesion in the cuff had fewer surveillance examinations compared with those who did not (median 4 [range 1–17] vs. 8 [1–21];  $P = 0.002$ ) (**Table 5s**).

#### Management of advanced lesions

Most pouch body adenomas were successfully managed endoscopically. The maximum therapy used for those who developed a pouch body advanced lesion (39 patients) was: endoscopic snare polypectomy in 30 patients, pouch excision in eight patients (described below), and palliative care for one patient with pouch body cancer.

Of the 45 patients who developed advanced cuff lesions, 23 were managed endoscopically (22 snare polypectomy and one ESD) and 11 underwent EUA with surgical excision of polyps. All four patients with cuff cancer and the patient with recurrent cuff HGD were managed by pouch excision or exenterative surgery (**Table 4s**).

#### Pouch excision

Pouch excision was performed for 14 patients (6%) owing to neoplasia: nine for benign pouch body disease (five for adenoma burden in both pouch body and cuff; four for pouch body lesions only) (**Table 6s**), and five for cuff lesions (four for cancers and one for an endoscopically unmanageable cuff lesion).

#### Discussion

The literature on the neoplastic outcomes of RPC in patients with FAP is inconsistent; some have authors have reported exclusively on any adenoma in either the cuff or pouch body [5–7, 10, 13, 20, 21], whilst others have combined these, despite their being biologically and anatomically distinct areas [14, 22–29]. No previous study has specifically considered the practical clinical end point of advanced lesion development in either the pouch body or cuff.



The risk of developing pouch adenomas in our study is consistent with the published data [6, 10, 12, 13, 22–24]. We observed that a pouch body adenoma developed in 65.5% of patients by 20 years, which is similar to other published data where pouch body adenomas were observed in 45%–78% by 20 years [10, 20]. Cuff adenoma development has generally been described according to anastomotic technique. We observed a lower rate following handsewn anastomosis compared with stapled anastomosis (72% vs. 81%;  $P=0.001$ ), consistent with other studies [5, 6, 13, 21]. Although stapled anastomosis was a risk factor for advanced lesions in the cuff, two of the four cases of cuff cancer occurred after handsewn anastomosis. This emphasizes that, although the overall risk of developing a cuff adenoma is lower after mucosectomy, leaving fragments of at-risk rectal mucosa buried outside the serosa of the pouch is a disadvantage when performing surveillance. After a stapled anastomosis, the at-risk rectal mucosa can be visualized and adenomas can be resected before they develop into cancer.

We found that in the first 10 years, the vast majority of patients had no or few pouch adenomas (► Fig. 3a). This supports a reduction in the surveillance frequency for most patients in the first 10 years. We demonstrated that the phenotype of the pouch recorded prior to finishing 10 years of surveillance could stratify the future risk of advanced lesions in both the cuff and pouch body beyond 10 years. This provides the opportunity for risk assessment at this point, to personalize clinical practice so that those at lower risk of advanced lesions can receive less intensive surveillance than those at high risk.

Studies assessing an association between duodenal and pouch adenomas have either failed to control for pouch age [10, 13] or did not control for time as a confounding factor [10, 11, 14, 22–29], which is important because increasing age is the only consistent risk factor for duodenal disease [30]. We took into account both of these confounders and observed that the severity of duodenal disease (Spigelman stage) was not a significant risk factor for the development of adenomas or advanced lesions in the cuff or pouch body.

There is good evidence of genotype–phenotype correlation with respect to some manifestations of FAP, but no such correlation with pouch neoplasia has been consistently identified. In our study, a 3' *APC* pathogenic variant appeared to be associated with cuff advanced lesions. We acknowledge the modest size of the group with a 3' *APC* pathogenic variant ( $n=20$ ) and the wide confidence intervals for this statistical association. This group of patients generally has a milder colorectal phenotype and elevated risk of desmoid, so are less likely to be advised to undergo RPC. The association with advanced lesions in the cuff is surprising and we are unable to provide a plausible biological explanation.

Gastric adenomas have been reported as a risk factor for pouch adenomas [10]; we did not explore this manifestation of FAP as only 23 patients (9%) in our cohort had a gastric adenoma. Although an association between the colonic phenotype and subsequent pouch body and cuff adenomas has been explored previously [12, 14, 31], we did not examine this as we use the colonic phenotype as a major determining factor of whether RPC is recommended, which would result in bias.

Pouch body cancer is rare and literature reviews have identified up to 23 cases [8, 9]. From these publications, pouch body cancers were diagnosed between 3 and 11 years after pouch construction [14, 32–37]. The true incidence is very difficult to estimate.

To our knowledge, this is the only study which has sought to identify patients at risk of developing advanced lesions in the pouch body or cuff. Given that most patients will develop pouch adenomas eventually, there is a need to identify more precisely those most at risk of developing advanced lesions. We observed that adenomas with a diameter of 10 mm preceded development of HGD or cancer; such lesions were generally not seen before 10 years.

Our cohort demonstrates that most patients develop at least one adenoma in the pouch body. All had LGD except for one case of invasive pouch body cancer that developed in a patient with both FAP and ulcerative colitis who received suboptimal surveillance and was on azathioprine for “pouchitis” (the effect of this on adenoma progression is unknown).

A current clinical challenge in patients with a pouch is to determine accurately when a pouch with many adenomas or advanced lesions should be removed to prevent cancer. Two cases of cuff cancer were diagnosed after a decision to perform pouch excision had been made owing to circumferential cuff lesions. Similarly, HGD was identified in an excised lesion after pouch excision for a circumferential adenoma.

There are limitations to our study. Despite being the largest European cohort, this is a single-center study, so some subanalyses were small. Although endoscopic practice has evolved considerably, improving adenoma detection, this leads to bias over time towards increased adenoma detection. Surveillance practice was inconsistent; pouch surgery was pioneered in 1978, but annual pouchoscopy was introduced in 1997. Some patients were referred to our center without prior surveillance and others were referred following adenoma detection.

Considering the study timespan and cohort size, procedures were performed by many endoscopists and consequently there was variability in reporting outcomes. When numerous polyps were removed, the report did not always reliably describe the exact number. We accept that the removal of adenomas alters the natural history of the development of advanced lesions.

Although a few patients may have participated in studies of chemoprevention for duodenal disease, a recent large study found sulindac to have no effect on prevention of cuff adenomas [5]. Given the use of chemoprevention is likely to have affected few patients over a short time, we have not included these data.

In conclusion, we have demonstrated that the vast majority of patients do not develop an adenoma within 5 years of pouch formation and that the development of HGD and cancer are rare events. The greatest risk appears to occur after 10 years, suggesting that surveillance in the first 10 years could be reduced for most patients, provided they have early engagement in the surveillance program. The pouch phenotype in the first decade stratified patients into high and lower risk groups for the future development of advanced lesions; risk may be assessed at 10 years to allow for a personalized surveillance strategy and the extension of surveillance intervals in the low risk group.

Multicenter prospective studies are required to better assess the influence of interventions on the natural history of pouch adenomas and to validate the safety of extending the surveillance intervals beyond those in current guidelines.

## Competing Interests

The authors declare that they have no conflict of interest.

## Funding

Medical Research Council HDR-UK | UKRI Rutherford Fund Fellowship National Institutes of Health | P30 CA023100  
Royal College of Surgeons/Bowel Cancer UK | Research fellowship National Institutes of Health | P30 CA023100  
AGA Research Foundation AGA Research Scholar Award | AGA2022-13-05

## References

- [1] Tudyka VN, Clark SK. Surgical treatment in familial adenomatous polyposis. *Ann Gastroenterol* 2012; 25: 201–206
- [2] Sinha A, Tekkis PP, Rashid S et al. Risk factors for secondary proctectomy in patients with familial adenomatous polyposis. *Br J Surg* 2010; 97: 1710–1715
- [3] Parks AG, Nicholls RJ. Proctocolectomy without ileostomy for ulcerative colitis. *BMJ* 1978; 2: 85–88
- [4] Heald RJ, Allen DR. Stapled ileo-anal anastomosis: a technique to avoid mucosal proctectomy in the ileal pouch operation. *Br J Surg* 1986; 73: 571–572
- [5] Lee CHA, Kalady MF, Burke CA et al. Incidence and management of rectal cuff and anal transitional zone neoplasia in patients with familial adenomatous polyposis. *Dis Colon Rectum* 2021; 64: 977–985
- [6] von Roon AC, Will OC, Man RF et al. Mucosectomy with handsewn anastomosis reduces the risk of adenoma formation in the anorectal segment after restorative proctocolectomy for familial adenomatous polyposis. *Ann Surg* 2011; 253: 314–317
- [7] Ganschow P, Treiber I, Hinz U et al. Residual rectal mucosa after stapled vs. handsewn ileal J-pouch-anal anastomosis in patients with familial adenomatous polyposis coli (FAP)—a critical issue. *Langenbecks Arch Surg* 2015; 400: 213–219
- [8] Smith JC, Schaffer MW, Ballard BR et al. Adenocarcinomas after prophylactic surgery for familial adenomatous polyposis. *J Cancer Ther* 2013; 4: 260–270
- [9] Tajika M, Niwa Y, Bhatia V et al. Risk of ileal pouch neoplasms in patients with familial adenomatous polyposis. *World J Gastroenterol* 2013; 19: 6774–6783
- [10] Ganschow P, Trauth S, Hinz U et al. Risk factors associated with pouch adenomas in patients with familial adenomatous polyposis. *Dis Colon Rectum* 2018; 61: 1096–1101
- [11] Parc YR, Olschwang S, Desaint B et al. Familial adenomatous polyposis: prevalence of adenomas in the ileal pouch after restorative proctocolectomy. *Ann Surg* 2001; 233: 360–364
- [12] Tajika M, Nakamura T, Nakahara O et al. Prevalence of adenomas and carcinomas in the ileal pouch after proctocolectomy in patients with familial adenomatous polyposis. *J Gastrointest Surg* 2009; 13: 1266–1273
- [13] Goldstein AL, Kariv R, Klausner JM et al. Patterns of adenoma recurrence in familial adenomatous polyposis patients after ileal pouch-anal anastomosis. *Dig Surg* 2015; 32: 421–425
- [14] Tonelli F, Ficari F, Bargellini T et al. Ileal pouch adenomas and carcinomas after restorative proctocolectomy for familial adenomatous polyposis. *Dis Colon Rectum* 2012; 55: 322–329
- [15] Kariv R, Rosner G, Fliss-Isakov N et al. Genotype-phenotype associations of APC mutations with pouch adenoma in patients with familial adenomatous polyposis. *J Clin Gastroenterol* 2019; 53: e54–e60
- [16] Monahan KJ, Bradshaw N, Dolwani S et al. Guidelines for the management of hereditary colorectal cancer from the British Society of Gastroenterology (BSG)/Association of Coloproctology of Great Britain and Ireland (ACPGBI)/United Kingdom Cancer Genetics Group (UKCGG). *Gut* 2020; 69: 411–444
- [17] McLaughlin SD, Clark SK, Thomas-Gibson S et al. Guide to endoscopy of the ileo-anal pouch following restorative proctocolectomy with ileal pouch-anal anastomosis; indications, technique, and management of common findings. *Inflamm Bowel Dis* 2009; 15: 1256–1263
- [18] Anderson JR, Cain KC, Gelber RD. Analysis of survival by tumor response. *J Clin Oncol* 1983; 1: 710–719
- [19] Gleiss A, Oberbauer R, Heinze G. An unjustified benefit: immortal time bias in the analysis of time-dependent events. *Transpl Int* 2018; 31: 125–130
- [20] Boostrom SY, Mathis KL, Pendlimari R et al. Risk of neoplastic change in ileal pouches in familial adenomatous polyposis. *J Gastrointest Surg* 2013; 17: 1804–1808
- [21] Wasmuth HH, Tranø G, Myrvold HE et al. Adenoma formation and malignancy after restorative proctocolectomy with or without mucosectomy in patients with familial adenomatous polyposis. *Dis Colon Rectum* 2013; 56: 288–294
- [22] Friederich P, de Jong AE, Mathus-Vliegen LM et al. Risk of developing adenomas and carcinomas in the ileal pouch in patients with familial adenomatous polyposis. *Clin Gastroenterol Hepatol* 2008; 6: 1237–1242
- [23] Banasiewicz T, Marciniak R, Kaczmarek E et al. The prognosis of clinical course and the analysis of the frequency of the inflammation and dysplasia in the intestinal J-pouch at the patients after restorative proctocolectomy due to FAP. *Int J Colorectal Dis* 2011; 26: 1197–1203
- [24] Pommaret E, Vienne A, Lefevre JH et al. Prevalence and risk factors for adenomas in the ileal pouch and the afferent loop after restorative proctocolectomy for patients with familial adenomatous polyposis. *Surg Endosc* 2013; 27: 3816–3822
- [25] Schulz AC, Bojarski C, Buhr HJ et al. Occurrence of adenomas in the pouch and small intestine of FAP patients after proctocolectomy with ileoanal pouch construction. *Int J Colorectal Dis* 2008; 23: 437–441
- [26] Thompson-Fawcett MW, Marcus VA, Redston M et al. Adenomatous polyps develop commonly in the ileal pouch of patients with familial adenomatous polyposis. *Dis Colon Rectum* 2001; 44: 347–353
- [27] Zahid A, Kumar S, Koorey D et al. Pouch adenomas in familial adenomatous polyposis after restorative proctocolectomy. *Int J Surg* 2015; 13: 133–136
- [28] Campos FG, Perez RO, Imperiale AR et al. Surgical treatment of familial adenomatous polyposis: ileorectal anastomosis or restorative proctocolectomy? *Arq Gastroenterol* 2009; 46: 294–299
- [29] Moussata D, Nancey S, Lapalus MG et al. Frequency and severity of ileal adenomas in familial adenomatous polyposis after colectomy. *Endoscopy* 2008; 40: 120–125
- [30] Bulow S, Bjork J, Christensen IJ et al. Duodenal adenomatosis in familial adenomatous polyposis. *Gut* 2004; 53: 381–386
- [31] Remzi FH, Church JM, Bast J et al. Mucosectomy vs. stapled ileal pouch-anal anastomosis in patients with familial adenomatous polyposis: functional outcome and neoplasia control. *Dis Colon Rectum* 2001; 44: 1590–1596

- [32] Bassuini MM, Billings PJ. Carcinoma in an ileoanal pouch after restorative proctocolectomy for familial adenomatous polyposis. *Br J Surg* 1996; 83: 506
- [33] Palkar VM, deSouza LJ, Jagannath P et al. Adenocarcinoma arising in "J" pouch after total proctocolectomy for familial polyposis coli. *Indian J Cancer* 1997; 34: 16–19
- [34] Cherki S, Glehen O, Moutardier V et al. Pouch adenocarcinoma after restorative proctocolectomy for familial adenomatous polyposis. *Colorectal Dis* 2003; 5: 592–594
- [35] Linehan G, Cahill RA, Kalimuthu SN et al. Adenocarcinoma arising in the ileoanal pouch after restorative proctocolectomy for familial adenomatous polyposis. *Int J Colorectal Dis* 2008; 23: 329–330
- [36] Lee SH, Ahn BK, Chang HK et al. Adenocarcinoma in ileal pouch after proctocolectomy for familial adenomatous polyposis: report of a case. *J Korean Med Sci* 2009; 24: 985–988
- [37] Tajika M, Nakamura T, Bhatia V et al. Ileal pouch adenocarcinoma after proctocolectomy for familial adenomatous polyposis. *Int J Colorectal Dis* 2009; 24: 1487–1489