

DONOVANOSIS OF THE ANUS IN THE MALE* AN EPIDEMIOLOGICAL CONSIDERATION

BY

MILTON MARMELL

From the Department of Pathology of the Harlem Hospital, New York City. (Dr. Vera B. Dolgopol, Director of Pathology.)

Donovanosis, also known as granuloma inguinale, granuloma venereum, and by other names (Marmell and Santora, 1950), is a chronic specific infection manifested clinically by ulcerating granulomatous lesions involving, in the majority of cases, the skin and subcutaneous tissues. Although these manifestations are generally limited to the genitalia and adjacent areas, the lesions may appear—both as primary sites of infection and as the results of auto-inoculation and lymphogenic spread—in other parts of the body, including the viscera and skeleton. The specific agent that causes this disease is *Donovania granulomatis*, a bacterial organism of distinct morphology, commonly known as the Donovan body. The disease is diagnosed by the demonstration of *D. granulomatis* in tissue cells from the lesions. Donovanosis is endemic in tropical and subtropical regions, particularly in Asia and the Americas.

Although donovanosis has been known as a clinical entity since 1896, the epidemiology of the infection has remained largely without clarification (Rajam and Rangiah, 1954). The incubation period of the naturally acquired infection, the factors involved in racial and individual susceptibility, and the mode of infection and manner of transmission are not established. Whether it is venereal or non-venereal in nature has been debated from the early history of the disease to the present day. The epidemiological unknowns have led even to the hypothesis that donovanosis may exhibit two different characteristics from the epidemiological point of view: venereal in certain conditions and non-venereal in others (Forkner, Coats, Grace, Rake, and Speiser, 1955).

Although donovanosis is no longer as common as before the advent of antibiotic therapy, the elucidation of the epidemiology of the infection is important both from the academic and from the public health point of view. With this in mind, we present histories of ten patients with donovanosis who had lesions of the anus, without any involvement of the genitals. Similar cases found in the literature are reviewed and the possible implication that anal donovanosis may have in the venereal transmission of the disease is discussed.

Since 1947, 61 men with donovanosis have been observed by the author in the Hospital of the New York Department of Correction and in Harlem Hospital. Of these patients, 51 had lesions of the genitals and/or the groin, and ten had lesions of the anus without any genital manifestations of the infection. In all patients the diagnosis was established by the demonstration of *D. granulomatis* in tissue smears stained with Wright or Giemsa stains. The methods of obtaining the specimens and preparation of the smears have been previously described (Marmell and Santora, 1950).

Case Reports

Case 1, a 30-year-old coloured man, was admitted to the Hospital of the Department of Correction because of an anal ulcer of 5 years' duration. The lesion began as an itching nodule in the right perianal region. Scratching of this nodule to relieve the pruritus produced excoriation and the spread of the lesion. At the time of examination, an area approximately 8 cm. in diameter was involved. The lesion was painless, but gave discomfort because of pruritus and constant moisture from the sero-sanguinous exudate (Fig. 1, overleaf).

Questioning revealed that the patient had been born in Virginia and had come to New York 6 months before his

* Received for publication March 11, 1958.

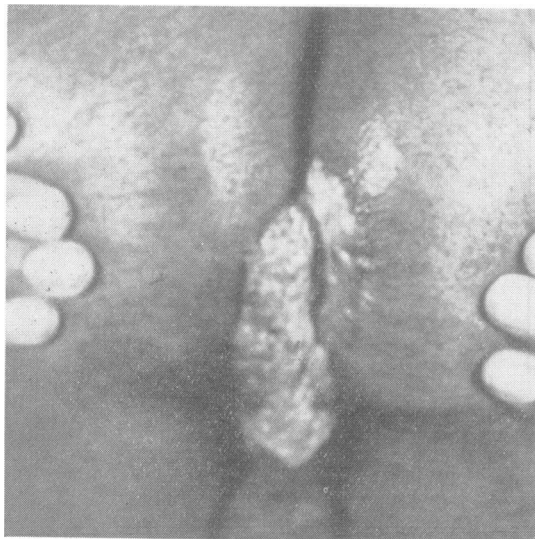


FIG. 1.—Case 1.

arrest and admission to the Hospital. He admitted to pederasty while he was incarcerated in a penal institution in a Southern State. The lesion had appeared 6 months after his confinement to the "chain gang".

Case 2, a 22-year-old Puerto Rican, was admitted to the Hospital of the Department of Correction because of an extensive anal lesion of 6 months' duration. The lesion began as a nodule on the perineum adjacent to the anus. Scratching caused ulceration and the spread of the lesion. Examination revealed a secondarily infected, foul-smelling ulcer about 7 cm. across and 5 cm. in length, encircling the lower half of the anal orifice.

On interrogation, the patient freely admitted homosexual practice since the age of 16, always taking the passive role. The lesion did not prevent frequent homosexual relations. He did not seek medical attention, but was diagnosed and treated after his arrest for loitering and indecent exposure. By occupation, this man was a short-order cook in a lunch room.

Case 3, a 29-year-old coloured man, was admitted to the Harlem Hospital because of an anal ulcer of 4 months' duration (Fig. 2). The lesion was noted by the patient 3 days after passive homosexual intercourse as a small "cut" in which defecation produced a stinging sensation. The fissure healed, according to the patient, upon treatment with "nupercainal ointment", but 3 weeks later it reappeared and increased in size. Examination revealed a moist, ulcerative, granulatous lesion, moderately painful, occupying an area of 2.5 by 6 cm. on the left buttock, in the perianal region, and a similar, though smaller, lesion on the right side.

The patient, who was from North Carolina, but had lived in New York City since early childhood, admitted passive pederasty since he was "a young boy—as long as I can remember".

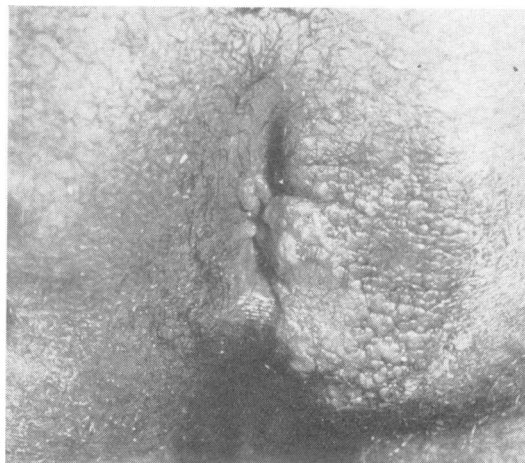

FIG. 2.—Case 3.

Case 4, a 41-year-old Puerto Rican, was admitted to the Harlem Hospital with an itching mass of 8 years' duration in the anal region. Examination revealed a cauliflower-like mass about 7 by 5 by 7 cm., extending from the left lateral and anterior margin of the anus to the median raphe (Fig. 3).

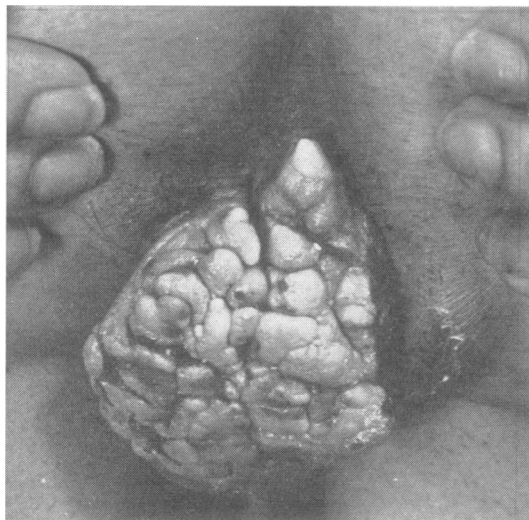


FIG. 3.—Case 4.

The patient, a dancer and entertainer by profession, had first noted the lesion as a "little bump". During the ensuing years, the nodule had increased in size. Questioning elicited the following statement: "I was born a homosexual and had my first intercourse with a man when I was 14 years old. I always play the passive role. I get no pleasure out of a woman. I wish I was born a woman".

Case 5, a 40-year-old Negro, was admitted to the Harlem Hospital because of an anal ulcer of 7 months' duration. Examination revealed opposing (kissing) ulcerations of the buttocks about 3 by 6 cm. in diameter. The patient admitted to passive pederasty when under the influence of liquor at "wild parties". The present lesions had developed about 10 days to 2 weeks after such a party.

The patient stated that he was "sickly" as a boy and had been treated for tuberculosis for 2 years, from the age of 9 to 11. He had been circumcised at the age of 7 "to help me grow".

Case 6, a 30-year-old coloured man, was admitted to the Harlem Hospital with an anal lesion of 4 months' duration. The lesion had appeared as a protrusion from the anus 7 days after rectal intercourse. Examination revealed a granulomatous, painless, itching lesion on the inner aspect of the left buttock, slightly above the anus. The lesion was 1 cm. wide by 4 cm. long. Adjacent to this was another granulomatous lesion 0.5 by 1.5 cm. on the perineum (Fig. 4).

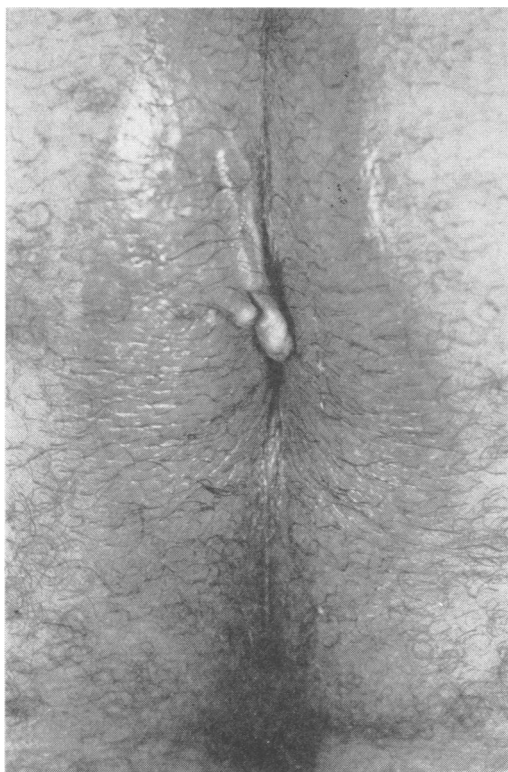

FIG. 4.—Case 6.

The patient, who was born in New York State, and had lived there all his life, admitted to passive homosexual practices since the age of 17. Since that time, he had felt that he should have been a woman. His main source of income was from prostitution with males.

Case 7, a 31-year-old Negro, was admitted to the Harlem Hospital because of ulceration in the anal region and thigh of 5 years' duration. On examination an indurated granulomatous growth was found on the right side of the anus. This lesion measured 2.5 by 3.5 cm. It was tender and bled on touch. Another large, irregular lesion on the inner surface of the right thigh measured 7 by 4 cm. It was exquisitely tender and bled profusely when rubbed. Although both areas had the clinical appearance of donovanosis, *D. granulomatis* was demonstrated in the anal lesion only (Fig. 5).

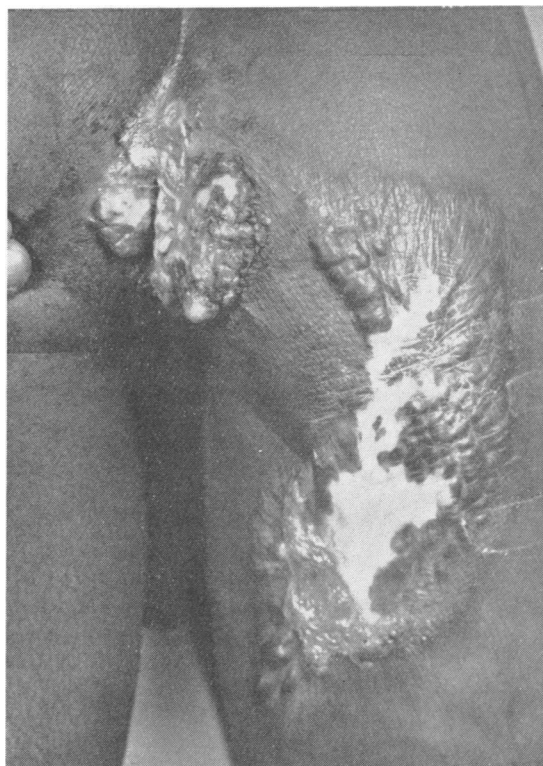


FIG. 5.—Case 7.

The patient, a native of Georgia, admitted to solely passive homosexual practices since the age of 15. He stated that he had never had any sexual desire for the opposite sex and had never indulged in sexual activities with a woman.

Case 8, a 22-year-old coloured man, was admitted to the Harlem Hospital because of a growth around the anal region of about 9 months' duration. Examination revealed a cauliflower-like condylomatous lesion 9 cm. in diameter. The lesion appeared as an itching nodule about 4 weeks after passive homosexual intercourse while the patient was in the State of South Carolina. The

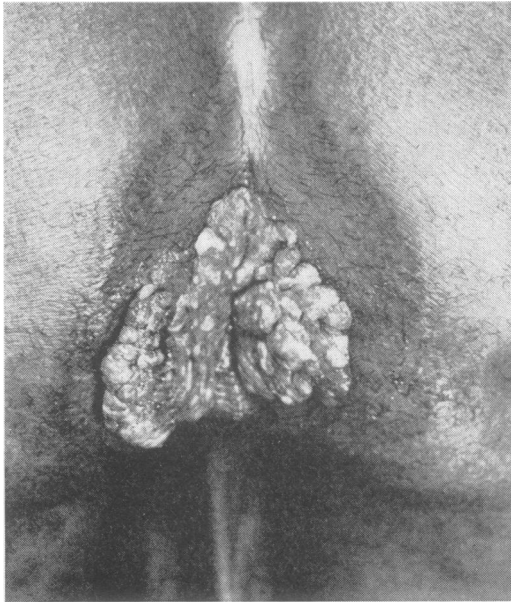


FIG. 6.—Case 8.

nodule had increased in size and became moderately painful, and for 2 months before examination had prevented sexual activity (Fig. 6).

The patient, who stuttered, was born in South Carolina, where he had been seduced, at the age of 8, by an 11-year-old boy. Since then he had indulged in homosexual activities to the exclusion of heterosexual intercourse (see Case 9).

Case 9, a 22-year-old Negro, was admitted to the Harlem Hospital because of an anal sore of 6 months' duration. Examination revealed a flat, granular condyloma 3 cm. wide and 5 cm. long on the inner aspect of the right buttock, adjacent to the anus (Fig. 7). The patient was born in South Carolina, which state he was revisiting when the lesion appeared a few days following homosexual intercourse. He admitted pederasty since the age of 8.

It is interesting to note that Case 8 and Case 9 were friends and lived together both in New York City and in South Carolina. The external evidence of donovanosis appeared in these two men 3 months apart. Both denied having had sex relations with each other, but admitted the possibility that they might have had the same partner.

Case 10, a 21-year-old, unmarried, white man, a hair-dresser by occupation, was admitted to the Harlem Hospital complaining of pain in the rectum. 4 years earlier, he had developed perianal lesions which had been diagnosed by biopsy at another hospital as donovanosis, and a year later a diverting colostomy had been performed. The patient, at that time, was inadequately treated with streptomycin and chlortetracycline.

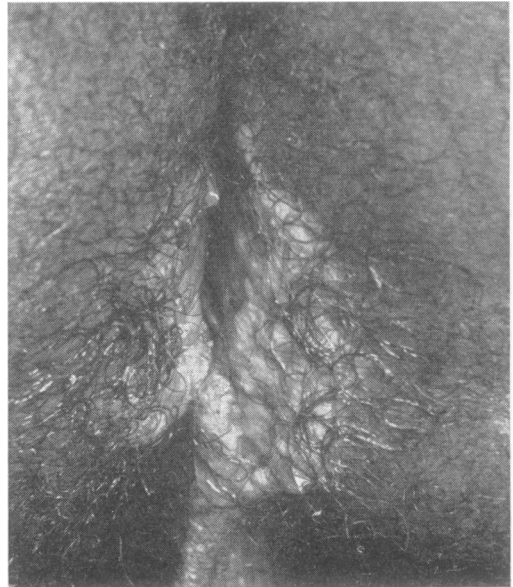


FIG. 7.—Case 9.

On admission to the Harlem Hospital, physical examination revealed a thin, white male, in physical and mental distress. There was a functioning colostomy. A large granular lesion had invaded the anus, rectum, and left buttock. There were numerous sinuses and abscesses in the groins, scrotum, buttock and leg (Fig. 8, opposite).

This patient vehemently denied any homosexual practices, stating that they were contrary to his religious convictions. Furthermore, he stated, sex meant little to him and his infrequent sex experiences were with women he had known for months and years and who were not diseased. He attributed his condition to infection with sand while bathing on a New York City beach.

Discussion

The role of the homosexual male in the spread of venereal disease is well recognized. Anorectal infection with *Treponema pallidum*, *Neisseria gonorrhoeae*, and the virus of lymphogranuloma venereum is generally preceded by homosexual practices in the form of passive pederasty. Cases of anal donovanosis culled from the literature also show, in most cases, a history of admitted pederasty (Table, opposite). Of a total of 48 patients reported in the literature, for whom epidemiological data are given, 44 admitted pederasty and only four denied such practices. Similarly, among our own patients, nine out of ten patients admitted pederasty. There are thus 58 recorded patients with anal lesions, of whom 53 admitted and five denied homosexual activity.

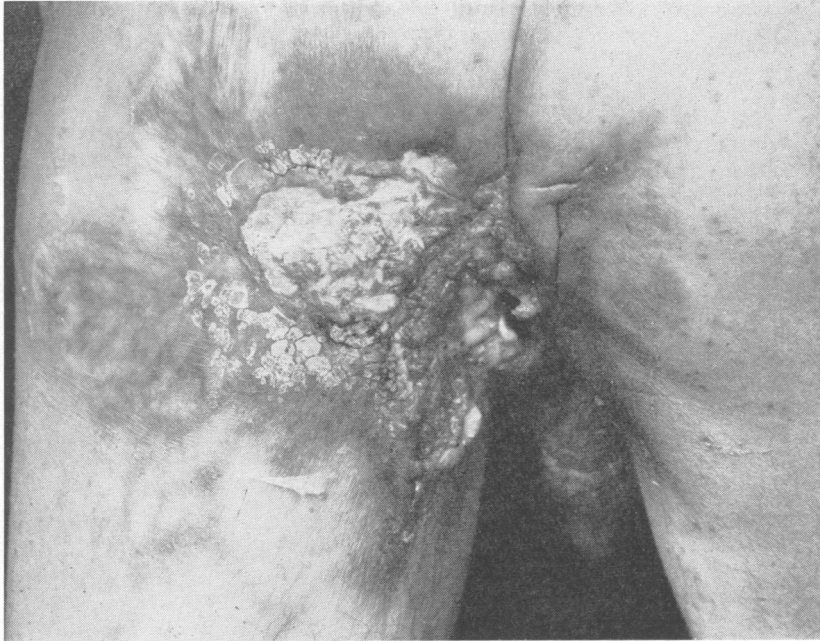

FIG. 8.—Case 10.

TABLE
PEDERASTY AND ANAL DONOVANOSIS IN MALE CASES
FOUND IN LITERATURE†

Author	Date	Number of Patients	
		Denied Pederasty	Admitted Pederasty
McKenney	1930	1	
Reed	1931	1	
Goldberg	1945	1	
Jennison, Helwig, and Milstone	1947	1	
Roffo and Zarate	1916		1
de Souza	1933		1
Rajam	1936		2
Wilson	1948		6*
Marshak, Barton, and Bauer	1948		3
Rajam and Rangiah .. .	1954		28
Gault	1955		3
Present Study	1958	1	9
Total		5	53

* Two contacts traced and found to have donovanosis of penis and groin.

† Three additional cases of anal donovanosis in admitted sodomists not listed in this Table were reported by Serma (1957).

The five patients who denied pederasty were:

- (1) A soldier who was accused of pederasty along with a group of other soldiers in his barracks, and the

only one of this group to escape a court martial verdict of guilty of sodomy (Jennison, Helvig, and Milstone, 1947);

- (2) A 25-year-old coloured, unmarried soldier stationed in a camp in the Southern United States and the China-Burma-India theatre of operations during World War II (Goldberg, 1945)
- (3) A 29-year-old white, unmarried seaman plying the tropical seas (Reed, 1931);
- (4) A 27-year-old coloured, unmarried man in the State of Alabama (McKenney, 1940);
- (5) Our own patient, a 29-year-old white, unmarried man who operated a hair-dressing establishment, and to whom "marriage as well as sex in general does not mean much".

Considering the attitude of Western Civilizations towards homosexual practices, it is understandable that some patients should be unwilling to admit pederasty. Natural reticence may be involved, but fear of the police, fear of the army courts martial, fear of the loss of job or prestige, fear of being branded a "security risk", among other factors, are powerful and, at times, insurmountable deterrents to an admission of homosexuality.

Regardless of our opinion as to the veracity of the five patients who denied pederasty, the association of anal donovanosis in the male with admitted homosexual activity is marked, and appears to suggest in this disease a causal relationship as it does in syphilis, gonorrhoea and lymphogranuloma

venereum. This view appears to be more plausible than some other considered modes of transmission, such as the transfer of the infecting agents by means of infected insects (Butts, 1937; Butts and Olansky, 1946), infected animals (Cleland and Hickinbotham, 1909), contaminated water (Curjel, 1917), or the invasion of traumatized tissues by a bacterium of intestinal origin (Rake, 1948).

The fact that patients with anal donovanosis practise passive pederasty does not, *per se*, constitute proof of the venereal transmission of the disease, and it is not here presented as such. It does, however, present another link in the chain of evidence arguing for such transmission.

The reasons for the seeming variable period of incubation of the disease still await elucidation, and the fact that symptoms of the disease rarely appear in coital partners of donovanosis patients still requires explanation. These problems, however, need not necessarily be concerned with the transmission of donovanosis.

We believe that the answer to these questions can be found in the study of the pathogenesis of donovanosis. The natural history of the infection shows characteristics that may well account for the variations noted in the time of incubation and in infectivity.

Summary

In the examination of 61 men with donovanosis, 51 were found to have genital and/or inguinal lesions

and ten had anal lesions only without any involvement of the genitals or groin. Nine of these ten patients admitted homosexual practices in the form of passive pederasty and one denied such practices.

Of 48 patients with anal donovanosis described in the literature, for whom any epidemiological data were presented, 44 admitted pederasty.

This association of anal donovanosis with pederasty suggests venereal transmission of the disease.

Appreciation is expressed to Mr. Edward Entin for taking the photographs.

REFERENCES

- Butts, D. C. A. (1937). *Amer. J. Syph.*, **21**, 544.
 — and Olansky, S. (1946). *Arch. Derm. Syph.*, **54**, 524.
 Cleland, J. B., and Hickinbotham, J. R. (1909). *J. trop. Med. Hyg.*, **12**, 143.
 Curjel, D. F. (1917). *Indian med. Gaz.*, **52**, 305.
 de Souza, T. (1933). *Rev. Ginec. Obstet. (Rio de J.)*, **27**, 190.
 Forkner, C. E., Coats, E. C., Grace, A. W., Rake, G. W., and Speiser, M. D. (1955). *N. Y. Med.*, **11**, 694.
 Gault, E. I. (1955). *J. Indian med. Ass.*, **25**, 157.
 Goldberg, L. C. (1945). *Amer. J. Syph.*, **29**, 608.
 Jennison, D. B., Helwig, E. B., and Milstone, J. H. (1947). *Arch. Derm. Syph.*, **55**, 342.
 McKenney, D. C. (1930). *Trans. Amer. proctol. Soc.*, **31**, 34.
 Marmell, M., and Santora, E. (1950). *Amer. J. Syph.*, **34**, 83.
 Marshak, L., Barton, R. L., and Bauer, T. J. (1948). *Arch. Derm. Syph.*, **57**, 858.
 Rajam, R. V. (1936). *Indian med. Gaz.*, **71**, 525.
 — and Rangiah, P. N. (1954). "Donovanosis (Granuloma Inguinale Granuloma Venereum)". World Health Organization Monograph Series No. 24, Geneva.
 Rake, G. (1948). *Amer. J. Syph.*, **32**, 150.
 Reed, A. C. (1931). *New Engl. J. Med.*, **204**, 1364.
 Roffo, A. H., and Zarate, J. T. (1916). *Rev. Asoc. méd. Argent.*, **24**, 293.
 Serma, J. S. (1957). *Indian J. Derm. Venereol.*, **23**, 9.
 Wilson, W. W. (1948). *Sth. med. J. (Bgham, Ala.)*, **41**, 412.