
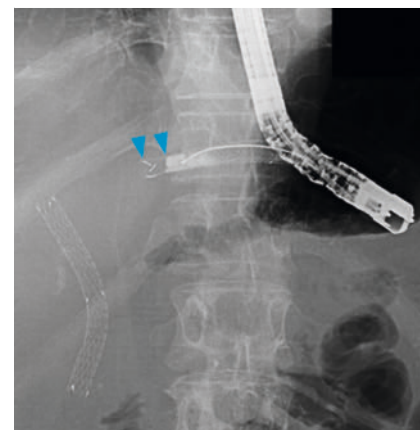




# Piercing technique for mucosal hyperplasia at an uncovered part of a partially covered stent after endoscopic ultrasound-guided hepaticogastrostomy



**► Fig. 1** **a** A partially covered self-expandable metal stent (Modified Giobor Stent; Taewoong Medical, Seoul, South Korea) made of braided nitinol wire partially covered by a silicone membrane. The proximal end has a 10-mm uncovered portion. **b** Endoscopic view of the partially covered metal stent in the gastric lumen after endoscopic ultrasound-guided hepaticogastrostomy.



**► Fig. 2** The uncovered part of the partially covered metal tent was not imaged by contrast medium injection (arrowheads), indicating a complete recurrent biliary obstruction due to hyperplasia.

A partially covered self-expandable metal stent (PCSEMS) is preferred in endoscopic ultrasound-guided hepaticogastrostomy (EUS-HGS) to prevent stent dislocation and branch duct occlusion [1, 2]. A PCSEMS with a 10-mm uncovered part on the proximal end (Modified Giobor Stent; Taewoong Medical, Seoul) (► Fig. 1a) has been used frequently [2, 3]; however, tissue hyperplasia occurs around the uncovered part, leading to recurrent biliary obstruction (RBO) [2, 3]. RBO due to hyperplasia is sometimes hardened with abundant fibrosis, resulting in failed guidewire passage during endoscopic reintervention [3,4]. Here, we present a novel technique to regain biliary access after EUS-HGS with subsequent hyperplasia with the uncovered portion of the PCSEMS.

A 67-year-old male with a history of distal gastrectomy with Roux-en-Y reconstruction was admitted due to jaundice. The patient had undergone EUS-HGS with the PCSEMS for biliary obstruction due to lymph node metastasis 8 months before admission (► Fig. 1b). To relieve

jaundice, reintervention via the distal end of the PCSEMS was performed. A cannulation catheter was inserted from the distal end of the PCSEMS, but a 0.035-inch guidewire (Jagwire; Boston

Scientific, Natick, Massachusetts, United States) could not be advanced beyond the PCSEMS. The uncovered part of the PCSEMS was not imaged by contrast medium injection, indicating a complete

**▶ VIDEO**

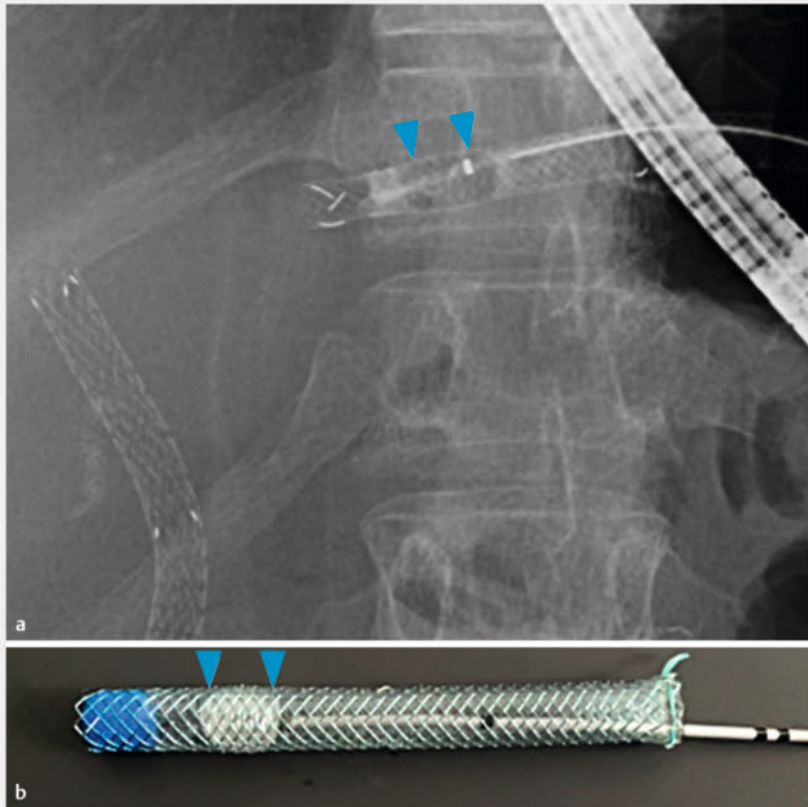
Piercing technique for mucosal hyperplasia at an uncovered part of a partially covered metal stent after endoscopic ultrasound-guided hepaticogastrostomy

▶

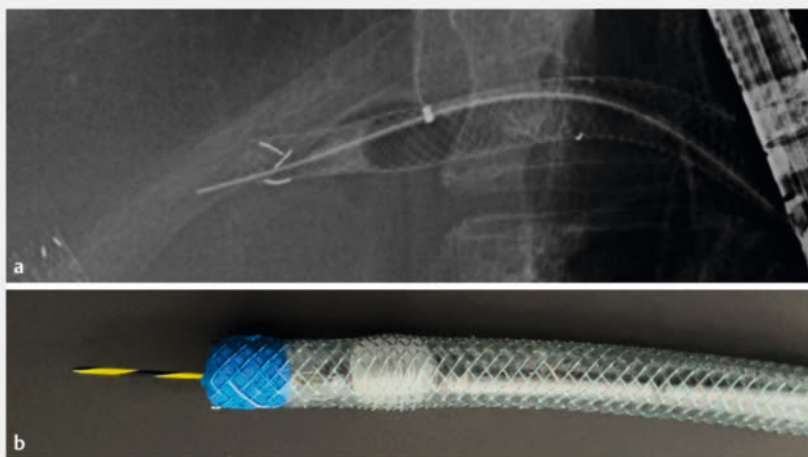
Yasuo Otsuka; Kosuke Minaga; Akane Hara; Yasuhiro Masuta; Mamoru Takenaka; Masatoshi Kudo

Department of Gastroenterology and Hepatology, Kindai University Faculty of Medicine

► **Video 1** Endoscopic reintervention using a “piercing technique” for mucosal hyperplasia after endoscopic ultrasound-guided hepaticogastrostomy.



► **Fig. 3** A stone extraction balloon (Fusion Extraction Balloon; Cook Medical, Bloomington, Indiana, United States) was inflated inside the partially covered metal stent to allow passage of the guidewire through the center of the stent (**a** fluoroscopic view, **b** diagram).





► **Fig. 4** In a “piercing technique,” the stiff back end of a 0.035-inch guidewire (Jagwire; Boston Scientific, Natick, Massachusetts, United States) was used, which enabled the smooth advancement of the guidewire beyond the hyperplasia at the proximal end of the stent (**a** fluoroscopic view, **b** diagram).

RBO due to hyperplasia (► **Fig. 2**). Next, a stone extraction balloon was inflated inside the PCSEMS to allow passage of the guidewire through the center of the PCSEMS (► **Fig. 3**). However, the hyperplasia was too stiff. Finally, a “piercing technique” using the stiff back end of the guidewire [5] was performed, which allowed the guidewire to smoothly advance the stricture (► **Fig. 4**, ► **Video 1**). After dilating the uncovered part with an 8-mm balloon dilator, a dedicated plastic stent was successfully deployed through the PCSEMS (► **Fig. 5**). The patient’s jaundice resolved after endoscopic revision and was discharged 6 days after admission.

### Conflict of Interest

The authors declare that they have no conflict of interest.

### The authors

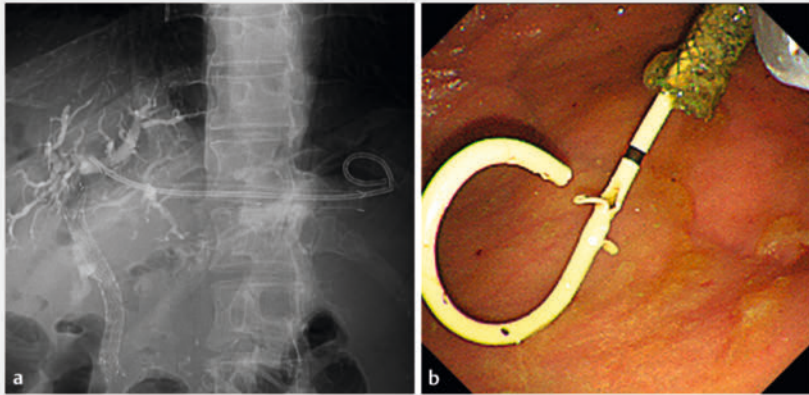
Yasuo Otsuka<sup>1</sup>, Kosuke Minaga<sup>1</sup> , Akane Hara<sup>1</sup>, Yasuhiro Masuta<sup>1</sup>, Mamoru Takenaka<sup>1</sup> , Masatoshi Kudo<sup>1</sup>

<sup>1</sup> Department of Gastroenterology and Hepatology, Kindai University Faculty of Medicine, Osaka-Sayama, Japan

### Corresponding author

**Dr. Kosuke Minaga**

Kindai University Faculty of Medicine,  
Department of Gastroenterology and  
Hepatology, Osaka-Sayama, Japan  
kousukeminaga@yahoo.co.jp



► **Fig. 5** A dedicated 7F × 14-cm plastic stent (TYPE-IT Stent; Gadelius Medical, Tokyo, Japan) was successfully deployed through the existing partially covered metal stent (**a** fluoroscopic view, **b** endoscopic view).

## Bibliography

Endosc Int Open 2023; 11: E811–E813

DOI 10.1055/a-2132-5116

ISSN 2364-3722

© 2023. The Author(s).

This is an open access article published by Thieme under the terms of the Creative Commons Attribution-NonDerivative-NonCommercial License, permitting copying and reproduction so long as the original work is given appropriate credit. Contents may not be used for commercial purposes, or adapted, remixed, transformed or built upon. (<https://creativecommons.org/licenses/by-nc-nd/4.0/>)

Georg Thieme Verlag KG, Rüdigerstraße 14,  
70469 Stuttgart, Germany



## References

- [1] Minaga K, Kitano M. Recent advances in endoscopic ultrasound-guided biliary drainage. *Dig Endosc* 2018; 30: 38–47
- [2] Nakai Y, Sato T, Hakuta R et al. Long-term outcomes of a long, partially covered metal stent for EUS-guided hepaticogastrostomy in patients with malignant biliary obstruction (with video). *Gastrointest Endosc* 2020; 92: 623–631
- [3] Minaga K, Kitano M, Uenoyama Y et al. Feasibility and efficacy of endoscopic reintervention after covered metal stent placement for EUS-guided hepaticogastrostomy: A multicenter experience. *Endosc Ultrasound* 2022; 11: 478–486
- [4] Matsubara S, Nakagawa K, Suda K et al. Radiofrequency ablation of hyperplasia at an uncovered portion of a partially covered metal stent in endoscopic ultrasound-guided hepaticogastrostomy (with video). *J Hepatobiliary Pancreat Sci* 2021; 28: e32–e33
- [5] Toyonaga H, Hayashi T, Katanuma A. Piercing technique via cholangioscopy for the reconstruction of complete anastomotic obstruction after choledochojejunostomy. *Dig Endosc* 2020; 32: e86–e88