



Direct Oral Anticoagulants for Cancer-Associated Venous Thromboembolism

Marta Masini¹ · Matteo Toma² · Paolo Spallarossa² · Italo Porto^{1,2} · Pietro Ameri^{1,2}

Accepted: 2 May 2023 / Published online: 6 June 2023
© The Author(s) 2023

Abstract

Purpose of Review To present the randomized controlled trial (RCT) evidence and highlight the areas of uncertainty regarding direct oral anticoagulants (DOAC) for cancer-associated venous thromboembolism (CAT).

Recent Findings In the last years, four RCTs have shown that rivaroxaban, edoxaban, and apixaban are at least as effective as low-molecular-weight heparin (LMWH) for the treatment of both incidental and symptomatic CAT. On the other hand, these drugs increase the risk of major gastrointestinal bleeding in patients with cancer at this site. Another two RCTs have demonstrated that apixaban and rivaroxaban also prevent CAT in subjects at intermediate-to-high risk commencing chemotherapy, albeit at the price of higher likelihood of bleeding. By contrast, data are limited about the use DOAC in individuals with intracranial tumors or concomitant thrombocytopenia. It is also possible that some anticancer agents heighten the effects of DOAC via pharmacokinetic interactions, up to making their effectiveness-safety profile unfavorable.

Summary Leveraging the results of the aforementioned RCTS, current guidelines recommend DOAC as the anticoagulants of choice for CAT treatment and, in selected cases, prevention. However, the benefit of DOAC is less defined in specific patient subgroups, in which the choice of DOAC over LMWH should be carefully pondered.

Keywords Anticoagulation · Thrombosis · Embolism · Cancer · Cardio-oncology

Introduction

In spite of major advances in oncological care, cancer-associated venous thromboembolism (CAT), including deep venous thrombosis (DVT) and pulmonary embolism (PE), remains highly prevalent in cancer patients, with substantial health and social costs [1].

It has been estimated that subjects with cancer face a 4- to 6- sixfold increased risk of venous thromboembolism (VTE) compared with the general population [2]. Tumors may initiate the coagulation cascade directly, by producing pro-coagulant molecules, or via secretion of mediators like pro-inflammatory cytokines, which activate the

endothelium and stimulate platelet aggregation. Malignant cells may also invade venous vessels, damage the vascular wall, and cause blood stasis with ensuing thrombosis [3]. Furthermore, anti-neoplastic therapies may trigger VTE: this is the case, for instance, with thalidomide and lenalidomide, BCR-ABL tyrosine kinase inhibitors, and agents targeting the vascular endothelial growth factor receptor [4]. Finally, oncological patients often have general risk factors for VTE, such as prolonged immobilization and indwelling central venous catheters.

From Low-Molecular-Weight Heparin to Direct Oral Anticoagulants for Cancer-Associated Venous Thromboembolism

Subcutaneous low-molecular-weight heparin (LMWH) was the recommended anticoagulant for CAT until a few years ago [5–7].

The use of this drug for CAT is grounded in a limited number of studies that enrolled in total around 2000 subjects [8–12], with two open-label randomized controlled trials

Marta Masini and Matteo Toma equally contributed to this work.

✉ Pietro Ameri
pietroameri@unige.it

¹ Department of Internal Medicine, University of Genova, Viale Benedetto XV, 6 - 16132 Genoa, Italy

² Cardiovascular Disease Unit, IRCCS Ospedale Policlinico San Martino, Genoa, Italy

(RCTs) with blinded outcome adjudication with dalteparin and tinzaparin accounting for 78% of all patients [8, 9]. Overall, the rate of recurrent CAT was consistently, but most often not significantly, lower with LMWH than with vitamin K antagonists (VKA); by contrast, the frequency of bleeding events was discordant across investigations (Table 1).

It is noteworthy that persistence on full-dose LMWH is low, due to inconvenience of subcutaneous administration for individuals who frequently already have to bear demanding therapies, fear of bleeding, and, in some countries, financial concerns [13]. Among 52,911 outpatients with newly diagnosed cancer who developed VTE and were prescribed LMWH between 2009 and 2014 in the USA, only 13% maintained such treatment over the following 6 months [14].

Direct oral anticoagulants (DOAC) were developed to overcome the erratic pharmacokinetics and pharmacodynamics of VKA, which blunt the coagulation system indirectly, by interfering with vitamin K–dependent synthesis of coagulation factors II, VII, IX, and X in the liver. As such, the effect of VKA is delayed, typically by 12 to 72 h, and influenced by genetically determined activity of hepatic enzymes, hepatocyte function, and endogenous and dietary vitamin K levels [15]. Instead, DOAC directly

inhibit coagulation factors Xa (edoxaban, rivaroxaban, and apixaban) or IIa (dabigatran). The onset of action of these medications is rapid, the relationship between systemic drug concentrations and degree of anticoagulation is predictable, and it is possible to use fixed doses without laboratory monitoring [16]. These characteristics lead to a better efficacy-safety profile as compared with VKA, which has made DOAC the oral anticoagulants of choice for a wide range of indications, including VTE.

The RCTs evaluating DOAC for VTE were conducted in unselected populations comprising small subgroups with active cancer [17–21]. Until recently, analyses of these subgroups [22–25] and retrospective studies [26–28] represented the evidence supporting the prescription of DOAC for CAT. DOAC appeared to be associated with fewer recurrences of VTE than LMWH or VKA and variable rates of bleeding. However, these data are flawed by methodological limitations, such as selection and confounding bias, comparison with either VKA or LMWH, and lack of information about cancer stage and treatment.

In the last years, the results of a series of RCTs have consolidated the indication of DOAC for CAT treatment, as well as prevention in cancer patients at high risk of

Table 1 Randomized controlled trials of anticoagulant therapy for cancer-associated venous thromboembolism

Study (Ref. #)	Duration	Tested LMWH	Recurrent VTE		Major bleeding	
			LMWH	VKA	LMWH	VKA
CLOT (8)	6 months	Dalteparin	27/336 (8%)	53/336 (15.8%)*	19/338 (5.6%)	12/335 (3.6%)
CATCH (9)	6 months	Tinzaparin	31/449 (6.9%)	45/451 (10%)	12/449 (2.7%)	11/451 (2.4%)
CANTHANOX (10)	3 months	Enoxaparin	2/71 (2.8%)	3/75 (4%)	5/71 (7%)	12/75 (16%)
ONCENOX (11)	6 months	Enoxaparin	4/61 (6.6%)	3/30 (10%)	6/67 (8.9%)	1/34 (2.9%)
LITE (12)	3 months	Tinzaparin	18/369 (4.9%)	21/368 (5.7%)	10/144 (6.9%)	13/146 (8.9%)
Study (Ref. #)	Duration	Tested DOAC	Recurrent VTE		Major bleeding	
			DOAC	dalteparin	DOAC	dalteparin
SELECT-D (29)	6 months	Rivaroxaban	8/203 (3.9%)	18/203 (8.9%)*	11/203 (5.4%)	6/203 (3%)
Hokusai VTE Cancer (30)	Up to 9 months	Edoxaban	41/522 (7.9%)	59/524 (11.3%)	36/522 (6.9%)	21/524 (4%)*
ADAM VTE (31)	6 months	Apixaban	0/145 (0%)	2/142 (1.4%)	1/145 (0.7%)	9/142 (6.3%)
Caravaggio (32)	6 months	Apixaban	32/576 (5.6%)	46/579 (7.9%)	22/576 (3.8%)	23/579 (4%)

The upper part of the table shows the frequency of recurrent venous thromboembolism (VTE) and major bleeding in randomized controlled trials comparing different types of low-molecular-weight heparin (LMWH) with vitamin K antagonists (VKA), while the lower part presents the same outcomes in trials evaluating direct oral anticoagulants (DOAC) vs. dalteparin. Event rates are expressed as total number divided by treated patients, as published

*Indicates significant difference for the corresponding hazard ratio

VTE. On the other hand, there are still areas of uncertainty regarding the use of DOAC for CAT.

Randomized Controlled Trials Evaluating Direct Oral Anticoagulants for Treatment of Cancer-Associated Venous Thromboembolism

Four phase 3, open-label, multicenter RCTs assessed DOAC vs subcutaneous dalteparin in patients with CAT (Table 1).

The earliest study, Comparison of an Oral Factor Xa Inhibitor with Low Molecular Weight Heparin in Patients with Cancer with Venous Thromboembolism (SELECT-D), compared rivaroxaban and dalteparin in 406 subjects with cancer and symptomatic or incidental PE or symptomatic DVT [29••]. Rivaroxaban was administered at the dosage of 15 mg twice daily for 3 weeks followed by 20 mg daily, while dalteparin treatment consisted in 200 IU per kilogram of body weight once daily for the first month, and then 150 IU per kilogram once daily (Fig. 1). The primary outcome was recurrence of VTE over 6 months and was significantly less frequent in the rivaroxaban than in the dalteparin arm (3.9% vs. 8.9%; HR 0.43, 95% CI 0.19–0.99). Major bleeding was non-significantly more frequent with rivaroxaban than with dalteparin (5.4% vs. 3%; HR 1.83, 95% CI 0.68–4.96). Conversely, clinically relevant non-major bleeding was significantly increased by rivaroxaban (12.3% vs. 3.4%; HR 3.76, 95% CI 1.63–8.69). Risk of bleeding was highest in the subgroup with gastroesophageal tumors [29••].

The Edoxaban for the Treatment of Cancer-Associated Venous Thromboembolism (Hokusai VTE Cancer) trial evaluated edoxaban vs dalteparin in 1050 patients with

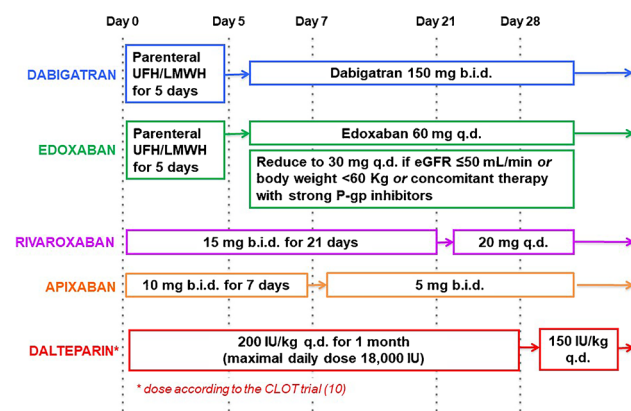


Fig. 1 Therapeutic anticoagulation schemas for the treatment of cancer-associated venous thromboembolism. b.i.d., bis in die; eGFR, estimated glomerular filtration rate, as calculated by the Cockcroft-Gault formula; LMWH, low-molecular-weight heparin; P-gp, P glycoprotein; q.d., quaque die; UFH, unfractionated heparin

symptomatic or incidental VTE and cancer other than basal cell and squamous cell skin cancer, which had been diagnosed within the previous 2 years [30••]. Edoxaban was initiated after at least 5 days of parenteral anticoagulation with intravenous unfractionated heparin or subcutaneous LMWH and was given at the dose of 60 mg once daily. This dosage was reduced to 30 mg once daily in case of estimated glomerular filtration rate < 50 mL/min/1.73 m², body weight < 60 kg, or concomitant use of inhibitors of P-glycoprotein (P-gp, also see next section). Dalteparin was given with the same schema as in SELECT-D. Therapy lasted for at least 6 and up to 12 months, and minimum follow-up was 9 months. The primary end-point was a composite of recurrent symptomatic or incidental VTE and major bleeding, i.e., overt bleeding associated with a drop in hemoglobin concentration of ≥ 2 g/dl or the need of transfusion of ≥ 2 units of blood, happening at a critical site, or contributing to death. This primary outcome occurred in 12.8% of edoxaban-treated patients and 13.5% of those assigned to dalteparin (HR 0.97, 95% CI 0.70–1.36). Secondary analyses revealed a trend for lower rate of VTE recurrence (7.9% vs. 11.3%; HR 0.71, 95% CI 0.48–1.06) and a significantly higher risk of major bleeding (6.9% vs. 4%; HR 1.77, 95% CI 1.03–3.04) with edoxaban [30••]. Again, major bleeding was mostly upper gastrointestinal.

Apixaban was first investigated as an alternative to dalteparin in an investigator-initiated, US-based, multicenter RCT, Apixaban or Dalteparin in Reducing Blood Clots in Patients With Cancer Related Venous Thromboembolism (ADAM VTE) [31••]. Three hundred patients received apixaban (10 mg twice daily for the first 7 days, followed by 5 mg twice daily) or dalteparin (same dosage as in SELECT-D and Hokusai VTE Cancer). The study was designed to test the superiority of apixaban over dalteparin in reducing the primary outcome of major bleeding up to 6 months, which occurred at a rate of 0% with apixaban and 1.4% with dalteparin (HR and 95% CI not estimable). The secondary endpoint of any thromboembolism (DVT, PE, and arterial thromboembolism) was observed in 0.7% and 6.3% of individuals assigned to apixaban and dalteparin, respectively (HR 0.09, 95% CI, 0.01–0.78) [31••].

Subsequently, the multinational, non-inferiority Apixaban for the Treatment of Venous Thromboembolism in Patients With Cancer: A Prospective Randomized Open Blinded End-Point (Probe) Study (CARAVAGGIO) randomized 576 subjects with cancer and symptomatic or incidental VTE to apixaban or dalteparin (same doses as above) [32••]. The primary outcome of recurrent VTE at 6 months was faced by 5.6% of patients in the apixaban group and 7.9% of those assigned to dalteparin (HR 0.63, 95% CI 0.37–1.07), while the rates of major bleeding were 3.8% and 4%, respectively (HR 0.82, 95% CI 0.4–1.69) (Table 1).

In summary, these RCTs showed that DOAC are at least as effective as dalteparin in protecting against CAT recurrence.

Nevertheless, treatment with edoxaban and rivaroxaban took the toll of a higher risk of bleeding, primarily in patients with gastrointestinal malignancies. This side effect has been ascribed to the direct action of DOAC within the gastrointestinal tract, but it was not observed with apixaban [32••].

At least half of the participants in these RCTs had metastatic cancer, and no heterogeneity was found between subjects with or without metastasis [29••, 30••, 31••, 32••]. Additional sub-analyses confirmed the efficacy and safety profile of DOAC vs dalteparin for CAT across different tumor sites and stages, with the aforementioned exception of enhanced bleeding in individuals with gastrointestinal cancer receiving edoxaban or rivaroxaban [33, 34].

Randomized Controlled Trials Evaluating Direct Oral Anticoagulants for Prevention of Cancer-Associated Venous Thromboembolism

Two RCTs addressed the use of DOAC to prevent CAT in subjects who start chemotherapy and are at intermediate-to-high risk for VTE, as defined by a Khorana score ≥ 2 . Previously, LMWH had been demonstrated to be superior to placebo for VTE prevention in ambulatory oncological patients receiving chemotherapy [35••, 36••], especially for pancreatic cancer [37].

The Apixaban for the Prevention of Venous Thromboembolism in Cancer Patients (AVERT) phase 2 RCT compared apixaban with placebo [35••], and the Rivaroxaban for Thromboprophylaxis in High-Risk Ambulatory Patients with Cancer (CASSINI) phase 3 RCT compared rivaroxaban with placebo [36••]. In both studies, follow-up was up to 180 days and the main safety outcome was major bleeding, while the primary efficacy outcome was VTE in AVERT and VTE and death from VTE in CASSINI.

In a modified intention-to-treat analysis including 563 out of 574 subjects randomized in AVERT, VTE occurred significantly less frequently with apixaban than with placebo (4.2% vs. 10.2%, HR 0.41, 95% CI 0.26–0.65), but the opposite happened for major bleeding (3.5% vs. 1.8%; HR 2.0, 95% CI 1.01–3.95). In CASSINI, the primary composite efficacy end-point as well as major bleeding were less frequent—albeit not to a significant extent—in patients randomized to rivaroxaban than placebo (6.0% vs. 8.8%, HR 0.66, 95% CI 0.40–1.09 for the efficacy endpoint; and 2.6% vs. 6.4%, HR 1.96, 95% CI 0.59–6.49 for major bleeding).

When considering only the treatment period (i.e., the time interval during which the study drug was actually taken), major bleeding was no longer significantly different between the apixaban and placebo groups of AVERT (2.1% vs. 1.1%; HR 1.89, 95% CI 0.39–9.24) and the primary end-point of

CASSINI occurred significantly less often in rivaroxaban than placebo treated patients (2.6% vs. 6.4%; HR 0.40, 95% CI 0.20–0.80) [35••, 36••].

It is important to note that both apixaban and rivaroxaban were tested in these RCTs at doses different from the ones investigated in VTE trials, respectively 2.5 mg twice daily and 10 mg daily.

Open Issues in the Management of Cancer-Associated Venous Thromboembolism with Direct Oral Anticoagulants

Pharmacological Interactions

Dabigatran is the DOAC with the most extensive renal clearance (about 80%), while rivaroxaban and apixaban are substantially metabolized by the cytochrome P450, CYP3A4 [38, 39]. All DOAC are excreted in the intestine and to a lesser extent in the kidney via P-gp, so inhibitors of this transporter may increase DOAC plasma concentrations.

Based on predicted or known modulation of CYP3A4 and P-gp, DOAC should be cautiously used in case of co-treatment with many anti-tumor drugs, such as doxorubicin, abiraterone, enzalutamide, imatinib, and sunitinib [38]. Nonetheless, no signal of lower efficacy or safety was observed in the subgroups on active anti-cancer therapy in RCTs of DOAC for CAT [29••, 30••, 31••, 32••]. The dosage of edoxaban is halved when patients are taking major P-gp inhibitors (Fig. 1), and this strategy likely prevents most harmful consequences of the pharmacokinetic interaction between edoxaban and other medications acting on P-gp [40]. It is remarkable that the comparative efficacy and safety of apixaban and dalteparin was not different in participants in CARAVAGGIO who were or were not concomitantly given anti-cancer agents (around 60% and 40%, respectively) [41], even though therapy with P-gp modulators is not a criterion to modify the dose of apixaban.

Incidental Cancer-Associated Thromboembolism

CAT may be incidentally detected during imaging exams performed for unrelated reasons, such as tumor staging [42]. Retrospective analyses indicate that the rate of recurrent VTE after a first incidental diagnosis of CAT is similar to the one observed after symptomatic CAT, encouraging the institution of anticoagulant therapy [43, 44]. As many as 30% of patients in Hokusai VTE Cancer, 50% in SELECT-D, and 20% in CARAVAGGIO had incidental CAT at enrollment [29••, 30••, 32••]. This presentation was more common for PE than for DVT [45, 46]. In agreement with observational studies,

the rates of clinical adverse outcomes were substantial in both incidental and symptomatic CAT arms. Bleeding was particularly frequent in subjects given DOAC or dalteparin for clinically silent CAT, implying that the balance between the anti-thrombotic and pro-hemorrhagic activity of anticoagulants is critical in this setting.

A peculiar type of asymptomatic CAT is the one involving venous catheters. In an open-label investigation in which 70 subjects with central venous catheter-related VTE received rivaroxaban for 12 weeks, the central venous line was always preserved and the rate of recurrent VTE was 1.43%, but there was 1 episode of fatal PE and 9 (12.9%) patients experienced bleeding events [47].

Prolonged Anticoagulation

Two prospective, multicenter, single-arm studies, DALTECAN and TICAT, collected long-term data in patients with active cancer and VTE treated with dalteparin for a maximum of 1 year or tinzaparin for 1 year, respectively [48, 49]. In both, the frequency of recurrent VTE and major bleeding was highest in the first months and declined thereafter. However, only 32% of participants in DALTECAN and 55% of those enrolled in TICAT completed 12 months of treatment. In phase 3 RCTs, DOAC therapy lasted 6–12 months [29••, 30••, 32••].

At present, the choice of prolonging anticoagulation beyond 6–12 months should be tailored considering the severity of CAT and the risk of bleeding, but also tumor- and patient-related factors [50, 51]. For instance, gastrointestinal and genitourinary cancer are associated with more VTE and bleeding events on anticoagulant therapy, including DOAC [29••, 30••], and VTE recurs more often with locally advanced or metastatic than localized cancer [31••]. Furthermore, a recent analysis of a subset of 652 patients with cancer-associated PE in Hokusai VTE Cancer showed that worse performance status at follow-up was associated with both anticoagulation discontinuation and heightened risk of VTE recurrence and major bleeding [52].

Intracranial Tumors

Intracranial neoplasms, either primary or metastatic, are matter of extreme concern when starting anticoagulation because of the possibility of cerebral hemorrhage [53, 54]. Few subjects with intracranial tumors were recruited in Hokusai VTE Cancer, SELECT-D, and ADAM-VTE, and none in CARAVAGGIO. Retrospective studies showed that DOAC do not portend an increased rate of major bleeding compared with LMWH in patients with primary brain

tumors or brain metastases, although intracranial hemorrhage is more likely with the latter ones [55–58].

Thrombocytopenia

Anticoagulation is contraindicated when platelets are $< 25 \times 10^9/L$ [59]. When platelets are between 25 and $50 \times 10^9/L$, LMWH should be used since data with DOAC in this context are scarce [59]. In fact, the platelet count threshold in RCTs of DOAC for CAT ranged from $50 \times 10^9/L$ (Hokusai VTE Cancer and ADAM VTE) to $75 \times 10^9/L$ (CARAVAGGIO) to $100 \times 10^9/L$ (SELECT-D) [25–28].

LMWH is also preferred over DOAC when platelets are $> 50,000 \times 10^9/L$, but with possibility of a further decrease in the subsequent days [60••]. Similarly, prophylactic-dose LMWH, and not DOAC, may be considered to prevent CAT in individuals with thrombocytopenia, with close monitoring of the platelet count [60••].

In presence of acute VTE or high thrombotic risk, or when there is a history of recurrent or progressive thrombosis, transfusions may be performed to raise the platelet count above $50 \times 10^9/L$ and, therefore, make full-dose anticoagulation feasible. Conversely, if the thrombotic risk is low, LMWH can be given at a dosage reduced by 25–50%, and the dose can be adjusted to 50% of the normal in case of subacute or chronic VTE [61]. Modified-dose anticoagulation has been shown to be safe in patients with active malignancy, acute VTE and a platelet count $< 100 \times 10^9/L$ [62].

Management of Direct Oral Anticoagulants During Invasive Procedures

For the prophylaxis of cardioembolism in atrial fibrillation, it is recommended to interrupt DOAC in the hours or days before an invasive procedure and then restart them after a variable amount of time, depending on intervention-related and intrinsic bleeding risk and renal function [16]. This guidance is based on the predictable pharmacokinetics of DOAC, as well as on data showing that bleeding is more likely if heparin is temporary substituted for DOAC or VKA (so called heparin bridging) [63]. It is yet to be proved that this strategy is also valid for DOAC therapy of CAT, even though it is reasonable that this is indeed the case.

Guideline Recommendations for Treatment and Prevention of Cancer-Associated Venous Thromboembolism

The key indications for treatment and prevention of CAT published by major scientific societies since 2019 are summarized in Table 2 [64••, 65••, 66••, 67••, 68••].

Table 2 Key recommendations of the latest guidelines for treatment and prevention of cancer-associated venous thromboembolism

Recommendations for treatment of CAT	
European Society of Cardiology (ESC) 2022 (64)	Edoxaban, apixaban, or rivaroxaban are recommended for treatment of symptomatic or incidental VTE in patients without contraindications (class I, level A)
International Initiative on Thrombosis and Cancer (ITAC) 2022 (65)	Edoxaban, apixaban, or rivaroxaban are recommended for the treatment of VTE in patients with creatinine clearance ≥ 30 mL/min and in the absence of high risk of gastrointestinal or genitourinary bleeding, strong drug–drug interactions, or gastrointestinal absorption impairment (grade 1A) Treatment of established VTE should last ≥ 6 months (grade 1A); thereafter, termination or continuation of anticoagulation should be based on individual evaluation of the benefit-risk ratio, tolerability, drug availability, patient preference, and cancer activity (guidance in the absence of data)
American Society of Hematology (ASH) 2021 (66)	For short-term treatment of VTE (3–6 months), edoxaban, apixaban, or rivaroxaban are suggested over LMWH (conditional recommendation, low certainty in the evidence of effects + +/+ + + +) and VKA (conditional recommendation, very low certainty in the evidence of effects +/+ + + +) For long-term anticoagulation (6 months), DOAC or LMWH are suggested (conditional recommendation, very low certainty in the evidence of effects +/+ + + +)
National Comprehensive Cancer Network (NCCN) 2020 (67)	DOAC are recommended for treatment of VTE (grade 1)
American Society of Clinical Oncology (ASCO) 2019 (68)	Edoxaban and rivaroxaban are treatment options for VTE (evidence quality: high; strength of recommendation: strong) Anticoagulation beyond the initial 6 months should be offered to selected patients, such as those with metastatic disease or those receiving chemotherapy (evidence quality: low; strength of recommendation: weak to moderate) For long-term anticoagulation, edoxaban, rivaroxaban, or LMWH are preferred over VKA (evidence quality: high; strength of recommendation: strong)
Recommendations for primary prophylaxis	
ESC 2022 (64)	Prophylaxis with apixaban, rivaroxaban, or LMWH may be considered for ambulatory patients at high risk of thrombosis receiving systemic therapy, if there are no significant contraindications (class IIb, level B)
ITAC 2022 (65)	Prophylaxis with apixaban or rivaroxaban is indicated in ambulatory patients with locally advanced or metastatic pancreatic cancer treated with systemic anticancer therapy, who have a low risk of bleeding (grade 1 B) Prophylaxis with apixaban or rivaroxaban is recommended in ambulatory patients who are receiving systemic anticancer therapy and are at intermediate to-high-risk of VTE, identified by a validated risk assessment model (i.e., a Khorana score ≥ 2), and not actively bleeding or not at a high risk for bleeding (grade 1B)
ASH 2021 (66)	Prophylaxis with apixaban or rivaroxaban is suggested for ambulatory patients at high risk for thrombosis receiving systemic therapy (conditional recommendation, moderate certainty in the evidence of effects + + +/+ + + +)
NCCN 2020 (67)	Consider apixaban or rivaroxaban for up to 6 months in high-risk patients (Khorana score ≥ 2) starting a new chemotherapy regimen (grade 2A)

DOAC direct oral anticoagulants; LMWH low-molecular-weight heparin; VKA vitamin K antagonists; VTE venous thromboembolism

Rivaroxaban, edoxaban, and apixaban have been added as therapeutic options for VTE in cancer patients after the presentation of the results of the landmark RCTs, and currently they are the first choice. With variable emphasis, guidelines advocate caution in using DOAC in subjects with gastrointestinal malignancies, especially of the upper gastrointestinal tract, or when significant interactions are expected with other drugs. DOAC or LMWH are suggested for prolonged anticoagulation beyond 6 months, after careful assessment of potential benefits and risks.

All guidelines propose primary prophylaxis with apixaban or rivaroxaban in patients at high risk of thrombosis, but not of

bleeding, receiving systemic anticancer therapy. The susceptibility to CAT is mostly defined by a Khorana score ≥ 2 , but also by specific cancer types, such as advanced pancreatic cancer.

Conclusions

Treatment and to a lesser extent prevention of CAT now rely on DOAC, because of the ease of use and the efficacy-safety profile of these drugs. It has also pointed out that DOAC are cost-effective and cost-saving as compared to LMWH in treating VTE [69].

However, there may be subjects for whom anticoagulation with LMWH is better than with DOAC, such as those with upper gastrointestinal cancer or taking anti-neoplastic agents strongly interfering with DOAC metabolism. LMWH, rather than DOAC, is also desirable for CAT associated with thrombocytopenia $< 50 \times 10^9/L$.

Furthermore, additional studies are needed to inform the optimal use of DOAC in special situations or patient populations, such as in the proximity of invasive procedures or in individuals with intracranial tumors.

Funding Open access funding provided by Università degli Studi di Genova within the CRUI-CARE Agreement. I. P. was supported by the Italian Ministry of Health (PNRR-MAD-2022–12376779).

Declarations

Conflict of Interest P. S. received speaker and/or advisor fees from Daiichi Sankyo, Bayer, Incyte, Gentili, FIRMA, and Malesci, all outside the submitted work.

I. P. received speaker and/or advisor fees from AstraZeneca, Daiichi Sankyo, Terumo Corporation, Biotronik, Bayer, and Amgen, all outside the submitted work.

P. A. received speaker and/or advisor fees from Daiichi Sankyo, AstraZeneca, Boehringer Ingelheim, Bayer, Novartis, Vifor, Janssen, and MSD, all outside the submitted work.

Open Access This article is licensed under a Creative Commons Attribution 4.0 International License, which permits use, sharing, adaptation, distribution and reproduction in any medium or format, as long as you give appropriate credit to the original author(s) and the source, provide a link to the Creative Commons licence, and indicate if changes were made. The images or other third party material in this article are included in the article's Creative Commons licence, unless indicated otherwise in a credit line to the material. If material is not included in the article's Creative Commons licence and your intended use is not permitted by statutory regulation or exceeds the permitted use, you will need to obtain permission directly from the copyright holder. To view a copy of this licence, visit <http://creativecommons.org/licenses/by/4.0/>.

References

Papers of particular interest, published recently, have been highlighted as:

- Of importance
- Of major importance

1. Khorana AA, Dalal MR, Lin J, et al. Health care costs associated with venous thromboembolism in selected high-risk ambulatory patients with solid tumors undergoing chemotherapy in the United States. *Clinicoecon Outcomes Res.* 2013;5:101–8.
2. Heit JA, Silverstein MD, Mohr DN, et al. Risk factors for deep vein thrombosis and pulmonary embolism: a population-based case-control study. *Arch Intern Med.* 2000;160:809–15.
3. Falanga A, Russo L, Milesi V, Vignoli A. Mechanisms and risk factors of thrombosis in cancer. *Crit Rev Oncol Hematol.* 2017;118:79–88.

4. Mosarla RC, Vaduganathan M, Qamar A, et al. Anticoagulation strategies in patients with cancer: JACC Review Topic of the Week. *J Am Coll Cardiol.* 2019;73(11):1336–49.
5. Lyman GH, Khorana AA, Kuderer NM, et al. Venous thromboembolism prophylaxis and treatment in patients with cancer: American Society of Clinical Oncology clinical practice guideline update. *J Clin Oncol.* 2013;31(17):2189–204.
6. Mandala M, Falanga A, Roila F. Management of venous thromboembolism (VTE) in cancer patients: ESMO Clinical Practice Guidelines. *Ann Oncol.* 2011;22(Suppl 6):vi85-92.
7. Kearon C, Akl EA, Ornelas J, et al. Antithrombotic therapy for VTE disease: chest guideline and expert panel report. *Chest.* 2016;149:315–52.
8. Lee AY, Levine MN, Baker RI, et al. Low-molecular-weight heparin versus a coumarin for the prevention of recurrent venous thromboembolism in patients with cancer. *N Engl J Med.* 2003;349:146–53.
9. Lee AY, Kamphuisen PW, Meyer G, CATCH Investigators, et al. Tinzaparin vs warfarin for treatment of acute venous thromboembolism in patients with active cancer: a randomized clinical trial. *JAMA.* 2015;314(7):677–86.
10. Meyer G, Marjanovic Z, Valcke J, et al. Comparison of low-molecular-weight heparin and warfarin for the secondary prevention of venous thromboembolism in patients with cancer: a randomized controlled study. *Arch Intern Med.* 2002;162(15):1729–35.
11. Deitcher SR, Kessler CM, Merli G, et al. Secondary prevention of venous thromboembolic events in patients with active cancer: enoxaparin alone versus initial enoxaparin followed by warfarin for a 180-day period. *Clin Appl Thromb Hemost.* 2006;12(4):389–96.
12. Hull RD, Pineo GF, Brant RF, et al. Self-managed long-term low-molecular-weight heparin therapy: the balance of benefits and harms. *Am J Med.* 2007;120(1):72–82.
13. Wittkowsky AK. Barriers to the long-term use of low-molecular weight heparins for treatment of cancer-associated thrombosis. *J Thromb Haemost.* 2006;4:2090–1.
14. Khorana AA, Yannicelli D, McCrae KR, et al. Evaluation of US prescription patterns: are treatment guidelines for cancer-associated venous thromboembolism being followed? *Thromb Res.* 2016;145:51–3.
15. Botto GL, Ameri P, De Caterina R. Many good reasons to switch from vitamin K antagonists to non-vitamin K antagonists in patients with non-valvular atrial fibrillation. *J Clin Med.* 2021;10(13):2866. <https://doi.org/10.3390/jcm10132866>.
16. Steffel J, Verhamme P, Potpara TS, et al. The 2018 European Heart Rhythm Association Practical Guide on the use of non-vitamin K antagonist oral anticoagulants in patients with atrial fibrillation. *Eur Heart J.* 2018;39(16):1330–93.
17. Schulman S, Kearon C, Kakkar AK, et al. Dabigatran versus warfarin in the treatment of acute venous thromboembolism. *N Engl J Med.* 2009;361:2342–52.
18. Bauersachs R, Berkowitz SD, Brenner B, et al. Oral rivaroxaban for symptomatic venous thromboembolism. *N Engl J Med.* 2010;363:2499–510.
19. Buller HR, Prins MH, Lensin AW, et al. Oral rivaroxaban for the treatment of symptomatic pulmonary embolism. *N Engl J Med.* 2012;366:1287–97.
20. Agnelli G, Buller HR, Cohen A, et al. Oral apixaban for the treatment of acute venous thromboembolism. *N Engl J Med.* 2013;369:799–808.
21. Büller HR, Décousus H, Grosso MA, et al. Edoxaban versus warfarin for the treatment of symptomatic venous thromboembolism. *N Engl J Med.* 2013;369:1406–15.
22. Prins MH, Lensing AW, Brighton TA, et al. Oral rivaroxaban versus enoxaparin with vitamin K antagonist for the treatment of symptomatic venous thromboembolism in patients with

- cancer (EINSTEIN-DVT and EINSTEIN-PE): a pooled subgroup analysis of two randomised controlled trials. *Lancet Haematol.* 2014;1:e37–46.
23. Schulman S, Goldhaber SZ, Kearon C, et al. Treatment with dabigatran or warfarin in patients with venous thromboembolism and cancer. *Thromb Haemost.* 2015;114:150–7.
 24. Raskob GE, van Es N, Segers A, Hokusai-VTE Investigators, et al. Edoxaban for venous thromboembolism in patients with cancer: results from a non-inferiority subgroup analysis of the Hokusai-VTE randomised, double-blind, double-dummy trial. *Lancet Haematol.* 2016;3:e379–87.
 25. Agnelli G, Buller HR, Cohen A, et al. Oral apixaban for the treatment of venous thromboembolism in cancer patients: results from the AMPLIFY trial. *J Thromb Haemost.* 2015;13:2187–91.
 26. Alzghari SK, Seago SE, Garza JE, et al. Retrospective comparison of low molecular weight heparin vs. warfarin vs. oral Xa inhibitors for the prevention of recurrent venous thromboembolism in oncology patients: The Re-CLOT study. *J Oncol Pharm Pract.* 2018;24(7):494–500.
 27. Phelps MK, Wiczer TE, Erdeljac HP, et al. Comparison of direct oral anticoagulants versus low-molecular-weight-heparins for the treatment of cancer associated thrombosis. *Blood.* 2016;128:5013.
 28. Ross JA, Miller MM, Rojas Hernandez CM. Comparative effectiveness and safety of direct oral anticoagulants (DOACs) versus conventional anticoagulation for the treatment of cancer-related venous thromboembolism: a retrospective analysis. *Thromb Res.* 2017;150:86–9.
 29. ●● Young AM, Marshall A, Thirlwall J, et al. Comparison of an oral factor Xa inhibitor with low molecular weight heparin in patients with cancer with venous thromboembolism: results of a randomized trial (SELECT-D). *J Clin Oncol.* 2018;36(20):2017–23. **RCT evaluating DOAC for treatment of CAT.**
 30. ●● Raskob GE, van Es N, Verhamme P, Hokusai VTE cancer investigators, et al. Edoxaban for the treatment of cancer-associated venous thromboembolism. *N Engl J Med.* 2018;378(7):615–24. **RCT evaluating DOAC for treatment of CAT.**
 31. ●● McBane RD 2nd, Wysokinski WE, Le-Rademacher JG, Zemla T, Ashrani A, Tafur A, Perepu U, Anderson D, Gundabolu K, Kuzma C, Perez Botero J, Leon Ferre RA, Henkin S, Lenz CJ, Houghton DE, Vishnu P, Loprinzi CL. Apixaban and dalteparin in active malignancy-associated venous thromboembolism: The ADAM VTE trial. *J Thromb Haemost.* 2020;18(2):411–21. <https://doi.org/10.1111/jth.14662>. **RCT evaluating DOAC for treatment of CAT.**
 32. ●● Agnelli G, Muñoz A, Franco L, Mahé I, Brenner B, Connors JM, Gussoni G, Hamulyak EN, Lambert C, Suero MR, Bauersachs R, Torbicki A, Becattini C. Apixaban and dalteparin for the treatment of venous thromboembolism in patients with different sites of cancer. *Thromb Haemost.* 2022;122(5):796–807. <https://doi.org/10.1055/s-0041-1735194>. **RCT evaluating DOAC for treatment of CAT.**
 33. Mulder FI, Van Es N, Kraaijpoel N, Raskob G, et al. Corrigendum to “Edoxaban for treatment of venous thromboembolism in patient groups with different types of cancer: results from the Hokusai VTE Cancer study” [*Thromb. Res.* vol. 185, January 2020, pages 13–19]. *Thromb Res.* 2020;191:156–9. <https://doi.org/10.1016/j.thromres.2020.02.022>.
 34. Verso M, Agnelli G, Muñoz A, Connors JM, Sanchez O, Huisman M, Brenner B, Gussoni G, Cohen AT, Becattini C. Recurrent venous thromboembolism and major bleeding in patients with localised, locally advanced or metastatic cancer: an analysis of the Caravaggio study. *Eur J Cancer.* 2022;165:136–45. <https://doi.org/10.1016/j.ejca.2022.01.023>.
 35. ●● Carrier M, Abou-Nassar K, Malice R, et al. Apixaban to prevent venous thromboembolism in patients with cancer. *N Engl J Med.* 2019;380(8):711–9. **RCT evaluating DOAC for prevention of CAT.**
 36. ●● Khorana AA, Soff GA, Kakkar AK, et al. Rivaroxaban for thromboprophylaxis in high-risk ambulatory patients with cancer. *N Engl J Med.* 2019;380(8):720–8. **RCT evaluating DOAC for prevention of CAT.**
 37. Frere C, Crichton B, Bourmet B, Caivet C, Ait N, Buscail L, et al. Primary thromboprophylaxis in ambulatory pancreatic cancer patients receiving chemotherapy: a systemic review and meta-analysis of randomized controlled trials. *Cancers.* 2020;12(8):2028.
 38. Gnoth MJ, Buetehorn U, Muenster U, et al. In vitro and in vivo P-glycoprotein transport characteristics of rivaroxaban. *J Pharmacol Exp Ther.* 2011;338(1):372–80.
 39. Mueck W, Kubitzka D, Becka M. Co-administration of rivaroxaban with drugs that share its elimination pathways: pharmacokinetic effects in healthy subjects. *Br J Clin Pharmacol.* 2013;76(3):455–66.
 40. Raskob G, Büller H, Prins M, Segers A, Shi M, Schwocho L, van Kranen R, Mercuri M, Hokusai-VTE Investigators. Edoxaban for the longterm treatment of venous thromboembolism: rationale and design of the Hokusai-venous thromboembolism study—methodological implications for clinical trials. *J Thromb Haemost.* 2013;11(7):1287–94.
 41. Verso M, Muñoz A, Bauersachs R, Huisman MV, Mario Mandalà M, Vescovo G, Becattini C, Agnelli G. Effects of concomitant administration of anticancer agents and apixaban or dalteparin on recurrence and bleeding in patients with cancer-associated venous thromboembolism. *Eur J Cancer.* 2021;148:371–81. <https://doi.org/10.1016/j.ejca.2021.02.026>.
 42. Font C, Farrus B, Vidal L, et al. Incidental versus symptomatic venous thrombosis in cancer: a prospective observational study of 340 consecutive patients. *Ann Oncol.* 2011;22(9):2101–6.
 43. Mulder F, Di Nisio M, Ay C, Carrier M, Bosch F, Segers A, Kraaijpoel N, Grosso MA, Zhang G, Verhamme P, Wang T, Weitz J, Middeldorp S, Raskob G, Beenen LFM, Büller HR, van Es N. Clinical implications of incidental venous thromboembolism in cancer patients. *Eur Respir J.* 2020;55(2):1901697. <https://doi.org/10.1183/13993003.01697-2019>.
 44. Giustozzi M, Connors JM, Ruperez Blanco AB, Szmit S, Falvo N, Cohen AT, Huisman M, Bauersachs R, Dentali F, Becattini C, Agnelli G. Clinical characteristics and outcomes of incidental venous thromboembolism in cancer patients: insights from the Caravaggio study. *J Thromb Haemost.* 2021;19(11):2751–9. <https://doi.org/10.1111/jth.15461>.
 45. Den Exter PL, Hooijer J, Dekkers OM, et al. Risk of recurrent venous thromboembolism and mortality in patients with cancer incidentally diagnosed with pulmonary embolism: a comparison with symptomatic patients. *J Clin Oncol.* 2011;29(17):2405–9.
 46. van der Hulle T, den Exter PL, Planquette B, et al. 2016 Risk of recurrent venous thromboembolism and major hemorrhage in cancer-associated incidental pulmonary embolism among treated and untreated patients: a pooled analysis of 926 patients. *J J Thromb Haemost.* 2016;14(1):105–13.
 47. Davies GA, Lazo-Langher A, Gandara E, et al. A prospective study of rivaroxaban for central venous catheter associated upper extremity deep vein thrombosis in cancer patients (Catheter 2). *Thromb Res.* 2018;162:88–92.
 48. Francis CW, Kessler CM, Goldhaber SZ, et al. Treatment of venous thromboembolism in cancer patients with dalteparin for up to 12 months: the DALTECAN Study. *J Thromb Haemost.* 2015;13(6):1028–35.
 49. Jara-Palomares L, Solier-Lopez A, Elias-Hernandez T, et al. Tinzaparin in cancer associated thrombosis beyond 6 months: TiCAT study. *Thromb Res.* 2017;157:90–6.
 50. Noble S, Sui J. The treatment of cancer associated thrombosis: does one size fit all? Who should get LMWH/warfarin/DOACs? *Thromb Res.* 2016;140(Suppl 1):S154–9.

51. Zwicker JI, Bauer KA. How long is enough? Extended anticoagulation for the treatment of cancer-associated thrombosis. *J Clin Oncol.* 2014;32(32):3596–9.
52. Farmakis IT, Barco S, Mavromanoli A, Konstantinides S, Valerio L. Performance status and long-term outcomes in cancer-associated pulmonary embolism: insights from the Hokusai-VTE Cancer Study. *JACC CardioOncol.* 2022;4(4):507–18.
53. Zwicker JL, Karp Leaf R, Carrier M. A meta-analysis of intracranial hemorrhage in patients with brain tumors receiving therapeutic anticoagulation. *J Thromb Haemost.* 2016;14(9):1736–40.
54. Donato J, Campigotto F, Uhlmann EJ, et al. Intracranial hemorrhage in patients with brain metastases treated with therapeutic enoxaparin: a matched cohort study. *Blood.* 2015;126(4):494–9.
55. Swartz AW, Drappatz J. Safety of direct oral anticoagulants in central nervous system malignancies. *Oncol.* 2021;26:427.
56. Leader A, Hannulyak EN, et al. Intracranial hemorrhage with direct oral anticoagulants in patients with brain metastases. *Blood Adv.* 2020;4:6291.
57. Carney BJ, Uhlmann EJ, et al. Intracranial hemorrhage with direct oral anticoagulants in patients with brain tumors. *J Thromb Haemostasis.* 2019;17:72–6.
58. Lee A, Oley F, et al. Direct oral anticoagulants or low-molecular-weight heparins for venous thromboembolism in patients with brain tumors. *Thromb Res.* 2021;208:148.
59. Samuelson Bannow BT, Lee A, Khorana AA, et al. Management of cancer-associated thrombosis in patients with thrombocytopenia: guidance from the SSC of the ISTH. *J Thromb Haemost.* 2018;16(6):1246–9.
- 60.●● Falanga A, Leader A, et al. EHA guidelines on management of antithrombotic treatments in thrombocytopenic patients with cancer. *Hemasphere.* 2022;6(8):e750. <https://doi.org/10.1097/HS9.0000000000000750>. **Guidelines on CAT prevention and treatment.**
61. Kopolovic I, Lee AYY, Wu C. Management and outcomes of cancer-associated venous thromboembolism in patients with concomitant thrombocytopenia: a retrospective cohort study. *Ann Hematol.* 2015;94(2):329–36.
62. Carney B, Wang TF, et al. Anticoagulation in cancer-associated thromboembolism with thrombocytopenia: a prospective, multicenter cohort study. *Blood Adv.* 2021;5(24):5546–53.
63. Douketis JD, Spyropoulos AC, Kaatz S, BRIDGE Investigators, et al. Perioperative Bridging Anticoagulation in Patients with Atrial Fibrillation. *N Engl J Med.* 2015;373:823–33.
- 64.●● Lyon A, Lopez-Ferdinandez T, et al. 2022 ESC Guidelines on cardio-oncology developed in collaboration with the European Hematology Association (EHA), the European Society for Therapeutic Radiology and Oncology (ESTRO) and the International Cardio-Oncology Society (IC-OS) Developed by the task force on cardio-oncology of the European Society of Cardiology (ESC). *Eur Heart J.* 2022;43(41):4229–361. <https://doi.org/10.1093/eurheartj/ehac244>. **Guidelines on CAT prevention and treatment.**
- 65.●● Dominique Farge, Corinne Frere et al, the International Initiative on Thrombosis and Cancer (ITAC) advisory panel. 2022 international clinical practice guidelines for the treatment and prophylaxis of venous thromboembolism in patients with cancer, including patients with COVID-19. July, 2022: [https://doi.org/10.1016/S1470-2045\(22\)00160-7](https://doi.org/10.1016/S1470-2045(22)00160-7). **Guidelines on CAT prevention and treatment.**
- 66.●● Lyman GH, Carrier M, Ay C, et al. American Society of Hematology 2021 guidelines for management of venous thromboembolism: prevention and treatment in patients with cancer. *Blood Adv.* 2021;5(4):927–74. **Guidelines on CAT prevention and treatment.**
- 67.●● Streiff MB, Holmstrom B, Angelini D et al. NCCN Clinical Practice Guidelines in Oncology. Cancer-associated venous thromboembolic disease. Version 2.2018 – August 27, 2018. https://www.nccn.org/professionals/physician_gls/pdf/vte.pdf (assessed 10 April 2019); Version 2.2021 – October 15;19(10):1181–1201. **Guidelines on CAT prevention and treatment.**
- 68.●● Key NS, Khorana AA, Kuderer NM, et al. Venous thromboembolism prophylaxis and treatment in patients with cancer: ASCO clinical practice guideline update. *J Clin Oncol.* 2019;5:JCO1901461. **Guidelines on CAT prevention and treatment.**
69. Muñoz A, Gallardo E, Agnelli G, Crespo C, Forghani M, Arumi D, Fernández de Cabo S, Soto J. Cost-effectiveness of direct oral anticoagulants compared to low-molecular-weight-heparins for treatment of cancer associated venous thromboembolism in Spain. *J Med Econ.* 2022;25(1):840–7. <https://doi.org/10.1080/13696998.2022.2087998>.

Publisher's Note Springer Nature remains neutral with regard to jurisdictional claims in published maps and institutional affiliations.