

# EFFECT OF ACTINOSPECTACIN IN EXPERIMENTAL SYPHILIS IN THE RABBIT

## I. EARLY LESION SYPHILIS\*

BY

JOHN W. CLARK, JR., AND ANNE R. YOBS

WITH THE TECHNICAL ASSISTANCE OF

WILLIAM E. POST, JR.

*From the Venereal Disease Research Laboratory, Communicable Disease Center, Public Health Service, U.S. Department of Health, Education, and Welfare, Atlanta 22, Georgia, U.S.A.*

Actinospectacin is a broad-spectrum antibiotic produced by *Streptomyces spectabilis*, which was discovered and developed by the Upjohn Company, Kalamazoo, Michigan. We are interested in the effect of drugs in syphilis as possible therapeutics, in the incidental effects of widely-used treatment regimens in concomitant syphilis, and in the insight into the metabolism of *Treponema pallidum* to be derived from the modes of action of substances which have demonstrable effects on the organism. This is a report of a series of experiments to determine the effect of Trobicin† on experimental primary syphilis in the rabbit.

### Experimental Methods

The methods used were derived from the work of Garson and McLeod (1957), Garson, Washburn, and Clark (1960), and Washburn, Garson, and Clark (1960). Male rabbits were injected intracutaneously in the shaved skin of the back at six sites with a suspension of virulent *Treponema pallidum* (Nichols strain), each site receiving  $10^7$  or more organisms in 0.2 ml. The animals were kept in quarters maintained at 68-70°F. The injection of this number of freshly-collected *T. pallidum* produces a continuously dark-field positive area which rapidly evolves into a chancre. At 7 days' incubation, 1,044 such lesions on 174 rabbits averaged 11.9 mm. in diameter and 2.9 mm. in height.

7 days after inoculation, the animals were divided into groups of six rabbits each. One group was not treated. Each dosage level and each treatment schedule studied was administered to separate six-animal groups by the intramuscular injection of an aqueous solution.

The animals were observed clinically and serologically. Weights were recorded at weekly intervals. The rabbits were examined one to six times each day during treatment, daily for 10 days after treatment, and twice a week for 6 months thereafter. Diameters and elevations of lesions were recorded every 2 days for 3 weeks and at weekly intervals for 8 weeks. Dark-field examinations of lesion exudates were performed before treatment, every 4 to 8 hours for the first 24 to 48 hours of treatment, daily for the next 10 days, and then at 2 or 3-day intervals until the lesions regressed. The exudate was collected by incising the lesion and expressing tissue fluids by gentle pressure exerted with thumb and forefinger, and the six chancres of each rabbit were examined in rotation to reduce the effect of trauma on the subsequent course of the chancres.

Testes were examined twice weekly from the fourth to the twelfth post-inoculation week and weekly during the next 3 months of observation. Palpable abnormalities were aspirated and the tissue fluids examined by dark-field microscopy. Testes normal on palpation were routinely aspirated and examined by dark-field microscopy at intervals during the second and third months of observation.

Failure to locate treponemes after a diligent search for 15 to 20 minutes of one or more preparations from one or more of an animal's lesions on 3 separate days was considered to be indicative of the gross disappearance of treponemes from the surface lesions. Testicular abnormalities were similarly examined until proved positive or until they disappeared. Any clinically suspicious change in a rabbit previously designated dark-field negative in this manner was re-examined by the same procedure. Failure to attain dark-field negativity, relapse to dark-field positivity, or development of dark-field positive secondary manifestations was *prima facie* evidence of treatment failure. The clinical course of the lesions and serological results were also considered in the evaluation of drug effects.

Blood specimens were collected before inoculation and at 1, 2, 3, 6, 12, and 24 weeks after infection. All sera were stored in tubes sealed with paraffin-coated corks

\* Received for publication June 10, 1963.

† Actinospectacin sulphate was supplied for these studies by the Upjohn Company as "Trobicin".

Trade names are for identification only and do not represent an endorsement by the Public Health Service.

at  $-18^{\circ}\text{C}$ . Quantitative VDRL slide tests were performed on all sera and the TPI test was used when additional serological evidence was required.

6 months or more after treatment, the popliteal lymph nodes and, in certain instances, the inguinal nodes, of each clinically cured animal were emulsified, examined by dark-field, and injected into the testicles of two normal VDRL-negative rabbits. The recipients were followed clinically and serologically for 3 months—in certain instances, by transfer of their nodal and/or testicular tissues to additional normal animals. Routine dark-field examinations of testicular aspirates were performed 6 and 12 weeks after node transfer.

Autopsies and histological examinations of casualties were performed. When death was obviously imminent, tissues were transferred before the end of the 6-month observation period.

Actinospectacin sulphate in water was administered intramuscularly in three schedules:

*Experiment 1.*—Groups of six rabbits received 40 (Exp. 1a), 200 (Exp. 1b), or 400 (Exp. 1c) mg./kg./day divided into six doses per day administered every 4 hours for 6 days.

*Experiment 2.*—Groups of six rabbits received a single injection of 20 (Exp. 2a), 240 (Exp. 2b), or 1,200 (Exp. 2c) mg./kg.

*Experiment 3.*—A single daily injection of 40 mg./kg./day was given for 6 days to one group of six rabbits.

## Results

No local reactions due to actinospectacin were observed.

During the week of treatment and intensive observation, one rabbit died and thirty of 41 survivors lost weight. The weight loss was negligible, averaging 0.07 kg. per rabbit, and subsequent gains were comparable to those of the untreated animals. Weight loss was not correlated with either dosage level or treatment schedule.

Four of eighteen untreated and nine of 42 treated rabbits died during the 6-month post-treatment observation period. There was no evidence that these deaths were related to the treatment. Casualties were not related to the amount of actinospectacin administered, and there was no histopathological evidence of cellular toxicity.

*T. pallida* were readily demonstrated in the lesions at the injection sites on the untreated animals until after dark-field positive secondary lesions began to appear during the fifth week of infection. The clinical course of the primary lesions is indicated graphically in Fig. 1.

Lesions of two of the eighteen untreated animals virtually regressed 3 weeks after inoculation. The other lesions followed a more usual pattern as shown in Fig. 1. After 6 weeks' incubation, eight of the

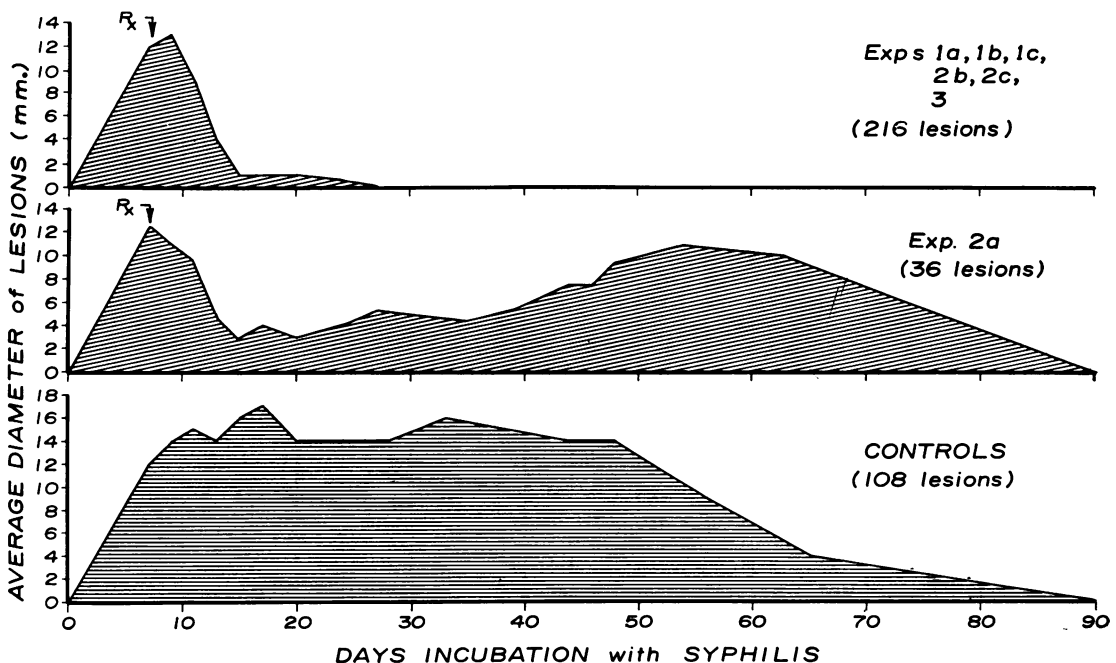


FIG. 1.—Regression in mean diameter of lesions.

eighteen control rabbits had positive secondary skin lesions, four had confirmed syphilitic orchitis, and two others had both skin lesions and testicular syphilomata. By the 12th week all the controls, with the exception of one which died, had developed confirmed secondary manifestations.

The rabbits were VDRL-negative initially. One week after infection, 66 of 174 had become reactive—41 at 1 dilution, seventeen at 2.5 dilutions, six at 5 dilutions, and two at 10 dilutions. At two weeks all were reactive with titres from 2.5 to 50 dilutions. The geometric mean titres of the controls attained a plateau of about 12 dilutions after 2 weeks' incubation, which was maintained for 12 weeks. After 6 months the reactivity level had dropped to about 8 dilutions. All surviving controls were reactive.

Popliteal nodal tissue from the untreated rabbits transferred after 6 months' incubation produced syphilomata in at least one of the two recipients within 27 to 58 days; twelve of the fourteen donors produced syphilis in both recipients. One of the two recipients of each of two controls was dark-field, VDRL, and TPI positive, its counterpart negative (see Discussion).

The effect of actinospectacin is summarized in the Table. In Experiment 1 (treated every 4 hours for 6 days) *T. pallida* were not demonstrated in the 200 or the 400 mg./kg./day groups after 2 days of treatment or in the 40 mg./kg./day group after 5 days of treatment. Regression of lesions was obvious by the fourth day and was virtually complete by the tenth day after the start of therapy. No secondary manifestations developed. At the end of treatment, the multiple injection per day groups showed VDRL titres comparable to or higher than those of the controls (Fig. 2, opposite).

Two weeks after the start of treatment (3 weeks after inoculation), a precipitous drop in the titres of

the treated animals to the 3-dilution range was noted. After 6 months, eight of fifteen survivors were negative, six reactive at one dilution, and one reactive at 2.5 dilutions. The node transfer recipients were all negative.

The results of observations on the rabbits in Experiment 3, which were given 40 mg./kg. actinospectacin as a single daily injection for 6 days, closely paralleled those given the same dosage in a different schedule in Experiment 1. Treponemes disappeared by the fifth day of treatment, lesions regressed by the tenth day after the start of treatment, VDRL titres dropped after treatment, and node transfer recipients were not infected. After 6 months, two of four survivors were VDRL negative and two reactive at one dilution; these specimens were TPI negative. One animal, which had to be destroyed because of an injury, was TPI negative at 6 weeks; its VDRL titre had dropped from 25 dilutions at 3 weeks to one dilution at 6 weeks' incubation. Transfer of nodal tissue from this animal was inadvertently omitted.

Rabbits in Experiment 2 received actinospectacin in a single injection. When only 20 mg./kg. was given (Exp. 2a), demonstration of treponemes was made increasingly difficult from the second post-treatment day. However, the lesions remained dark-field positive. Five of six rabbits exhibited positive secondary skin lesions and the sixth developed a confirmed testicular syphiloma during the fourth week after treatment. While the rate of regression of the primary lesions in this group was comparable to that of the other treated animals for two post-treatment weeks, the inoculation sites eventually developed again into characteristic chancres. This group had a slight reduction in VDRL titres at 3 and 6 weeks' incubation followed by an increase at 12 weeks. As illustrated in Fig. 2, the 12 and 24-week titres in Experiment 2a were comparable to those of the controls.

TABLE  
INTRAMUSCULAR ACTINOSPECTACIN IN PRIMARY RABBIT SYPHILIS

Exp. No.	Treatment Schedule					Rabbits				
	mg./kg.		Injections	Days	Total	Surviving Essential Observations	No. Rx Failures	Cured		
	Total	per day						No.	per cent.	
1	a	240	40	4-hrly	6	6	5	0	5	100
	b	1200	200	4-hrly	6	6	5	0	5	100
	c	2400	400	4-hrly	6	6	5	0	5	100
2	a	20	20	Single	1	6	6	6	0	0
	b	240	240	Single	1	6	4	2	2	50
	c	1200	1200	Single	1	6	6	0	6	100
3		240	40	Single	6	6	5	0	5	100

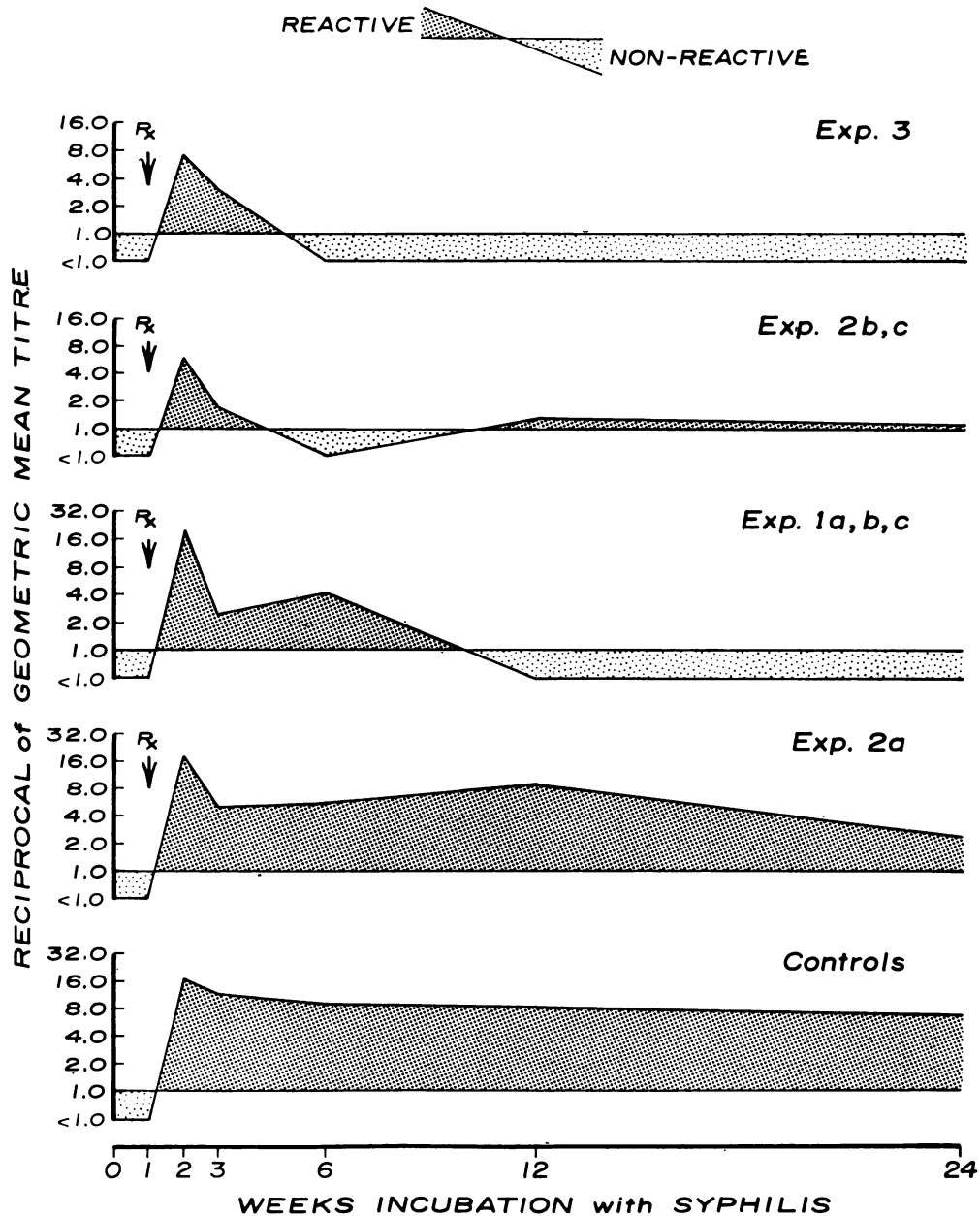


FIG. 2.—Results of VDRL slide test.

The 240 mg./kg. (Exp. 2b) and the 1,200 mg./kg. (Exp. 2c) groups in Experiment 2 were dark-field negative on the sixth post-treatment day; and the lesions had almost disappeared by the tenth day. One rabbit in the 240 mg./kg. group developed a

confirmed secondary lesion. The VDRL slide tests of the rabbits in Experiment 2 were either non-reactive 5 weeks after treatment or reactive at one or two dilutions. An increase in titre of the dark-field positive relapse, and of the other treatment failure later

demonstrated by positive node transfer, was noted at 12 weeks. Two of the four 240 mg./kg. group surviving to node transfer were proved to have syphilis by infected recipients. All of the recipients of node tissue from the six 1,200 mg./kg. rabbits remained normal. The 6-month sera of the 1,200 mg./kg. group were TPI negative, as were the sera of the recipients of their nodal tissues collected 3 months after the transfer.

### Discussion

Actinospectacin cured experimental primary syphilis in the rabbit by the criteria used when adequate levels were maintained for sufficiently long periods. The three levels in the 4-hour schedule for 6 days in Experiment 1 cured, as did the lowest of these when given as a single dose of 40 mg./kg./day for 6 days in Experiment 3. In experiment 2 the total of these two effective schedules administered as a single dose of 240 mg./kg. cured two of the four survivors of the observation period, one of the treatment failures developing a confirmed secondary lesion, and each producing syphilis upon tissue transfer. When 1,200 mg./kg. was given as a single injection, five of six rabbits met each of the criteria for cure. A dark-field positive secondary lesion was recorded on the sixth rabbit on the 38th post-treatment day. None of the recipients of node tissue from the six animals in this group developed the disease. Sera collected 12 and 24 weeks after treatment and from the recipients 12 weeks after node transfer were TPI negative.

Dark-field demonstration of motile *T. pallida* is the most definitive diagnostic criterion. In lieu of this, infectivity to normal rabbits of nodal tissue transferred 6 months or more after exposure or treatment determines whether an individual rabbit has syphilis. Unfortunately, this tool is not 100 per cent. sensitive. As reported, all fourteen of the controls surviving to node transfer produced syphilis in the recipients, but two did so in only one of their two test animals as shown by serology and by dark-field examination of aspirates. The failure to produce syphilis from the nodes of the rabbit which was recorded as having had a dark-field positive skin lesion 38 days after having been given 1.2 g./kg. in a single injection might be considered an example of the lack of sensitivity of the node transfer procedure. However, considering all the data, it appears that the discrepancy is a technical error, and that 1.2 g./kg. in a single injection cured all six subjects as it did in fact cure five.

A single 20 mg./kg. injection of actinospectacin, found to be effective in gonorrhoea in man by Willcox (1962) and by Laird and Taylor (1962), did

not cure syphilis in the rabbit. Treponemes were less readily demonstrated in chancre exudates and the lesions regressed dramatically during the first 10 post-treatment days, persisted as insignificant papules averaging less than 5 mm. in diameter for 20 more days, and then again developed into more characteristic chancres.

The demonstrated alteration of the symptoms of primary syphilis in rabbits, if true in man, is important in the control of the disease. Repository forms are anticipated which, if generally used, might result in some level of the drug being present in large numbers of people over extended periods. If actinospectacin becomes popular in the treatment of gonorrhoea, this could be an important factor in a high-risk-of-exposure-to-syphilis segment of the population. Diagnosis of concomitant early syphilis might become more difficult in patients receiving actinospectacin. A study of the effects of actinospectacin on subclinical incubating syphilis is to be reported.

### Summary

- (1) A report is given of the effects of various dosages and treatment schedules of actinospectacin in experimental primary syphilis in the rabbit.
  - (a) As little as 40 mg./kg./day cured when divided into six equal 4-hourly intramuscular injections continued for 6 days, or given as a single daily dose for 6 days.
  - (b) Single injections of 1.2 g./kg. cured all subjects; 240 mg./kg. did not.
  - (c) Single injections affected the course of the clinical manifestations of primary syphilis at the lowest concentration used—20 mg./kg.
- (2) The implications of the findings are discussed.

### REFERENCES

- Garson, W., and McLeod, C. P. (1957). "Antibiotics Annual, 1956-1957", p. 1073. Medical Encyclopedia, New York.
- , Washburn, T. C., and Clark, J. W., Jr. (1960). "Antibiotics Annual, 1959-1960", p. 472. Antibiotica, New York.
- Laird, S. M., and Taylor, G. (1962). *Brit. J. vener. Dis.*, **38**, 60.
- Washburn, T. C., Garson, W., and Clarke, J. W., Jr. (1960). "Antibiotics Annual, 1959-1960", p. 487. Antibiotica, New York.
- Willcox, R. R. (1962). *Brit. J. vener. Dis.*, **38**, 150.
- (1962). W.H.O. Document No. WHO/VDT/293, August 15, 1962.

**La syphilis expérimentale chez le lapin traité par l'actinospectacine (Trobicin)**

RÉSUMÉ

- (1) Les auteurs passent en revue les effets sur la syphilis primaire expérimentale chez le lapin de différents dosages d'actinospectacine.
- (2) Une dose de 40 mg./kg. par jour donnée par voie intramusculaire toutes les 4 heures (ou bien une fois par jour) pendant 6 jours suffit à produire un bon résultat.
- (3) Une seule injection de 1,2 g./kg. guérit toujours, mais 240 mg./kg. n'eurent aucun effet.
- (4) Les manifestations cliniques de la syphilis primaire furent modifiées par une seule injection de la plus faible dose utilisée, soit 20 mg./kg.
- (5) On discute les implications de ces données.