

GENITAL INFECTION IN ASSOCIATION WITH TRIC VIRUS INFECTION OF THE EYE

I. ISOLATION OF VIRUS FROM URETHRA, CERVIX, AND EYE* PRELIMINARY REPORT

BY

BARRIE R. JONES AND M. KHALAF AL-HUSSAINI

Institute of Ophthalmology, London

AND

ERIC M. C. DUNLOP

Whitechapel Clinic, The London Hospital

It has long been known that the Halberstaedter-Prowazek inclusion bodies found in inclusion blennorrhoea of the conjunctiva of the newborn could sometimes be demonstrated in the cervix of the mother (Halberstaedter and Prowazek, 1909; Heymann, 1910; Thygeson, 1934; Thygeson and Mengert, 1936; Braley, 1938; Jones, Collier, and Smith, 1959; Kotcher, Gray, James, Frick, and Bottorff, 1962) and the urethra of the father (Fritsch, Hofstätter, and Lindner, 1910; Lindner, 1910).

Inclusion conjunctivitis, a syndrome diagnosed chiefly in Europe and America, has been recognized as a counterpart in the adult of the disease in the newborn. Trachoma is a more serious eye disease and is responsible for much blindness in underdeveloped countries. Corneal involvement, with the development of pannus and scarring of the conjunctiva, differentiates it from inclusion conjunctivitis. Virus was isolated from trachoma by T'ang, Chang, Huang, and Wang (1957); this was confirmed by Collier and Sowa (1958). Isolation of virus from neonatal inclusion blennorrhoea was reported by Jones and others (1959), and confirmed by Hanna, Zichosch, Jawetz, Vaughan, and Thygeson (1960).

Virus was also isolated by Jones and others (1959) from the cervix of a woman whose baby had developed inclusion blennorrhoea. This has not yet been repeated in Europe or America, but virus has been isolated from the cervix of the mother in the

case of three women in Gambia whose babies had developed ophthalmia neonatorum with inclusions (Furness, Graham, Reeve, and Collier, 1960): since one of the babies developed pannus, it is possible that these genital isolates could produce trachoma.

Hitherto, there has been no report of the isolation of this type of virus from the urethra. The nature of the agents isolated from that site by Siboulet and Galistin (1963) remains obscure.

A study of cases of infection of the eye in the adult, in which inclusions were present, indicated that in London these cases did not always fall into two entirely separate types—trachoma or inclusion conjunctivitis; several cases were better described as falling into an intermediate syndrome of punctate kerato-conjunctivitis (Jones, 1961, 1964b). Furthermore, cervicitis with inclusions was found in a patient with trachoma (Jones, 1961, 1964a). Virus of genital origin, which had been isolated from neonatal inclusion blennorrhoea, gave rise to the trachoma syndrome when inoculated into the eye of a volunteer (Jones and Collier, 1961). Mitsui, Konishi, Nishimura, Kajima, Tamura, and Endo (1962) confirmed this observation.

Laboratory investigations have not yet provided any method of distinguishing between isolates from trachoma and isolates from the other syndromes. Hence it has been agreed to refer to the elementary body viruses isolated from any of these ocular or genital conditions as TRIC virus isolates—TR from trachoma and IC from inclusion conjunctivitis (Gear, Gordon, Jones, and Bell, 1963). Using this

* Read at the Meeting of the M.S.S.V.D. in Copenhagen on June 7, 1963.

nomenclature, the syndromes that TRIC virus infection is known to cause should be referred to as follows:

Ocular syndromes in the adult:

- Trachoma
- TRIC virus punctate kerato-conjunctivitis
- Inclusion conjunctivitis

Ocular syndrome in the neonate:

- TRIC virus ophthalmia neonatorum (inclusion blennorrhoea)

Genital infection:

- TRIC virus cervicitis
- TRIC virus urethritis

Present Study

It seems that TRIC virus is responsible for an unknown proportion of so-called "non-specific" genital infection. Because of the difficulty in establishing the diagnosis of TRIC virus infection of the genital tract, attention was directed to two groups of persons believed, on epidemiological grounds, to be likely to have the condition (Dunlop, Jones, and Al-Hussaini, 1964).

The genital tract was investigated in the parents of five babies suffering from TRIC virus ophthalmia neonatorum, and also in eight adults presenting with any of the syndromes of ocular disease due to TRIC virus infection. In most instances the consorts were similarly investigated.

The aim of the study, of which the present paper is a preliminary report, was to isolate virus from the eye and the genital tract in order to establish the diagnosis, and to secure isolates of both genital and ocular origin for laboratory study and ultimate assessment of their pathogenicity for the adult eye.

Methods

Scrapings of the epithelium of the urethra, cervix, and conjunctiva were collected into bottles containing 2 ml. sucrose potassium glutamate solution (S.P.G.) with antibiotic (Bovarnick, Miller, and Snyder, 1950). These were inoculated in 0.3-ml. aliquots into the yolk sac of 6-day to 9-day embryonate hen eggs which were incubated at 35°C. The antibiotics used to prevent bacterial contamination were streptomycin, neomycin, polymyxin, ristocetin, mycostatin, and various combinations of these. From the yolk sacs, harvested as soon as possible after death of the embryo or on the 11th day, a 20 per cent. suspension in S.P.G. with streptomycin was passed in 0.3-ml. aliquots into the next series of eggs.

Yolk-sac smears, stained by Giemsa's method, were examined for elementary bodies; if the findings were equivocal, dark-ground illumination was used. Yolk sacs containing bacteria or fungi were discarded. Repeated culture on blood agar plates and in Brewer's thioglycollate medium gave no growth from membranes infected by any of the established isolates. Dr R. Lemcke of the Lister

Institute kindly tested 5th-passage yolk-sac material infected with IOL-9/GU that was used for the inoculation of baboons. There was no growth of mycoplasma after 7 days incubation on either aerobic or anaerobic plates.

Results

Seven isolations were made, in each case from scrapings in which inclusions were found (Al-Hussaini, Jones, and Dunlop, 1964); three were from TRIC virus ophthalmia neonatorum and one each from trachoma, TRIC virus punctate kerato-conjunctivitis, TRIC virus cervicitis, and TRIC virus urethritis (Table I).

TABLE I
TRIC VIRUS ISOLATIONS FROM EYE, CERVIX, AND URETHRA

Source	No. of Cases	No. with Inclusions	Isolates		
			No.	Designation	Case Nos.
Ophthalmia Neonatorum ..	5	5	3	IOL-3/ON IOL-5/ON IOL-8/ON	Baby C Baby E Baby H
Trachoma	3	2	1	IOL-6/OT	Miss F
Punctate Kerato-conjunctivitis ..	2	2	1	IOL-7/OPK	Mr G
Inclusion Conjunctivitis ..	3	3	0	O	
Cervicitis	5	1	1	IOL-4/GCx	Mrs D
Urethritis	3	3	1	IOL-9/GU	Mr H
Total	21	16	7		

Virus was not isolated from both the eye and the genital tract of any one patient, but in one family (H), virus was isolated from the baby (isolate IOL-8/ON, see Table II) and from the father's urethra (isolate IOL-9/GU). As this is the first isolation from the urethra to be recorded, the characteristics of the agent are being fully defined.

Designation of Isolates

Table II (opposite) sets out the designation of TRIC virus isolates made at the Institute of Ophthalmology, London (IOL) using the nomenclature suggested by Gear and others (1963), the site from which the isolate was made, and the associated ocular syndrome. The abbreviated designations that will be used throughout the present reports are indicated. In the case of the genital isolate IOL-4/GCx grown from the cervix of Mrs D, the term Cx in the designation has been added to indicate its origin from the cervix; similarly U has been added in the case of the genital isolate IOL-9/GU to indicate its origin from the urethra of Mr H; similarly PK has been added to the

TABLE II
DESIGNATION OF TRIC VIRUS ISOLATES, INSTITUTE OF OPHTHALMOLOGY, LONDON

Patient	Source and Associated Ocular Syndrome	Date of Yolk Sac Inoculation	Designation	Abbreviated Designation
Mr A	Trachoma	16.11.61	TRIC/ /GB/IOL-1/OT	IOL-1/OT
Miss B	Trachoma	17.11.61	TRIC/ /GB/IOL-2/OT	IOL-2/OT
Baby C	TRIC virus ophthalmia neonatorum	14.6.62	TRIC/ /GB/IOL-3/ON	IOL-3/ON
Mrs D	TRIC virus cervicitis in mother of baby with TRIC virus ophthalmia neonatorum	19.7.62	TRIC/ /GB/IOL-4/GCx	IOL-4/GCx
Baby E	TRIC virus ophthalmia neonatorum	5.10.62	TRIC/ /GB/IOL-5/ON	IOL-5/ON
Miss F	Trachoma	6.11.62	TRIC/ /GB/IOL-6/OT	IOL-6/OT
Mr G	TRIC virus punctate kerato-conjunctivitis	7.12.62	TRIC/ /GB/IOL-7/OPK	IOL-7/OPK
Baby H	TRIC virus ophthalmia neonatorum	7.12.62	TRIC/ /GB/IOL-8/ON	IOL-8/ON
Mr H	TRIC virus urethritis in father of baby with TRIC virus ophthalmia neonatorum	28.12.62	TRIC/ /GB/IOL-9/GU	IOL-9/GU

designation of the ocular isolate IOL-7/OPK to indicate its origin from the eye of Mr G suffering from TRIC virus punctate kerato-conjunctivitis.

The first two isolations (from Mr A and Miss B) were made before this investigation was started, and will not be discussed further.

Morphology

The elementary bodies in Giemsa-stained yolk-sac smears range from 0.25–0.50µ in diameter, the smaller particles being purple and the larger ones blue. They are blue with Castañeda's and red with Macchiavello's stain. Under dark-ground illumination, the stained elementary bodies gave a brilliant golden fluorescence.

Electron photomicroscopy of aluminium-shadowed preparations (Fig. 1, overleaf) of the urethral isolate IOL-9/GU (Mr H), purified by differential centrifugation with arcton 113, demonstrated that its elementary bodies have a detailed structure indistinguishable from that of other members of the psittacosis-lymphogranuloma venereum-TRIC virus (PLT) group.

Serological Reactions

The urethral isolate IOL-9/GU (Mr H) and one of the ocular isolates IOL-7/OPK (Mr G) were tested for the complement-fixing antigen of the PLT group (Table III).

Antigens were prepared from yolk-sac membranes showing +++ elementary bodies of IOL-9/GU at the 6th and of IOL-7/OPK at the 4th passage. 10 per cent. suspensions of the membranes in CaMg saline were treated with trypsin and centrifuged as described by Reeve and Taverne (1962). Control antigens were similarly prepared from a Gambian trachoma-

TABLE III

COMPLEMENT-FIXATION TITRATIONS OF RABBIT ANTISERUM, PREPARED AGAINST INCLUSION BLENNORRHOEA VIRUS LB 1, WITH DIFFERENT VIRUS ISOLATES

Antigen	Rabbit Serum	
	Anti-LB 1	Normal
IOL-9/GU (Mr H)	1:32	<1:4*
IOL-7/OPK (Mr G)	1:32	<1:4*
G 187	1:20	<1:10
Normal Yolk Sac	<1:4*	<1:4*

* Lowest dilution tested

isolate G187 and a normal yolk-sac membrane. All antigens were boiled for 20 minutes. These antigens were tested against normal rabbit serum and against a rabbit antiserum prepared against a TRIC virus isolate from the cervix, grown in He La cells. This isolate (LB1) has previously been shown to contain the group antigen shared by trachoma isolates G1 and TE55 and by psittacosis virus, when tested against serum from a patient suffering from lymphogranuloma venereum (Jones and others, 1959). All sera were inactivated for 30 minutes at 56°C. Normal guinea-pig serum stored at -20°C. without preservative was diluted to contain 2 MHD. All dilutions were prepared in CaMg saline containing 2 per cent. V/V heated guinea-pig serum. Fixation was carried out at 37°C. for 60 minutes on perspex plates in a modified Fulton and Dumbell test, using 0.5 per cent. sheep red cells sensitized with 10 MHD rabbit anti-sheep haemolysin. The results (Table III) indicate that both isolates IOL-9/GU and IOL-7/OPK contain the complement-fixing antigen of the PLT group.

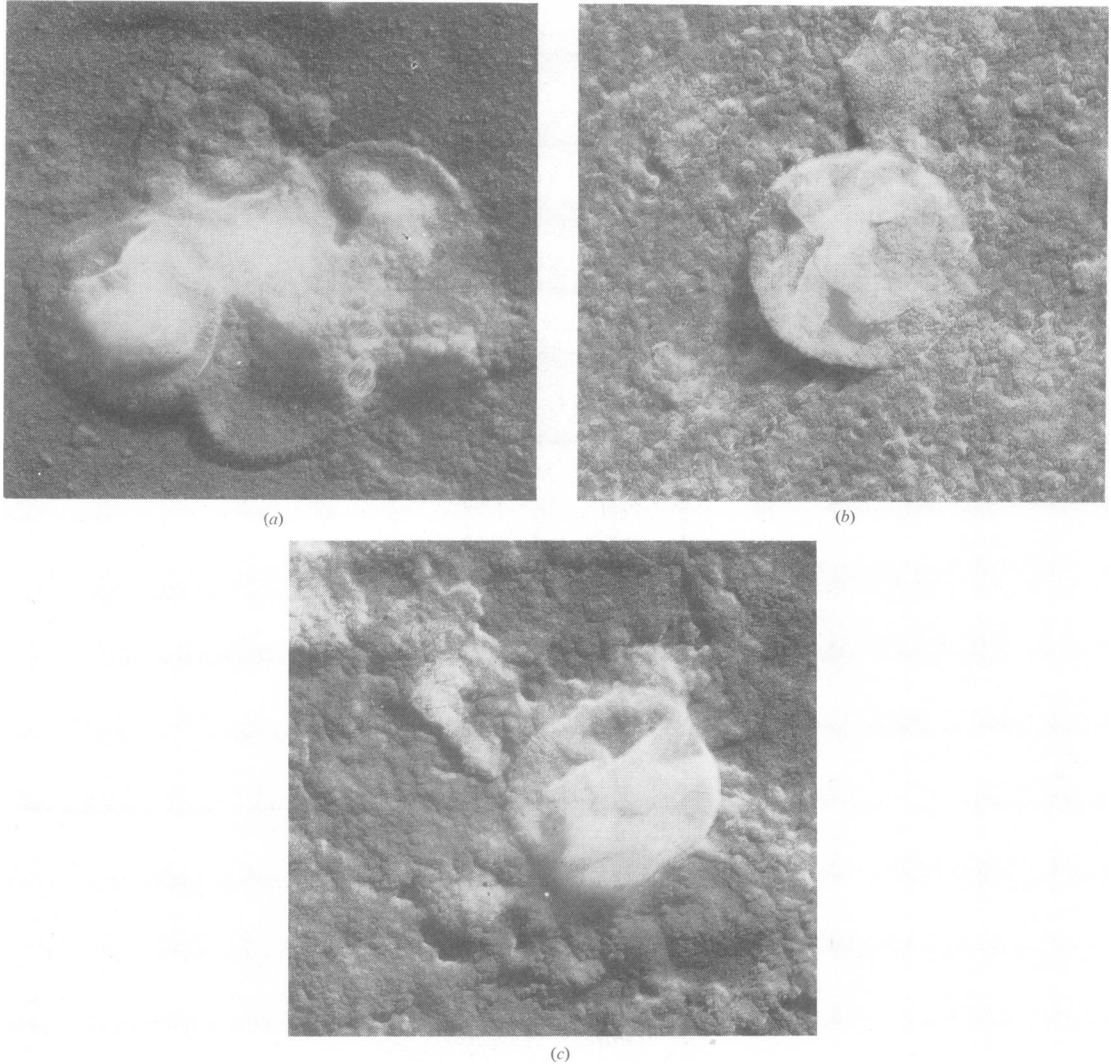


FIG. 1.—Electron micrographs of aluminium-shadowed elementary bodies of TRIC virus isolate IOL-9/GU from the urethra of Mr H ($\times 42,700$).

The results of complement-fixation tests against PLT group antigen, carried out with sera from patients in this study, are reported by Dunlop, Jones, and Al-Hussaini (1964), as are the results of intradermal tests for sensitivity to members of this group.

Host Range

(a) *Yolk Sac*.—These isolates have been passed repeatedly in the yolk sac. Some embryos show haemorrhages at the insertions of the feather shafts but no other abnormalities.

With repeated passage the mean day of embryo

death has stabilized to 9 days with most isolates. One isolate (IOL-7/OPK) is of interest because on two occasions, at different pass levels, and in different virus growth-lines, the mean day of death has suddenly changed to the 5th day.

(b) *Intracerebral Passage* in suckling mice and

(c) *Intraperitoneal Passage* in mice and guinea-pigs are in progress, and up to the third passage show no direct evidence of virus growth.

(d) *Conjunctival Inoculation* of mice, rabbits, and guinea-pigs gave no evidence of infection.

(e) *Inoculation of the Right Eye* of each of three baboons (*Papio cynocephalus*), with the urethral isolate IOL-9/GU, by the technique previously described (Jones and others, 1959) was followed 4 days later by a mild acute mucopurulent conjunctivitis. The inflammation became less acute after the 7th to 9th day, and progressively more follicular up to the 4th week.

Initial bodies and numerous Halberstaedter-Prowazek inclusion bodies, with iodine-staining matrices (Fig. 2) were found in the conjunctival scrapings in which the cytological findings were typical of a TRIC virus conjunctivitis. Virus was re-isolated from the right eye of one baboon, 10 days after inoculation. This experiment, and the results of inoculation of the genital tract of both male and female prepubertal baboons and postpubertal monkeys, will be reported separately.

Discussion

Isolation of virus established a diagnosis of TRIC virus infection of the genital tract in the case of only two of eight parents of babies suffering from ophthalmia neonatorum due to this cause. The isolation of virus was a less sensitive diagnostic measure than the finding of inclusions as these were found in four cases. It has, however, provided a second isolate from the cervix in Britain and the first isolate from a male with so-called "non-specific" urethritis. To date this isolate from the urethra behaves as a typical TRIC virus member of the PLT group. The way is thus open to assess the pathogenicity for the human eye of virus of urethral origin and thereby to clarify the relationship of two of the common infections of man, namely trachoma and non-specific urethritis.

Summary

Two groups of persons were studied who were believed on epidemiological grounds to be likely to have TRIC virus infection of the genital tract.

(1) The genital tract was investigated in the parents of babies suffering from TRIC virus ophthalmia neonatorum.

(2) The genital tract was investigated in adults presenting with any of the syndromes of ocular disease due to TRIC virus infection. In some instances, the consorts were similarly investigated.

By inoculation of the yolk sacs of embryonate hen eggs, elementary body viruses were isolated in seven

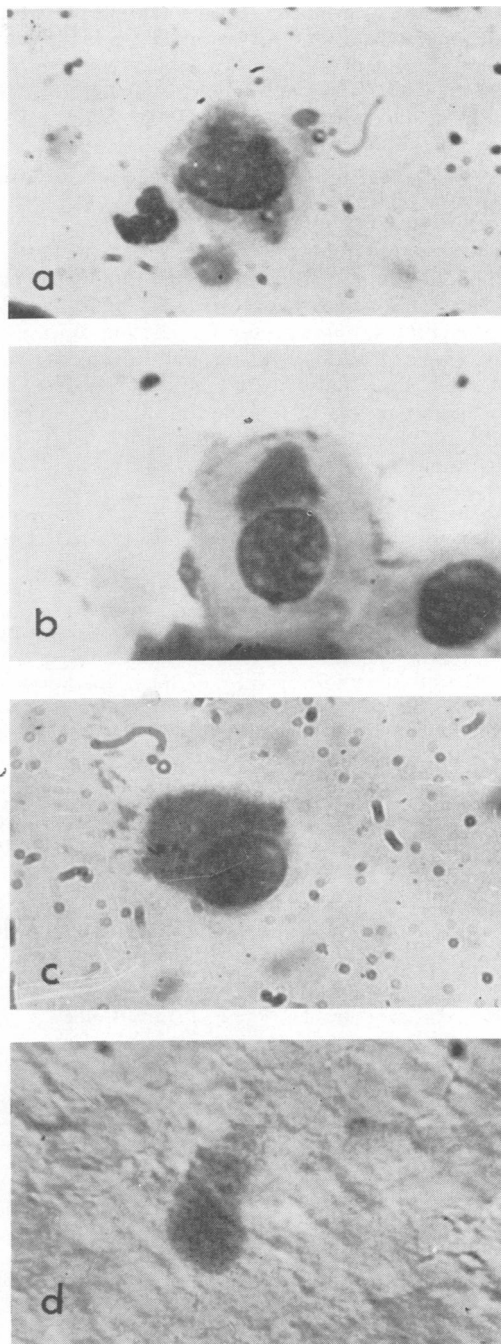


FIG. 2.—Scrapings from the conjunctiva of baboons inoculated with TRIC virus isolate IOL-9/GU from urethra of Mr H ($\times 900$).

- (a) Baboon 2 on D3 (third day after inoculation), showing initial bodies.
 (b) Baboon 1 on D3, showing Halberstaedter-Prowazek inclusion body.

(c) Baboon 2 on D3, showing Halberstaedter-Prowazek inclusion body.

(d) Baboon 3 on D3, showing iodine-stained matrix of inclusion body.

(a, b, c stained by Giemsa; d stained by iodine).

cases; in each instance from scrapings in which inclusions were found. Isolations were made from the conjunctiva of three of five babies suffering from neonatal TRIC virus ophthalmia (Babies C, E, H), and from the cervix of Mrs D (isolate IOL-4/GCx). Three of the fathers (D, C, H) were found to have non-specific urethritis with inclusions in urethral scrapings, and virus was isolated from Mr H (isolate IOL-9/GU).

This agent contains the complement-fixing antigen of the PLT group of viruses. By electron microscopy its elementary bodies were seen to resemble those of other members of this group. Inoculation of the eyes of baboons with this agent resulted in conjunctivitis with inclusions. These positive results, together with the negative results of inoculation of lower animals establish that the agent of urethral origin is a TRIC virus isolate.

We are grateful to Dr L. H. Collier, Honorary Director, Medical Research Council Trachoma Research Unit, Lister Institute of Preventive Medicine, who has given valuable advice; to Miss Wendy Wallers and Dr Peter Reeve, who carried out the complement-fixation titrations at the M.R.C. Trachoma Research Unit, Lister Institute of Preventive Medicine; to Mrs R. Tilly, who prepared the electron photomicrographs in the Department of Anatomy, Institute of Ophthalmology; and to Mr V. Ponnuswamy and Mr J. Kinnison for technical assistance.

REFERENCES

- Al-Hussaini, M. K., Jones, B. R., and Dunlop, E. M. C. (1964). *Brit. J. vener. Dis.*, **40**, 25.
- Bovarnick, M. R., Miller, J. C., and Snyder, J. C. (1950). *J. Bact.*, **59**, 509.
- Braley, A. E. (1938). *Amer. J. Ophthalm.*, **21**, 1203.
- Collier, L. H., and Sowa, J. (1958). *Lancet*, **1**, 993.
- Dunlop, E. M. C., Jones, B. R., and Al-Hussaini, M. K. (1964). *Brit. J. vener. Dis.*, **40**, 33.
- Fritsch, H., Hofstätter, A., and Lindner, K. (1910). *v. Graefes Arch. Ophthalm.*, **76**, 547.
- Furness, G., Graham, D., Reeve, P., and Collier, L. H. (1960). *Rev. int. Trachome*, **37**, 574.
- Gear, J. S., Gordon, F. B., Jones, B. R., and Bell, S. D. (1963). *Nature*, **197**, 26.
- Halberstaedter, L., and von Prowazek, S. (1909). *Berl. klin. Wschr.*, **46**, 1839.
- Hanna, L., Zichosch, J., Jawetz, E., Vaughan, D. G., and Thygeson, P. (1960). *Science*, **132**, 1660.
- Heymann, B. (1910). *Berl. klin. Wschr.*, **47**, 663.
- Jones, B. R. (1961). *Trans. ophthalm. Soc. U.K.*, **81**, 367.
- (1964a). *Rev. int. Trachome* (in press).
- (1964b). *Asian Arch. Ophthalm.* (in press).
- and Collier, L. H. (1962). *Ann. N.Y. Acad. Sci.*, **98**, 212.
- , —, and Smith, C. H. (1959). *Lancet*, **1**, 902.
- Kotcher, E., Gray, L. A., James, Q. C., Frick, C. A., and Bortorff, D. W. (1962). *Ann. N.Y. Acad. Sci.*, **97**, 571.
- Lindner, K. (1910). *Wien. klin. Wschr.*, **23**, 283.
- Mitsui, Y., Konishi, K., Nishimura, A., Kajima, M., Tamura, O., and Endo, K. (1962). *Brit. J. Ophthalm.*, **46**, 651.
- Reeve, P., and Taverne, J. (1962). *J. gen. Microbiol.*, **27**, 501.
- Siboulet, A., and Galistin, P. (1962). *Brit. J. vener. Dis.*, **38**, 209.
- T'ang, F.F., Chang, H.L., Huang, Y. T., and Wang, K. C. (1957). *Chin. med. J.*, **75**, 429.
- Thygeson, P. (1934). *Amer. J. Ophthalm.*, **17**, 1019.
- and Mengert, W. F. (1936). *Arch. Ophthalm. (Chicago)*, **15**, 377.

Infection génitale avec infection oculaire due au virus TRIC I. Isolation du virus de l'urètre, du col de l'utérus, et de l'oeil

RÉSUMÉ

On étudia deux groupes de personnes que l'on croyait atteintes d'infection génitale par le virus TRIC.

(1) Les parents d'enfants atteints d'ophtalmie infantile due au virus TRIC.

(2) Les adultes atteints de n'importe quelle infection oculaire par le virus TRIC.

Dans sept cas on isola les corps de virus élémentaires par inoculation des oeufs embryonnaires de poulet; dans chaque cas on trouva des inclusions dans les frottis. On isola le virus de la conjonctivite de trois nouveau-nés sur cinq atteints (Enfants C, E, H) et du col de l'utérus de Mme D (Isolat IOL-4/GCx). Trois des pères (D, C, H) furent atteints d'urétrite non-spécifique, avec inclusions dans les frottis urétraux, et de H on isola le virus (Isolat IOL-9/GU).

Cet agent contient l'antigène fixant le complément des virus psittacose-lymphogranulome-trachome (PLT). Par le microscope électronique on voit que les corps élémentaires ressemblent à ceux d'autres virus de ce groupe.

L'inoculation de cet agent dans les yeux de babons produisit une conjonctivite à inclusions. Ces résultats positifs, avec les résultats négatifs d'inoculation dans les yeux d'animaux moins développés, démontrent que cet agent d'origine urétrale est en effet un isolat du virus TRIC.