

CORRECTION

Open Access



# Correction: Inflammatory myofibroblastic tumor of the thigh without bone involvement: a case report

Jun Lin<sup>1†</sup>, Hao Liu<sup>1†</sup>, Yin Zhuang<sup>1</sup>, Peng Yang<sup>1</sup>, Yifei Zheng<sup>1</sup>, Yan Yang<sup>1</sup> and Huilin Yang<sup>1\*</sup>

**Correction: World J Surg Onc 12, 208 (2014)**  
<https://doi.org/10.1186/1477-7819-12-208>

Following the publication of the original article [1], the author reported that Fig. 3D is a repetition of Fig. 3C. The correct figure is included here.

Published online: 05 September 2023

## Reference

1. Lin J, Liu H, Zhuang Y, et al. Inflammatory myofibroblastic tumor of the thigh without bone involvement: a case report. *World J Surg Onc.* 2014;12:208. <https://doi.org/10.1186/1477-7819-12-208>.

---

<sup>†</sup>Jun Lin and Hao Liu contributed equally to this work.

The original article can be found online at <https://doi.org/10.1186/1477-7819-12-208>.

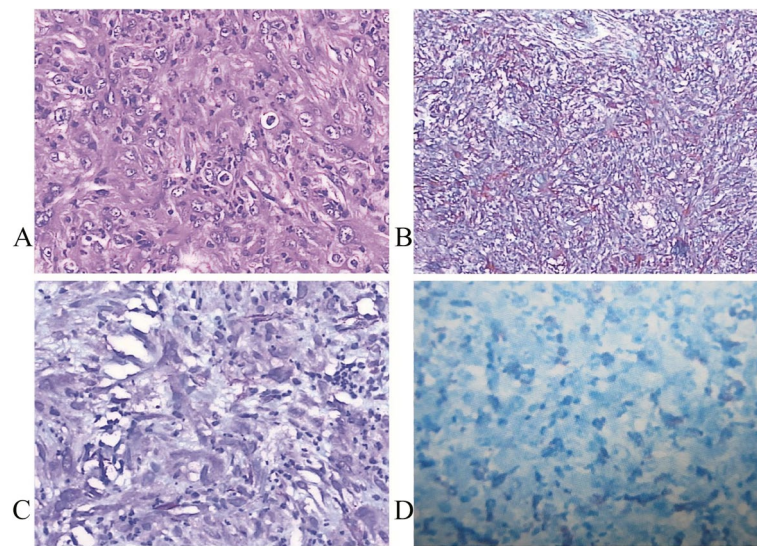
\*Correspondence:

Huilin Yang

[hlyangszhou@gmail.com](mailto:hlyangszhou@gmail.com)

<sup>1</sup> Department of Orthopedic Surgery, The First Affiliated Hospital of Soochow University, 188 Shizi Street, Suzhou 215006, Jiangsu, China





**Fig. 3** Photomicrograph by hematoxylin–eosin (HE) and immunohistochemistry staining for tumor. Photomicrograph showing proliferation of eosinophilic spindle cells with numerous inflammatory cells including lymphocytes and few granulocytes. [HE, original magnification,  $\times 200$ ] (A). Immunohistochemistry revealed tumor cell immunoreactivity for vimentin (B), smooth muscle actin (SMA) (C), and CD68 (D) (original magnification,  $\times 200$ )