

Syphilis maligna praecox

A case report

K. LEJMAN AND Z. STARZYCKI

From the Dermatological Clinic, Medical Academy, Kraków, Poland

The opinions of syphilologists concerning the pathogenesis of syphilis maligna praecox (SMP) are not unanimous. Some authors maintain that there is a lowering of resistance in such cases, but others explain the appearance of ulcerative lesions in the course of SMP as a hyperergic reaction to *T. pallidum*. The concept of serological anergy, thought in the past to be one of the characteristic features of SMP, and the idea of an enhanced virulence of *T. pallidum*, find no support in the most recent communications. Most authors agree that it is very difficult to find *T. pallidum* in the lesions of SMP. In the last decade these problems have been fully discussed by Wiedmann (1962) and Krüger (1965) as well as by Adam and Korting (1960), Cripps and Curtis (1967), and Fisher, Chang, and Tuffanelli (1969).

The following clinically typical case of SMP was characterized by the presence of very large numbers of *T. pallidum* both in the exudates and in histological preparations of specific lesions.

Case report

A 27-year-old unmarried male hairdresser was admitted to the Dermatological Clinic on July 11, 1969, with abundant pustulo-ulcerative lesions disseminated over the trunk and extremities. He said that he had intercourse with an unmarried woman 11 months before. Several weeks after the sexual contact an ulceration on the skin of the penis began and after another 3 to 4 weeks an eruption composed of papulo-pustular elements appeared on the trunk and limbs. The lesions grew slowly, and 2 months before he came to the clinic they began to ulcerate centrally.

The patient recognized the nature of his illness, but did not want any medical treatment. He gave up work, isolated himself, and started to drink alcohol to excess. His diet was unsatisfactory and he lost weight substantially.

Examination

He was of normal build, 179 cm. tall, and weighing 67 kg. He was afebrile; blood pressure 130/80, pulse 78 and regular.

On his trunk and partially on the upper and lower extremities there was an abundant eruption of papulo-pustular and nodulo-pustular elements, round or oval, centrally collapsed, filled with a dark, moist crust, and surrounded with an erythematous halo (Fig. 1).

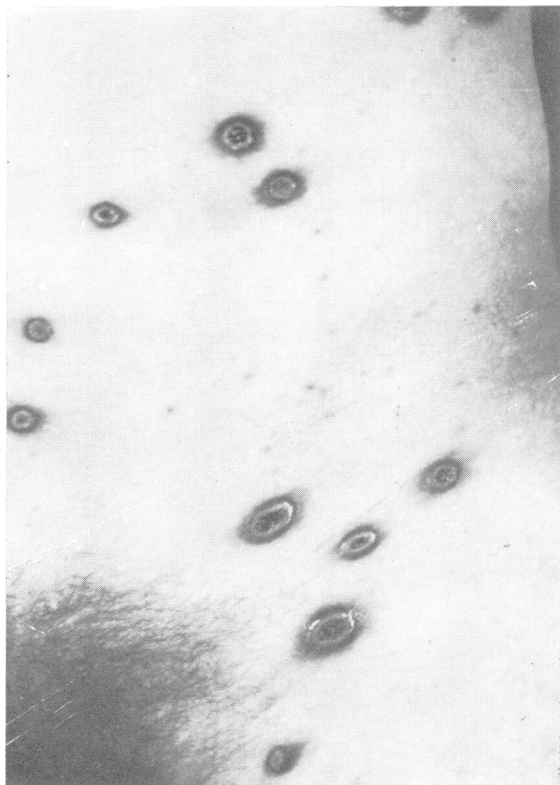


FIG. 1 *Early nodulo-pustular eruption on the trunk*

Below the axillae and on the back, the papules had become necrotic, mostly oval ulcerations, reaching the size of 5 × 3 even 6 × 4 cm. (Fig. 2). When the base of these ulcerations was pressed, a profuse blood-stained seropurulent secretion could be seen. It was possible to observe the different stages of the development of these

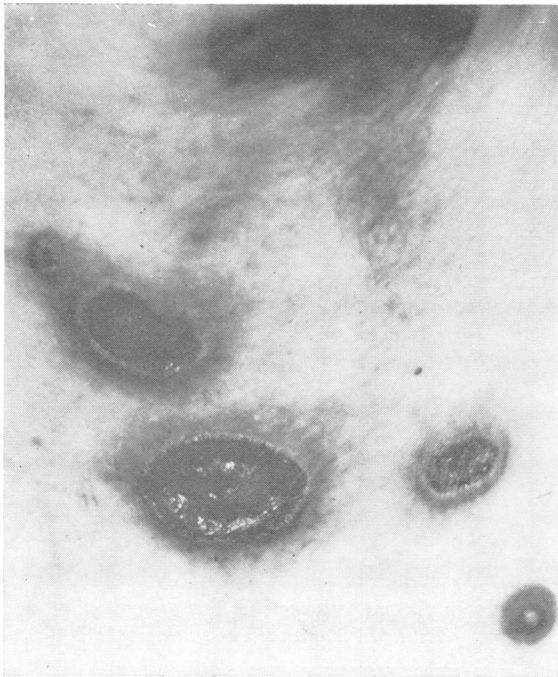


FIG. 2 Early necrotic syphilitic ulcers beneath axilla

lesions, from those of cherry-stone size to the ulcerations described above. All lesions were painless: the isolated ones were found on the scalp and on the face. In the ano-genital region there were typical abundant condylomatous oozing lesions. On the palms and soles there were flat infiltrated brownish papules partly covered with scales. The mucous membranes were free from specific lesions but there were symptoms of angina syphilitica and hoarseness. There was generalized enlargement of the lymph nodes. The primary chancre on the anterior surface of the prepuce had healed, leaving a flat, smooth, depigmented scar.

Laboratory findings

Dark field examination of the discharge obtained by pressure on the nodulo-pustular lesions revealed very large numbers of typical, vigorously motile *Treponema pallida*. Saprophytic treponemes were absent. The bacterial flora was scanty, but *Staphylococcus aureus* and *Streptococcus pyogenes* were cultured.

Haemoglobin 12.5 g./100 ml., WBC 5,700 per cu. mm. (neutrophils 55 per cent., eosinophils 5 per cent., lymphocytes 39 per cent., monocytes 1 per cent.). Erythrocyte sedimentation rate 110 mm./hr. Urine analysis and chest X-ray within normal limits. Serum bilirubin 0.52 mg per cent. Total serum protein 8.35 g./100 ml. Serum protein electrophoresis showed dysproteinaemia with low albumin, and raised alpha₂ and gamma-globulin. Immunoelectrophoresis showed raised levels of IgG, IgM, and IgA, and lowered values of albumin.

Serological tests

The Wassermann reaction (WR) was strongly positive, the VDRL reactive at a titre 1:32, the FTA-200 test reactive at a titre 1:36,000, and the TPI test positive, with 100 per cent. immobilization.

Lumbar puncture

Cerebrospinal fluid cell count 5 cells/cu. mm.; protein 26 mg. per cent; Pandy, Nonne-Appelt, and Weichbrodt tests weakly positive; WR and VDRL negative.

Histopathology

A small lesion from the skin of the patient's back was biopsied, and the sections stained with haematoxylin and eosin (HE) and with the modification of the Krajian silver stain (Walter, Smith, Israel, and Gager, 1969).

Sections stained with HE revealed that the centre of the lesion was covered with a thick, stratified crust composed of alternating layers of drying pus and parakeratotic epidermis. The recent sub-epidermal pustules were seen at the base and on the margins of the crust, so that it appeared to be obvious that the crust had developed from repeated formation of pustules at the same site. There was a massive migration of leucocytes through the epidermis at the base of the pustules. The structure of the skin was destroyed by a massive infiltrate mainly composed of plasma cells. In the deeper layers of the infiltrate, irregular bands of young connective tissue were seen. Agglomerates of neutrophils and eosinophils were scattered irregularly through the infiltrate. Blood vessel lesions increased proportionally to their size. The number of capillaries beneath the pustule was increased and their lumina were narrowed by endothelial swelling and proliferation. Medium-sized vessels showed thickening or lamination of the walls and were often completely occluded by thrombi and proliferative processes.

The sections stained with the modification of Krajian silver stain revealed the following:

In the epidermis treponemes were dispersed between the cells of the rete Malpighi, although not in large numbers.

T. pallida appeared in very large numbers throughout the infiltrated skin, dispersed between plasma cells (Fig. 3, overleaf).

Some of the plasma cells showed nuclei with cloudy contours, and were probably undergoing necrosis due to the toxic influence of *T. pallidum*.

T. pallida had penetrated the blood vessel walls causing alteration and swelling of the endothelial cells (Fig. 4, overleaf).

T. pallida were present in large numbers even in the thrombi which occluded the lumina of the capillaries (Fig. 5, overleaf).

Treatment and course

Early malignant, nodulo-pustular and ulcerative syphilis was diagnosed and treatment was started with penicillin, but a Herxheimer reaction set in very soon after the first injection of 600,000 u. procaine penicillin (July 14, 1969), much sooner than is usually observed in cases of secondary syphilis. Fever began after 90 minutes

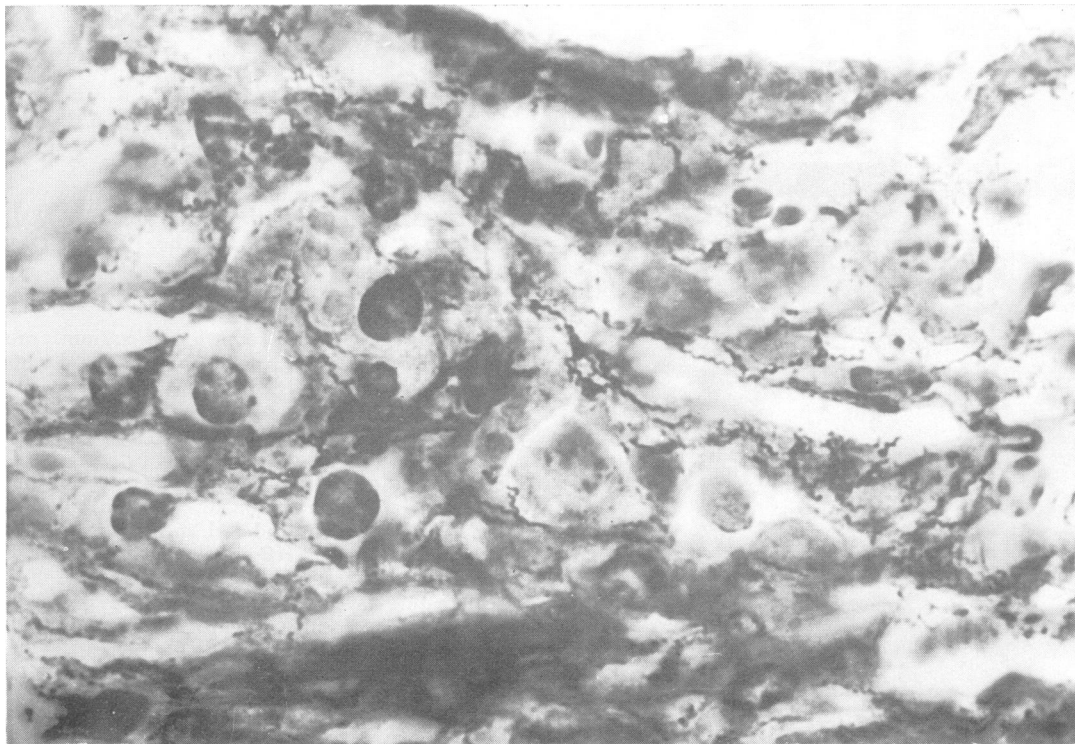


FIG. 3 *Infiltrate in upper dermis. Spreading of T. pallida between plasma cells and necrosis of some plasma cells. The walls of a capillary vessel are infiltrated by T. pallida. Modified Krajan silver stain. $\times 1,200$*

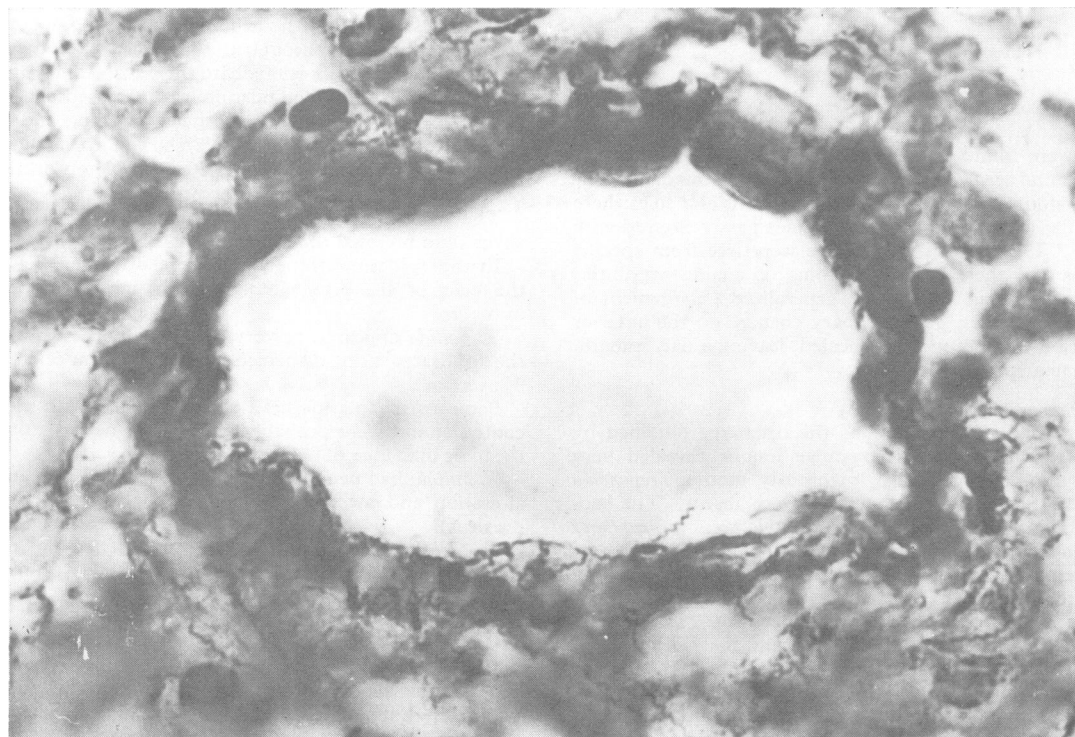


FIG. 4 *Dilated precapillary vessel from upper layers of infiltrate, beneath pustule. Swollen endothelium, overlaid by T. pallida. Modified Krajan silver stain. $\times 1,200$*

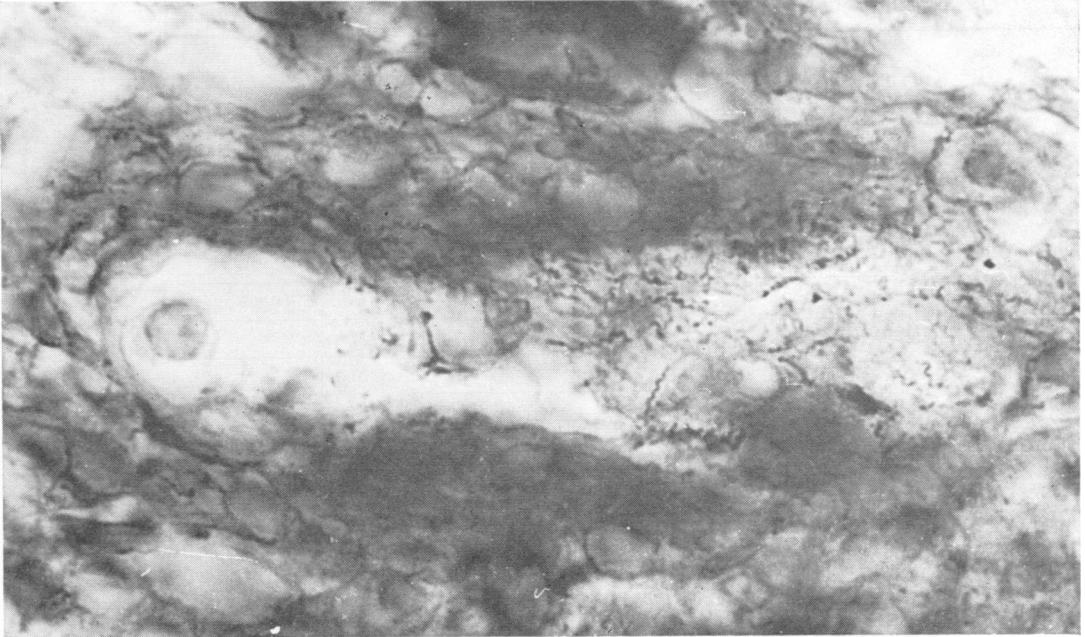


FIG. 5 *Tangential section through wall and lumen of a partially thrombosed capillary vessel, showing large masses of T. pallida. Modified Krajan silver stain. $\times 1,000$*

and 5 hours after the injection it reached its maximum (40.3°C). After another 4 hours the temperature was still 39°C ., and 19 hours later it was back to normal. The fever was accompanied by chills, sweating, headache, and malaise.

The patient was given 600,000 u. procaine penicillin intramuscularly daily for 15 days, and then 900,000 u. daily. The total dose was 30.6 m.u. given during 39 days.

The lesions responded well to the treatment. After the 5th injection of penicillin the process of resorption began and by the 30th day all lesions had healed, leaving flat depigmented scars.

The general condition of the patient improved remarkably and he gained 4.5 kg. in weight.

Result

After the completion of treatment on August 20, 1969, the WR was still strongly positive and the VDRL was reactive at titre 1:64. The same serological results were noted on September 15, 1969. The patient then failed to re-attend until March 4, 1971, when all the scars were sharply demarcated, with slightly bulging foci of anetoderma with a characteristic wrinkled surface, yielding on pressure. The WR was negative, the VDRL reactive at a titre of 1:2, the TPI test positive with 100 per cent. immobilization, and the FTA-200 test titre decreased to 1:450.

Results of examination of the female partner and of other males infected by her with syphilis

An unmarried woman aged 25, the partner of the patient described above, was examined on May 27, 1969.

She had early recurrent syphilis, with papular lesions in the ano-genital region, syphilitic leucoderma, and alopecia.

Between November 11, 1968, and May 15, 1969, 7 other male partners of this woman were all infected with syphilis and reported to the out-patient department (Table, overleaf).

Only Case 8, the subject of this paper, showed signs of malignancy. In three males the solitary primary chancres were situated almost in the same region, and secondary lesions were of the usual appearance.

Discussion

The case presented fulfils the clinical criteria for SMP which, according to the opinions of older authors (as reviewed by Cripps and Curtis, 1967) and contemporary investigators (Lees and Fowler, 1948; Adam and Kortling, 1960; Schönfeld and Schneider, 1969; Fisher and others, 1969) corresponds to the severe form of the secondary stage and not to the early manifestations of tertiary syphilis.

TABLE Results of clinical and serological examinations of eight men infected with syphilis by one woman

Patient no.	Age (yrs)	Signs of early syphilis	Date of diagnosis	Serological tests	
				WR	VDRL
1	30	Primary Chancere on inner surface of prepuce	January 6, 1969	++	1/32
2	34	Primary Chancere in coronal sulcus	November 28, 1968	+++	1/16
3	37	Primary Chancere on inner surface of prepuce	January 1, 1969	+	1/2
4	19	Secondary, macular	March 27, 1969	+++	1/64
5	57	Secondary, macular	May 27, 1969	+++	1/64
6	48	Secondary, maculo-papular	March 21, 1969	+++	1/64
7	35	Secondary, psoriasiform on palms	March 6, 1969	+++	1/64
8	27	Secondary malignant nodulo-pustular and ulcerative	September 3, 1968	+++	1/32

In favour of the secondary stage, in our case, were the multiplicity and symmetry of lesions, their early appearance and evolution from nodulo-pustular elements to ulcerations, and finally the lack of central healing and of a tendency to arciform configurations (Schönfeld and Schneider, 1969; Fisher and others, 1969).

Our patient's case also conformed to further criteria stated by Fisher and others (1969): strongly positive serological test results, severe Herxheimer reaction, and excellent response to antibiotic therapy. It should also be emphasized, in the light of contemporary syphilis serology, that seronegativity in the course of SMP seems to be an exceptional phenomenon, as in the case reported by Cripps and Curtis (1969).

Finally, the infiltrate within the lesions, composed almost entirely of plasma cells, corresponds to early syphilis.

The slow evolution of large ulcerative lesions from smaller papulo- and nodulo-pustular elements and the duration of the whole process for many months, should be regarded as a feature peculiar to our case. These lesions contained an abundance of *T. pallida*, but as no biopsy was taken from the margin of an ulceration, we cannot say whether the organisms disappeared within these advancing lesions. If such a phenomenon had been observed, one further diagnostic criterion of SMP would have been fulfilled: the absence of *T. pallida* in ulcerative lesions in this form of syphilis.

Fortunately, we were able to observe the course of the disease in seven other subjects infected by the same woman as the patient with early malignant syphilis. All these seven men showed the customary picture of early syphilis, with no sign of malig-

nancy. The infection took a severe course only in this one healthy but chronically intoxicated man. This supports the concept of the role of lowered resistance to the organism in the pathogenesis of SMP.

The uncommon centrally collapsed nodulo-pustular elements of the eruption which were observed in our case correspond well with the terms 'great pox', *grosse vérole*, and similar names in different languages, used by 16th century authors to describe the 'new', severe disease, characterized by much greater pustular lesions than the umbilicated pustules of 'small pox' or *petite vérole* which were already well known in Europe.

Summary

A case is described of early malignant syphilis characterized by a nodulo-pustular eruption disseminated symmetrically over the trunk and extremities, abundant in *T. pallida* and evolving slowly into ulcerative lesions. The results of serological tests were strongly positive. The patient did not attend the clinic until 11 months had elapsed since sexual exposure, and during that period he had been drinking alcohol to excess. He was one of eight men infected by the same woman and was the only one who developed the severe symptoms of malignant syphilis. The lesions responded well to penicillin, leaving anetodermic scars.

References

- ADAM, W., and KORTING, G. W. (1960) *Arch. klin. exp. Derm.*, **210**, 14
 CRIPPS, D. J., and CURTIS, A. C. (1967) *Arch. intern. Med.*, **119**, 411
 —, — (1969) *Arch. Derm. (Chicago)*, **100**, 122

- FISHER, D. A., CHANG, L. W., and TUFFANELLI, D. L. (1969), *Ibid.*, **99**, 70
- KRÜGER, G. H. (1965) In 'Dermatologie und Venereologie', ed. H. A. Gottron and W. Schönfeld, band 5, teil 2, pp. 918. Thieme, Stuttgart
- LEES, R., and FOWLER, W. (1948) *Brit. med. J.*, **1**, 451
- SCHÖNFELD, W. (ed. W. Schneider) (1969) 'Lehrbuch der Haut- und Geschlechtskrankheiten', 10th ed., pp. 441. Thieme, Stuttgart
- WALTER, E. K., SMITH, J. LAWTON, ISRAEL, C. W., and GAGER, W. E. (1969) *Brit. J. vener. Dis.*, **45**, 6
- WEIDMANN, A. (1962) In 'Handbuch der Haut und Geschlechtskrankheiten J. J. Jadassohn Ergänzungswerk ed. A. Marchionini', band 6, teil 2, bandteil A, pp. 169. Springer, Berlin

Un cas de syphilis maligne précoce

SOMMAIRE

On décrit un cas de syphilis maligne précoce caractérisée par une éruption nodulo-pustuleuse disséminée symétriquement sur le tronc et les extrémités, abondante en *T. pallida*, et évoluant lentement vers des lésions ulcéreuses. Les épreuves sérologiques furent fortement positives. Onze mois s'étaient écoulés entre le rapport infectant et le moment où le malade se présenta à la clinique; pendant ce temps, celui-ci avait bu de l'alcool en excès. Il figurait parmi huit hommes infectés par la même femme et fut le seul à manifester des symptômes graves de syphilis maligne. Les lésions répondirent bien à la pénicilline, laissant des cicatrices anétodermiques.