

TABLE Comparison of two patients

	Patient of Verjaal and De Nef ¹	Our patient
Growth and performance		
Prenatal onset growth deficiency	+	+
Psychomotor retardation	+	+
Decreased visual responsiveness	+	+
Hearing loss	+	+
Craniofacies		
Microcephaly	+	+
Triangular face	+	+
Micrognathia	+	+
Prominent nasal bridge	0	+
Hypoplastic nasal alae	-	+
Eyes		
Ptosis	+	+
Short palpebral fissures	0	+
Epicanthal folds	+	+
Upward slanting palpebral fissures	+	-
Ears		
Malformed	+	+
Preauricular pits	+	-
Other		
Polydactyly (postaxial)	+	+
	(feet)	(hands)
Cryptorchidism	+	+
Heart murmur	+	+
Limited joint mobility	-	+
Hernias	-	+

the severe ptosis, however, has made only a slight difference in the child's visual responsiveness.

Comparison of the two cases indicates that monosomy 3p forms a clinically recognisable pattern of malformation which should be considered in the face of prenatal onset growth deficiency, small ears, ptosis, and postaxial polydactyly.

The authors wish to thank Dr J J De Nef for generously providing follow-up information on the previously reported child, and Marian Gallagher for her assistance in the preparation of the manuscript.

Addendum

Since this article was submitted for publication, we have become aware of two further cases with identical deletions of chromosome 3.² The children, both females, aged 11 and 3 years, also had severe growth and mental deficiency, microcephaly, ptosis, micrognathia, and altered ear structure. The findings further support the hypothesis that monosomy 3 (p25) has a distinct clinical phenotype.

MARILYN C HIGGINBOTTOM,
JAMES T MASCARELLO,
HAROLD HASSIN,
AND WILLIAM K MCCORD
*Department of Pediatrics,
University of California, San Diego,
and the Children's Hospital and Health Center,
San Diego, California, USA*

References

- Verjaal M, De Nef J. A patient with a partial deletion of the short arm of chromosome 3: karyotype: 46 XY,del(3)(p25). *Am J Dis Child* 1978;132:43-5.
- Garcia Sagredo JM, Quintana Castilla A, Ludena Carpio MC. The phenotype of partial monosomy 3 (p25→pter) observed in two unrelated patients. *Abstract from Symposium of the European Society of Human Genetics, Zurich, 26-28 March 1981: 69.*

Requests for reprints to Dr Marilyn C Higginbottom, Children's Hospital and Health Center, 8001 Frost Street, San Diego, California 92123, USA.

Chronic renal disease, myotonic dystrophy, and gonadoblastoma in XY gonadal dysgenesis

SUMMARY A patient with XY gonadal dysgenesis and gonadoblastoma showed myotonic dystrophy and chronic renal disease of unknown aetiology. The coexistence of renal disease and XY gonadal dysgenesis in this and two other subjects suggests a presently obscure aetiological relationship between the phenomena.

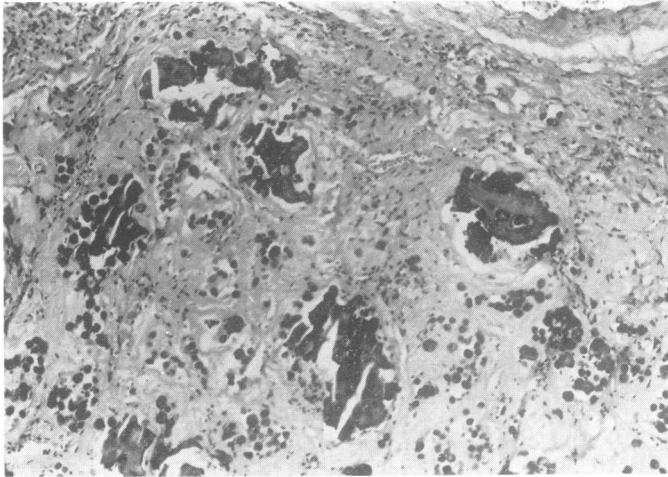
XY gonadal dysgenesis is a genetically heterogeneous group of disorders, the most common form being an X linked recessive or male limited autosomal dominant disorder in which phenotypic females have bilateral streak gonads and fail to undergo normal secondary sexual development.^{1,2} The pathogenesis is uncertain^{3,4} and H-Y antigen may or may not be present.⁵ Gonadoblastomas or dysgerminomas have been reported in 20 to 30% of cases.⁶

Blanchet *et al*⁷ reported a patient who, in addition to XY gonadal dysgenesis, showed renal failure resulting from "interstitial nephritis". While the patient was receiving immunosuppressive therapy, a gonadoblastoma was discovered after renal transplantation. However, the authors did not attribute the development of neoplasia to immunosuppression. Harkins *et al*⁸ also observed renal failure of unknown origin. Similarly, we have observed renal failure in a patient with XY gonadal dysgenesis who not only had gonadoblastoma but also myotonic dystrophy, an autosomal dominant trait.

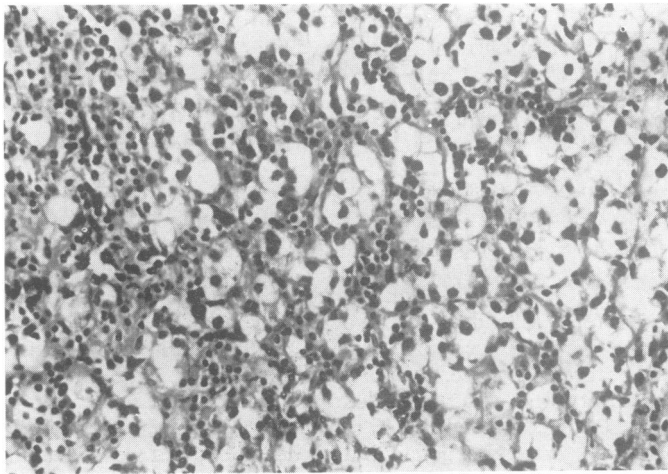
Case report

The proband was born to a 35-year-old father and a 32-year-old mother. The patient, her father, and her

Supported in part by grants HD 11021, HD 02840, CA 19822, HD 82855, HD 04134, from the National Institutes of Health.
Received for publication 26 April 1981



(a)



(b)

FIGURE (a) Extensive fibrosis and mulberry-like calcification characteristic of most of the tumour mass. (Original magnification, $\times 32$.) (b) Higher magnification showing the abundant pale cytoplasm and the darkly-stained nuclei of the germ cells. Small lymphocytes are scattered throughout the tumour. (Original magnification, $\times 80$.)

paternal aunt had muscle disease, cataracts, and other stigmata of myotonic dystrophy. The diagnosis of myotonic dystrophy was established in the proband by muscle biopsies and electromyography. Several other males in the family were said to show premature balding, but none complained of weakness. The proband's male and female sibs were unaffected.

Infancy and early childhood development were considered normal in the proband. Although active and healthy at that time, routine urine analysis at 17 years of age revealed albuminuria. Over the next $2\frac{1}{2}$ years the patient was admitted to hospital on several occasions because of persistent proteinuria; haematuria was not present. Intravenous urography

and cystoscopy showed no abnormalities, but proteinuria continued. At the age of 20 years, the patient developed ankle oedema. One year later she noted easy tiring, occasional nausea, headaches, blurred vision, and hypertension that was controlled with methyldopa. Renal function (creatinine clearance tests) was less than 5% of normal and peritoneal dialysis was required. At the age of 21 years the patient was admitted for renal transplantation.

She had undergone no spontaneous secondary sexual development by the age of 17 years. At that time, administration of birth control pills led to withdrawal uterine bleeding, but cessation of hormones resulted in no subsequent uterine bleeding. No further hormones were administered, but at

the age of 19 years the patient experienced spontaneous uterine bleeding for several consecutive months. Breast development and pubic hair development also occurred.

At 21 years the patient was 162 cm tall. Blood pressure was 130/80. Facial muscles were atrophic and her face was expressionless. Her grasp showed typical myopathic behaviour, confirmed in the lower extremities and in the upper right extremity by electromyography. Slit lamp examination showed no cataracts. Scalp hair distribution was normal. Breast development was at Tanner stage 2. External genitalia were normal and the uterus was small but well-differentiated. Initially, a pelvic examination revealed no abnormalities. However, pelvic x-rays, made as a result of genetic consultation, revealed a calcified pelvic mass, following which a right adnexal mass was detected on pelvic examination. Chromosomal analysis of lymphocytes revealed a 46,XX complement, without evidence of mosaicism. Buccal epithelial cells contained Y chromatin but not X chromatin.

At the age of 21, the patient received a renal transplant from her mother. The graft was placed in the patient's right iliac fossa through a retroperitoneal approach. Bilateral nephrectomy was subsequently performed. The left and right kidneys weighed 44 and 45 g, respectively; both showed advanced total glomerular sclerosis with marked tubular atrophy and interstitial fibrosis. The walls of the small arteries and arterioles were characterised by marked fibrous intimal thickening and medial hypertrophy consistent with hypertensive nephropathy. The findings were those of an end-stage renal disease. No definite aetiological designation was possible.

After normal renal function was established by the transplanted kidney, exploratory laparotomy for the calcified mass revealed a left streak gonad, a right gonadoblastoma, and a small uterus and cervix. The 2 cm left gonad consisted of an irregular fibrous stroma, hilar cells, and rete ovarii; neither oocytes nor testicular structures were observed. The 13 g right gonad consisted of a pink-tan, glistening nodule of rubbery consistency; no definitive ovarian or testicular tissue was identified. Two-thirds of the mass was fibrotic, hyalinised, and calcified (figure a). The non-calcified areas showed sheets of primitive germ cells; small lymphocytes were present in the fibrous tissue stroma. The germ cells were large and showed abundant pale cytoplasm and darkly stained nuclei (figure b), a pattern similar to that of a dysgerminoma or seminoma. Overall, the features suggest a 'burned-out' gonadoblastoma characterised by the overgrowth of the germ cells with lymphocytic

stroma, extensively replaced by fibrosis, hyalinisation, and calcification.

The patient now receives hormonal replacement therapy and has normal renal function.

Discussion

The patient reported here had three rare disorders: XY gonadal dysgenesis, myotonic dystrophy, and end-stage renal disease. The coexistence of the first two could be merely coincidental, but the third requires comment. In particular, this is the third patient with XY gonadal dysgenesis who has shown end-stage renal disease requiring kidney transplantation. The patient we report had end-stage renal disease of unknown aetiology, as did that of Harkins *et al.*⁸ The patient reported by Blanchet *et al.*⁷ had "interstitial nephritis". Different pathological processes thus may or may not have occurred in these patients. If the processes are similar, genetic heterogeneity or pleiotropy for the XY gonadal dysgenesis mutant could exist. Possibly of relevance is the occurrence of a nephrotic syndrome in subjects with XY gonadal dysgenesis,⁹ and coexistence of XY gonadal dysgenesis, renal disease (glomerulonephritis or nephrotic disease), and Wilms' tumour.¹⁰

Interestingly, the patient reported here showed spontaneous menstruation and breast development, possibly attributable to hormone production by the gonadoblastoma. Patients with XY gonadal dysgenesis ordinarily show no evidence of oestrogen production. Thus, puberal feminisation associated with XY gonadal dysgenesis strongly suggests the presence of a gonadoblastoma or dysgerminoma, either of which should be extirpated.

JOE LEIGH SIMPSON,* RAJU S K CHAGANTI,††
JANET MOURADIAN,† AND JAMES GERMAN††

From *the Department of Obstetrics and Gynecology,
Section of Human Genetics,
Northwestern University, Chicago, Illinois;
†Departments of Pathology and Pediatrics,
Cornell Medical College, New York;
and †Laboratory of Human Genetics,
The New York Blood Center,
New York, USA

References

- 1 Simpson JL, Christakos AC, Horwith M, Silverman FS. Gonadal dysgenesis in individuals with apparently normal chromosomal complements: tabulation of cases and compilation of genetic data. *Birth Defects* 1971;7(6): 215-28.
- 2 Simpson JL. *Disorders of sexual differentiation. Etiology and clinical deliniation.* New York: Academic Press, 1976.

- ³ Simpson JL, Blagowidow N, Martin AO. XY gonadal dysgenesis: genetic heterogeneity based upon clinical observations, H-Y antigen status and segregation analysis. *Hum Genet* (in press).
- ⁴ German JL, Simpson JL, Chaganti RSK, Summitt RL, Reid LB, Merkatz IR. Genetically determined sex-reversal in 46,XY humans. *Science* 1978;**202**:53-6.
- ⁵ Wachtel SS, Koo GC, de la Chapelle A, Kallio H, Heyman JM, Miller OJ. H-Y antigen in 46,XY gonadal dysgenesis. *Hum Genet* 1980;**54**:25-30.
- ⁶ Simpson JL, Photopulos G. The relationship of neoplasia to disorders of abnormal sexual differentiation. *Birth Defects* 1976;**12**(1):15-50.
- ⁷ Blanchet P, Daloz P, Lesage R, Papas S, Van Campenhout J. XY gonadal dysgenesis with gonadoblastoma discovered after kidney transplantation. *Am J Obstet Gynecol* 1977;**129**:221-2.
- ⁸ Harkins PG, Haning RY Jr, Shapiro SS. Renal failure with XY gonadal dysgenesis: report of the second case. *Obstet Gynecol* 1980;**56**:751-2.
- ⁹ Gertner JM, Kauschansky A, Criesker DW, Siegel NJ, Breg WR, Genel M. XY gonadal dysgenesis associated with the congenital nephrotic syndrome. *Obstet Gynecol* 1980;**55**:66s-9s.
- ¹⁰ Barakat AY, Papadapoulou Z, Chandra RS, Hollerman CE, Calcagno PL. Pseudohermaphroditism, nephron disorder and Wilms' tumor: a unifying concept. *Pediatrics* 1975;**54**:466-9.

Requests for reprints to Professor J L Simpson, Section of Human Genetics, Prentice Women's Hospital and Maternity Center, 333 East Superior Street, Chicago, Illinois 60611, USA.