

## References

- <sup>1</sup> Lansky S, Daniel W, Fleiszar K. Physical retardation associated with ring chromosome mosaicism: 46,XX,r(10)/45,XX,10-. *J Med Genet* 1977;14:61-3.
- <sup>2</sup> Fryns JP, DeBoeck K, Jaeken J, Van den Berghe H. Malformative syndrome associated with a ring 10 chromosome and a translocated 10q/19 chromosome. *Hum Genet* 1978;43:239-44.
- <sup>3</sup> Sparkes RS, Ling SM, Muller H. Ring 10 chromosome: 46,XX,r10(p15q26). *Hum Genet* 1978;43:341-5.
- <sup>4</sup> Simoni G, Rossella F, Dalpra L, Visconti G, Piria-Schwarz C. Ring chromosome 10 associated with multiple congenital malformations. *Hum Genet* 1979;51:117-21.
- <sup>5</sup> Tsukino R, Tsuda N, Dezawa T, Ishii T, Koike M. Ring chromosome 10: 46,XX,r(10)(p15q26). *J Med Genet* 1980;17:48-51.

Requests for reprints to Dr Hiroshi Nakai, Department of Pediatrics, Tohoku University School of Medicine, Seiryō-cho 1-1, Sendai 980, Japan.

## Tetrasomy 18p: tentative delineation of a syndrome

**SUMMARY** A patient is described with multiple congenital anomalies and probable tetrasomy 18p resulting from an extra i(18p) in an otherwise normal karyotype. Review of ten previously reported i(18p) cases allowed the tentative characterisation of a tetrasomy 18p syndrome.

Many cases of extra marker chromosomes have been reported, including familial and 'de novo' events. In the inherited cases the extra chromosome appears not to be causally related to the phenotype of the probands. The de novo cases present a variety of clinical pictures depending on the different origins of the markers.

With the improvement of chromosome banding techniques, efforts have been made to identify these extra chromosomes more precisely. This paper reports a case of multiple congenital anomalies associated with an extra marker, identified as an isochromosome of the short arm of chromosome 18.

### Case report

The patient is the only male child of unrelated,

Received for publication 2 September 1982.

healthy parents. The mother was 20 and the father 22 years old at the time of his birth. Undiagnosed anomalies were found in four paternal relatives of the proband: an aunt, two stillborn first cousins, and a first cousin once removed. The proband was born at term after an uncomplicated pregnancy and a normal delivery. The length at birth was 48 cm, weight 2800 g, and head circumference 33 cm. Neonatally he had a short period of jaundice and sucked poorly. He had three episodes of febrile tonic-clonic seizures when 6 months old. Psychomotor development was retarded: he sat at 14 months of age, could stand with support, and had no speech. Physical examination at the age of 14 months showed: height 79 cm, head circumference 42.5 cm (below the 2nd centile), brachicephaly, flat occiput, prominent forehead, low hair line, facial hypoplasia on the right, a right ear with rudimentary helix and antihelix and wide concha, high arched palate, horizontal palpebral fissures, slightly flat nose, bilaterally adducted thumbs, short halluces, and clinodactyly of the 5th toes. Neurological examination showed mild hypertonia of the left limbs and ankle clonus on the left. Skull x-rays were normal. Serum immunoglobulin levels (IgA, IgG, and IgM) and urine analysis for amino-acids were normal. Dermatoglyphic patterns are summarised in table 1. The Walker index was -2.08.

### CYTOGENETIC STUDIES

Chromosome analyses were done on cultured peripheral lymphocytes. Q and C banding were performed according to Caspersson *et al*<sup>1</sup> and Sumner,<sup>2</sup> respectively. Ag-NOR staining was by the technique of Bloom and Goodpasture.<sup>3</sup> There were 47 chromosomes among 100 cells analysed. The extra chromosome was metacentric, smaller than the G group chromosomes, without satellites, and was not seen to participate in satellite associations. Q banding (fig 1) showed a symmetrical staining pattern in its arms. The size of the arms and their fluorescence intensity were comparable to those of the short arm of chromosome 18. After C banding (fig 2) a single centromeric band was observed and its size was similar to that of chromosome 18. Ag-stained NORs were not present in either arm (fig 3). These observations led us to believe that the extra marker chromosome is most

TABLE 1 *Dermatoglyphic patterns of the proband.*

	Digits					<i>a-b</i> ridge count	<i>atd</i> angle	Palmar area I <sub>4</sub> *	Hallucal area
	I	II	III	IV	V				
Left	L <sup>u</sup>	L <sup>r</sup>	W	W	W	47	101°	LD	LD
Right	W	L <sup>u</sup>	L <sup>u</sup>	W	W	53	87°	LD	LD

\*No pattern was found in the remaining palmar areas.

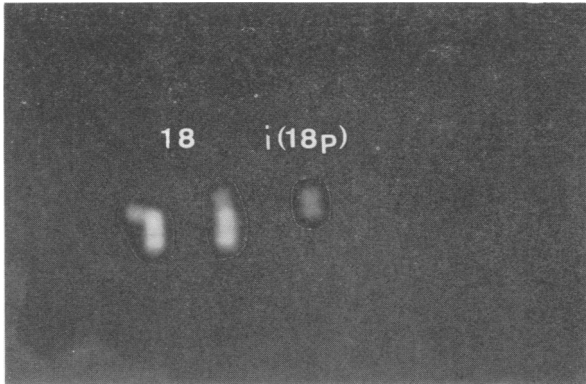


FIG 1 Q bands of chromosomes 18 and i(18p).

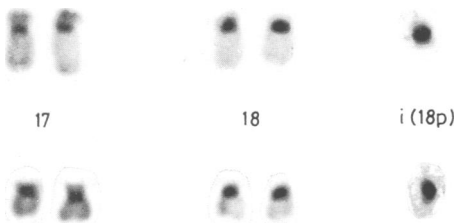


FIG 2 C bands of chromosomes 17, 18, and i(18p).

probably an isochromosome of the short arm of chromosome 18. The karyotypes of the parents were normal.

**Discussion**

The clinical signs present in our patient and in ten other cases of presumptive i(18p) previously described are summarised in table 2. All patients had psychomotor retardation that was almost always severe. Hypertonia, small skull, small and/or triangular mouth, high arched palate, low set ears, and simian creases occurred with a frequency of 50%

or more. Prominent occiput, flat occiput, prominent forehead, low hair line, facial asymmetry, epicanthus, pinched nose, flat nasal bridge, micrognathia, malformed ears, short neck, scoliosis, and cryptorchidism were less frequent features (27 to 45%).

Among the 11 patients, seven had finger abnormalities of different types (clinodactyly, camptodactyly, syndactyly, overlapping fingers, adducted thumb, flexion contracture of fingers). Renal malformations, which included malrotation of the kidney, horseshoe kidney, or double ureter, were observed in three out of five patients investigated.

The high frequency of hypertonia (8/11) and, in some cases, the presence of exaggerated tendon reflexes (3/11),<sup>4 8 9</sup> ankle clonus (2/11)<sup>8</sup> (present case), and atypical Babinsky sign (3/11)<sup>5 6 8</sup> are indicative of a lesion of the pyramidal system. This would explain the fact that the majority of patients<sup>5 6 9 10</sup> developed spasticity.

Regarding the immunological data, low serum IgA was reported in two patients<sup>8 10</sup> at 5 to 6 months of age. Complete return to normal levels was observed in one of them<sup>10</sup> when tested at 12 months of age. These findings, associated with the detection of normal serum IgA producing lymphocytes even

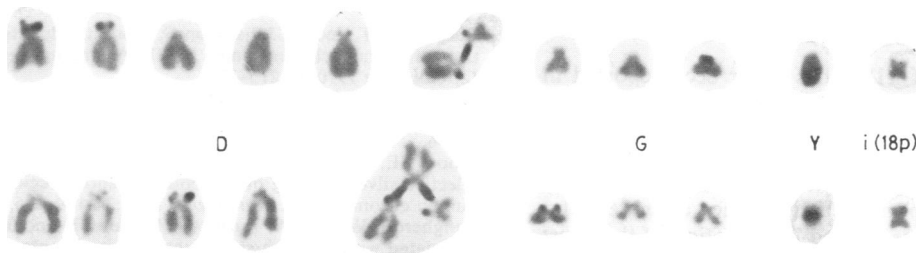


FIG 3 Ag-NOR staining of D and G group chromosomes and i(18p).

TABLE 2 Clinical signs in cases of *i(18p)* (based on published texts and photographs).

Signs	References										Present case
	4	5	6	7	8	9				10	
						4 cases					
Age	10 mth	51 y	12 y	2.5 y	4 mth	16 y	7 y	8 y	13 y	12 mth	14 mth
Sex	F	M	F	F	M	M	M	M	M	F	M
Birth weight (g)	2600	2700	2920	2600	3240	2800	3750	2350	4000	2500	2800
Psychomotor retardation	+	+	+	+	+	+	+	+	+	+	+
Hypertonia	+	+	+	-	+	+	+	+	-	+	+
Small skull	+	?	+	+	+	+	-	+	+	+	+
Prominent occiput	+	-	-	+	-	+	-	-	+	+	-
Flat occiput	-	-	-	-	-	-	+	-	-	-	+
Prominent forehead	-	-	-	+	-	+	-	-	+	-	+
Low hair line	-	+	+	-	-	-	-	-	-	-	+
Facial asymmetry	-	+	-	-	-	+	-	-	-	-	+
Epicanthus	-	-	-	+	-	-	-	-	+	+	-
Pinched nose	-	-	-	-	+	+	+	+	+	-	-
Flat nasal bridge	+	-	-	+	-	-	-	-	-	-	+
Small and/or triangular mouth	-	-	-	+	+	+	+	+	+	+	-
High arched palate	cp	-	+	+	+	+	+	-	+	-	+
Micrognathia	+	-	-	+	-	-	-	-	-	+	-
Low set ears	+	+	-	+	+	+	+	-	+	+	-
Malformed ears	-	-	+	-	-	+	-	-	-	-	+
Short neck	-	+	-	-	-	+	-	-	+	-	-
Scoliosis	+	+	+	+	-	-	+	-	-	-	-
Cryptorchidism or small testes	-	+	-	-	-	-	-	+	+	-	-
Simian crease	-	+	+	-	-	+	+	-	+	+	-
Finger abnormalities	-	c	cl	-	c	c/sy	cd	-	c/ol	-	ad
Renal abnormalities	m	?	h	?	?	-	?	d	?	-	?

cp, cleft palate; c, flexion contracture of fingers; cl, clinodactyly; sy, syndactyly; cd, camptodactyly; ol, overlapping; ad, adducted; m, malrotation of kidney; h, horseshoe kidney; d, double ureter.

when serum IgA was low, led the authors<sup>10</sup> to suggest a temporary immunological deficiency. Among the other *i(18p)* patients only ours had undergone immunological studies and the level of serum IgA was found to be normal at 13 months of age.

Deficiency of IgA is known to be present in patients with deletions of either arm of chromosome 18. The paucity of data regarding *i(18p)* cases makes it impossible to decide whether the finding of low IgA levels in two patients is fortuitous or causally related to the chromosomal imbalance.

Besides our case, only four probands had their dermatoglyphic patterns described.<sup>5 7 8 10</sup> The *a-b* ridge counts recorded for two of them<sup>5 7</sup> were 106 and 92 while in our case it was 100. This increase seems to be the only unusual dermatoglyphic feature associated with the syndrome.

In the cases of *i(18p)*, mean maternal age was  $27.64 \pm 6.79$  and mean paternal age was  $29.09 \pm 6.11$ . Therefore, parental age does not appear to be increased.

Recurrence of *i(18p)* has never been reported in the same sibship. Both parents had normal karyotypes in seven of the eight instances when parental chromosomes were analysed. The mother of one patient<sup>6</sup> had 47 chromosomes, including a telocentric 18 and an *i(18p)*. She had another daughter who was mentally retarded and had deletion of the short arm of one chromosome 18. In the remaining ten sibships, one spontaneous abortion occurred among

23 pregnancies. The sister of one proband<sup>5</sup> had mental retardation and congenital anomalies, but the chromosome constitutions of the girl and her parents were not investigated.

The authors are very grateful to Dr O Frota-Pessoa for his critical reading of the manuscript. They also thank Mrs Ligia S Vieira for her invaluable technical assistance. This work was partly supported by FAPESP (81/0676-1) and CNPq (PIG-SIP 04/012; 301510/79).

DENISE A S BATISTA,  
ANGELA M VIANNA-MORGANTE,  
AND A RICHIERI-COSTA  
*Departamento de Biologia,  
Instituto de Biociências,  
Universidade de São Paulo, Brazil.*

#### References

- 1 Caspersson T, Zech L, Johansson C, Modest E. Identification of human chromosomes by DNA-binding agents. *Chromosoma* 1970;30:215-27.
- 2 Sumner AT. A simple technique for demonstrating centromeric heterochromatin. *Exp Cell Res* 1972;75:304-6.
- 3 Bloom SE, Goodpasture C. An improved technique for selective silver staining of nucleolar organizer regions in human chromosomes. *Hum Genet* 1976;34:199-206.
- 4 Tangheroni W, Cao A, Furbetta M. Multiple anomalies associated with an extra small metacentric chromosome: modified Giemsa stain results. *Humangenetik* 1973;18:291-5.

- <sup>5</sup> Nielsen J, Hreidarsson AB, Berggreen S, Reid E, Tsuboi T, Saldaña-García P. A mentally retarded male with karyotype 47,XY,+mar=?i(18p). *Ann Genet (Paris)* 1974;**17**:129-33.
- <sup>6</sup> Taylor KM, Wolfinger HL, Brown MG, Chadwick DL. Origin of a small metacentric chromosome: familial and cytogenetic evidence. *Clin Genet* 1975;**8**:364-9.
- <sup>7</sup> Balicek P, Zizka J, Lichý J. An isochromosome of the short arms of the no 18 chromosome in a mentally retarded girl. *Clin Genet* 1976;**9**:192-6.
- <sup>8</sup> Ogata K, Iinuma K, Kamimura K, Morinaga R, Kato J. A case report of a presumptive +i(18p) associated with serum IgA deficiency. *Clin Genet* 1977;**11**:184-8.
- <sup>9</sup> Nielsen KB, Dyggve H, Friedrich U, Hobolth N, Lyngbye T, Mikkelsen M. Small metacentric non-satellited extra chromosome. *Hum Genet* 1978;**44**:59-69.
- <sup>10</sup> Rocchi M, Stormi M, Archidiacono N, Filippi G. Extra small metacentric chromosome identified as i(18p). *J Med Genet* 1979;**16**:69-73.

Requests for reprints to Dr A M Vianna-Morgante, Departamento de Biologia, Instituto de Biociências USP, CP 11461, 05421 São Paulo, SP, Brazil.

## Distal monosomy 14 not associated with ring formation

**SUMMARY** A 12-year-old boy with congenital heart disease, short stature, mildly dysmorphic facies, and mild intellectual impairment was found to have a de novo terminal deletion (14)(q32.3). Although his phenotype resembles that of six reported patients with a similar breakpoint, his CNS involvement is milder. He appears to be the first reported case of a terminal deletion of chromosome 14 not associated with ring 14 formation. Advanced parental ages and maternal origin of the chromosome with the deletion are noted.

Received for publication 20 September 1982.

There are ten previously reported cases of terminal monosomy of chromosome 14q not associated with partial duplication of another chromosome. In nine, the loss was associated with ring formation,<sup>1-5</sup> and in one<sup>6</sup> with mosaicism for a complex inversion. We report the first case where the loss was the result of a simple de novo deletion.

### Case report

The patient was a 12-year-old white male admitted for evaluation of congenital heart disease. He was born at term to 35-year-old unrelated parents, after an uncomplicated pregnancy, with a birth weight of 3250 g. Except for the heart disease, he has remained in good physical health. A heart murmur was first detected when he was 2 years old and was followed with annual examinations. The present admission was prompted by decreasing exercise tolerance of 2 years' duration. Cardiac catheterisation showed an atrial septal defect and a partial anomalous venous return that have now been surgically corrected. His psychomotor development was delayed in comparison to his older sibs. In school he is two grade levels behind chronological age. Formal psychometric testing (WISC-R) showed low average intelligence (full scale IQ 85), but with significant verbal-performance discrepancy (verbal IQ 94, performance 78). There is no history of seizures or other neurological symptoms and an EEG was not performed. There is no family history of consanguinity, congenital malformations, or mental retardation. Both parents, an older brother, and three older sisters are in good health, of average height, and at least average intelligence.

On physical examination, the patient was a mildly dysmorphic child (fig 1). Weight was at the 5th centile and head circumference at the 50th centile, while the height was below the 3rd centile and at the

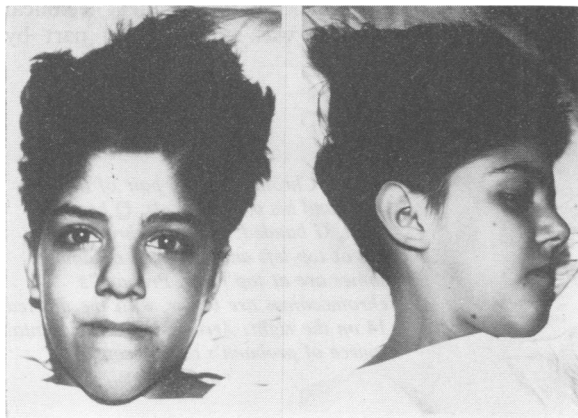


FIG 1 The proband at 12 years. Note high forehead, low anterior hairline, broad nasal bridge, broad philtrum, and simple helix.