

Deletion 2q: two new cases with karyotypes 46,XY,del(2)(q31q33) and 46,XX,del(2)(q36)

ROBERT S YOUNG*, STEVEN D SHAPIRO*, KATHRYN L HANSEN*,
L KENNEDY HINE*, DELBERT E RAINOSEK*, AND FERNANDO A GUERRA†

From *the University of Texas Health Science Center, and †Santa Rosa Medical Center,
San Antonio, Texas, USA.

SUMMARY We describe the clinical and cytogenetic findings of two patients with deletions of the long arm of chromosome 2. One has an interstitial deletion identical to that found in a previously reported patient, although they are phenotypically dissimilar. The other patient has a terminal deletion, the first such deletion reported to date.

Although translocations involving chromosome 2 are by no means uncommon,¹ to our knowledge isolated long arm deletions of chromosome 2 have been reported in only five patients.²⁻⁶ We have recently observed two patients with isolated deletions of the long arm of chromosome 2, one an interstitial deletion and the other most probably a terminal deletion.

Case reports

CASE 1

Case 1 is a 4-month-old male infant, the second child born to a 27-year-old G2, P2 woman and a 27-year-old man. The first child, a female, was delivered by caesarian section because of fetal heart rate deceleration; she is, however, physically and developmentally normal. The family history revealed a 62-year-old maternal great uncle who is mentally retarded from congenital hydrocephalus, a second maternal great uncle who died at birth of unknown causes, and a maternal aunt who died at 6 weeks of age from an unspecified heart defect. The paternal family history is non-contributory.

The antenatal period was unremarkable except for persistent nausea and vomiting from the third to the eighth month, for which Bendectin (doxylamine succinate and pyridoxine hydrochloride) was prescribed. There was also moderate maternal exposure to commercial insecticide fumes during the second week of gestation. There were no other known exposures to potential teratogenic agents of any kind.

The patient was delivered vaginally without complications at 38 weeks by dates and 36 weeks by Dubowitz assessment. The Apgar score at 5 minutes was 8 with points deducted for hypotonia and decreased movement. Birth weight was 2580 g (5th centile), length was 47 cm (3rd centile), and head circumference was 32 cm (3rd centile). After delivery, the patient was placed in the neonatal intensive care unit for assessment of his multiple congenital anomalies (fig 1) which included: mildly low set posteriorly rotated ears with bilateral notched

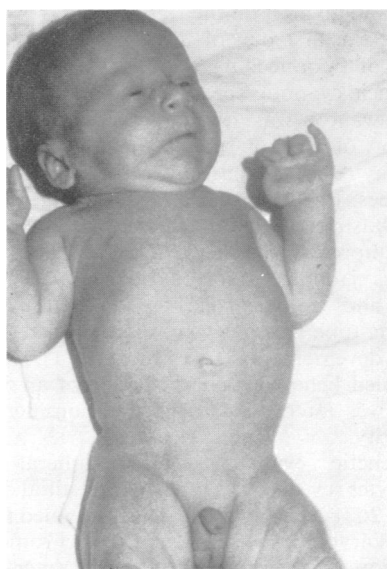


FIG 1 Case 1.

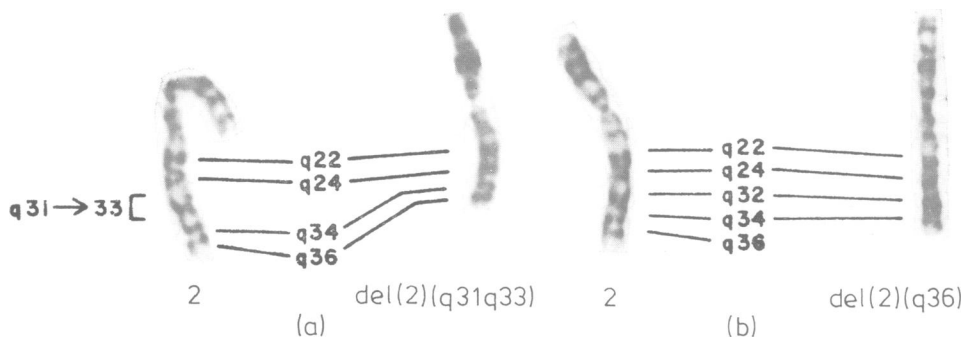

FIG 2 GTG banding of the chromosomes 2 of (a) case 1 and (b) case 2.

lobes, bilateral iris colobomata, mild microphthalmia and narrow palpebral fissures, left corneal opacity, beaked nose, maxillary alveolar ridge hyperplasia, borderline micrognathia, pilonidal dimple, shawl scrotum, bulbous tip to the penis, complete syndactyly of the 2nd and 3rd fingers of the left hand, bilateral simian creases, syndactyly of the second to the fifth toes bilaterally, and bilateral equinovarus. He had generalised jaundice and a weak cry, but manifested no cardiopathy.

His dermatoglyphs showed an excess of digital whorls. He has six whorls and four ulnar loops, while his parents have ten ulnar loops each. His axial triradius is in the r' position on the left and is absent on the right. A hypothenar radial loop is present on the left palm. He has bilateral hallucal fibular arches and his big toe patterns are a fibular loop on the left foot and an arch on the right foot.

During the first day of life the patient had two episodes of poor feeding with associated vomiting and apnoeic cyanotic spells without bradycardia. A barium swallow was normal except for a dyscoordination of the soft palate upon swallowing. A chest x-ray revealed infiltrates in the left upper and lower lobes. Intravenous ampicillin and gentamycin plus orogastric tube feeding were begun and the patient improved markedly over the following 2 days. His jaundice resolved quickly with phototherapy and he was discharged aged 11 days. Orogastric tube feedings were discontinued 2 weeks later. A developmental assessment at 11 weeks of life revealed behaviour characteristic of an 8-week-old and was interpreted as normal considering his prematurity.

Cytogenetic evaluation of peripheral blood lymphocytes revealed a consistent interstitial deletion of bands $2q31 \rightarrow q33$ in all 50 cells examined (fig 2a). Parental karyotypes were normal. His chromosomal constitution is therefore $46,XY,\text{del}(2)(\text{pter} \rightarrow q31::q33 \rightarrow \text{qter})$ de novo.

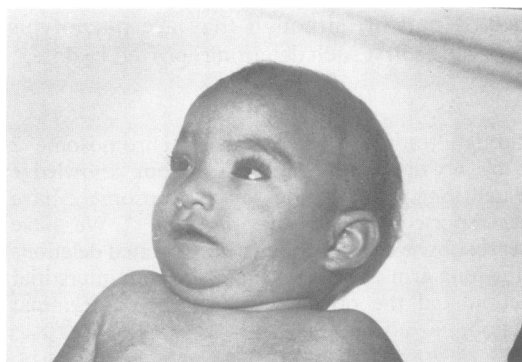


FIG 3 Case 2.

CASE 2

Case 2 (fig 3) is an 8-month-old Hispanic female born to a non-consanguineous 30-year-old G4, P4 woman and a 31-year-old man. All sibs are reported to be physically and mentally normal. The patient's father abandoned the family shortly after her birth, although her mother recalls no member of her husband's family with birth defects, mental retardation, or a history of multiple miscarriages. The same history applies to the maternal side of the family with the exception of one mentally retarded cousin, aetiology unknown.

The mother denied any illness or exposure to unusual chemicals, drugs, or radiation throughout the gestational period. The patient was born by spontaneous vaginal delivery after 37 weeks' gestation by dates. The placenta and amniotic fluid were normal except for slight meconium staining.

Apgar scores were 6 and 9 at 1 and 5 minutes, respectively. She weighed 2300 g (-3 SD), measured 48.3 cm in length (25th centile), and had a head circumference of 30.5 cm (-3.5 SD). Physical

examination revealed a microcephalic infant with a high pitched weak cry, bilateral epicanthus, downward slanting palpebral fissures, extremely long eyelashes, a flat nasal bridge, low set pointed ears with preauricular hirsutism, a cupid's bow mouth, a cleft of the soft and hard palates with absent uvula, inverted nipples, arachnodactyly with extra mesophalangeal flexion creases on the fourth digit of the left hand and digits 2 to 5 on the right hand, genu varum, and bilateral syndactyly of the second and third toes. All other systems appeared clinically normal.

Digital dermatoglyphic patterns include four arches and six ulnar loops for a total ridge count of 34. This apparent increase in arch patterns must be tempered by the fact that her mother has six arches. A vestige pattern is present in the left thenar eminence. The axial triradii are displaced distally, located in the t'' position on the left and t' on the right. She has bilateral big toe arches and bilateral hallucal distal loops.

Radiographic examination revealed pulmonary infiltrates consistent with aspiration pneumonia and a T1 to T8 spina bifida occulta. A barium swallow was normal, as were her liver function and sweat chloride tests.

The patient's course has been complicated by feeding difficulties secondary to her cleft palate and two episodes of aspiration pneumonia, for which she was admitted to hospital. She has developed seizures which are partially controlled by phenobarbital. Overall, her development, both physical and mental, is significantly delayed.

Cytogenetic evaluation of peripheral lymphocytes revealed a small long arm deletion of chromosome 2

in all 50 cells analysed (fig 2b). The deleted segment appears to be terminal (2q36→qter), although interstitial deletions of bands 2q33→q34, 2q34→q35, or 2q33→q35 cannot be ruled out. Her karyotype is most probably 46,XX,del(2)(qter→q36:). Her mother's karyotype is normal, but her father was unavailable for study. It is unknown, therefore, whether the patient represents a de novo deletion or the unbalanced product of a balanced translocation segregating in her father.

Discussion

From both a clinical and cytogenetic viewpoint there is very little similarity between the five cases reported so far and our two patients. The table presents these seven cases from the most proximal 2q deletion on the left to the most distal on the right and lists those features shared by at least two patients in the series. Two pairs of patients do, however, have essentially identical cytogenetic defects and would therefore be expected to resemble each other phenotypically.

The first pair are the patients reported by Fryns *et al*³ and McConnell *et al*,⁴ who are both monosomic for 2q22→2q24. They have a number of features in common, including low birth weight, relatively small facial features, micrognathia, cleft palate, great vessel abnormalities, and overlapping fingers. The second pair with a common deleted segment are the patient reported by Taysi *et al*⁵ and our case 1 who are monosomic for bands 2q31→q33. These two patients are strikingly dissimilar having only developmental delay and low set ears as consistent features.

TABLE Clinical features common to two or more patients with 2q deletions.

	<i>Antich et al</i> ²	<i>Fryns et al</i> ³	<i>McConnell et al</i> ⁴	<i>Taysi et al</i> ⁵	<i>Our case 1</i>	<i>Warter et al</i> ⁶	<i>Our case 2</i>
Deleted segment	q12→q14	q21→q24	q22→q31	q31→q33	q31→q33	q34→q36	q36→qter
Sex	M	F	F	F	M	F	F
Developmental delay/ mental retardation		+		+	+	+	+
Low birth weight		+	+	-		-	+
Sutural irregularities	+		+		-		+
Microcephaly		-	-	+	-	+	+
Large/bulging forehead	+	+			-		+
Small facial features		+	+		-		-
Neural tube defect			+		-		+
Microphthalmia		+			+		-
Corneal opacity		+			+		-
Ptosis		+		+	-		-
Low set ears	+		+	+	+		+
Micrognathia	+	+	+		+		-
Cleft palate		+	+		-		+
Cleft lip and palate	+				-		-
Short neck	+	+			-		-
Cardiopathy	+	+	+	+	-	+	-
Overlapping fingers		+	+		-		-
Long fingers/toes		+			-		+
Clefting between toes 1 and 2			+	+	-		-

As the table indicates, the phenotype of case 2 most closely resembles that of the patients of Fryns *et al*³ and McConnell *et al*,⁴ even though her deletion is considerably more distal than these others. One might anticipate some phenotypic overlap with the patient described by Warter *et al*⁶ if she actually has an interstitial deletion of band 2q35 or 2q36, since Warter's patient is monosomic for bands 2q34→q36, but this is not the case. Based on the cytogenetic and clinical evidence our case 2 appears to be the first reported case of a terminal long arm deletion of chromosome 2.

Given the paucity of 2q deletion patients and the clinical variability typically seen among persons with identical chromosomal abnormalities, it is fruitless to speculate at this point on the '2q monosomy phenotype'.

References

¹ Genest P, LaChance R, Poty J, Jacob D. Autosomal translocation in a mentally retarded male child with

46,XY,t(2q-;13q+) complement: case report and review. *J Med Genet* 1971;**8**:504-7.

² Antich J, Carbonell X, Clusellas N. *De novo* interstitial deletion of the long arm of chromosome 2 in a malformed newborn—karyotype: 46,XY,del(2)(q12q14). *Clin Genet* 1981;**19**:489.

³ Fryns JP, Van Bosstraeten B, Malbrain H, Van den Berghe H. Interstitial deletion of the long arm of chromosome 2 in a polymalformed newborn—karyotype: 46,XX,del(2)(q21q24). *Hum Genet* 1977;**39**:233-8.

⁴ McConnell TS, Kornfeld M, McClellan G, Aase J. Partial deletion of chromosome 2 mimicking a phenotype of trisomy 18: case report with autopsy. *Hum Pathol* 1980;**11**:202-5.

⁵ Taysi K, Dengler DR, Jones LA, Heersma JR. Interstitial deletion of the long arm of chromosome 2: case report and review of literature. *Ann Genet (Paris)* 1981;**24**:245-7.

⁶ Warter S, Lausecker C, Pennerath A. Etude chromosomique et clinique d'une fillette porteuse d'une deletion (2)(q34q36). *Hum Genet* 1976;**32**:225-7.

Correspondence and requests for reprints to Dr Robert S Young, Department of Pediatric Dentistry, University of Texas Health Science Center, San Antonio, Texas 78284, USA.