

from sulphhaemoglobin. An effective antidote, methylene blue, allows methaemoglobin to be reduced by a NADPH-dependent reductase system. Ascorbic acid and riboflavin can be used to reduce methaemoglobin in the homozygous deficiency but do not act rapidly enough to aid in the emergency management of acquired toxic methaemoglobinaemia.

The case reported illustrates a life threatening toxic reaction to a commonly used urinary analgesic. This was the third episode of drug induced cyanosis in the patient. This case provides further evidence that oxidant drugs place heterozygotes (as well as homozygotes) for the deficiency at risk of significant methaemoglobinaemia.<sup>10</sup>

We wish to acknowledge the role of Mr Stephen Maassen, Mr Timothy Mather, and Dr David Juckett in the determination of cytochrome *b<sub>5</sub>* reductase levels, and thank Floretta Reynolds for the haemoglobin studies and Mary Kellogg for secretarial assistance. This work was supported in part by USPHS Research Grants AM-09250 and AM-20964.

#### References

- <sup>1</sup> Crawford SE, Moon HE Jr, Panos TC, Hooks CA. Methemoglobinemia associated with pyridium administration; report of a case. *JAMA* 1951;**146**:24-5.
- <sup>2</sup> Greenberg MS, Wong H. Methemoglobinemia and Heinz body hemolytic anemia due to phenazopyridine hydrochloride. *N Engl J Med* 1964;**271**:431-5.
- <sup>3</sup> Cohen RJ, Sachs JR, Wicker DJ, Conrad ME. Methemoglobinemia provoked by malarial chemoprophylaxis in Vietnam. *N Engl J Med* 1968;**279**:1127-31.
- <sup>4</sup> Horne MK, Waterman MR, Simon LM, Garriott JC, Foerster EH. Methemoglobinemia from sniffing butyl nitrite. *Ann Intern Med* 1979;**91**:417-8.
- <sup>5</sup> Carrell RW, Kay R. A simple method for the detection of unstable haemoglobins. *Br J Haematol* 1972;**23**:615-9.
- <sup>6</sup> Scott FM. The relation of diaphorase of human erythrocytes to inheritance of methemoglobinemia. *J Clin Invest* 1960;**39**:1176-9.
- <sup>7</sup> Hegesh E, Calmanovici N, Avron M. New method for determining ferrihemoglobin reductase (NADH-methemoglobin reductase) in erythrocytes. *J Lab Clin Med* 1968;**72**:339-44.
- <sup>8</sup> Hultquist DE, Passon PG. Catalysis of methaemoglobin reduction by erythrocyte cytochrome *b<sub>5</sub>* and cytochrome *b<sub>5</sub>* reductase. *Nature* 1971;**229**:252-4.
- <sup>9</sup> Jaffe ER. Methaemoglobinaemia. *Clin Haematol* 1981;**10**:99-122.
- <sup>10</sup> Smith RP, Olson MW. Drug induced methemoglobinemia. *Semin Hematol* 1973;**10**:253-68.

Correspondence and requests for reprints to Dr Donald E Hultquist, Department of Biological Chemistry, Medical Sciences Building I, Box 034, University of Michigan, Ann Arbor, Michigan 48109, USA.

## Involvement of dorsal root ganglia in Fabry's disease

NATAN GADOTH AND URI SANDBANK

*Departments of Neurology and Pathology, Beilinson Medical Center, Petah Tiqva, Tel Aviv University Sackler School of Medicine, Israel.*

**SUMMARY** Bouts of shooting pain along the extremities are common in the early stages of Fabry's disease. No pathological explanation has been advanced to clarify the mechanism of such pain. In the present case neuronal storage of glycolipid was confined to dorsal root ganglia neurones only. It is suggested that this may explain the shooting pain in Fabry's disease. In hereditary sensory radicular neuropathy, familial dysautonomia, and tabes dorsalis, changes in dorsal root ganglia cells cause similar clinical signs and thus it may be concluded that shooting pains in Fabry's disease may be caused by damage to dorsal root ganglia neurones.

Received for publication 28 June 1982.  
Accepted for publication 10 December 1982.

Fabry's disease is an X linked recessive, glycolipid storage disease, affecting endothelium, myocardium, fibroblasts, epithelial cells of the glomerulus, smooth muscle, cornea, glial cells, and neurones. Storage of di- and triglycosylceramide in the affected tissues is believed to be caused by  $\alpha$ -galactosidase A deficiency.<sup>1</sup>

Early in the course of the disease the young patient suffers from bouts of severe, spontaneous shooting pain, usually in the distal part of his extremities but sometimes involving teeth, jaws, and abdomen. This characteristic symptom lacks a solid neuropathological correlation. Two possible theories have been advanced, that the pain is caused by damaged peripheral nerve endings or by depletion of small myelinated fibres in peripheral nerves.<sup>2</sup> The present report describes a patient with Fabry's disease in whom, in addition to the usual visceral

involvement, detailed neuropathological evaluation disclosed marked accumulation of storage material within dorsal root ganglia neurones exclusively. We suggest that the involvement of dorsal root ganglia neurones might be responsible for the presence of shooting pains in this disease.

### Case report

The male patient was 37 years old at the time of death. He enjoyed normal health up to the age of 15. From then he started to have bouts of unexplained fever, frequently followed by generalised joint tenderness lasting for 2 to 3 weeks. Unrelated to these attacks he had paroxysms of lightning pain, shooting down from the hips to both knees, ankles, and feet. Similar pain in both arms radiated to the tips of his fingers. The occurrence of joint tenderness and fever led to the diagnosis of rheumatic fever by several experienced paediatricians. At the age of 18, proteinuria and hypertension were found. At the age of 25, sudden truncal ataxia and right spastic hemiparesis were found. Two years later, cardiomyopathy was diagnosed, based on the presence of chest pain, palpitations, shortness of breath, and cardiomegaly. The diagnosis of Fabry's disease was then suspected when, in addition to the above clinical history, angiokeratomas were noticed for the first time over the umbilical area. At that stage he suffered from nephropathy, cardiomyopathy, corneal clouding, and cerebrovascular disease. The painful dysaesthesias had gradually decreased in frequency and slowly disappeared. The clinical diagnosis was confirmed by kidney biopsy in which storage of glycolipid was found. Ceramide dihexoside and trihexoside were found in the urine and a deficiency of ceramide-trihexosidase ( $\alpha$ -galactosidase A) was found in leucocytes. The family history was compatible with X linked recessive transmission of lethal kidney disease. The patient had two maternal uncles who died of chronic renal failure. Recently a third maternal uncle was examined by us and was found to have the classical features of Fabry's disease, which was confirmed enzymatically. The patient's mother had mild proteinuria and showed relatively low activity of leucocyte  $\alpha$ -galactosidase A. During the last 10 years of his life the patient had several cerebrovascular accidents resulting in pseudobulbar palsy, which finally led to his death.

### Necropsy findings

The heart, spleen, and kidneys were enlarged. The heart weighed 450 g and the myocardium was pale brown with a yellowish hue. The kidneys weighed 210 g each and were also pale brown to yellow in

colour. The spleen weighed 300 g and was firm. In the myocardium, microscopical examination revealed eosinophilic granules measuring up to  $0.5 \mu$  in diameter located mainly around the nuclei. These granules stained positively with PAS and Sudan black stains. Electron microscopical examination revealed the presence of osmophilic irregular bodies and a second type of lamellated bodies between the muscle fibres (fig 1). In the kidneys, within the epithelium of both proximal and distal tubules, similar bodies to those described in the myocardium were seen. In the spleen, proliferation of large histiocytes with abundant eosinophilic cytoplasm

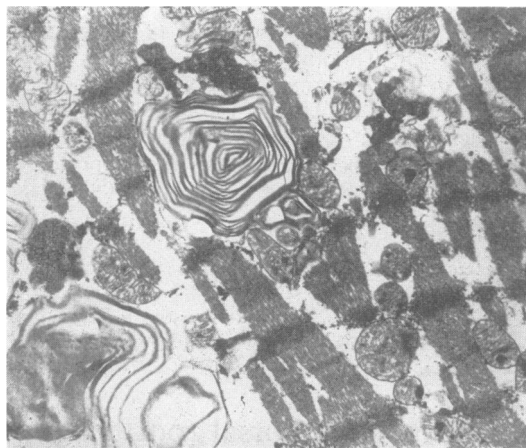

FIG 1 Myocardium: lamellar bodies and osmophilic irregular bodies are present between muscle fibres. (Original magnification  $\times 6800$ .)

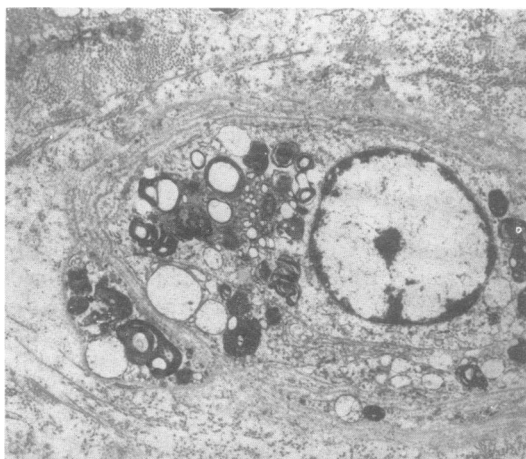


FIG 2 Small dermal blood vessel. Endothelial cell and pericyte cytoplasm contains vacuoles and osmophilic and lamellar bodies. (Original magnification  $\times 3300$ .)

was observed. In these organs, many small arterioles showed a thickened wall which stained heavily with PAS stain. In the dermis the blood vessels contained vacuoles, osmophilic bodies, and lamellar bodies, located in the endothelial cells (fig 2). In the brain, multiple encephalomalacic cysts were found in the pons, cerebellum, and both occipital lobes. Many arterioles in the brain showed extensive irregular thickening of their walls by an eosinophilic homogenous PAS positive material. Extensive study of multiple sections of the brain and spinal cord did not reveal any abnormality in the neurones or glial cells. Examination of spinal ganglia showed extremely large neurones with the nucleus and Nissl substance at the periphery of the neurone and the cytoplasm containing fine eosinophilic granules (fig 3). PAS stain showed that the cytoplasm of the neurones was loaded with PAS positive granules

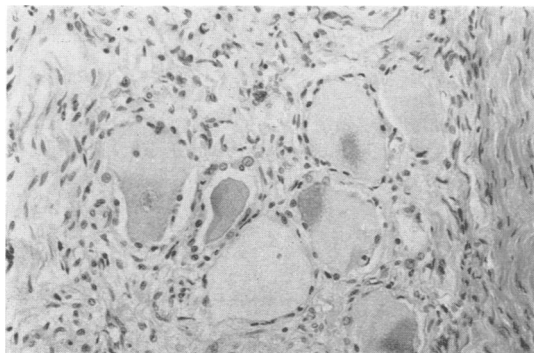


FIG 3 Swollen neurones in dorsal root ganglia with displaced nucleus and Nissl substance containing fine eosinophilic granules. (Haematoxylin and eosin. Original magnification  $\times 200$ ).

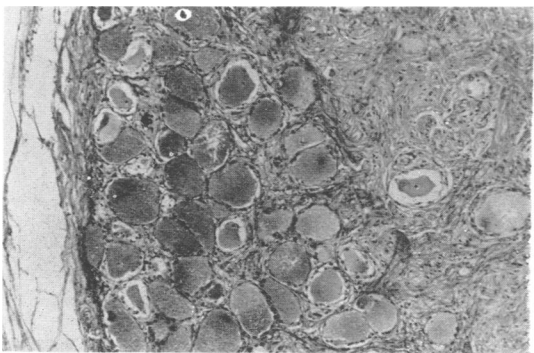


FIG 4 Swollen neurones in dorsal root ganglia containing PAS positive granules. (Original magnification  $\times 100$ .)

(fig 4) which also stained positively with Sudan black. The somatic peripheral nervous system was intact. However, small blood vessels of peripheral nerves showed extensive thickening by PAS positive material. Electron microscopy showed abundant round or irregular osmophilic bodies dispersed in the cytoplasm of the endothelial cells.

### Discussion

This patient's clinical history represents the classical course of Fabry's disease. During adolescence, lightning pain, burning of hands and feet, and bouts of unexplained fever are characteristic, leading frequently to a presumed diagnosis of rheumatic fever. Later, during early maturity there is diminution and eventual cessation of 'pain crises', and during late maturity the patient suffers from small shrunken kidneys, cardiomegaly, hypertension, corneal clouding, retinopathy, cerebrovascular disease, and severe renal failure. Our neuropathological findings are somewhat unusual and may provide an adequate explanation for the bouts of shooting pain so characteristic of this disease. Although widespread neuronal storage of glycolipid was found by several authors,<sup>3-7</sup> others have failed to find such changes although typical storage was always present in extraneural tissues.<sup>8,9</sup> Thus it seems that widespread diffused neuronal storage is not a consistent finding. However, it is generally believed that the autonomic neurones are preferentially affected.<sup>3-7,10,11</sup> In our patient neuronal storage was localised to sensory root ganglia exclusively.

Kocen and Thomas<sup>2</sup> were the first to suggest that dorsal root ganglia cells might be involved in Fabry's disease although they were wrong in stating that "no observations appear to have been made on the dorsal root ganglia cells". Two years before this, Steward and Hitchcock<sup>3</sup> found glycolipid storage in dorsal root ganglia neurones but there was extensive widespread involvement of other neurones as well. Similar findings were reported by Tabira *et al*,<sup>7</sup> Kahn,<sup>12</sup> and Ohnishi and Dyck.<sup>13</sup> It is obvious that storage in dorsal root ganglia neurones only, as was seen in our patient, can produce bouts of shooting pain when these neurones are still alive and storing glycolipid. Cessation of pain in later stages of the disease may be the result of neuronal death.

Pain of a similar nature is a prominent sign during the course of hereditary sensory radicular neuropathy, familial dysautonomia, and tabes dorsalis. In the first two, a marked reduction of dorsal root ganglia neurones is present,<sup>14,15</sup> while in tabes dorsalis degeneration of dorsal rootlets and, to a lesser extent, dorsal root ganglion neurones is characteristic.<sup>16</sup> It may be concluded from our study

that in Fabry's disease bouts of shooting pain can be caused by damage to dorsal root ganglia neurones.

We thank Dr Z Leibovitz-Ben-Gershon from the Pediatric Research Unit, Hadassah University Hospital, Jerusalem, for determination of  $\alpha$ -galactosidase activity.

#### References

- <sup>1</sup> Desnick RJ, Klionsky B, Sweeley CC. Fabry's disease. In: Stanbury JB, Wyngaarden JB, Frederickson DS, eds. *The metabolic basis of inherited disease*. 4th ed, chap 39. New York: McGraw-Hill, 1978:810-40.
- <sup>2</sup> Kocen RS, Thomas PK. Peripheral nerve involvement in Fabry's disease *Arch Neurol* 1970;**22**:81-8.
- <sup>3</sup> Steward VW, Hitchcock C. Fabry's disease: (angiokeratoma corporis diffusum). A report of 5 cases with pain in the extremities as the chief symptom. *Pathol Eur* 1968;**3**:377-88.
- <sup>4</sup> Pompen AWM, Ruiten M, Wyers HJG. Angiokeratoma corporis diffusum (universale) Fabry, as a sign of an unknown internal disease; two autopsy reports. *Acta Med Scand* 1947;**128**:234-55.
- <sup>5</sup> Sciba K. Zur pathogenese des Angiokeratoma Corporis Diffusum Fabry mit cardio-vaso-renalem symptomkomplex. *Verh Dtsch Ges Pathol* 1951;**34**:221-5.
- <sup>6</sup> Rahman AN, Lindenberg R. The neuropathology of hereditary dystopic lipodosis. *Arch Neurol* 1963;**9**:373-85.
- <sup>7</sup> Tabira T, Goto I, Kuroiwa Y, Kikuchi M. Neuropathological and biochemical studies in Fabry's disease. *Acta Neuropathol (Berl)* 1974;**30**:345-54.
- <sup>8</sup> Jensen E. On the pathology of angiokeratoma corporis diffusum (Fabry). *Acta Pathol Microbiol Scand* 1966;**68**:313-31.
- <sup>9</sup> Christensen Lou HO, Reske-Nielsen E. The central nervous system in Fabry's disease. A clinical, pathological and biochemical investigation. *Arch Neurol* 1971;**25**:351-9.
- <sup>10</sup> Sung JH, Hayano M, Mastro AR, Desnick R. Neuropathology of Fabry's disease. *Proc Int Cong Neuropathol, Budapest*, 1974.
- <sup>11</sup> Sung JH. Autonomic neurons affected by lipid storage in the spinal cord in Fabry's disease. Distribution of autonomic neurons in the sacral cord. *J Neuropathol Exp Neurol* 1979;**38**:87-98.
- <sup>12</sup> Kahn P. Anderson-Fabry disease: a histological study of three cases with observation on the mechanism of production of pain. *J Neurol Neurosurg Psychiatry* 1973;**36**:1053-62.
- <sup>13</sup> Ohnishi A, Dyck PJ. Loss of small peripheral sensory neurons in Fabry disease. *Arch Neurol* 1974;**31**:120-7.
- <sup>14</sup> Denny-Brown D. Hereditary sensory radicular neuropathy. *J Neurol Neurosurg Psychiatry* 1951;**14**:237-52.
- <sup>15</sup> Pearson J, Tytel BA, Grover-Johnson N, Axelrod F, Dancis J. Quantitative studies of dorsal root ganglia and neuropathologic observations on spinal cord in familial dysautonomia. *J Neurol Sci* 1978;**35**:77-92.
- <sup>16</sup> Storm-Mathisen A. Syphilis. In: Vinken PJ, Bruyn GW, eds. *Handbook of clinical neurology*. Vol 33. Amsterdam: North Holland, 1978:363.

Correspondence and requests for reprints to Dr N Gadoth, Department of Neurology, Beilinson Medical Center, Petah Tiqva 49100, Israel.

---

#### Correction

In the paper 'Graves' disease and Down's syndrome' by McCulloch *et al* which was published in *Journal of Medical Genetics* 1983;**20**:133-4, 'sputum' should read 'serum' in the last line of the Summary.