

genocopies of the BDLS phenotype should also be considered. It is still conceivable that BDLS is related to a minor chromosome deletion or duplication so subtle that it has not been detected by current techniques. As the technology improves, additional studies of the BDLS will be helpful, perhaps with emphasis placed on those chromosomes which have been involved in cytogenetic abnormalities in BDLS patients.

#### References

- <sup>1</sup> Berg JM, McCreary BD, Ridler MAC, Smith GF. *The de Lange syndrome*. Oxford: Pergamon Press, 1970.
- <sup>2</sup> Stevenson RE, Scott CI. Discordance for Cornelia de Lange syndrome in twins. *J Med Genet* 1976;**13**:402-4.
- <sup>3</sup> Beck B, Mikkelsen M. Chromosomes in the Cornelia de Lange syndrome. *Hum Genet* 1981;**59**:271-6.
- <sup>4</sup> Breslau EJ, Distèche C, Hall JG, Thuline H, Cooper P. Prometaphase chromosomes in five patients with the Brachmann-de Lange syndrome. *Am J Med Genet* 1981;**10**:179-86.
- <sup>5</sup> Steinbach P, Adkins WN, Caspar H, *et al*. The dup(3q) syndrome: report of eight cases and review of the literature. *Am J Med Genet* 1981;**10**:159-77.
- <sup>6</sup> Yunis JJ. High resolution of human chromosomes. *Science* 1976;**191**:1268-70.
- <sup>7</sup> France NE, Crome L, Abraham JM. Pathological features in the de Lange syndrome. *Acta Paediatr Scand* 1969;**58**:470-80.

Correspondence and requests for reprints to Dr William G Wilson, Department of Pediatrics, Box 386, University of Virginia Medical Center, Charlottesville, Virginia 22908, USA.

## De novo duplication of the 7q11→q22 region

NATALINE B KARDON, LYNDA POLLACK, JESSICA DAVIS,  
AFINA BROEKMAN, AND MARION KRAUSS

*Department of Pediatrics, North Shore University Hospital, and Department of Pediatrics, Cornell University Medical College, New York, USA.*

**SUMMARY** A patient with de novo partial trisomy for the 7q11→7q22 region as defined by methotrexate high resolution banding is described. He presented with delayed growth and development and characteristic physical features. These consisted of frontal bossing, prominent metopic suture, almond shaped eyes, enophthalmos, large, low set, posteriorly rotated ears, long philtrum, narrow upper lip, high arched palate, and a short neck. Specific genitourinary anomalies were noted.

Partial duplication of chromosome 7q was first described by Carpentier *et al*.<sup>1</sup> Banding techniques provided further phenotypic delineation, and in 1976 Turleau *et al*<sup>2</sup> proposed two distinct syndromes based on different breakpoints. To date approximately 20 cases have been reported and most have resulted from a familial balanced translocation.<sup>3</sup>

Wahrman *et al*<sup>4</sup> described a patient with possible duplication of 7q11→7qter. We wish to describe a phenotypically similar patient with de novo partial duplication of 7q.

#### Case report

The proband, a white male, was born on 13.2.78 to unrelated 29-year-old Italian-Irish parents following a term pregnancy complicated by first trimester bleeding. Birth weight was 2500 g. The delivery and neonatal course were unremarkable. There is a single sib, a 5-year-old sister, who was the only survivor of a premature triplet delivery.

The patient was initially evaluated at 10 months of age because of delayed growth and development. Physical examination (fig 1) revealed a small alert male infant whose height and weight were below the 3rd centile. Pertinent findings included frontal bossing, prominent metopic suture, almond shaped eyes, enophthalmos, large, low set, posteriorly rotated ears, long philtrum, narrow upper lip, high arched palate, and a short neck. An accessory nipple was present on his right lower lateral chest. He had a small penis and bilateral cryptorchidism. On neurological examination he had normal muscle tone and normal reflexes. He sat without support, but he did not support his weight or attempt to stand. Dermatoglyphs were unremarkable.

At 15 months of age he was admitted to hospital because of failure to thrive. Proximal renal tubular acidosis was diagnosed, but the patient did not gain

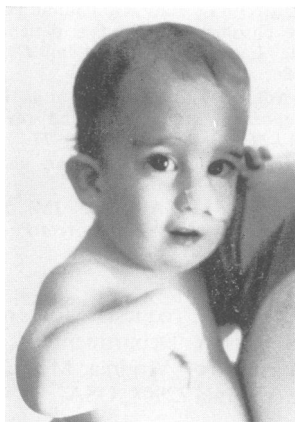

FIG 1 The proband at 10 months of age.

weight on appropriate therapy. IVP and abdominal CT failed to visualise the left kidney. An absent left ureteral orifice and a right sided ureterocele were found at cystoscopy. An atrophic left kidney was identified and removed at laparotomy. The patient returned to hospital several times because of intermittent febrile episodes (38 to 39°C). The aetiology of these episodes was never determined despite numerous cultures and immunological studies.

At 23 months he achieved a mental age level of 10 to 11 months with sporadic 14.6 month tasks and his motor skills were at 9 to 10 months on the Bayley scales of infant development.

When last seen at 4 years of age he was not speaking. He began walking independently at 3 years, but developed an aseptic necrosis of the right hip requiring brace therapy. The febrile episodes resolved spontaneously as did the renal tubular acidosis. His growth parameters have remained at the 3rd centile.

#### Materials and methods

Chromosome analysis of 72 hour peripheral lymphocyte and skin fibroblast cultures was done using Giemsa (GTG), R, and Q banding techniques. High resolution banding by methotrexate synchronisation was accomplished according to the techniques described by Yunis.<sup>5</sup> B-glucuronidase was assayed from skin fibroblasts and complete blood group typing of all family members was performed.

#### Results

The initial karyotype of the patient revealed an extra band on the long arm of one chromosome 7. Cytogenetic studies of parental and sib peripheral blood specimens were normal and failed to delineate the origin of the extra segment. High resolution

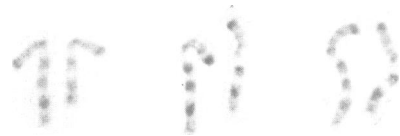

FIG 2 High resolution banding of chromosome 7 pairs demonstrating the duplicated q11→q22 segment.

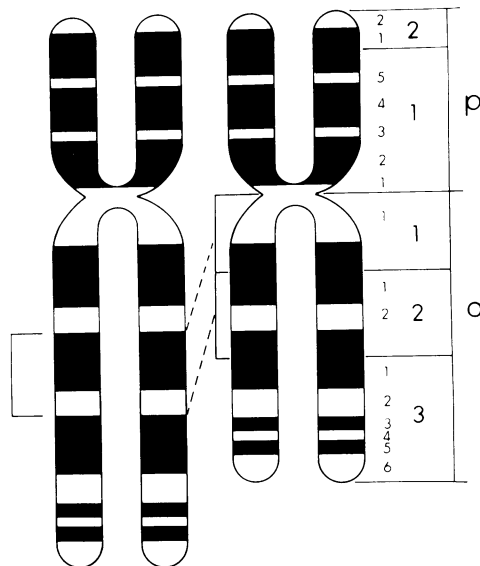


FIG 3 Idiogram of chromosome 7 illustrating duplicated region.

banding identified the derivative chromosome as a *de novo* duplication of the 7q11→q22 region (figs 2 and 3).

Attempts to demonstrate gene dosage effect were made but unfortunately were not successful. Enzymatic assay for B-glucuronidase (assigned to the 7pter→q22 region) from skin fibroblasts was within normal limits. Complete blood group typing including Kidd and Colton groups were uninformative for gene mapping.

#### Discussion

Partial trisomy 7q includes two or possibly three distinct syndromes based on the location and length of the extra chromosomal segment. The first case reported<sup>3</sup> involved a duplicated segment of the 7q22 or q31→qter region. All of the patients were of low birth weight and had growth and mental retardation. Consistent physical findings included micrognathia, cleft palate, eye findings (cataracts, colobomata), skeletal anomalies, and congenital heart defects. Grace *et al*<sup>6</sup> and Serville *et al*<sup>7</sup> reported

an interstitial duplication of the 7q22→q32 region in patients with frontal bossing, strabismus, large wide ears, and hypotonia. Turleau *et al*<sup>2</sup> proposed two syndromes based on these distinctive characteristics. More recently, Schmid *et al*<sup>8</sup> suggested a third syndrome as their patients had asymmetry of the skull, small dysplastic ears, kyphoscoliosis, and seizures, as well as strabismus and hypotonia.

Despite apparent specificity there is some phenotypic overlap and certain common features are described in all cases. These include mental retardation, low set ears, hypertelorism, small palpebral fissures, a short upper lip, and a short neck.

Almost all reports of partial trisomy 7q result from a familial reciprocal translocation or insertion translocation. In addition to trisomy, partial monosomy of a variety of other chromosomes is represented.<sup>3</sup> There are also reports of derivative chromosomes resulting from pericentric inversions of chromosome 7. The first *de novo* report was by Wahrman *et al*.<sup>4</sup> A very large chromosomal segment was duplicated and involved the 7q11→qter region. This was also the first case reported with genitourinary and renal anomalies. Our patient is similar clinically in that he had an atrophic kidney, a ureteral anomaly, and cryptorchidism, as well as the similar facial features that are characteristic of 7q trisomy. The specificity of renal anomalies is further illustrated by Ramirez and Uribe<sup>9</sup> as they report full trisomy 7 in an infant who presented with Potter's syndrome. The pathological examination revealed an absent left kidney and a right polycystic kidney.

Although a gene dosage effect could not be demonstrated by enzymatic assay or blood group linkage analysis, high resolution banding suggested a duplication of the 7q11→q22 region as compared to the other 7q bands. The phenotypic similarities to full and partial trisomy 7 make it unlikely that the

extra material is derived from another chromosome. The most likely mechanism producing the derivative chromosome is three breaks resulting in an insertion of the region in question or an unequal cross over in meiosis.

We wish to thank W L Marsh at the New York Blood Center for performing complete blood typing and Dr S L Sklower of the New York State Institute for Basic Research for performing the B-glucuronidase enzyme assay.

#### References

- 1 Carpentier S, Rethoré MO, Lejeune J. Trisomie partielle 7q par translocation familiale t(7;12)(q22;q24). *Ann Genet (Paris)* 1972;**15**:283-6.
- 2 Turleau C, Rossier A, de Montis G, Roubin M, Chavin-Colin F, de Grouchy J. Trisomie partielle 7q. Un ou deux syndromes? A propos d'une nouvelle observation. *Ann Genet (Paris)* 1976;**19**:37-42.
- 3 Vogel W. Partial duplication 7q. In: Yunis JJ, ed. *New chromosomal syndromes*. 1st ed. New York: Academic Press, 1977:185-95.
- 4 Wahrman J, Cohen MM, Rosenmann A, Goitein R, Richler C, Dagan J. A long unidentifiable extra chromosomal segment. A possible duplication of human 7q. *Cytogenet Cell Genet* 1978;**20**:160-8.
- 5 Yunis JJ. High resolution of human chromosomes. *Science* 1976;**191**:1268-70.
- 6 Grace E, Sutherland GR, Bain AD. Familial insertional translocation. *Lancet* 1972;ii:231.
- 7 Serville F, Broustet A, Sandler B, Bourdeau MJ, Leloup M. Trisomie 7q partielle. *Ann Genet (Paris)* 1975;**18**:67-70.
- 8 Schmid M, Wolf J, Nestler H, Krone W. Partial trisomy for the long arm of chromosome 7 due to familial balanced translocation. *Hum Genet* 1979;**49**:283-9.
- 9 Ramirez YE, Uribe JG. Full trisomy 7 and Potter syndrome. *Hum Genet* 1980;**54**:13-8.

Correspondence and requests for reprints to Dr Nataline B Kardon, Child Development Center/Genetics, North Shore University Hospital, 300 Community Drive, Manhasset, New York 11030, USA.

## De novo interstitial direct duplication of 15q: 46,XY,dir dup(15) (pter→q24::q14→q21·1::q24→qter)

HELEN M HERR, CHARLES I SCOTT JR, AND SUSAN J HORTON

*Department of Genetics, Alfred I duPont Institute of the Nemours Foundation, Wilmington, Delaware 19899, USA.*

**SUMMARY** A profoundly retarded, slightly dysmorphic male was re-examined cytogenetically by high resolution GTG banding and found to have a *de novo* interstitial direct duplication of 15q.

#### Case report

The patient reported here (fig 1) is a 12-year-old Caucasian male, the product of a 41-week gestation of a 34-year-old gravida 2 para 2 woman and her 36-year-old non-consanguineous husband. During the eighth and ninth months of pregnancy, hydrochlorothiazide (Hydrodiuril) for significant