

## A father and daughter with fragile X chromosome

This paper describes a fertile, twice married male with the fragile X syndrome (mental retardation and macroorchidism), his daughter, and other members of his family.

The proband (III.1, fig 1), now 27 years old, had delayed psychomotor development from early childhood.

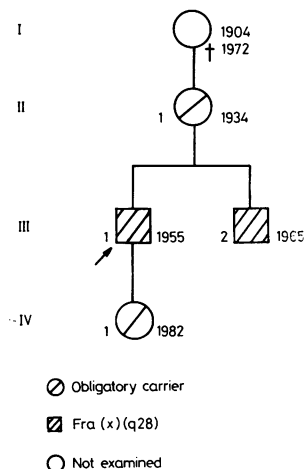


FIG 1 Partial family pedigree.



FIG 2 Proband (left) and proband's brother (right).

Received for publication 23 December 1982.  
Accepted for publication 19 February 1983.

He attended a school for the mentally disabled for 2 years with little success. He is now 178 cm tall, weight 70 kg, and head circumference 56 cm. He has pale blue irides, a slightly bulbous nose, and abnormal ears (fig 2). Testicular volume is 74 ml and 56.6 ml for the right and left testis respectively. IQ is 34. He becomes agitated, almost psychotic, after drinking even small amounts of alcohol. His younger brother (III.2) is similarly affected (fig 2). His IQ is 48. He is impulsive, tense, and prone to attacks of rage.

The fragile X was present in 19% of cells from the proband and in 40% of cells from his brother. No fragile X was demonstrated in their mother, who must be a carrier of the anomaly. Despite his condition, the proband has been married twice (both spouses having been chosen by his parents). The first marriage lasted only 3 months. He now lives with his second non-consanguineous wife who is also mentally retarded. When she became pregnant the couple were referred for genetic counselling. Antenatal diagnosis was recommended and the amniocentesis was carried out in Belgrade. The sample of amniotic fluid was sent to Dr J Boué in Paris for fetal karyotyping. The chromosome complement was 46,XX. A fragile X was seen in five out of 50 cells examined. The mother of the proband refused to allow a termination of the pregnancy which continued to term producing a phenotypically normal female. Repeated cultures of the infant's blood failed to demonstrate the presence of the fragile X in her lymphocytes.

We are not aware of previous reports of proven fertility in males with the fragile X syndrome and macroorchidism, but Cantú *et al*<sup>1</sup> demonstrated that testicular hyperplasia in these patients is not associated with abnormal spermatogenesis. It is, however, most unusual for these people to marry and this may be the only example reported so far.

SLAVKA MORIĆ-PETROVIĆ AND  
ŽIVANA LAČA  
Institute for Mental Health,  
Centre for Medical Genetics,  
Palmotićevo 37, 11000 Beograd,  
Yugoslavia.

### Reference

- 1 Cantú JM, Scaglia HE, Gonzáles-Diddi M, *et al*. Inherited congenital normofunctional testicular hyperplasia and mental deficiency. *Hum Genet* 1978;41:331-9.

Correspondence and requests for reprints to Dr S Morić-Petrović, Centre for Medical Genetics, Palmotićevo 37, 11000 Beograd, Yugoslavia.