

Poland-Möbius syndrome associated with dextrocardia

J M BOSCH-BANYERAS, A ZUASNABAR, A PUIG,
M CATALÀ, AND J M CUATRECASAS

Department of Paediatrics, Hospital General de Granollers, Barcelona, Spain.

SUMMARY A newborn male with Möbius syndrome, Poland anomaly, and dextrocardia is described. This is the second case reported of Poland-Möbius syndrome associated with dextrocardia. The patient presented with strabismus, facial diplegia, difficulty in swallowing, hypoplasia of the left pectoralis major muscle, partial absence of the upper costal cartilages, absence of the left areola, hypoplasia of the left forearm and hand, and dextrocardia without murmurs.

Poland syndrome consists of absence of the sternal head of the pectoralis major muscle with ipsilateral symbrachydactyly. The malformations of the limbs, especially those of the fingers, are variable and in some cases associated anomalies have been reported including Möbius syndrome. The association of both disorders (Poland-Möbius syndrome) may represent a distinct clinical entity.¹ We report the second case of Poland-Möbius syndrome associated with dextrocardia.

Case report

The patient was the 2790 g male product of an uncomplicated 38-week pregnancy and delivery. The parents were unrelated and young and healthy at the time of conception. There was no history of maternal irradiation or drug intake. On admission

Received for publication 8 April 1983.
Accepted for publication 13 June 1983.

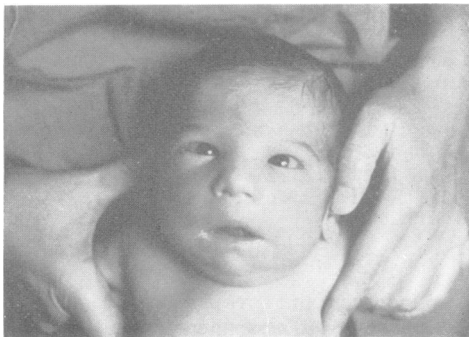


FIG 1 *The proband. Note bilateral convergent strabismus and facial diplegia.*

to the nursery the following congenital abnormalities were observed: bilateral convergent strabismus, fixed and expressionless facies (fig 1), difficulty in swallowing, hypoplasia of the left pectoralis major muscle with partial absence of the upper costal cartilages (lung hernia), absence of the left areola, hypoplasia of the left forearm and hand (fig 2), and

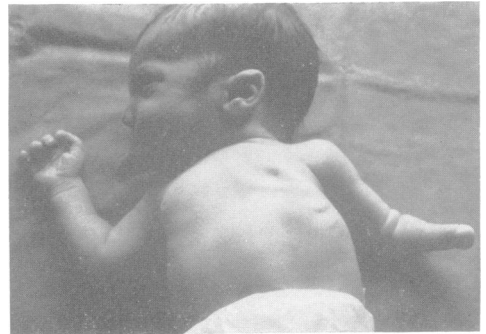

FIG 2 *Chest deformity and abnormalities of the left hand.*

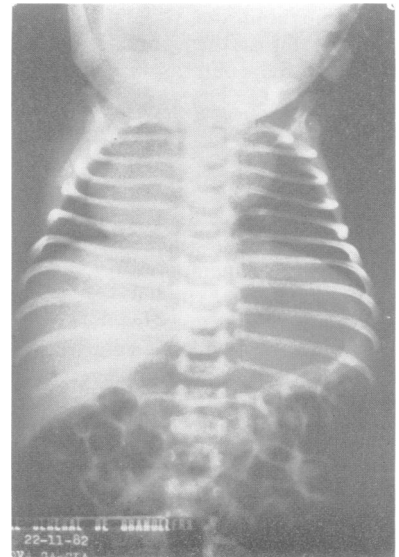


FIG 3 *Chest x-ray showing dextrocardia.*

dextrocardia without murmurs. Radiographs showed left radioulnar hypoplasia with absence of the bones of the left hand and dextrocardia, and that the ribs on the left were thinner than those on the right (fig 3). Electrocardiographic and echocardiographic results indicated isolated dextrocardia. The abdominal sonogram revealed two kidneys of normal size. Cerebral sonography and karyotype were normal.

Discussion

Poland² in 1841 described the association of aplasia of the sternal head of the pectoralis major muscle with ipsilateral symbrachydactyly. The population incidence of Poland syndrome is 1 in 30 000 live births.³ In some cases associated anomalies have been reported, such as hypoplasia of the hand and forearm, hypoplasia of the breast, absent nipple, partial or total absence of other upper segment musculature, rib deformities, Möbius syndrome, absent ipsilateral kidney, and club foot.⁴ The presentation of Poland syndrome with leukaemia,⁵ ipsilateral hemivertebrae,⁶ and osseous polysyndactyly and radioulnar synostosis⁷ has also been reported.

Our patient had typical features of Möbius syndrome, characterised by congenital paralysis of cranial nerves VII, IX, X, and VI (facial diplegia, difficulty in swallowing, and external ophthalmoplegia), as well as the Poland anomaly. In addition, dextrocardia was an unusual accompanying abnormality. The association of Poland syndrome with dextrocardia has been reported in a boy with acute lymphocytic leukaemia⁵ and in another boy with absence of the permanent incisors.⁸ Dextrocardia in Poland-Möbius syndrome has been published only once.⁹ In our case, as in the other patients, dextro-

cardia was accompanied by a normal abdomen with no other cardiac abnormalities.

The cause of Poland syndrome is unknown, but it has been suggested that the primary defect may be in the development of the proximal subclavian artery with early deficit of blood flow to the distal limb and pectoral region.¹⁰ The Poland-Möbius syndrome represents a distinctive malformation syndrome but its aetiology remains undetermined.¹

References

- Herrman J, Pallister PD, Gilbert EF, *et al.* Studies on malformation syndromes of man. XXXXI B. Nosologic studies in the Hanhart and the Möbius syndrome. *Eur J Pediatr* 1976;**122**:19-55.
- Poland A. Deficiency of the pectoralis muscles. *Guy's Hosp Rep* 1841;**6**:191-5.
- Freire-Maia N, Chautard EA, Opitz JM, Freire-Maia A, Quelce-Salgado A. The Poland syndrome. Clinical and genealogical data, dermatoglyphic analysis and incidence. *Hum Hered* 1973;**23**:97-104.
- McGillivray BC, Lowry RB. Poland syndrome in British Columbia: incidence and reproductive experience of affected persons. *Am J Med Genet* 1977;**1**:65-74.
- Walters TR, Reddy BN, Bailon A, Vitale LF. Poland's syndrome associated with leukemia. *J Pediatr* 1973;**82**:889.
- Mace JW, Kaplan JM, Schanberger JE, Gotlin RW. Poland's syndrome. Report of seven cases and review of the literature. *Clin Pediatr (Phila)* 1972;**11**:98-102.
- Peterson BP, Pardo JM, Bond EC. Poland syndrome: a new presentation. *J Pediatr* 1977;**90**:843-4.
- Hanka SS. Dextrocardia associated with Poland's syndrome. *J Pediatr* 1975;**86**:312.
- Sugarman GI, Stark HH. Möbius syndrome with Poland's anomaly. *J Med Genet* 1973;**10**:192-6.
- Bouvet JP, Maroteaux P, Briard-Guillemot ML. Le syndrome de Poland. Etudes clinique et génétique. Considérations physiopathologiques. *Nouv Presse Med* 1976;**5**:185-90.

Correspondence and requests for reprints to Dr J M Bosch-Banyeras, Department of Paediatrics, Hospital General de Granollers, Avda Francisco Ribas s/n, Granollers, Barcelona, Spain.