

Endocrine abnormalities in a patient with partial trisomy 4q

M A ANGULO, M CASTRO-MAGANA, J SHERMAN, P J COLLIPP,
J MILSON, C TRUNCA, AND A N DERENONCOURT

Department of Pediatrics, Nassau County Medical Center, East Meadow, New York 11554, USA.

SUMMARY Partial trisomy of the long arm of chromosome 4, usually resulting from a familial segregation of a balanced translocation, has been described in a number of patients. This report describes the genetic and endocrine findings in a 16 year old 46,XY,12q+ mentally retarded male. The banding pattern of the extra chromatin material from this *de novo* unbalanced translocation shows that the distal segment of the long arm of chromosome 4 is involved. Comparison of the clinical features in this patient with cases of partial trisomy 4q previously reported support the cytogenetic evidence for this translocation involving the distal portion of 4q. Endocrine data suggested an end-organ resistance, characterised by extreme hyperinsulinaemia, primary hypothyroidism, and hypergonadotrophic hypogonadism associated with no signs of autoimmunity. To our knowledge, no endocrine evaluation has been previously reported in patients with partial trisomy 4q.

Partial trisomy is usually the result of segregation of a familial balanced translocation. The trisomic segment common to all clinically similar patients with partial trisomy 4q corresponds to the distal third of the long arm of chromosome 4. Partial trisomy 4q is manifested by growth retardation, microcephaly, brachycephaly, receding forehead, narrow palpebral fissures with downward slant, epicanthic folds, long nose with prominent bridge, low set ears, downturned fish-like mouth, pointed chin, short neck, widely spaced nipples, cryptorchidism, inguinal hernias, hypotonia, and mental retardation.¹

To our knowledge no endocrine evaluation has been previously reported in patients with partial

trisomy 4q. This report describes the endocrine abnormalities of a 16 year old, white, mentally retarded male with a 46,XY,12q+ chromosome complement. The extra segment of chromosome in this patient has a G banding pattern similar to that of the distal quarter of the long arm of chromosome 4. Our patient has in addition the clinical features of partial trisomy 4q.

Case report

This 16 year old white male came to the Pediatric Growth Clinic at the Nassau County Medical Center for evaluation of short stature, obesity, mental retardation, and aggressive behaviour.

He was born at 40 weeks' gestation by normal delivery to a 40 year old mother and had a birth-weight of 2200 g. He was the only child of the mother's second marriage. His father was 51 years old and there was no history of similarly affected members on either side of the family. His two brothers and two sisters of the mother's first marriage were healthy and phenotypically normal.

He was found to have psychomotor retardation during the first 2 years of life. During that period he had an inguinal hernia repaired. He developed periods of unprovoked and uncontrollable aggressive behaviour at home and at school at the age of 15, which worsened over the following year. Psychological evaluation at the age of 16 revealed a moderate range of mental retardation with a mental age of 6 to 8 years corresponding to an IQ of 45. He was admitted to an institution for mentally retarded children where he was found to have glycosuria (3+) and 2 hour postprandial glucose of 253 mg/100 ml.

Physical examination revealed an adolescent Caucasian male with poor verbal articulation and a high-pitched, nasal voice. He had normal vital signs and increased subcutaneous fat, and was 86 kg in weight (+2 SD) and 160 cm tall (-2 SD). His head circumference was 56.5 cm (average).

He had a protruding forehead, narrowing of the

palpebral fissures, epicanthic folds, large ears, prominent nasal bridge, short philtrum, carp mouth, high arched palate, small and slightly receding chin, short neck, barrel shaped chest with widely spaced nipples, stage I axillary hair, stage III pubic hair (Tanner), a testicular volume of 12 ml, and stretched penile length of 10 cm (fig 1).

CYTOGENETIC FINDINGS

Chromosome preparations were made from peripheral blood cultures by standard methods. Giemsa staining after trypsin treatment was used to identify the rearrangements.²

The proband showed in all metaphases analysed a modal number of 46 chromosomes and one atypical chromosome 12 with strikingly elongated long arms. Since his parents had apparently normal chromosomes, the identity of the piece translocated to chromosome 12 could not be ascertained with absolute certainty. The banding pattern of the additional chromatin material, however, was most consistent with that of the distal segment of the long arm of chromosome 4 (fig 2). If this is the case, this translocation most likely arose in a germ cell from one of the parents, when breaks occurred at band 4q31 in the long arm of chromosome 4 and at

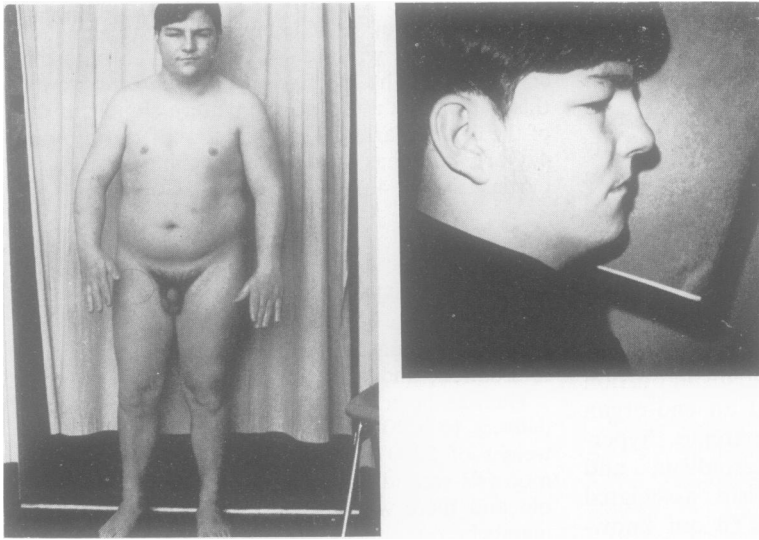


FIG 1 General and facial characteristics of the proband.

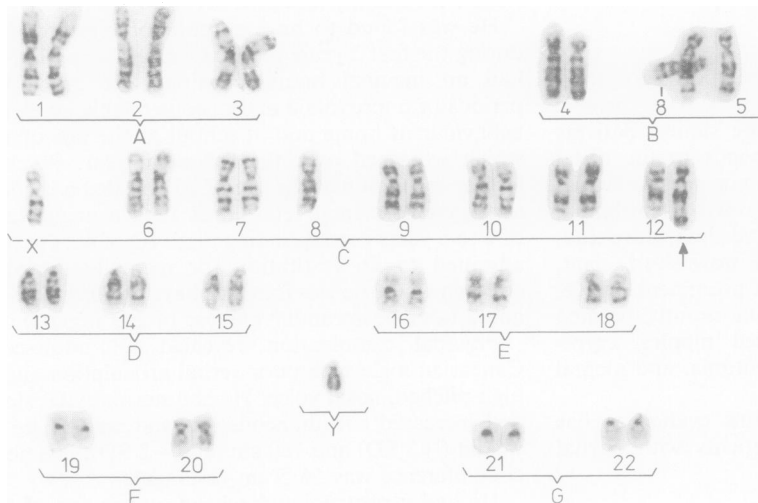


FIG 2 Karyotype from blood cultures of the patient showing the abnormal chromosome 12.

band 12q24 in the long arm of chromosome 12, and the distal portions of these chromosomes were exchanged. This patient's chromosome constitution is the result of having received the rearranged chromosome 12 and the normal chromosome 4 at fertilisation.

ENDOCRINE STUDIES

All hormone assays were performed by standard RIAs, as described previously.³⁻⁷ Serum LH and FSH were measured in samples drawn before and at 15 minute intervals after an intravenous bolus of synthetic LRH (100 µg) over 90 minutes. Basal FSH and LH were 35 mIU/ml and 25 mIU/ml respectively (normal FSH 2 to 10; normal LH 4.3 to 11.5). LRH administration induced an excessive response of both gonadotrophins, with a peak at 40 minutes (FSH 120 mIU/ml, LH 100 mIU/ml). Basal testosterone level was 210 ng/100 ml and its response to the administration of HCG 2500 IU intramuscularly daily for 5 consecutive days was impaired (220 ng/100 ml before and 310 ng/100 ml after). Basal serum T4 (3.8 µg/100 ml) and free T4 (0.4 ng/100 ml) were found to be low. His basal TSH levels were increased (50 µU/ml). Antimicrosomal and anti-thyroglobulin antibodies were not detected. The intravenous administration of 250 µg TRH provoked an exaggerated response of TSH and prolactin (TSH peak 130 µU/ml, PRL peak 135 ng/ml). The normal TSH response to TRH administration was achieved after 3 months' treatment with L-tyroxine (200 µg orally daily). Normal growth hormone (GH) response (14.5 ng/ml) was seen at 60 minutes after an intravenous infusion of arginine HCl 10% (0.5 g/kg). Insulin induced hypoglycaemia could not be obtained at doses of 0.1, 0.2, 0.3, and 0.4 U/kg, and no significant changes were seen in

GH and cortisol levels. A moderate rise of ACTH, however, was seen after a 41.6% drop in blood glucose concentration induced by the maximum insulin dose (fig 3).

Fasting serum glucose (173 mg/100 ml), insulin levels (400 µU/ml), and haemoglobin A_{1c} (11%) were found to be raised. A 5 hour glucose tolerance test with simultaneous measurements of serum insulin levels was found to be greatly impaired (table 1) indicating glucose intolerance associated with hyperinsulinism. Anti-insulin antibodies and islet cell antibodies were not detectable.

Additional laboratory studies, which included total blood cell count, erythrocyte sedimentation rate, antinuclear antibodies, serum electrolytes, liver enzymes, PTH (654 pg/ml), somatomedin C (0.93 U/ml), immunoglobulins, and serum and urine amino acids, were all normal. His bone age estimated by the method of Greulich and Pyle⁸ was 16 years. An IVP was normal and a CT scan of the head showed a mild to moderate degree of atrophy of the grey matter.

Discussion

Most reported cases of partial trisomy 4q result from a balanced parental rearrangement. Trisomy of the

TABLE 1 Oral glucose tolerance test (100 g glucose).

Time (h)	Glucose (mg/100 ml)	Insulin (µU/ml)
0	116	180
½	210	400
1	320	640
2	300	820
3	215	810
4	190	790
5	160	680

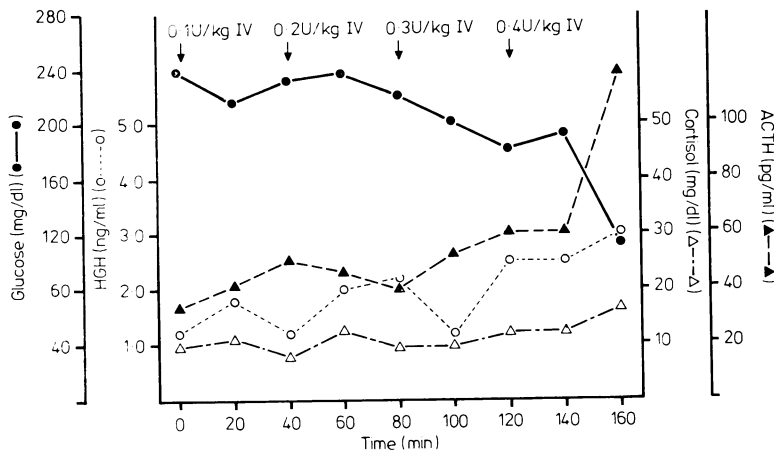


FIG 3 Insulin tolerance test demonstrating glucose, growth hormone (GH), ACTH, and cortisol response at different insulin doses.

distal third of 4q appears to be necessary for development of most of the clinical features first cytologically demonstrated in 1972⁹ and clinically delineated in 1975.¹⁰ Fewer than 30 cases have been reported, including two cases arising de novo associated with increased maternal age.¹ The phenotypic features of our patient are summarised and compared with 22 previously reported cases⁹⁻²² of partial trisomy 4q in table 2. The clinical picture of such chromosome abnormality varies considerably. With the exception of microcephaly, hypertelorism, and congenital heart disease, our patient had most of the clinical features associated with partial trisomy 4q. This variation may be related to such variables as age, sex, and different lengths of the long arm of chromosome 4, as well as the terminal loss of genetic material of the second chromosome involved in such an unbalanced translocation.

Although the translocation of 4q can occur onto any other chromosome, the chromosome analysis of the 22 cases used for comparison and others more recently reported²³⁻²⁶ reveals a relative predilection of 4q for chromosome 18 (11 out of 28 cases).

The patient's basal gonadotrophin levels and their response to the administration of LRH are characteristic of hypergonadotrophic hypogonadism. This is further supported by the greatly impaired testosterone response to the administration of HCG. The primary gonadal failure and the impaired secretion of gonadal steroids lead to a decreased negative feedback and raised FSH and LH. It is interesting that the most common forms of primary gonadal failure are associated with chromosomal abnormalities and characteristic physical findings.²⁷ Our patient may represent another chromosome abnormality associated with hypergonadotrophic

hypogonadism. The TSH level, and its response to TRH administration, is also characteristic of primary hypothyroidism. In contrast to most common forms of acquired hypothyroidism, no autoimmune aetiology could be demonstrated in our case, since antimicrosomal and antithyroglobulin antibodies were not detected. Evidence of an insulin resistant state in our patient derived first from the reduced effectiveness of exogenous insulin and secondly from the endogenous hyperinsulinism in the face of hyperglycaemia observed during the glucose tolerance test.

The association of glucose intolerance and hyperinsulinism are indicative of impaired insulin action. In our patient, the hyperinsulinaemia greatly exceeded that seen in obesity,²⁸ and therefore his insulin resistance is probably not solely due to his obesity.

Insulin resistance has been found to be associated with insulin antibodies,²⁹ antireceptor antibodies,³⁰ receptor deficiency,³¹ and post-receptor defects.³² Unfortunately, insulin receptor studies were not carried out in our case and, therefore, the pathogenesis of his insulin resistance remains undetermined. Our patient had extreme insulin resistance without increased anti-insulin antibodies, associated with an inborn defect (an unbalanced chromosome translocation).

In summary, our case seems to represent a partial trisomy 4q associated with exaggerated insulin resistance, hypergonadotrophic hypogonadism, and primary hypothyroidism. In contrast to most common forms of primary endocrine gland failure, no autoimmune aetiology could be demonstrated in our case. Therefore, it is tempting to speculate that a multiple hormone resistance could explain the pathogenesis of the endocrine abnormalities seen in our patient. Further studies are necessary to determine whether these endocrine abnormalities are part of the constellation of features associated with partial trisomy 4q, or if they are related to the loss of the terminal portion of chromosome 12.

TABLE 2 Comparison of 22 cases of partial trisomy 4q and our case.

Features	Published reports	Our case
Sex	12M/10F	M
Age	NB-8½ yr	16 yr
Mean birth weight	2460 g	2200 g
Size at birth	46.6 cm (43-50)	43 cm
Head circumference	33.6 cm (29-43.5)	42 cm
Psychomotor retardation	18/22	+
Large and low set ears	20/22	+
Short neck	14/22	+
Narrow palpebral fissures	13/22	+
Hypertelorism	13/22	-
Microcephaly	9/15	-
Hypotonia	12/22	+
Epicanthic folds	11/22	+
Congenital heart defect	11/22	-
Antimongoloid slanted eyes	8/22	-
Carp mouth	8/22	+
Inguinal and/or umbilical hernia	8/21	+
Protruding forehead	6/22	+
Prominent nasal bridge	6/22	+
Short philtrum	6/22	+
Widely spaced nipples	5/22	+
High arched palate	4/22	+

References

- de Grouchy J, Turleau C. Partial 4q trisomy. In: *Clinical atlas of human chromosomes*. New York: Wiley Medical Publications, 1977:28-32.
- Seabright M. A rapid banding technique for human chromosomes. *Lancet* 1971;ii:971-2.
- Benveniste R, Bell J, Rozenkobitch E, Rabinowitz D. Pituitary hormones and hypothalamic releasing factors. In: Luft R, Yalow RD, eds. *Radioimmunoassay: methodology and application in physiology and clinical studies*. Stuttgart: Thieme, 1976.
- Sluiter WJ, Van Kersen F, Van Zanten AK, Beckhuis H, Doorenbos H. A radioimmunoassay for human TSH employing a solid phase second antibody and a purified globin preparation for standardization of non-specific protein interactions. *Clin Chim Acta* 1972;42:255-62.

- ⁵ Sinha YN, Selby FW, Lewis UJ, Vanderlaan WP. A homologous radioimmunoassay for human prolactin. *J Clin Endocrinol Metab* 1973;**36**:509-16.
- ⁶ Glick SM, Roth J, Yalow RS, Berson SA. Immunoassay of human growth hormone in plasma. *Nature* 1963;**199**:784-7.
- ⁷ Abraham G. *Handbook of radioimmunoassay*. New York: Dekker, 1977: 591-652.
- ⁸ Greulich WW, Pyle SI. *Radiographic atlas of skeletal development of the hand and wrist*. 2nd ed. Stanford: Stanford University Press, 1959.
- ⁹ Surana RB, Conen PE. Partial trisomy 4 resulting from a 4/18 reciprocal translocation. *Ann Genet (Paris)* 1972;**15**:191-4.
- ¹⁰ Dutrillaux B, Laurent C, Forabosco A, et al. La trisomie 4q partielle. A propos de trois observations. *Ann Genet (Paris)* 1975;**18**:21-7.
- ¹¹ de la Chapelle A, Koivisto M, Schröder J. Segregating reciprocal (4;21) (q21;q21) translocation with proposita trisomic for parts of 4q and 21. *J Med Genet* 1973;**10**:384-9.
- ¹² Schwingshackl A, Ganner E. Partielle B trisomie bei cri du chat syndrome. *Pediatr Padol* 1973;**8**:362-71.
- ¹³ Fonatsch C, Faltz SD. Partial trisomy 4q and partial monosomy 18q as consequence of a paternal balanced translocation t(4q;18q-). *Humangenetik* 1974;**25**:227-33.
- ¹⁴ Schrott HG, Sakaguchi S, Francke U, Luzzatti L, Fialkow PJ. Translocation, t(4q-;13q-) in three generations resulting in partial trisomy of the long arm of chromosome 4 in the fourth generation. *J Med Genet* 1974;**11**:201-5.
- ¹⁵ Sparkes RS, Francke U. Syndrome of mental retardation and multiple congenital defects associated with partial trisomy of the long arm of chromosome 4 due to an inherited 20q- translocation. *Am J Hum Genet* 1973;**25**:73A.
- ¹⁶ Vogel W, Siebers JW, Gunkel J, et al. Phenotypic variation in partial trisomy 4q. *Humangenetik* 1975;**28**:103-12.
- ¹⁷ Baccichetti C, Tenconi R, Anglani F, Zacchello F. Trisomy 4q32-4qter due to a maternal 4/21 translocation. *J Med Genet* 1975;**12**:425-7.
- ¹⁸ Cervenka J, Djavadi GR, Gorlin RJ. Partial trisomy 4q syndrome. Case report and review. *Hum Genet* 1976;**34**:1-7.
- ¹⁹ Biederman B, Bowen P. Partial trisomy 4q due to familial 2/4 translocation. *Hum Genet* 1976;**33**:147-53.
- ²⁰ Issa M, Potter AM, Blank CE. Multiple congenital defects associated with trisomy for long arm of No 4. *J Med Genet* 1976;**13**:326-9.
- ²¹ Nielsen J, Rasmussen K, Lassen LB, Christiansen F. A family with a high risk of segregation for an autosomal unbalanced reciprocal translocation. *Hum Genet* 1976;**32**:343-8.
- ²² Yunis E, Giraldo R, Egel H, Ramirez E. Partial trisomy 4q. *Ann Genet (Paris)* 1977;**20**:243-8.
- ²³ Canki N, Debevec M, Rainer S, Rethoré M. Trisomie 4q26-4qter par translocation t(4;18)(q26;q23)mat. *Ann Genet (Paris)* 1977;**20**:195-8.
- ²⁴ McDermott A, Poulding R, Crechy D. Cri-du-chat syndrome in a child with a 46,XX,der(5)t(4;5)(q32;p14) pat karyotype. *Hum Genet* 1977;**39**:109-12.
- ²⁵ Stella M, Bonfante A, Ronconi G, Rossi G. Partial trisomy 4q: two cases with a familial translocation t(4;18)(q27;q23). *Hum Genet* 1979;**47**:245-51.
- ²⁶ Bonfante A, Stella M, Rossi G. Partial trisomy 4q: two cases resulting from a familial translocation t(4;18)(q27;p11). *Hum Genet* 1979;**52**:85-90.
- ²⁷ Grumbach MM, Conte FA. Disorder of sex differentiation. In: Williams RH, ed. *Textbook of endocrinology*. 6th ed. Philadelphia: Saunders, 1981.
- ²⁸ Rabinowitz D. Some endocrine and metabolic aspects of obesity. *Annu Rev Med* 1970;**21**:241-58.
- ²⁹ Flier JS, Khan CR, Roth J, Bar RS. Antibodies that impair insulin receptor binding in an unusual diabetic syndrome with severe insulin resistance. *Science* 1975;**190**:63-5.
- ³⁰ Khan CR, Megyesi K, Bar RS, Eastman RC, Flier JF. Receptors for peptide hormones: new insights into the pathophysiology of disease states in man. *Ann Intern Med* 1977;**86**:205-19.
- ³¹ Khan CR, Flier JS, Bar RS, et al. The syndromes of insulin resistance and acanthosis nigricans. Insulin-receptor disorders in man. *N Engl J Med* 1976;**294**:739-45.
- ³² Kobayashi M, Olefsky JM, Elders J, et al. Insulin resistance due to a defect distal to the insulin receptor: demonstration in a patient with leprechaunism. *Proc Natl Acad Sci USA* 1978;**75**:3469-73.

Correspondence and requests for reprints to Dr M A Angulo, Department of Pediatrics, Nassau County Medical Center, 2201 Hempstead Turnpike, East Meadow, NY 11554, USA.

Deletion of the short arm of chromosome 3: a case report with necropsy findings

DEBRA BENECK*, MARK J SUHRLAND†, RICHARD DICKER‡, M ALBA GRECO‡, AND SANDRA R WOLMAN*

Departments of Pathology*‡ and Pediatrics†‡, New York University Medical Center, New York, NY 10016, USA.

SUMMARY A male infant with partial deletion of the short arm of chromosome 3 is described. The features this patient shares with six previously reported cases include microcephaly, dolichocephaly, micrognathia, epicanthic folds,

ptosis, low set or malformed ears, postaxial polydactyly, and growth or mental retardation or both. In addition, visceral anomalies not previously reported in association with this chromosomal abnormality are described. These characteristics may constitute a recognisable clinical syndrome.