

# Hereditary sideroblastic anaemia and ataxia: an X linked recessive disorder

ROBERTA A PAGON\*, THOMAS D BIRD†, JAMES C DETTER‡, AND IRVING PIERCE

From the Departments of Pediatrics (Medical Genetics)\*, Medicine (Neurology)†, and Laboratory Medicine‡, the University of Washington School of Medicine\*†‡, Children's Orthopedic Hospital and Medical Center\*, and Seattle Veteran's Administration Medical Center†, Seattle, Washington, USA.

**SUMMARY** We report two families in which a non-progressive spinocerebellar syndrome and a sideroblastic anaemia are segregating together in an X linked recessive fashion. Four males in two generations of one family and a fifth male from an unrelated family had both conditions. Both the sideroblastic anaemia and the spinocerebellar syndrome differ from those which have previously been reported to be inherited in an X linked recessive manner. The association of these two clinically distinct disorders in two unrelated families suggests that they are either two closely linked loci which have undergone simultaneous mutation or pleiotropic effects of an altered allele at a single locus.

All the heterozygous women had normal neurological examinations and normal haematocrits and red cell indices. Some had ring sideroblasts on bone marrow examination, a dimorphic peripheral blood smear, and raised serum free erythrocyte protoporphyrin, suggesting that a proportion of heterozygotes can be detected by appropriate haematological studies.

We report two families in which a sideroblastic anaemia and spinocerebellar syndrome are segregating together in an X linked recessive fashion. Affected males have a moderate hypochromic, microcytic anaemia with ring sideroblasts on bone marrow examination. Although similar to the previously described X linked hereditary sideroblastic anaemia, this disorder is characterised by raised, rather than normal or low, free erythrocyte protoporphyrin levels and by a lack of excessive parenchymal iron storage in adulthood. The spinocerebellar disorder is different from the other reported X linked ataxias. It is characterised by a non-progressive ataxia and incoordination, as well as long motor tract signs in the younger affected boys. Intelligence is normal. Some heterozygous females have ring sideroblasts on bone marrow examination, a dimorphic peripheral blood smear, and raised serum free erythrocyte protoporphyrin.

male born at term, weighing 3.1 kg. At one year of age he had developmental delays because of truncal ataxia, dysmetria, and tremulousness. At 2½ years of age, when admitted to hospital for an unrelated illness, he was found to be anaemic (table 1). Peripheral blood smear showed microcytic, hypochromic red cells with anisocytosis and cigar-shaped cells. He had no hepatosplenomegaly. Bone

## Case reports

### FAMILY 1 (FIGURE)

The proband (patient IV.5) was a 5½ year old white

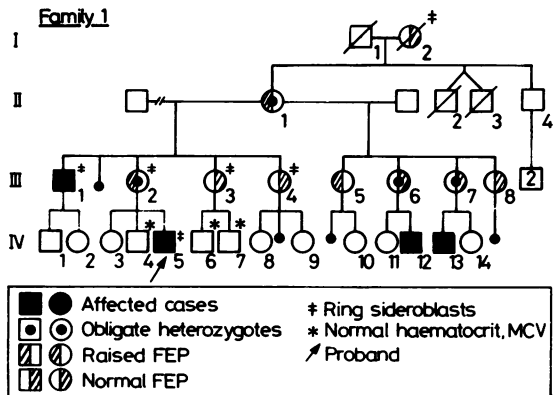


FIGURE Pedigree of family 1.

Received for publication 15 February 1984.  
Accepted for publication 2 August 1984.

TABLE 1 *Haematological findings.*

Patient	Sex	Age (y)	Genetic status	HCT (%)	MCV (fl)	Blood smear	FEP (mol/mol haem)	Ferritin (ng/ml)	Iron ( $\mu$ g/dl)	TIBC ( $\mu$ g/dl)	% sat	Ring sideroblasts	Xg <sup>d</sup>
<i>Family 1</i>													
III.1	M	33	A	35	67	D	184*	160	103	314	33	+	-
IV.5	M	5½	A	30	68	D	16.8*†	17	73	262	28	+	+
IV.12	M	2½	A	30	58	D	140*						+
IV.13	M	2	A	29	58	D							-
I.2	F	58	?	47		D	50‡					-	
II.1	F	50	OC	37	83	D	62*	88	82	278	29	+	+
III.2	F	32	OC	40	90	D	27*	40	71	329	22	+	+
III.6	F	25	OC	39	84	N	10	62	63	314	20		+
III.7	F	24	OC	37	83	D	18	42	72	278	26		+
III.3	F	30	50% risk	40	91	N	18	30	121	418	29	+	
III.4	F	28	50% risk	41	89	D	32‡	10	60	345	17	+	
III.5	F	27	50% risk	37	82	D	41*	53	114	323	35		+
III.8	F	22	50% risk	36	90	N	15	56	51	381	13		-
<i>Family 2</i>													
A	F	26	PC	36	87	D	31*					+	
B	M	8¼	A	26	58	D	230*	135	116	305	38	+	
<i>Normal values</i>													
							8-18	20-160	55-155	300-350	20-50		

A=affected. N=normal. PC=presumed carrier. OC=obligate carrier. D=dimorphic red cell population. FEP=free erythrocyte protoporphyrin. Raised FEP value. †Normal=1-5  $\mu$ g haem. ‡Normal=0-100  $\mu$ g/dl RBC. §Normal=1-60  $\mu$ g/dl.

marrow examination showed a myeloid to erythroid ratio of 3:1, no hyperplastic reaction of the red cell series, abundant iron stores, and a few ring sideroblasts. No transfusions were required and the haematocrit remained in the 29 to 32% range.

At 5½ years, his physical examination was normal including height (104.5 cm), occipital frontal circumference (OFC) (50.5 cm), visual acuity, and colour vision. He had no strabismus or nystagmus. He had pathologically brisk deep tendon reflexes in the lower extremities, unsustained ankle clonus, truncal ataxia when sitting, and a shuffling, ataxic gait. Muscle tone was normal. Plantar reflexes were extensor.

His maternal uncle, patient III.1, who was 33 years old, had weighed 2.3 kg at birth. Because of a non-progressive neurological disorder, he had not walked independently until 9 years of age. He had had strabismus surgery in childhood. At the age of 32 years he had a verbal IQ of 95 and a performance IQ of 82 on the WAIS-R.

Anaemia was discovered during a routine physical examination at 17 years of age (table 1). His peripheral smear showed microcytic, hypochromic red cells with marked poikilocytosis, shift to the left, and heavy stippling. Bone marrow examination showed hypercellularity with an E:G ratio of 3:1 and increased iron stores with 80% ring sideroblasts. Except for a serum iron of 224  $\mu$ g/dl at his initial evaluation, serum iron levels never exceeded 155  $\mu$ g/dl (normal 55 to 155  $\mu$ g/dl), and TIBC saturation was 51%, 53%, and 33% (normal 20 to 50%) at 22, 24, and 33 years of age, respectively. Haemoglobin

electrophoresis showed 3.1% Hb A<sub>2</sub> (normal) and 2.0% Hb F (slightly raised) and there were no red cell inclusions with brilliant cresyl blue staining. Red cell pyridoxine kinase activity was normal (L R Solomon, 1983, personal communication). Treatment with oral vitamin B<sub>6</sub> 200 mg/day for one month and then 400 mg/day for one month did not alter HCT, MCV, MCH, or reticulocyte count. His haematocrit was consistently in the 35 to 39% range and he never required transfusion.

At the age of 33 his physical examination was normal including height (169 cm), OFC (57 cm), visual acuity, and colour vision. He had mild dysarthria, mild bilateral finger-to-nose dysmetria, difficulty with rapid alternating movements, mild heel-to-shin ataxia, an abnormal Romberg test, poor tandem walking, and a moderately ataxic gait with toe walking. He had no nystagmus. His deep tendon reflexes were active but normal, except at the knees where they were pathologically brisk. There was no patellar or ankle clonus. Plantar reflexes were difficult to elicit but appeared to be flexor. Sensation was intact to pin, light touch, vibration, and position. There was no muscle weakness or atrophy. Cranial CT scan was normal as were brain stem auditory evoked potentials for both ears and pattern reversal visual evoked potentials for both eyes. A high resolution prometaphase karyotype was 46,XY with no evidence of an interstitial deletion of the X chromosome.

Patient IV.12 was a 2½ year old male born at term, weighing 3.8 kg. Early developmental milestones were normal. Truncal instability prevented

independent standing, although he was able to walk with support from the age of one year. Language was normal at 2½ years but mild articulation difficulties were present. Cranial CT and EEG were normal. He had had surgery for accommodative esotropia.

Anaemia was initially diagnosed at 6 months of age (table 1). General physical examination was normal, including height (92.7 cm) and OFC (51.75 cm). Tendon reflexes were normal in the upper extremities and pathologically brisk in the lower extremities with unsustained ankle clonus and bilateral extensor plantar responses. There was mild truncal ataxia and he was unable to walk without assistance. He had no nystagmus, no muscle atrophy, and no sensory deficits.

Patient IV.13 was a 23 month old male born at term, weighing 2.9 kg. His early developmental milestones were normal, but he made no progress in gross motor development after 12 months of age. He was unable to stand independently and walked only with support. He was able to drink from a cup and finger-feed himself. At 21 months of age he had normal receptive language but delayed expressive language and articulation difficulty. Audiological evaluation was normal. Anaemia was diagnosed during the first 6 months of life (table 1).

General physical examination was normal including height (83.0 cm) and OFC (49 cm). He had marked ataxia while sitting which usually required him to assume a tripod position, marked dysmetria, pathologically brisk deep tendon reflexes in his lower extremities, and a left extensor plantar response. Muscle tone was normal. He had no nystagmus or strabismus.

Three males (IV.4, IV.6, and IV.7) who were normal neurologically had normal haematocrits, haemoglobin levels, red cell indices, and peripheral smears.

The obligate heterozygote women (II.1, III.2, III.6, and III.7) and the women at 50% risk for inheriting this gene (III.3, III.5, and III.8) had normal physical examinations and detailed neurological examinations. Their haematological evaluations and that of a woman at 50% risk (III.4) who was unavailable for physical examination are summarised in table 1. Patient III.2 also had a peripheral blood high resolution prometaphase chromosome analysis which showed a 46,XX karyotype and no evidence of an interstitial deletion of one X chromosome.

#### FAMILY 2

The proband (patient B) was an 8 year old white male who was born at term, weighing 2.6 kg. Anaemia was diagnosed at 3 months of age during

routine examination. Peripheral smear showed poikilocytosis with abnormally shaped cells. Bone marrow examination at one year of age showed an E:G ratio of 3:1, normal myeloid precursors, abundant iron stores, and occasional ring sideroblasts. Serum iron at the ages of 7 months, 8 months, 2½ years, 4 years, and 8 years ranged from 64 to 116 µg/dl with TIBC saturation ranging from 20 to 38%. At 11 months of age Hb F was 6.2% and Hb A<sub>2</sub> was 2.7%. Red cell inclusion body studies were negative. Haematocrit ranged from 22 to 30% and he never required transfusion.

Early developmental milestones were normal, but at 13 months his parents noted poor balance. At 18 months of age he had truncal ataxia and dysmetria. At 2½ years of age he was unable to walk unaided, deep tendon reflexes were normal, and plantar responses were extensor. By 5½ years of age he walked using a weighted push walker and at 8 years of age he began walking with offset crutches. EEG, CT scan, nerve conduction velocity, ECG, audiological evaluation, urine metabolic screen, blood lead levels, quantitative immunoglobulins, cholesterol, triglyceride, and lipoprotein electrophoresis were normal. At 4 years 2 months a verbal IQ score was 107 (WPPSI) and a full scale IQ was 100 (Leiter).

At 8 years 3 months general physical examination was normal including height (124 cm) and OFC (50 cm). He had slightly hesitant speech with mild enunciation difficulties, but no dysarthria. There was no hepatosplenomegaly. Neurological examination showed no resting tremor or truncal ataxia, but there was intention tremor, dysmetria, dysdiadochokinesis, and gait ataxia which prevented independent walking. Visual acuity was normal and there was accommodative esotropia. Fine nystagmus which had been noted at 7 years of age was not observed. Deep tendon reflexes were normal at the knees and ankles. There was no ankle clonus and the plantar responses were flexor. Muscle strength and sensory examination to pin, touch, and vibration were normal.

There was no family history of anaemia or neurological disorders. His mother (patient A) was well and detailed neurological testing was normal. She had no history of anaemia, alcohol abuse, or exposure to drugs known to cause sideroblastic anaemia. Seven years earlier, at the time of her son's initial evaluation, she had had a bone marrow examination which showed a normal E:G ratio, abundant iron stores, ring sideroblasts, and many abnormal siderocytes. Her haematological evaluation is summarised in table 1. No other family members were available for evaluation.

A four generation pedigree of both families revealed that they were not related.

### Summary of findings

The five affected males reported here have a neurological disorder characterised by non-progressive ataxia and incoordination which was apparent by one year of age. This presumably represents dysfunction of the cerebellum or its afferent or efferent pathways. None had sensory loss, significantly reduced visual acuity, or optic atrophy. Three had strabismus. In addition, the three younger boys under the age of 6 years had long motor tract signs manifest by brisk deep tendon reflexes, ankle clonus, and extensor plantar responses which were not observed in their uncle or in the 8 year old unrelated boy. There was no pes cavus, scoliosis, or muscle wasting in any of the affected males. Intellectual abilities were within the normal range for the adult men and the 8 year old boy, and appeared to be normal in the three younger boys.

All five of the males with the neurological disorder had a hypochromic, microcytic anaemia and abnormalities of the peripheral smear that are typical of sideroblastic anaemia. This diagnosis was established in III.1, IV.5, and patient B by extensive haematological studies, including bone marrow examinations which showed an increased E:G ratio, increased iron stores, and ring sideroblasts. None of these three males had evidence of iron overload by serum iron and TIBC studies, although III.1 had an initial TIBC saturation of 70% 11 years

previously. Patients III.1 and B had no evidence of thalassaemia by haemoglobin electrophoresis and red cell inclusion studies. Patient III.1 was unresponsive to pyridoxine therapy.

None of the five males had any other medical problems or physical stigmata of other genetic disorders known to be X linked. The two males in family 1 who were old enough to be tested had normal colour discrimination by HRR plates and Ishihara plates. In family 1, Xg<sup>a</sup> blood group testing showed two of the affected males to be Xg<sup>a</sup> positive and two to be Xg<sup>a</sup> negative. No X chromosome deletion was seen on high resolution banded studies of one affected male (III.1) and one obligate heterozygote (III.2).

A dimorphic peripheral red cell smear was seen in four of the five obligate and presumed carriers and in two of the four women at 50% risk. Bone marrow examination showed ring sideroblasts in five of the six women tested, two of whom were obligate carriers, one of whom was a presumed carrier, and two of whom were at 50% risk. Free erythrocyte protoporphyrin was raised in only three of the six obligate and presumed carriers. The two obligate carriers with normal FEP did not have bone marrow examinations. In the four women at 50% risk, FEP was raised in one and normal in three, of whom two (III.3 and III.4) had ring sideroblasts on bone marrow examination. None of the heterozygous women or women at 50% risk who were tested had raised serum iron, transferrin saturation, or ferritin.

TABLE 2 *X linked spinocerebellar syndromes.*

Reference	Age of onset	IQ	Ataxia	Intention tremor/dysmetria	Dysarthria	Nystagmus	Strabismus	Eye findings	DTR	Plantar responses	Sensation	Progressive deterioration	Other findings
7		?N	-	-	-	+	-	N	↑	↓	N	?	Legs only involved
8	6-25 y	N	-	-	-	-	-	N	↑	↓	N	+	Walk unaided
9	6-12 mth	Low	+	+	+	+	+	OA 1/2	↑	↑	N	+	Decerebrate by 6 y, myoclonic seizures
10	Birth	Low	+	+	+	+	+	N	↑	↑	N	+	Weakness, flexion contractures, wheelchair by 12 y, scoliosis
11	5 y	N	+	+	+	+	+		-	↑	N	+	Generalised muscle atrophy, bedridden by 20 y, scoliosis
12-14	0-12 mth	N	-	-	+	+	+	OA +	↑	↑	N/A	+	Paralysis of legs
15	6-16 y	N	+	+	+	+/-		N	↑	↑	A	+	Distal muscle atrophy of legs, scoliosis
16	16-21 y	N	+	+	+	+		N	↑	↑	N	+	Leg weakness
Present report	6 mth	N	+	+	+/-	1/5	3/5	N	↑	↑/↓	N	-	Normal strength, walk unaided by 6-10 y, no scoliosis

OA=optic atrophy. A=abnormal. -=absent. DTR=deep tendon reflexes.

## Discussion

### THE SIDEROBLASTIC ANAEMIA PHENOTYPE

An X linked recessive form of sideroblastic anaemia has previously been described, but it is not associated with other systemic disorders except early haemosiderosis. Specifically, none of the males described in some detail with documented<sup>1-4</sup> or probable<sup>5,6</sup> X linked sideroblastic anaemia have had neurological problems. The X linked recessive spinocerebellar degenerations that have been reported have neurological manifestations different from those observed in these two families (table 2). None has been associated with anaemia. Thus, the X linked recessive disorder of sideroblastic anaemia and ataxia present in the two families described here appears to be unique.

The term sideroblastic anaemia refers to a heterogeneous group of anaemias in which immature red cells accumulate intramitochondrial iron, presumably secondary to a defect in haem synthesis.<sup>17,18</sup> There are several acquired forms of sideroblastic anaemia and at least two hereditary types: an X linked recessive type and a rarer autosomal recessive type. The metabolic defects in the hereditary sideroblastic anaemias are not known.

The X linked recessive type of sideroblastic anaemia is a hypochromic, microcytic anaemia that is usually mild to moderate, but there can be considerable variability even within a family.<sup>1,3,4</sup> It is characterised by a dimorphic red cell population in which RBCs of normal and abnormal shape are seen on peripheral smear. Iron stains of bone marrow preparations reveal a large number of immature red cells with intramitochondrial iron surrounding the nucleus, the so-called 'ring sideroblasts'.<sup>17,18</sup> The free erythrocyte protoporphyrin (FEP) is usually normal or decreased.<sup>19-21</sup> When free erythrocyte coproporphyrin (FEC) is increased, a defect in coproporphyrinogen oxidase is postulated; when FEC is low, a defect in  $\delta$ -aminolaevulinic acid synthase (ALA-S) has been postulated.<sup>18</sup> Rarely, FEP is raised<sup>22(case 5)</sup> but clinical details were not available to determine if such patients have a distinct phenotype. Some investigators have suggested that a defect in haem synthetase may be responsible for the anaemia in these patients.<sup>22</sup>

Males with X linked hereditary sideroblastic anaemia can have histological and clinical evidence of parenchymal iron overload by the second or third decade even without exogenous iron therapy or previous transfusions.<sup>2,5,18-20</sup> The serum iron and percentage transferrin saturation are abnormally high in childhood.<sup>23</sup> The basis of the excessive iron accumulation is not known. Pyridoxine has been

successful in increasing the haematocrit and FEP in some males with X linked sideroblastic anaemia, although the red cell morphology does not return to normal.<sup>3,4,24</sup> The observed variability in responsiveness to pyridoxine therapy within families<sup>3,4,24,25</sup> suggests that pyridoxine responsiveness or the lack of it does not indicate genetic subtypes of X linked hereditary sideroblastic anaemia.

Females heterozygous for X linked hereditary sideroblastic anaemia have a normal haematocrit and MCV, but a dimorphic population of red blood cells on peripheral smear<sup>1,25-27</sup> and ring sideroblasts on bone marrow examination.<sup>25-27</sup> Some investigators have reported raised serum iron (greater than 25  $\mu\text{mol/l}$ ) and transferrin saturation greater than 40% in carrier women.<sup>23</sup>

Although the sideroblastic anaemia in these two families is similar to the previously described X linked hereditary sideroblastic anaemia, there are two notable differences. All five of the affected males in this report had markedly raised FEP as did three of six obligate and presumed heterozygotes. This contrasts with the low or normal FEP levels in those males<sup>19-21</sup> and females<sup>28</sup> with documented X linked sideroblastic anaemia in whom FEP was evaluated. Secondly, the three males who were evaluated had normal serum iron, TIBC, and transferrin saturation. Thus, the basis of the altered red cell iron storage in the sideroblastic anaemia associated with ataxia may be biochemically distinct from that in the more common X linked form of sideroblastic anaemia. Males with sideroblastic anaemia-ataxia may not be at increased risk for long term complications of visceral iron storage.

The fact that heterozygotes for the sideroblastic anaemia ataxia gene may be identified by raised FEP levels (rather than by raised serum iron or ferritin levels as in X linked hereditary sideroblastic anaemia) needs to be recognised by those providing genetic counselling to such families. While our data suggest that bone marrow examination is more sensitive than FEP in carrier detection, further studies are needed.

Linkage studies in families with X linked hereditary sideroblastic anaemia have been uninformative for G6PD,<sup>27</sup> uninformative for Xg<sup>a</sup>,<sup>27-29</sup> or suggest no linkage with Xg<sup>a</sup>.<sup>3</sup> In family 1 of this report, two affected males were Xg<sup>a</sup> positive and two were Xg<sup>a</sup> negative, indicating no linkage of the Xg<sup>a</sup> locus and the sideroblastic anaemia-ataxia locus.

### THE SPINOCEREBELLAR PHENOTYPE

Other reported families with X linked hereditary sideroblastic anaemia have had no associated neurological disorders.<sup>1-4</sup> The neurological disorder in the five males reported here was an early onset,

non-progressive spinocerebellar syndrome manifesting primarily as ataxia, dysmetria, and dysidiadochokinesis. Dysarthria and intention tremor were mild when present. Impairment of visual acuity either from optic atrophy or retinal dystrophy was not seen. Strabismus was seen in three of the five males and nystagmus in one, but extraocular movements were normal. The ataxia appeared to improve with time such that truncal titubation decreased (patient B) and walking became progressively easier.

This disorder was also associated with signs of upper motor neurone involvement in early childhood that seemed to improve with age. The three younger males who were less than 6 years old had increased tendon reflexes in the lower extremities, equivocal or extensor plantar responses, and unsustained ankle clonus. The one affected adult and older boy did not have these long motor tract signs. Whether patient III.1 had evidence of upper motor neurone involvement as a boy is not known. Patient B had consistently been noted to have hypoactive tendon reflexes; however, plantar responses were extensor at the age of 2½ years, but were flexor on examination at 8½ years of age. None of the affected males had pes cavus, scoliosis, muscle wasting, sensory loss, or mental retardation.

Both X linked spinocerebellar degeneration and X linked spastic paraparesis are rare. Bell<sup>30</sup> found only one family with probable X linked spinocerebellar ataxia and one with definitive X linked recessive spinocerebellar ataxia in an extensive review of published reports. In a more recent review of pure spastic paraparesis,<sup>31</sup> none of the 23 families showed X linked inheritance.

The neurological manifestations of the males reported here were not typical of any of the previously reported X linked spinocerebellar degenerations or spastic parapareses (table 2). The families reported by Blumel<sup>7</sup> and Zatz *et al*<sup>8</sup> had spastic paraparesis with no cerebellar involvement. The other six reports were of families with a progressive combined spinocerebellar degeneration and long motor tract involvement. The family of Malamud and Cohen<sup>9</sup> had early onset and rapid progression of motor and mental deterioration, such that affected males were decerebrate by 6 years of age. The males reported by Baar and Gabriel<sup>10</sup> were 'crippled' at birth, had hyperreflexia and increased muscle tone of the upper and lower extremities, and profound mental retardation. Turner and Roberts<sup>11</sup> described a family in which nine males in two generations had the onset of clumsiness at the age of 5 years that progressed to a bedridden state with muscle atrophy, pes cavus, masked facies, and nystagmus. These males had absent tendon reflexes and normal mentality.

Johnston and McKusick,<sup>12</sup> Johnston,<sup>13</sup> and Thurmon and colleagues<sup>14</sup>(kindred 1) described the same family with a progressive spastic paraparesis, nystagmus, and optic atrophy. Only one family member had intention tremor.<sup>13 14</sup> Spira *et al*<sup>15</sup> reported males with delayed onset (between 2 and 16 years) ataxia that progressed to loss of ambulation and included pes cavus, scoliosis, dysmetria, dysarthria, muscle wasting, hyperactive tendon reflexes, and Babinski responses, as well as impaired position and vibration sense in adults. While the neurological findings in the family reported by Shokeir<sup>16</sup> were similar to those manifest by our patients, his patients had delayed onset of their cerebellar symptoms (between 6 and 23 years) and progressive deterioration until the age of 30 years. They also had hyperactive tendon reflexes and extensor plantar responses, and some had ankle clonus.

The neurological syndrome in the present families is unlike that seen in subacute combined degeneration of the spinal cord associated with pernicious anaemia because of the consistently normal sensory examination. The disease in the present families is also unlike X linked adrenoleucodystrophy (ADL) or adrenomyeloneuropathy (AMN) because of the presence of sideroblastic anaemia and the absence of mental changes, visual deficits, sensory loss, progression of neurological disease, and adrenal dysfunction.

### Conclusion

We conclude that in the two families presented here, the sideroblastic anaemia and spinocerebellar disorder are caused either by two closely linked loci on the X chromosome or by the pleiotropic effects of an altered allele at a single locus. The findings of normal intelligence, normal stature, and normal high resolution chromosome preparations suggest that a small deletion of the X chromosome is not present in these patients. Recognition that this disorder is clinically distinct and X linked recessive allows for appropriate genetic counselling of families of sporadic cases, such as the proband in family 2 of this report. Detection of some heterozygotes through bone marrow examination for ring sideroblasts and raised serum free erythrocyte protoporphyrin levels is possible. The favourable long term prognosis of the spinocerebellar syndrome is an indication for vigorous and early physical, occupational, and speech therapy and appropriate educational placement. The possibility of excessive parenchymal iron storage requires close monitoring. Further studies are warranted to determine the common metabolic link between the anaemia and the ataxia.

The authors thank Marilyn Ostertag, Jennifer Johnson, and Maxine Covington for their assistance in evaluation of the family and preparation of the manuscript. We are grateful to Dr Quinton De Marsh for referring the proband of family 1 and to Dr William Hammond for reviewing the manuscript. We are indebted to Dr Ellen Magenis of the University of Oregon Health Sciences Center, Portland, Oregon, for the high resolution chromosome studies. We are grateful to family 1 for their interest, enthusiasm, and cooperation.

#### References

- 1 Rundles RW, Falls HF. Hereditary (? sex-linked) anemia. *Am J Med Sci* 1946;**211**:641-58.
- 2 Gelphi AP, Ende N. An hereditary anemia with hemochromatosis. *Am J Med* 1958;**25**:303-14.
- 3 Bourne MS, Elves MW, Israels MCG. Familial pyridoxine-responsive anaemia. *Br J Haematol* 1965;**11**:1-10.
- 4 Elves MW, Bourne MS, Israels MCG. Pyridoxine-responsive anaemia determined by an X-linked gene. *J Med Genet* 1966;**3**:1-4.
- 5 Mills H, Lucia SP. Familial hypochromic anemia associated with postsplenectomy erythrocytic inclusion bodies. *Blood* 1949;**4**:891-904.
- 6 Byrd RB, Cooper T. Hereditary iron-loading anemia with secondary hemochromatosis. *Ann Intern Med* 1961;**55**:103-23.
- 7 Blumel J, Evans EB, Eggers GWN. Hereditary cerebral palsy. *J Pediatr* 1957;**50**:454-8.
- 8 Zatz M, Penha-Serrano C, Otto PA. X-linked recessive type of pure spastic paraplegia in a large pedigree: absence of detectable linkage with Xg. *J Med Genet* 1976;**13**:217-22.
- 9 Malamud N, Cohen P. Unusual form of cerebellar ataxia with sex-linked inheritance. *Neurology (Minneapolis)* 1958;**8**:261-6.
- 10 Baar HS, Gabriel AM. Sex-linked spastic paraplegia. *Am J Ment Defic* 1966;**71**:13-8.
- 11 Turner EV, Roberts E. A family with a sex-linked hereditary ataxia. *J Nerv Ment Dis* 1938;**87**:74-80.
- 12 Johnston AW, McKusick VA. A sex-linked recessive inheritance of spastic paraplegia. *Am J Hum Genet* 1962;**14**:83-94.
- 13 Johnston AW. X-linked spinocerebellar degeneration. *Birth Defects* 1974;**X**:334-6.
- 14 Thurmon TF, Walker BA, Scott CI, Abbott MH. Two kindreds with a sex-linked recessive form of spastic paraplegia. *Birth Defects* 1971;**VIII**(1):219-21.
- 15 Spira PJ, McLeod JG, Evans WA. A spinocerebellar degeneration with X-linked inheritance. *Brain* 1979;**102**:27-41.
- 16 Shokair MHK. X-linked cerebellar ataxia. *Clin Genet* 1970;**1**:225-31.
- 17 Cartwright GE, Deiss A. Sideroblasts, siderocytes and sideroblastic anemia. *N Engl J Med* 1975;**292**:185-93.
- 18 Bottomley SS. Porphyrin and iron metabolism in sideroblastic anemia. *Semin Hematol* 1977;**14**:169-85.
- 19 Weintraub LR, Conrad ME, Crosby WH. Iron-loading anemia. *N Engl J Med* 1966;**275**:169-76.
- 20 Vogler WR, Mingioli ES. Porphyrin synthesis and heme synthetase activity in pyridoxine-responsive anemia. *Blood* 1968;**32**:979-88.
- 21 Pasanen AVO, Salmi M, Tenhunen R, Vuopio P. Haem synthesis during pyridoxine therapy in two families with different types of hereditary sideroblastic anaemia. *Ann Clin Res* 1982;**14**:61-5.
- 22 Konopka L, Hoffbrand AV. Haem synthesis in sideroblastic anaemia. *Br J Haematol* 1979;**42**:73-83.
- 23 Hamel BCJ, Schretlen EDAM. Sideroblastic anemia. *Eur J Pediatr* 1982;**138**:130-5.
- 24 Bishop RC, Bethell FM. Hereditary hypochromic anemia with transfusion hemosiderosis treated with pyridoxine. *N Engl J Med* 1959;**261**:486-9.
- 25 Losowsky MS, Hall R. Hereditary sideroblastic anaemia. *Br J Haematol* 1965;**11**:70-85.
- 26 Pinkerton PH. X-linked hypochromic anaemia. *Lancet* 1967;**i**:1106-7.
- 27 Prasad AS, Tranchida L, Konno ET, et al. Hereditary sideroblastic anemia and glucose-6-phosphate dehydrogenase deficiency in a negro family. *J Clin Invest* 1968;**47**:1415-24.
- 28 Lee GR, MacDiarmid WD, Cartwright GE, Wintrobe MM. Hereditary, X-linked, sideroachrestic anemia. The isolation of two erythrocyte populations differing in Xg<sup>a</sup> blood type and porphyrin content. *Blood* 1968;**32**:59-70.
- 29 Weatherall DJ, Pembrey ME, Hall EG, Sanger R, Tippett P, Gavin J. Familial sideroblastic anaemia: problem of Xg and X chromosome inactivation. *Lancet* 1970;**ii**:744-8.
- 30 Bell J. On hereditary ataxia and spastic paraplegia. *Treasury of Human Inheritance* 1948;**4**:141-281.
- 31 Harding AE. Hereditary 'pure' spastic paraplegia: a clinical and genetic study of 22 families. *J Neurol Neurosurg Psychiatry* 1981;**44**:871-83.

Correspondence and requests for reprints to Dr Roberta A Pagon, Division of Medical Genetics, Children's Orthopedic Hospital and Medical Center, PO Box C-5371, Seattle, Washington 98105, USA.