

On 24.6.83, a 24 year old primipara in good health gave birth to a stillborn male fetus with multiple defects and the appearance of Potter's syndrome. Birth weight was 1775 g after a gestation of 36 weeks and a pregnancy complicated by polyhydramnios. At necropsy there was bilateral renal agenesis, absent ureters (bladder present), absent penis, imperforate anus, and a persistent truncus arteriosus. Owing to collapse of the skull, the cranium was not opened.

Following this, in November 1983, a four month macerated fetus required induction and delivery by D and C, and ten months later she delivered a missed abortion.

Because of this early fetal loss in conjunction with the previous malformed infant a karyotype was done on her and her husband. She showed a female karyotype with two apparently balanced translocations: 46,XX,t(2;13)(p21;q32) and t(5;14)(q33;q32). This indicated a very 'high' risk of reproductive failure. Her mother had one of the balanced translocations and had had two spontaneous abortions, as well as two sons and this daughter. One son, whose wife is currently 13 weeks pregnant, was found to have a normal karyotype. The family history showed a maternal female cousin who had Down's syndrome with no karyotype available.

This case demonstrates that recurrence risks for perinatally lethal renal disease in association with multiple defects may not only relate to autosomal recessive genes, as suggested by Bankier *et al*, but may also show a chromosomal cause. It is therefore important to karyotype such infants because of the consequent high risk implications to other family members.

ATHEL HOCKEY, JUNE CROWHURST,
AND IAN WALPOLE*

Genetic Counselling Clinic,

King Edward Memorial Hospital for Women; and

**University Department of Child Health,*

Princess Margaret Hospital for Children,

Subiaco, Western Australia 6008.

Mosaic trisomy 9

SIR,

In 1982¹ we published a case of mosaic trisomy 9 and delineated the clinical phenotype of this unusual trisomy. As there have been fewer than 30 patients reported so far, and since many of them died during the first year of life, there is little information about their development. For this reason we wish to report the development of our patient, who is now 4½ years old.

At 6 months the patient, a girl, had a urinary infection. Pyelography showed mild left pelvic dilatation. Cardiological studies were normal. At 20 months she had a convulsive episode; as she has been taking luminal ever since, the episode did not recur. When she was 2 years she was operated on for cataracts in the right eye. She has dorsal kyphoscoliosis and pes valgus.

With regard to developmental milestones, she stood up at 22 months and walked at 4 years. At present she does not speak. She is severely mentally retarded and has severe microcephaly (45 cm=50th centile for 1 year). Her mother became pregnant again last year and prenatal diagnosis showed a 46,XX karyotype.

J M SÁNCHEZ

*Fundación de Genética Humana,
Salta 661, 1074 Buenos Aires,
Argentina.*

Reference

- 1 Sánchez JM, Fijtman N, Migliorini AM. Report of a new case and clinical delineation of mosaic trisomy 9 syndrome. *J Med Genet* 1982;19:384-7.

Spondyloepiphyseal dysplasia tarda with progressive arthropathy: a rare disorder frequently diagnosed among Arabs

SIR,

Spondyloepiphyseal dysplasia tarda with progressive arthropathy (SEDPA) is a newly delineated clinical disorder,^{1,2} with strong evidence of autosomal recessive inheritance.^{1,3} The disorder bears a striking resemblance to rheumatoid arthritis but differs radiologically owing to the absence of destructive bone changes and the presence of dysplastic bone changes in addition to the platyspondyly. The lack of response to anti-rheumatoid treatment is also a distinguishing feature.

We recently examined a 30 year old Arab female patient with double first cousin Lebanese parents. They had six normal daughters and two mid-trimester miscarriages; there was no history of a similar condition in the family.

She appeared normal for the first 2½ years of life after which she developed difficulty in walking, swelling of the knees and small joints of the hands, followed by gradual stiffness in the knees. At the age of 5 years, a right genu valgum deformity was corrected surgically. Arthropathy of almost all limb joints was progressive and involved the elbows, wrists, hips, knees, and metaphalangeal and interphalangeal joints. By the age of 10 years, the small

hand joints were almost fixed in mild flexion, with hard, spindle shaped, painless swellings and marked limitation of movement. Later, the condition became slowly progressive with attacks of back pain and increasing pain in the hips necessitating an operation on the left side.

Examination showed normal facial features and disproportionate short stature: height 130 cm, upper segment to lower segment ratio 60 to 70 cm, and span 148 cm. Vision and hearing were normal. She had a mild flexion deformity in both elbows and knees with limitation of movement, which was also present in the hips and to a lesser degree in the shoulders and wrists.

Radiological examination showed generalised irregular platyspondyly with overall osteopenia and anterior fusion of L4 to L5 (fig 1). The pelvis was triangular in shape with small sciatic notches, severely narrowed hip joint spaces, and irregular enlarged femoral heads (fig 2). Phalangeal epiphyses and metaphyses were enlarged with multiple joint narrowing and osteoarthritic changes (fig 3).

Haematological investigations showed no evidence of rheumatoid disease.

In the paper by Wynne-Davies *et al.*,¹ which was the first time SEDT-PA was delineated as a new disorder, among the nine families with 15 patients

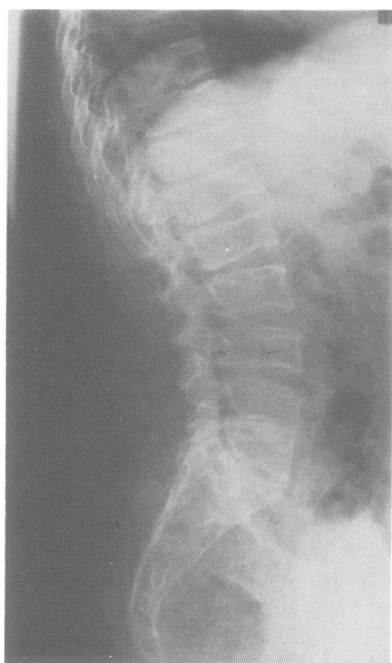


FIG 1 Lateral radiograph of the spine.

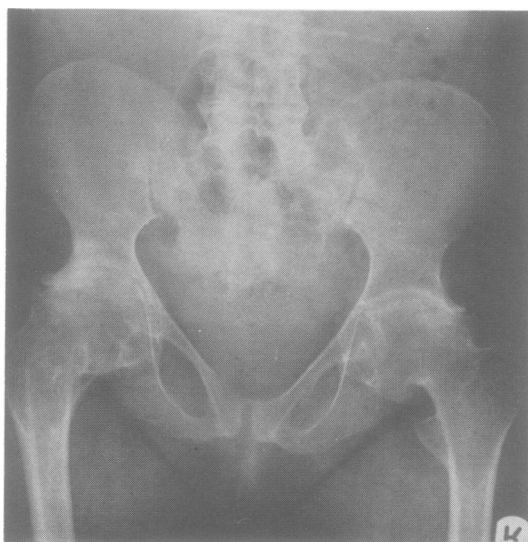

FIG 2 Radiograph of the pelvis.

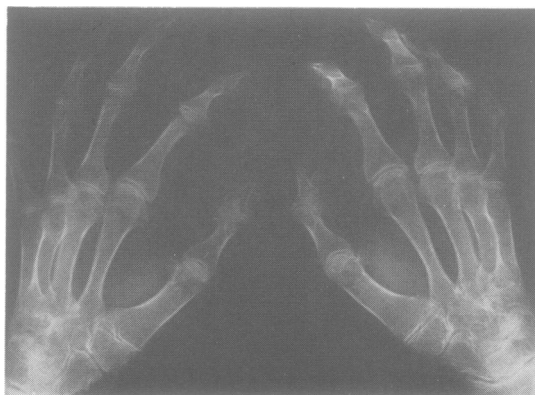

FIG 3 Radiograph of the hands.

described four families were Arabs and one was Greek. The only known instance of consanguinity was among one of the Arab families with four cases in two sibships. One of them had consanguineous parents and it is possible this may also be a feature in the other three Arab families.

Spranger *et al.*² also described an affected Arab girl of non-consanguineous parents who had a son said to suffer from the same symptoms. This girl was among five cases reported, including another case from Greece. Al-Awadi *et al.*³ recently described an Arab family from Jordan with eight affected members in five sibships, all of whom had first cousin

parents and were traced back to a common ancestor. Data from N Sakati (1985, personal communication) indicate the presence of SEDT-PA in Saudi Arabia also and include a family from Syria.

In total, we are aware of 15 published cases of classical SEDT-PA in addition to the present one. Seven were Arabs. Some of the Arab families include more than one sibship and several affected members. Consanguinity is frequent among them. These families constitute the majority of reported cases and, if those from Greece are included, it might be assumed that the allele responsible for the disorder in the homozygous state originated a long time ago in the Mediterranean region and was then distributed to Europe and other parts of the world. If this were true, the allele frequency in Mediterranean people would be expected to be relatively high and thus, because of the high consanguinity rate and large family size among Arabs, the condition would be more frequently seen. However, if cases of atypical rheumatoid arthritis are reviewed and a precise diagnosis made, we think that a better

estimate of the frequency of this disorder could be made. We expect the condition will be found to be commoner than is actually observed now even among Arabs and Mediterranean people.

AHMAD S TEEBI AND
SADIKA A AL AWADI
*Kuwait Medical Genetics Centre,
PO Box 4080,
Safat, Kuwait.*

References

- ¹ Wynne-Davies R, Hall C, Ansell BM. Spondyloepiphyseal dysplasia tarda with progressive arthropathy. A 'new' disorder of autosomal recessive inheritance. *J Bone Joint Surg (Br)* 1982;**64**:442-5.
- ² Spranger J, Albert C, Schilling F, Bartsocas C, Stöss H. Progressive pseudorheumatoid arthritis of childhood (PPAC). A hereditary disorder simulating rheumatoid arthritis. *Eur J Pediatr* 1983;**140**:34-40.
- ³ Al-Awadi SA, Farag TI, Naguib K, *et al.* Spondyloepiphyseal dysplasia tarda with progressive arthropathy. *J Med Genet*, 1984;**21**:193-6.