

Type II syndactyly or synpolydactyly

PAUL MERLOB AND MICHAEL GRUNEBAUM

From the Departments of Neonatology and Pediatric Radiology, Beilinson Medical Center, Petah Tiqva, and Tel Aviv University Sackler School of Medicine, Israel.

SUMMARY A new family with syndactyly type II or synpolydactyly is described with 16 affected members in six generations. No other major skeletal or extraskeletal malformations were present, but the association with minor local anomalies may be a common feature. Various metacarpal or metatarsal abnormalities may be part of this type of syndactyly. The family pedigree confirms the autosomal dominant mode of inheritance with incomplete penetrance and the frequent occurrence of non-manifesting heterozygotes resulting in 'skipped generations'.

Syndactyly type II or synpolydactyly is defined as a connection between the middle and ring fingers and fourth and fifth toes, variably associated with postaxial polydactyly in the same digits.¹ This is a rare congenital malformation and few well documented pedigrees have been published.²⁻⁶ We report a family with 16 affected members in six generations and discuss some of the features that are of special interest.

Case reports

The family pedigree is presented in fig 1. The first child (V.13) was born in 1981 after a normal pregnancy and delivery to a 33 year old, gravida 1, para 1 mother. The parents were unrelated. There was no history of any medication, alcohol intake, or smoking during pregnancy.

Physical examination revealed a healthy, term, male infant with a partial absence of the prepuce and malformations of both hands. Cutaneous syndactyly was observed between the third and fourth fingers with a duplication of the fourth finger (postaxial polydactyly). Skeletal survey was normal except for the radiographs of both hands (fig 2). Five metacarpal bones were identified and the third metacarpal was Y shaped. The ulnar arm of the third metacarpal was hypoplastic and represented the additional metacarpal of the duplicated fourth finger. The fourth and fifth metacarpals were shorter than usual. The fourth finger was duplicated and each digit was composed of three phalanges. The sixth finger had hypoplasia of all three phalangeal bones. Complete cutaneous syndactyly was

seen between the fourth and fifth fingers (duplicated fourth finger). Partial proximal cutaneous syndactyly was observed between the third and fourth fingers and also between the fifth and sixth fingers. The distal radius and ulna were normal. These changes were identical on both sides.

The second child (V.14), born in 1983, was a girl born at term with skeletal anomalies of the hands and feet. The postaxial syndactyly between the third and fourth fingers was accompanied by duplication of the fourth finger (fig 3). Both hands were affected symmetrically. On the feet there was bilateral postaxial syndactyly of the fourth and fifth toes, but postaxial polydactyly of the fifth toe was observed only on the right side (fig 4). A single palmar transverse crease and absence of the ventral skin creases of the fourth finger were noted on the right hand. The left hand had absence of the ventral skin creases of the fourth finger, absence of one crease of the fifth finger, prominence of the hypothenar region, and an abnormal pattern of palmar creases. The nail of the fifth toe of the left foot was hypoplastic.

The skeletal bone survey revealed abnormalities of both hands and feet. At a chronological age of 9 months the bone age was 6 months and equal on both sides. The hands were broader than normal. There were five metacarpals on each side and the third one was Y shaped (fig 5). The fourth and fifth metacarpals were shorter and narrower than usual. There were six fingers on each hand. On the right side there was bony fusion of the proximal half of the basal phalanx of the fourth and fifth fingers with complete syndactyly, almost forming one unit. Partial cutaneous syndactyly was also seen between the third and fourth fingers and between the fifth and sixth fingers.

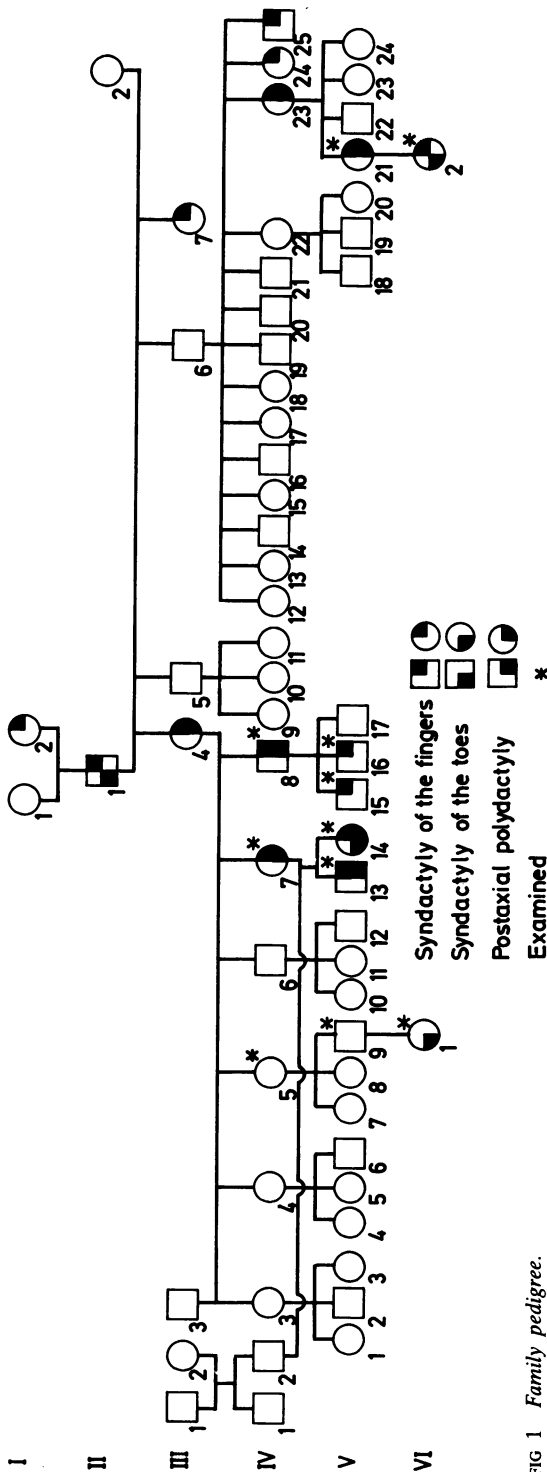


FIG 1 Family pedigree.

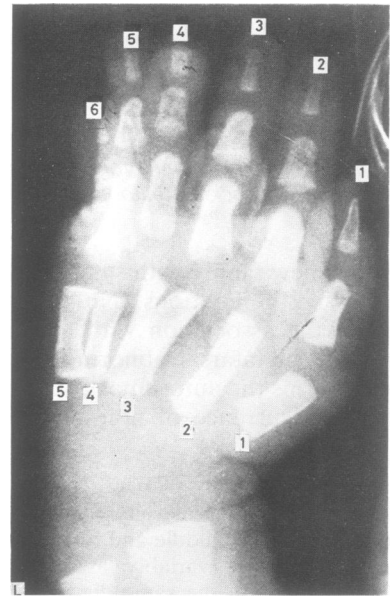


FIG 2 Patient V.13. Anteroposterior view of the left hand at birth.

The feet (fig 6) had symmetrical abnormalities of six metatarsal bones and six toes. The sixth metatarsal had a baseball stick shape and the phalanges of the fifth toe appeared hypoplastic on the left with complete absence of the proximal phalanx. On the right side the fifth toe appeared normal. The tarsal bones were normal bilaterally.

The mother (IV.7) of these children had postaxial syndactyly of the third and fourth fingers with polydactyly of the fourth finger. Her anomalies were bilateral and symmetrical. The feet were normal.

The uncle (IV.8) of the two children born in our hospital had the same skeletal anomalies of the third and fourth fingers. His synpolydactyly was bilateral and symmetrical but not associated with foot anomalies. Two of his three sons (V.15 and V.16) had the same clinical picture of bilateral synpolydactyly of the hands. We examined another three members of this family who showed variable aspects of syndactyly type II: VI.1 had involvement of the feet only, VI.2 had anomalies of the hands and feet, and V.21 had anomalies of the hands only.

By description and photographs another seven members of this family were identified as having variable patterns of synpolydactyly. No other malformations were known in this family. The proband's father (IV.2) and his family were healthy without any abnormalities.

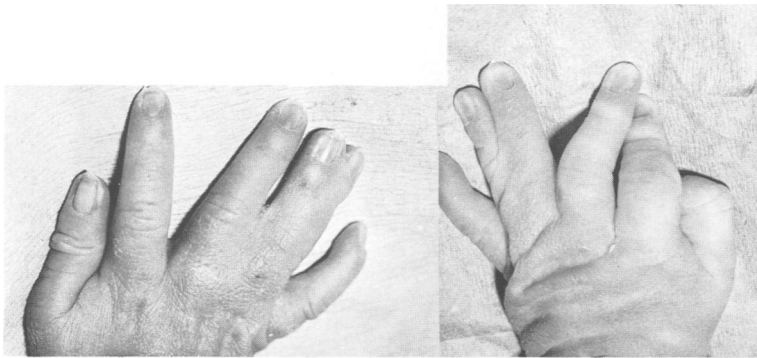


FIG 3 *Dorsal aspects of hands of V.14.*

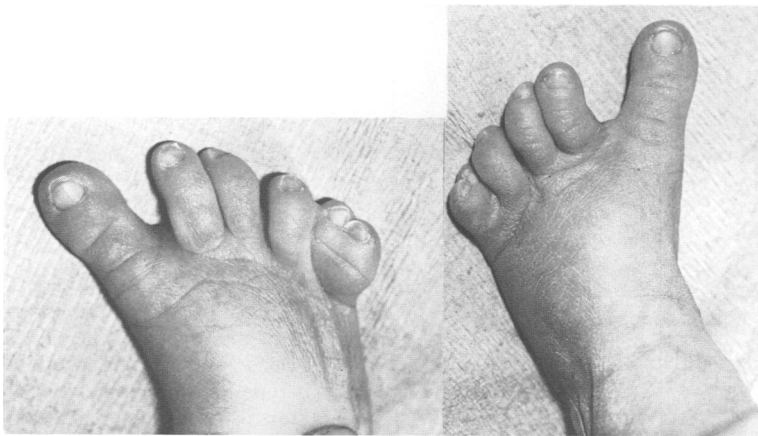

FIG 4 *Dorsal aspects of feet of V.14.*

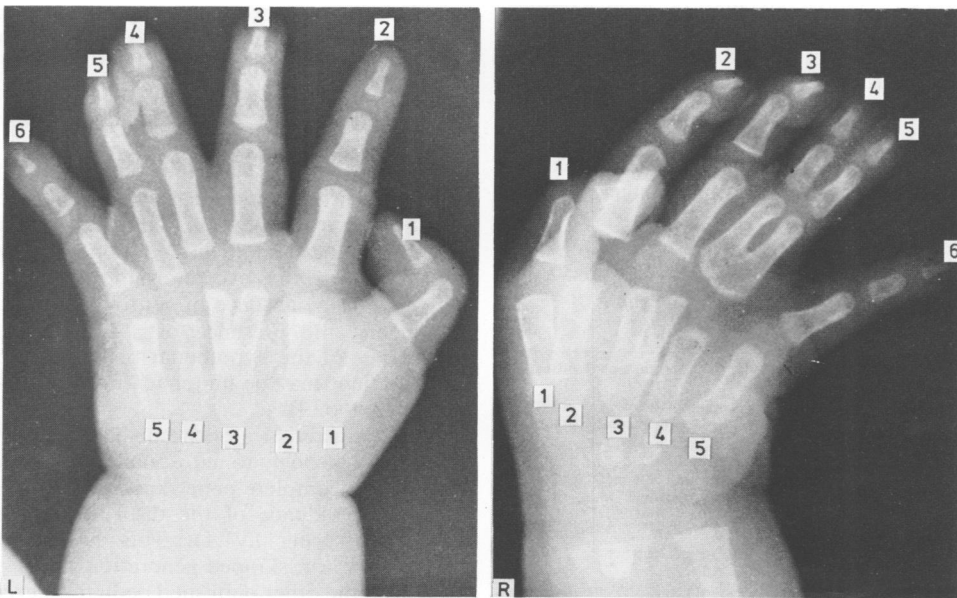


FIG 5 *Patient V.14. Anteroposterior view of the hands at 9 months.*

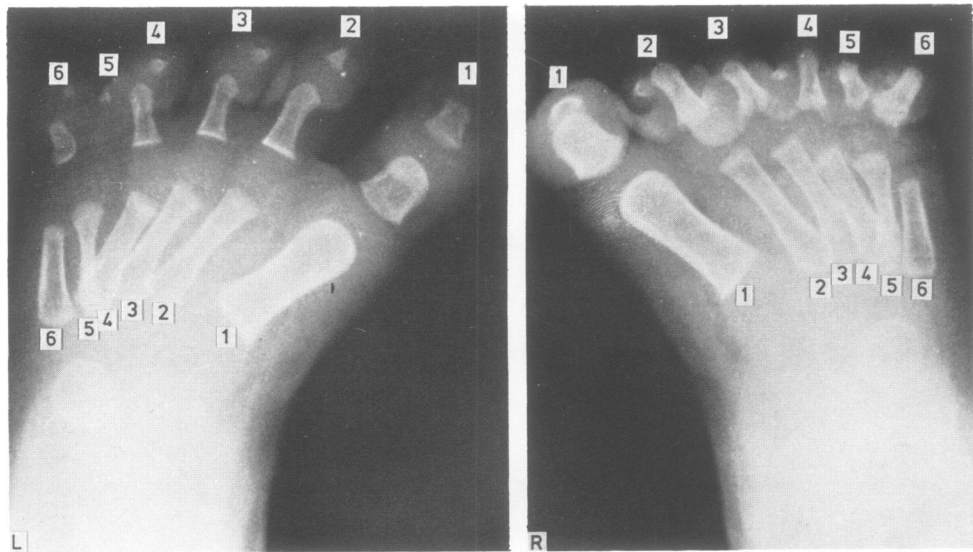


FIG 6 Patient V.14. Anteroposterior view of the feet.

Discussion

Syndactyly type II or synpolydactyly is one of the rarer types of isolated, non-syndromal syndactyly.^{1 6} The different anatomical types of isolated syndactyly are presented clearly by Temtamy and McKusick.¹ However, the clinical expression of various types of syndactyly may be more complicated, causing difficulties in proper classification.

Some of our patients had the basic trait of syndactyly type II, represented by syndactyly of the third and fourth fingers associated with polydactyly of the fourth fingers, and polydactyly of the fifth toe included in the web of the fourth and fifth toes. In addition, they showed many anomalies of the

metacarpal and metatarsal bones. With the exception of the patients of Alvord,⁴ all other published pedigrees described various anomalies of the metacarpal and metatarsal bones (table). This frequent association of syndactyly type II with involvement of the metacarpals or metatarsals raises the question of whether these anomalies are also a basic feature of synpolydactyly. These cases can be distinguished from syndactyly type V mainly by the presence of polydactyly; clinical inspection alone is not sufficient for a complete description of the patient's anomalies and *x*-rays, at least of the hands and feet, are obligatory.

As in our patients, all other published pedigrees of synpolydactyly showed absence of other major skeletal or extraskelatal anomalies. The association with minor local anomalies has only rarely been described with the exception of palmar dermatoglyphs.^{5 6} The absence of ventral skin creases on the fingers, the presence of a simian line, and prominence of the hypothenar region encountered in our patient may be minor features often seen in syndactyly type II.

Most characteristics of the pedigree under study (fig 1) point strongly to autosomal dominant inheritance with incomplete penetrance. Subject V.9 had no clinical evidence of the disorder, but had an affected offspring (VI.1). This non-manifesting heterozygote, or 'skipped generation', was encountered in all the other published pedigrees, except for the family of Ridler *et al.*⁶

TABLE Metacarpal/metatarsal involvement in synpolydactyly.

Pipkin <i>et al</i> ³	IV.28	Fourth and fifth metatarsal of each foot fused at the base Sixth metatarsal on each foot articulates independently of the fused fourth and fifth metatarsals
Cross <i>et al</i> ⁵	V.31	Third metacarpal bone appears widened
	III.5	Left foot has an extra metatarsal
Ridler <i>et al</i> ⁶	IV.2	Y shaped and duplicated fourth left metatarsal
Present pedigree	IV.2	Both first metatarsals short and thick with slight tibial deviation
	V.13	Y shaped third metacarpal with a hypoplastic ulnar arm
		Shorter fourth and fifth metacarpals
	V.14	Y shaped third metacarpals
		Shorter and narrower fourth and fifth metacarpals
		Six metatarsals: sixth had a baseball stick shape

References

- ¹ Temtamy S, McKusick VA. Synopsis of hand malformations with particular emphasis on genetic factors. *Birth Defects* 1969;**5**:146–55.
- ² Thomsen O. Einige Eigentuemlichkeiten der erblichen Poly- und Syndaktylie bei Menschen. *Acta Med Scand* 1927;**65**:609–44.
- ³ Pipkin SB, Pipkin AC. Variation of expression of polydactyly. *J Hered* 1946;**37**:93–6.
- ⁴ Alvord RM. Zygodactyly and associated variations in a Utah family. *J Hered* 1947;**38**:49–53.
- ⁵ Cross HF, Lerberg DB, McKusick VA. Type II syndactyly. *Am J Hum Genet* 1968;**20**:368–80.
- ⁶ Ridler MAC, Laxova R, Dewhurst K, Saldana-Garcia P. A family with syndactyly type II (synpolydactyly). *Clin Genet* 1977;**12**:213–20.

Correspondence and requests for reprints to Dr Paul Merlob, Department of Neonatology, Beilinson Medical Center, Petah Tiqva 49 100, Israel.