

# Trisomy 12 mosaicism in a 7 year old girl with dysmorphic features and normal mental development

C J English, J A Goodship, A Jackson, M Lowry, J Wolstenholme

**Abstract**

**We present the case of a mentally normal 7 year old girl with short stature, scoliosis, atrial septal defect, and dysmorphic features including linear pigmented streaks on the forearms and lower legs. Chromosome analysis of cultured fibroblasts showed trisomy 12 in 9% and 13% of cells from two skin biopsies. Two trisomy 12 cells were found in lymphocytes after analysis of 500 metaphases. Her clinical features are compared with those of other liveborn cases of trisomy 12 mosaicism and the problems of prenatal diagnosis of such an abnormality are discussed.**

(J Med Genet 1994;31:253-254)

There have been four cases in which mosaic trisomy 12 has been confirmed in tissues from liveborn persons. These comprise a 36 year old moderately mentally retarded woman with abnormal facies, short stature, and neuromuscular defects, a child with multiple malformations who died at the age of 5 weeks, a girl with normal cognitive function at 6 years of age but who is described as clumsy, and a 31 year old man with infertility and situs inversus (table).

We present the case of a 7 year old girl with trisomy 12 mosaicism and a combination of abnormalities that differs from the other four liveborn cases, and discuss the problems of prenatal detection of this chromosome abnormality.

**Case report**

The proband was the first child of unrelated white parents, the mother aged 26 and the father 29. The pregnancy was uneventful, labour was induced at 42 weeks' gestation, and delivery was normal, birth weight 3200 g.

Blood was sent for chromosome analysis in the neonatal period because of unusual facial features. Her motor milestones were delayed; she sat at 14 months and was nearly 3 years of age before she was able to walk. Other milestones were normal, however, smiling at 6 weeks and with comprehension, words, and play developing at the same times as in her younger normal sister.

She was seen again at 6 years of age when her height was less than the 3rd centile and she had a mild scoliosis. Her head circumference was between the 10th and 25th centiles. She had a flat profile with malar hypoplasia (fig 1). Her hair was fine, blonde, and slow growing but her teeth and nails were normal. There were linear pigmented streaks on her lower legs and forearms (fig 2). Cardiovascular examination at this time showed fixed splitting of the second heart sound with a pulmonary ejection murmur.

Chest x ray showed cardiomegaly and pulmonary plethora and the ECG showed right axis deviation right bundle branch block. A clinical diagnosis of an ostium secundum atrial septal defect was confirmed at operation. A skin biopsy was taken at the time of operation because of the clinical suspicion of mosaicism owing to the pattern of pigmentation. The skin biopsy was repeated at a later clinic visit. On neurological examination there was weakness of the quadriceps. She is unable to stand from a crouching position, goes upstairs one at a time, and gets up from the floor using Gower's manoeuvre. She attends a normal school and her performance is average in the class.

**CYTOGENETIC RESULTS**

Trypsin G banded chromosome analysis of phytohaemagglutinin stimulated lymphocytes in the neonatal period showed a 46,XX karyotype in 10 cells. Analysis of cultured fibro-

**Regional Genetics Service, University of Newcastle upon Tyne, 20 Claremont Place, Newcastle upon Tyne, NE2 4AA, UK**  
 C J English  
 J A Goodship  
 A Jackson  
 J Wolstenholme

**Sunderland District General Hospital, Kayll Road, Sunderland SR4 7TP, UK**  
 M Lowry

Correspondence to Dr English.

Received 11 August 1993  
 Accepted for publication 6 October 1993

*Cases of trisomy 12 mosaicism in liveborns*

Reference	Age	Sex	Amniocytes*	Fetal blood*	Blood*	Skin*	Other tissues*	Clinical features†
Case 1 <sup>1</sup>	36 y	F	NS	NS	7/53	0/80	NS	Mental retardation, <b>short stature</b> , microcephaly, dysmorphic facies, <b>scoliosis, neuromuscular defects</b>
Case 2 <sup>2</sup>	5 wk	F	7/16	0/100	0/30	5/20	Urine 0/50 Placenta 16/16	<b>Heart defect</b> , dysmorphic
Case 3 <sup>3</sup> (N J Leschot, personal communication)	6 y	F	76/140	NS	0/30	0/30	Urine 35/42	<b>Normal mental development</b> , clumsy
Case 4 <sup>4</sup>	31 y	M	NS	NS	11/157	NS	NS	Infertility, situs inversus, chronic sinusitis and bronchitis, <b>normal mental development</b>
Our case	7 y	F	NS	NS	2/500	6/56	NS	<b>Normal mental development</b> , abnormal facies, <b>short stature, scoliosis, heart defect</b> , abnormal skin pigmentation, fine hair

\* Trisomy 12 cells/total cells examined.  
 † = Common features in bold type.  
 NS = not studied.




Figure 1 Appearance of the proband.

blasts from a skin biopsy taken at the time of operation from apparently normal skin at the edge of the thoracic incision showed trisomy 12 in three out of 33 cells (9%). A repeat skin biopsy taken from apparently normal skin of the forearm showed three out of 23 cells with trisomy 12 (13%). Re-examination of the original neonatal blood slides showed trisomy 12 in two cells out of 500 (0.4%).

A cultured fibroblastic cell line from the patient, stored in liquid nitrogen, is available (reference number F92/0255).

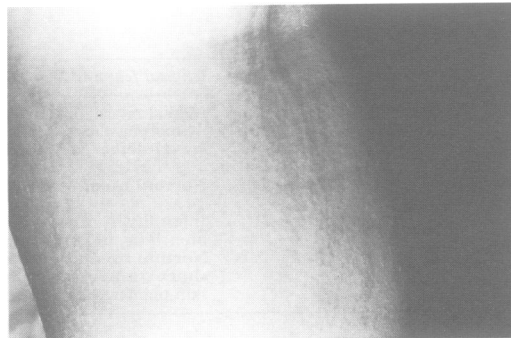


Figure 2 Linear pigmented streaks in the popliteal fossa.

## Discussion

The phenotype associated with trisomy 12 mosaicism is poorly defined. The limited overlap of features of the present case with those previously published is indicated in the table in bold. Although short stature, scoliosis, and neurological complications were apparent in both our patient and case 1, the latter was also microcephalic, with moderate mental retardation and different dysmorphic features. The more complex heart defect which led to the death of case 2 at 5 weeks of age precludes detailed comparison with our case. In common with our patient, case 3 has normal mental development and the possibility of a neurological defect since she is described as clumsy. Case 4 also showed normal mental development, but quite different clinical features; however, these features are all consistent with Kartagener syndrome.

The inconsistent clinical features of these cases may be attributable to the proportion of cells that are abnormal in different tissues, although there seems to be no clear correlation from the tissue types investigated in the cases described so far. Another factor which may affect the phenotype is imprinting. If, as had been described for chromosome 15,<sup>5</sup> an initially trisomic conception develops a disomic cell line by a correcting non-disjunction event, then the resulting phenotype may depend on the parental origin of the remaining chromosomes 12 in the apparently normal cell line, as well as the effect of trisomic cells. In fact, case 2 showed a non-mosaic trisomy 12 in the single analysis of cultured placental tissue after delivery.

The very low incidence of trisomic cells in the blood of our patient (0.4%), and the apparent normality of lymphocytes in cases 2 and 3 would suggest that cytogenetic analysis of fetal blood is an unreliable indicator of the fetal karyotype after prenatal detection of trisomy 12 mosaicism in either amniotic fluid or chorion villus samples. Our case not only adds further information to the phenotype associated with mosaic trisomy 12, but would have remained undetected were it not for the pigmentary dysplasia. Chromosome mosaicism is a well recognised cause of such pigmentation<sup>6</sup> and this emphasises the importance of chromosome analysis of skin fibroblasts in such subjects even if the blood karyotype is initially found to be apparently normal.

- 1 Patil SR, Bosch EP, Hanson JW. First report of mosaic trisomy 12 in a liveborn individual. *Am J Med Genet* 1983;14:453-60.
- 2 Von Koskull H, Ritvanen A, Ammala P, Gahmberg N, Salonen R. Trisomy 12 mosaicism in amniocytes and dysmorphic child despite normal chromosomes in fetal blood. *Prenat Diagn* 1989;9:433-7.
- 3 Leschot NJ, Wilmsen-Linders EJM, Van Geijn HP, Samson JF, Smit LME. Karyotyping urine sediment cells confirms trisomy 12 mosaicism detected at amniocentesis. *Clin Genet* 1988;34:135-9.
- 4 Richer CL, Bleau G, Chapdelaine A. Trisomy 12 mosaicism in an infertile man. *Can J Genet Cytol* 1977;19:565-7.
- 5 Cassidy SB, Lai LW, Erickson RP, et al. Trisomy 15 with loss of the paternal 15 as a cause of Prader-Willi syndrome due to maternal disomy. *Am J Hum Genet* 1992;51:701-8.
- 6 Flannery DB. Pigmentary dysplasias, hypomelanosis of Ito, and genetic mosaicism. *Am J Med Genet* 1990;35:18-21.